



Paper Accepted*

ISSN Online 2406-0895

Case Report / Приказ случаја

Emilija Nestorović^{1,†}, Duško Terzić¹, Svetozar Putnik¹, Arsen Ristić², Miljko Ristić¹

HeartMate 3 Fully Magnetically Levitated Left Ventricular Assist Device for Advanced Heart Failure

HeartMate 3 систем за асистирању потпору левој комори са потпуно магнетним левитирајућим мотором за узнатредовалу срчану слабост

¹ Clinical Center of Serbia, Clinic for Cardiac surgery, Department for Heart Transplant, Belgrade, Serbia;

² Clinical Center of Serbia, Cardiology Clinic, Serbia

Received: July 19, 2017

Revised: November 16, 2017

Accepted: November 22, 2017

Online First: December 8, 2017

DOI: <https://doi.org/10.2298/SARH170719202N>

* **Accepted papers** are articles in press that have gone through due peer review process and have been accepted for publication by the Editorial Board of the *Serbian Archives of Medicine*. They have not yet been copy edited and/or formatted in the publication house style, and the text may be changed before the final publication.

Although accepted papers do not yet have all the accompanying bibliographic details available, they can already be cited using the year of online publication and the DOI, as follows: the author's last name and initial of the first name, article title, journal title, online first publication month and year, and the DOI; e.g.: Petrović P, Jovanović J. The title of the article. *Srp Arh Celok Lek*. Online First, February 2017.

When the final article is assigned to volumes/issues of the journal, the Article in Press version will be removed and the final version will appear in the associated published volumes/issues of the journal. The date the article was made available online first will be carried over.

† **Correspondence to:**

Emilija NESTOROVIĆ

Clinic for Cardiac surgery, Clinical Center of Serbia, Koste Todorovica 8, 11 000 Belgrade, Serbia

E-mail: emanestor@gmail.com

HeartMate 3 Fully Magnetically Levitated Left Ventricular Assist Device for Advanced Heart Failure

HeartMate 3 систем за асистирану потпору левој комори са потпуно магнетним левитирајућим мотором за узнатредовалу срчану слабост

SUMMARY

Introduction As the waiting time for heart transplantation continues to increase due to shortage in organ donation, supporting patients with advanced heart failure with left ventricular assist device (LVAD) increases as well. The latest generation of LVAD, left ventricular assist system (LVAS) started to expand worldwide due to more promising outcomes.

The aim of this article was to present the case of treating advanced heart failure in a patient who underwent implantation of HeartMate 3 LVAS as bridge to transplantation.

Case presentation The patient is a 59 year-old man with advanced heart failure required drugs inotrope support with ischemic cardiomyopathy as underlying cause of heart failure. Therefore, in the absence of an adequate donor, it was decided to incorporate the LVAS as a bridge to transplantation. Patient had improvement of functional capacity, cardiac, renal and liver function.

Conclusion Use of a HeartMate 3 in advanced heart failure patient results in improvements in functional capacity, cardiac, renal and liver function. Further studies should be performed in order to identify whether improved outcomes are sustained with a longer follow-up period.

Keywords: LVAD; heart failure; heart transplantation

САЖЕТАК

Увод Услед недостака донорских органа, време чекања на трансплантацију срца све је дуже и све је већи број пацијената у узнатредовалој срчаној слабости који су лечени уређајима за асистирану циркулацију левог срца (УЦЛС). Због добрих резултата, широм света је започела примена најновије генерације УЦЛС, система за асистирану потпору леве коморе (САЛС).

Циљ овог рада је био да прикаже лечење болесника у узнатредовалој фази срчане слабости имплантацијом САЛС - *HeartMate 3*, као премошћавање периода до трансплантације срца.

Приказ болесника Мушкарац стар 59 година на инотропној потпори лековима, у узнатредовалој фази срчане слабости и исхемијском кардиомиопатијом као основним узроком. У одсуству донора, болеснику је уграђен САЛС за премошћавање периода до трансплантације срца. Код болесника је дошло до побољшања функционалног капацитета, срчане, реналне и хепатичке функције.

Закључак Употреба *HeartMate 3* код болесника у узнатредовалој срчаној слабости доводи до побољшања функционалног капацитета, срчане, реналне и хепатичке функције. Даља истраживања треба спровести у циљу откривања да ли се са временом праћења побољшани исходи одржавају.

Кључне речи: уређаји за асистирану циркулацију; срчана слабост; трансплантација срца

INTRODUCTION

Patients with advanced heart failure (HF) have quite limited possibilities for therapy so there is an unacceptably high morbidity and mortality in connection to the disease. In light of the insufficient availability of donor hearts and growing number of heart transplantation (HT) ineligible patients, left ventricular assist devices (LVAD) are often used to support patients with advanced HF awaiting HT or as destination therapy (DT) [1]. In order to improve clinical outcomes of LVAD therapy technological advances have been made through different types of LVAD pumps over the past 30 years, from pulsatile to continuous flow (CF) and now back to artificial pulsatility. Compared to the pulsatile flow HM XVE, the newer generation of LVAD and CF-LVAD is considerably smaller, with significantly lower incidence of adverse events and has become the standard of care as a bridge to transplantation (BTT) [1]. HeartMate (HM) II (Abbott Corporation) is an axial pump that provides CF, which requires a tissue pocket and a larger body surface of the patient, while other intrapericardial CF pumps, like HeartWare (HeartWare Inc.), utilize a magnetically levitating rotor system to decrease mechanical wear in order to reduce hemolysis and the incidence of pump thrombosis. Also, due to

smaller size it is suitable for patients with smaller body surface area [2]. Despite the fact that with the newer generation of LVAD, survival rate is much better, the overall adverse events are still significantly high [3]. Therefore, technology enhancements of LVAD have become increasingly important in order to improve post LVAD outcomes and to reduce the rate of adverse events. The latest generation pump, HM 3 (Abbott Corporation) is intrapericardial fully magnetically levitated CF-LVAD with artificial pulsatility with large, consistent pump gaps designed to reduce blood trauma and minimize stasis of blood.

The aim of this article was to present the case of treating the end-stage of HF in a patient who has been implanted the latest generation of LVAD, left ventricular assist system (LVAS), HM 3.

CASE REPORT

The patient is a 59 year-old man with advanced HF, with ischemic cardiomyopathy as underlying cause. Ten months prior to hospitalization at our institution the patient suffered from acute heart infarction of the anterior wall as the first manifestation of coronary disease. Since the patient was admitted to a local hospital after 24 hours had passed, neither percutaneous coronary intervention nor fibrinolysis were applied. At the local hospital patient underwent coronary angiography that showed occlusion of the left anterior descending coronary artery and stenosis of the proximal circumflex coronary artery and he was treated with medicaments. After the acute ischemic phase, the hospital treatment was hindered by the development of left ventricular (LV) aneurysm and the appearing symptoms of HF. He complained of fatigue when he was at rest, choking, chest pain and swellings in the legs. Ten months after the myocardial infarction he came to our institution due to symptoms of advanced HF and required drugs inotrope support. Both two-dimensional transthoracic echocardiography (TTE) and transesophageal echocardiography (TEE) were performed in a standard manner using Vivid E 9 (GE Medical Systems, Milwaukee, WI) and showed a volume overload of LV (EDV 257ml), increased LV end-diastolic (LVEDD) and end-systolic diameters (LVESD), 7.4 cm and 6.3 cm, respectively, and significantly decreased ejection fraction of LV (LVEF) to 18% calculated by Biplane method. There were akinesis in the LV septum, apex, apical part of anterolateral and inferior walls, apical and medial part of the anterior wall with LV apex aneurysm without visible thrombotic masses. Severe mitral regurgitation (MR 3+) was present. The right ventricle had regular dimensions (2.6 cm) with good systolic and longitudinal functions (global fractional area change (FAC) 27%, tricuspid annular plane systolic excursion (TAPSE) 21mm and right ventricular systolic excursion velocity (RV S') 18 cm/s). There was severe functional tricuspid regurgitation (TR 3+) with high right ventricle systolic pressure (RVSP 77mmHg). Single-photon emission computed tomography showed the absence of viable myocardium of the septum, anterior and lateral wall of the LV. Preoperative hemodynamic data showed pulmonary capillary wedge pressure (PCWP) 27 mmHg, central venous pressure (CVP) 11mmHg, cardiac index (CI) 1.9 l/min/m². In order to assess possibility of implantation LVAS, the nature of the LV apex aneurysm was estimated by performing

magnetic resonance imaging of the heart. At the part of LV apex aneurysm the myocardial wall thickness was 3-5 mm with aneurysmal extension which was borderline finding for pump implantation. Based on all tests that were done it was concluded that patient is in the end-stage of HF (New York Heart Association (NYHA) IV, Interagency Registry for Mechanically Assisted Circulatory Support (INTERMACS) 3, with significantly impaired LV function required continuous inotropic support, and therefore it was decided in the absence of an adequate donor to incorporate the LVAS as a BTT.

The patient underwent surgery under general anesthesia. The surgery included the implantation of LVAS, HM 3. After median sternotomy, in conditions of extracorporeal circulation without aortic clamping and stopping of the heart, the LV was opened at the top, the ring sewn, and after preparation the pump was connected to the ring. Drive line was placed through the skin in the form of double tunneling and connected to the pump controller and the energy source. Finally, a graft was sewn to the aorta (Figure 1). Unlike LVAD HM2 device where it is necessary to form a tissue pocket to place the device, LVAS HM3 was applied fully intrapericardially. The intervention passed without complications.

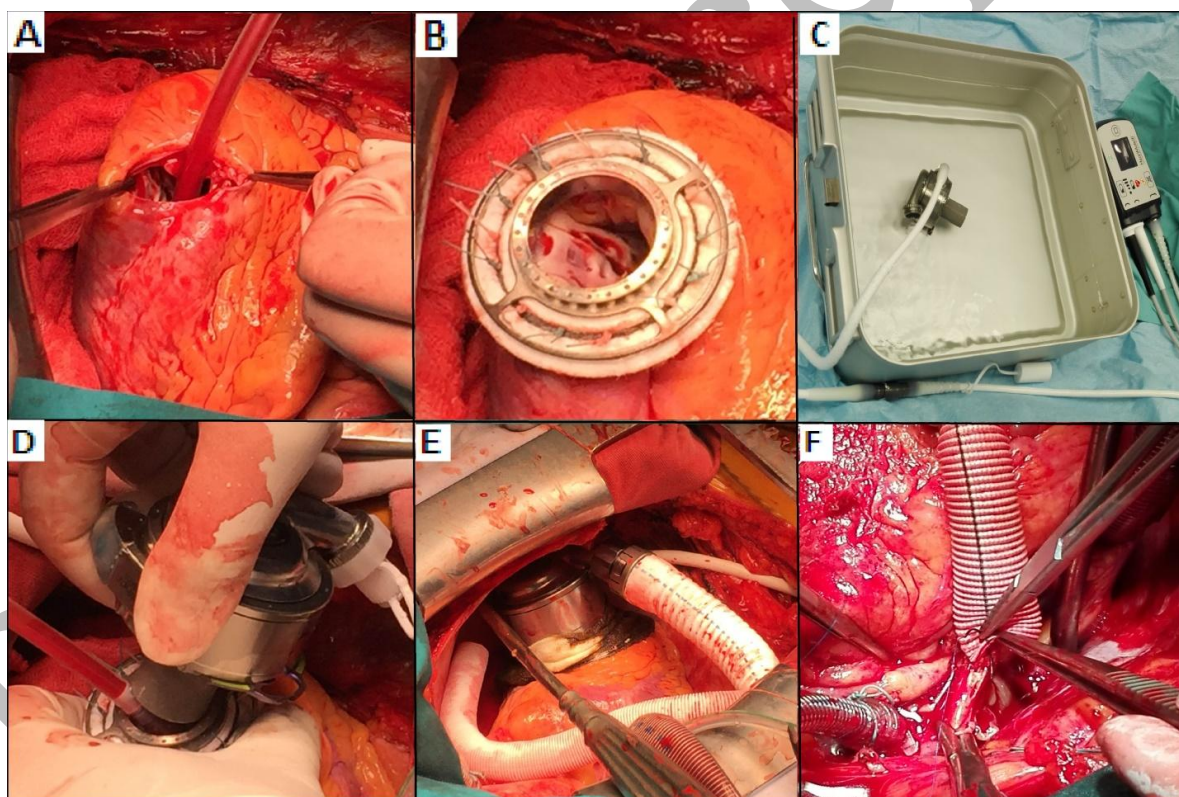


Figure 1. Left ventricular assist system, HeartMate 3 implantation. a) left ventricle open at the top, b) sewn ring at the left ventricle, c) preparation the pump, d) connecting pump to the ring, e) connected pump in pericard cavity, f) outflow graft sewn to the aorta.

The postoperative recovery passed without complications. After LVAS implantation, a standardized anticoagulation regimen was used with initiation of infusion of heparin followed by transition to warfarin as well as aspirin. Anticoagulation therapy was included in order to maintain INR from 2.0 to 3.0. There were normal flow through both pump's inflow and outflow cannula. The

pump speed was set at 4900 rpm, with pump flow 3.4 l/min and pump power 3.2w. There were stable LVAS parameters and data on the pump controller. Radiographic finding was regular (Figure 2). Postoperative hemodynamic data showed PCWP 10 mmHg, CVP 7 mmHg, CI 3.2 l/min/m².

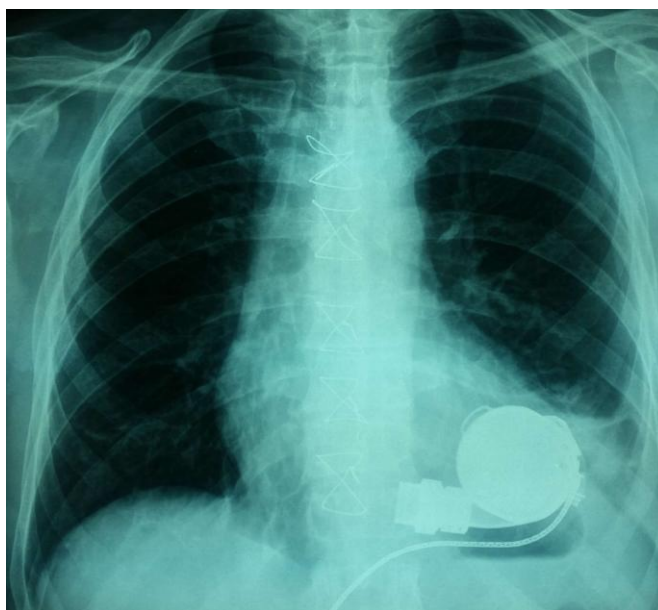


Figure 2. Radiographic finding after left ventricular assist system, HeartMate 3 implantation.

Functional cardiac (TTE and brain-type natriuretic peptide (BNP)), renal and liver function assessments were done before LVAD implantation, at discharge from hospital and at 12 months. TTE examination at discharge showed improvement in LVEDD and LVESD from baseline values of 7.4 and 6.3 to 5.5 and 4.5 respectively. This improvement was sustained over the time of the follow-up. For LVEF and BNP (pg/ml), the baseline values of 18% and 670, improved to 39% and 173, respectively, and continued to improve during the period of 12 months to

50% and 120, respectively. The dimension of the right ventricle was sustained in normal range (2,6 cm) with a good systolic function. At discharge NYHA functional classification improved from IV at baseline to II and continued to improve during the period of 12 months to I. There were improvements in renal function from baseline estimated glomerular filtration rate (ml/min/1.73m²) and serum creatinine (nmol/l) of 40 and 155 to 57 and 114 respectively and there was no change for the whole follow-up period. With regard to hepatic function, total bilirubin [umol/l] showed a reduction at discharge point (25.8 vs. 12.4), with no further change afterwards. There were no significant changes of AST [IU/l], and ALT [IU/l] values during the whole follow-up period.

DISCUSSION

HT remains the treatment of choice in cardiac replacement therapy for patients with end – stage HF. As the waiting time for HT continues to increase, supporting patients with LVAD increases as well. LVAD support enables improved quality of life and survival compared to medical therapy [4]. However, despite all of these benefits of new technology of LVAD, there is still significant incidence of device-related complications that may have lessened enthusiasm for investigating LVAD therapy in less sick patients [5]. LVAD technology is advancing continuously and rapidly. Smaller devices, total implantability, artificial pulsatility, and remote monitoring are being investigated which will broaden LVAD technology application. The outcomes in patients supported by LVAD have improved along with experience and technology advances. The HM 3 LVAS is a new centrifugal-flow device which uses full magnetic levitation allowing wide and consistent flow paths and an artificial pulse

designed for enhanced hemocompatibility. It uses a fully magnetically levitated rotor with frictionless movement that excludes heat generation and wear of the moving component. During operation, blood from the LV enters the inflow cannula and pump along a central axis and is propelled through the wide-gap impeller blades of the rotor and finally out through the outflow graft. The power cable from the pump housing is externalized and connected to a modular cable that is attached to the external system controller and a power supply. The pump receives power from a power module or mobile power unit for wall power, or from a pair of 14-V lithium-ion batteries. The pump operates at a rotor speed in the range of 3000-9000 rpm and the maximum flow rate is 10 l/min. The LVAS operates continuously in an artificial pulse mode, where the rotor speed changes rapidly every 2 s to generate pulsatile flow from the pump [6].

Use of a HeartMate 3 in advanced HF patients results in improvements in functional capacity, cardiac, renal and liver function. LVAD technology is quickly evolving and its accessibility is increasing if compared to HT. Further studies should be performed in order to identify whether improved outcomes are sustained with longer follow-up period.

REFERENCES

1. Kirklin JK, Naftel DC, Kormos RL, Stevenson LW, Pagani FD, Miller MA, et al. The Fourth INTERMACS Annual Report: 4,000 implants and counting. *J Heart Lung Transplant*. 2012; 31: 117–26.
2. Sajgalik P, Grupper A, Edwards BS, Kushwaha SS, Stulak JM, Joyce DL, Joyce LD, Daly RC, Kara T, Schirger JA. Current Status of Left Ventricular Assist Device Therapy. *Mayo Clin Proc*. 2016; 91(7): 927–40.
3. Kirklin JK, Naftel DC, Pagani FD, Kormos RL, Stevenson LW, Blume ED, et al. Seventh INTERMACS annual report: 15,000 patients and counting. *J Heart Lung Transplant*. 2015; 34: 1495–504.
4. Estep JD, Starling RC, Horstmanshof DA, Milano CA, Selzman CH, Shah KB, et al. Risk Assessment and Comparative Effectiveness of Left Ventricular Assist Device and Medical Management in Ambulatory Heart Failure Patients: Results From the ROADMAP Study. *J Am Coll Cardiol*. 2015; 66(16): 1747–61.
5. Grimm JC, Magruder JT, Kemp CD, Shah AS. Late Complications Following Continuous-Flow Left Ventricular Assist Device Implantation. *Front Surg*. 2015; 2: 42.
6. Netuka I, Sood P, Pya Y, Zimpfer D, Krabatsch T, Garbade J, et al. Fully Magnetically Levitated Left Ventricular Assist System for Treating Advanced HF: A Multicenter Study. *J Am Coll Cardiol*. 2015; 66(23): 2579–89.