



СРПСКИ АРХИВ
ЗА ЦЕЛОКУПНО ЛЕКАРСТВО
SERBIAN ARCHIVES
OF MEDICINE

Address: 1 Kraljice Natalije Street, Belgrade 11000, Serbia

+381 11 4092 776, Fax: +381 11 3348 653

E-mail: office@srpskiarhiv.rs, Web address: www.srpskiarhiv.rs

Paper Accepted*

ISSN Online 2406-0895

Original Article / Оригинални рад

Miloš Trajković¹, Nikola Živković^{2,3,†}, Dragan Krasić^{1,2}, Andrija Ćosić¹, Vojkan Lazić¹,
Miloš Stojanović¹, Ana Cvetanović^{2,4}, Staša Krasić⁵

**Clinical characteristics and surgical treatment of dacryocystitis –
a ten-year retrospective study**

Клиничке карактеристике и хируршки третман дакриоциститиса –
десетогодишња ретроспективна студија

¹Clinic of Dentistry, Niš, Serbia;

²University of Niš, Faculty of Medicine, Niš, Serbia;

³Niš Clinical Centre, Pathology and Pathological Anatomy Center, Niš, Serbia;

⁴Niš Clinical Centre, Oncology Clinic, Niš, Serbia;

⁵University of Belgrade, Faculty of Medicine, Belgrade, Serbia

Received: October 12, 2018

Revised: September 26, 2019

Accepted: October 16, 2019

Online First: October 17, 2019

DOI: <https://doi.org/10.2298/SARH181012114T>

***Accepted papers** are articles in press that have gone through due peer review process and have been accepted for publication by the Editorial Board of the *Serbian Archives of Medicine*. They have not yet been copy-edited and/or formatted in the publication house style, and the text may be changed before the final publication.

Although accepted papers do not yet have all the accompanying bibliographic details available, they can already be cited using the year of online publication and the DOI, as follows: the author's last name and initial of the first name, article title, journal title, online first publication month and year, and the DOI; e.g.: Petrović P, Jovanović J. The title of the article. *Srp Arh Celok Lek*. Online First, February 2017.

When the final article is assigned to volumes/issues of the journal, the Article in Press version will be removed and the final version will appear in the associated published volumes/issues of the journal. The date the article was made available online first will be carried over.

†**Correspondence to:**

Nikola ŽIVKOVIĆ

Pathology and Pathological Anatomy Center, Niš Clinical Centre, 48 Dr Zoran Đinđić Boulevard, Niš 18000, Serbia

E-mail: nikola.zivkovic@medfak.ni.ac.rs

Clinical characteristics and surgical treatment of dacryocystitis – a ten-year retrospective study

Клиничке карактеристике и хируршки третман дакриоциститиса – десетогодишња ретроспективна студија

SUMMARY

Introduction/Objective Nasolacrimal duct obstruction with consequent epiphora and the development of dacryocystitis represents a common pathological entity in the clinical practice of ophthalmologists and maxillofacial surgeons. The etiology of dacryocystitis is multifactorial and still hasn't been clarified in detail. It is considered that ascending infections from the nasal cavity and paranasal sinuses, injuries and surgical interventions in the middle third of the face, dacryoliths, tumors of the lacrimal sac and surrounding structures may be some of the etiological factors of nasolacrimal duct obstruction. The aim of this study is to present clinical characteristics and surgical treatment of dacryocystitis.

Methods A retrospective study was carried out. It covered a period of 10 years during which 49 patients with clinically verified Dacryocystitis (DC) were treated after surgical examination and complete diagnostics. 37 patients out of the total number underwent surgery.

Results The occurrence of predisposing factors was present in 80% of the patients - rhinitis and the inflammation of paranasal sinuses in 27 patients (72%), injuries and surgical interventions in the middle third of the face in 9 patients (24%), whereas lacrimal sac and nasolacrimal duct tumors were noted in 3 patients (8%). Surgical failure, which was manifested in terms of recurrent dacryocystitis and epiphora, was noted in 6 cases (16%).

Conclusion Regarding the possible complications of inadequately administered antibiotic therapy and a broad spectrum of pathological entities which comprise the differential diagnosis, dacryocystorhinostomy with an adequate histopathological analysis and appropriate antibiotic therapy in the acute stage represents a right way for the treatment of dacryocystitis.

Keywords: dacryocystitis; predisposing factors; differential diagnosis; surgical treatment

САЖЕТАК

Увод/Циљ Обструкција дренаже назолакрималног канала са последичном епифором и развојем дакриоциститиса представља учестали патолошки ентитет у клиничкој пракси офталмолога и максилороцијалног хирурга. Етиологија дакриоциститиса је мултифакторијална и још увек није разјашњена до детаља. Сматра се да асцендентно ширење инфекције из носног кавитета и параназалних синуса, повреде и хируршке интервенције у пределу средње трећине лица, дакриолити, тумори лакрималног сакуса и околних структура могу бити неки од етиолошких фактора опструкције дренаже назолакрималног канала. Циљ ове студије је приказивање клиничких карактеристика и хируршког лечења дакриоциститиса.

Метод Обављена студија је ретроспективна. Обухватила је период од 10 година у којем је након хируршког прегледа и комплетне дијагностике лечено 49 пацијената са клинички евидентним дакриоциститисом од којих је оперисано њих 37.

Резултати Појава предиспонирајућих фактора се среће код 80% пацијената - присуство ринитиса и запаљења параназалних синуса код 27 пацијената (72%), повреде и хируршке интервенције у пределу средње трећине лица код 9 пацијената (24%), док је појава тумора лакрималног сакуса и назолакрималног дуктуса уочена код 3 пацијента (8%). Оперативни неуспех који се манифестовао појавом рекурентног дакриоциститиса и епифоре уочен је у 6 (16%) случајева.

Закључак С обзиром на могуће компликације неадекватно ординираних антибиотске терапије и широк спектар патолошких ентитета који чине диференцијалну дијагнозу, дакриоцисториностомија уз адекватну хистопатолошку анализу и одговарајућу антибиотску терапију у акутној фази представља сигуран начин за терапију дакриоциститиса.

Кључне речи: дакриоциститис; предиспонирајући фактори; диференцијална дијагноза; хируршко лечење

INTRODUCTION

Nasolacrimal duct obstruction (NLDO) with consequent epiphora and the development of dacryocystitis (DC) represents a common pathological entity in the clinical practice of ophthalmologists and maxillofacial surgeons [1].

The etiology of DC is multifactorial and still hasn't been clarified in detail. It is considered that ascending infections from the nasal cavity and paranasal sinuses, injuries and surgical interventions in the middle third of the face, dacryoliths, tumors of the lacrimal sac and surrounding structures may be some of the etiological factors of NLDO [2].

The acute dacryocystitis (ADC) is characterized by the appearance of hyperemia and a painful swelling in the medial canthus region, as opposed to the chronic form (CDC) which is characterized by a persistent painless swelling in the mentioned region with signs of mucopurulent exudation from the lacrimal punctum, epiphora, chronic conjunctivitis and episodes of exacerbation of the chronic process.

The congenital form of DC is statistically the rarest form found in 5% of infants [3]. It is a very serious disease characterized by a high mortality rate if not treated adequately.

The initial treatment of ADC implies a systemic and local administration of antibiotics, incision and drainage of the lacrimal sac content which leads to decompression, evacuation of content, and possible microbiological analyses. The absence of treatment of the acute stage may lead to complications such as preseptal and orbital cellulitis, meningitis and cavernous sinus thrombosis.

The final treatment involves dacryocystorhinostomy (DCR), which can be external or endonasal. Both procedures, external dacryocystorhinostomy (ext-DCR), described by AddeoToti in 1904, and endonasal dacryocystorhinostomy (endo-DCR), described by Caldwell in 1983, have undergone numerous modifications over time [4].

The aim of this study is to present clinical characteristics and surgical treatment of DC.

METHODS

A retrospective study was carried out. It covered a period from 2006. to 2015. during which 49 patients with clinically verified DC were treated after a surgical examination and complete diagnostics. 37 patients out of the total number underwent surgery.

All patients were surgically treated under general anesthesia (GA) at Maxillofacial Surgery Clinic, Faculty of Medicine, University of Niš.

The analysis included the gender and age of patients, existence of chronic diseases, occurrence of predisposing factors, i.e. existence of rhinitis, sinusitis, as well as injuries or surgical interventions in the middle third of the face. It also studied clinical characteristics of DC in terms of acute or chronic presentation of the process, localization, histopathology, microbiological analyses, recurrence and postoperative complications of all patients which involved epiphora or recurrent DC. All patients underwent external dacryocystorhinostomy under general endotracheal anesthesia along with keeping a silicone tube for two months (Figures 1, 2).

Classic ext-DCR with mono or bicanicular silicone intubation, depending on the clinical manifestation of DC, was performed in all patients. The purpose of the above surgical procedures is based on the removal of the cystic sacs and the de novo formation of the nasolacrimal duct, which allows the normalization of the function of the lacrimal apparatus.

The minimal period of postoperative monitoring was 18 months.

A Multi slice computerized tomography (MSCT) was performed preoperatively in four patients with suspected lacrimal sac tumor in order to determine the extent of process and to plan further treatment.

This paper was approved by the institutional ethics committee, and written consent was obtained from the patients for the publication of this study and any accompanying images.

RESULTS

The mean age of the mentioned group of patients was 56, with the age interval ranging from 27 to 72. Considering gender, 28 patients (75%) were females, whereas 9 patients included in the study (25%) were males.

The presence of chronic systemic diseases was determined in 30 patients (81%). Chronic arterial hypertension was present in 20 patients, diabetes mellitus in 10, chronic obstructive pulmonary disease in 8, glaucoma in 5, and hyperthyroidism and rheumatoid arthritis in 4 patients.

The occurrence of predisposing factors was present in 80% of the patients (Table 1); 18 patients consulted a doctor in the acute stage of the disease. They were treated with broad-spectrum antibiotics (cephalosporines II or III generation and clindamycin) until clinical and laboratory results indicated the regression of the signs of infection. Incisions in the sac region were made in 10 cases. The acute stage of dacryocystitis was more frequent in younger patients.

Initially, a chronic process was present in 31 patients. The congenital form of DC was not included in the study.

Dacryocystitis was more common on the left than on the right side (Figure 3).

Microbiological analyses indicated dominant presence of gram-positive flora. *Staphylococcus aureus*, *Staphylococcus pneumonia* and *Staphylococcus epidermidis* were isolated in 85% of cases, equally present both in the acute and chronic process. Methicillin-resistant *Staphylococcus aureus* (MRSA) was isolated in two cases. Gram-negative bacteria, *Hemophilus influenzae*, *Pseudomonas aeruginosa*, *Neisseria* and *Klebsiella* were isolated in 10 patients, exclusively in the acute stage of dacryocystitis. Three microbiological findings of chronic dacryocystitis were negative.

Surgical failure, which was manifested in terms of recurrent dacryocystitis and epiphora, was noted in 6 cases (16%).

In three patients after DCR, a recurrence of the disease appeared on average four weeks after the surgery. Initially, the patients in question were diagnosed with acute dacryocystitis which was treated with broad-spectrum antibiotics and incisions. Given that microbiological

findings indicated the presence of gram-negative bacteria, no recurrences were noted after the administration of therapy based on the antibiogram.

In two cases, the anamnesis showed the existence of long-standing episodes of chronic dacryocystitis treated out-patiently at another medical institution. After DCR had been performed, a recurrence of the underlying disease appeared two weeks after the removal of stitches. Considering that microbiological analyses indicated the existence of MRSA, the patients were treated with intensive antibiotic therapy with vancomycin, after which the signs of infection regressed. Reinterventions were carried out after the regression of infection, after which no recurrences were noted.

In one case, recurrences appeared two weeks after the accidental loss of a silicone tube. No recurrences were noted after the reintervention and placing a new silicone tube.

Histopathological (HP) analyses after DCR indicated that chronic nongranulomatous inflammation was reported in 34 cases (91%) (Figure 4), the presence of papilloma in 2 cases, whereas lacrimal sac adenocarcinoma was reported in only one case.

DISCUSSION

Dacryocystitis is the inflammation of the lacrimal sac clinically presented in the acute and chronic form.

The process is more frequent in females above the age of 40, contrary to the congenital form which is equally present in both sexes and represents 1% of the total number of all types of dacryocystitis [5]. A more frequent occurrence of DC in females than in males is explained by a smaller diameter of the nasolacrimal duct and therefore bigger chances for the appearance of a pathway and consequent infection. The acute form of dacryocystitis is more common in the young. Similar results were presented in the study by BahramEshaghiet et al [6].

Greater incidence of dacryocystitis on the left compared to the right side is a consequence of a sharper angle between the lacrimal sac and the nasolacrimal duct, therefore creating a greater possibility for the disruption of drainage, pathway, and a consequent infection, which is in correlation with the results of the study [7].

Ext-DCR, which uses transcutaneous access to enable exquisite visibility of the operative field, more control over intraoperative complications and a shorter surgical course, is a surgical method of choice in treating dacryocystitis. The success of the mentioned technique ranges from 80% to 96%, which is also in correlation with the results of our study [8].

In all cases, a silicone tube was placed despite the research conducted by Feng YF et al. [9] who concluded that success of the initial ext-DCR both with and without placing a silicone tube was identical.

The process of endo-DCR, which statistically shows identical success as the aforementioned procedure, has never been carried out in our institution due to lack of technical possibilities [10].

Microbiological analyses indicated the presence of combined bacterial flora, i.e. the presence of both gram-positive and gram-negative bacteria.

A study which included microbiological findings from 84 AC and CDC reported that *Staphylococcus aureus* was the most common gram-positive bacteria present in 28.8% of cases, equally present both in acute and chronic processes [11]. The existence of MRSA, which has been statistically increasing since 1998, is related to frequent episodes of exacerbation of the chronic form of the disease and the appearance of recurrences after DCR [12]. Gram-negative bacteria, with *Haemophilus influenzae*, *Pseudomonas aeruginosa*, *Neisseria*, *Klebsiella* and *Escherichia coli* being the most common ones, are in most cases associated with the acute form of dacryocystitis, foudroyant clinical course and frequent recurrences [13].

In a study which retrospectively encompassed 377 HP findings after performed DCR, Anderson NG et al. [14] reported dominant presence of chronic nongranulomatous inflammation (321, 85.1%), granulomatous inflammation including sarcoidosis (8, 2.1%), lymphoma (7, 1.9%) and a total of five malignant tumors. The authors of the study stressed out that the clinical course of the mentioned malignancies completely corresponded to the clinical image of CDC and suggested an obligatory HP analysis after each DCR. Dominant presence of chronic inflammation (85.1%) marked rhinitis and inflammation of paranasal cavities as possible etiological factors of DC. The results of the aforementioned study are in correlation with our results.

A study by Daniel R. Lefebvre et al. [15], which included 49 patients with performed DCR, reported surgical failure in 7 cases (13%). Surgical failure occurred in patients with MRSA, gram-negative bacteria, rhinosinusitis, lymphoma, early loss of a silicone tube and Crohn's disease. In our study, the reasons of DCR failure were associated with MRSA infection in two cases, gram-negative bacteria infection also in two cases, and accidental loss of a silicone tube in one case. The occurrence of surgical failure associated with MRSA and gram-negative bacteria is also emphasized in studies of other authors [16].

The available literature suggests that the recommended silicone tube retaining time after DCR is at least two months [17]. Accidental loss or early removal is associated with the appearance of NLDO. In our study, all patients had the tube removed after two months, except for one patient, i.e. a case of accidental loss. In a study which included 25 patients with evidently high risk of postoperative failure after DCR, Sodhi PK et al. [18] suggested the removal of a silicone tube 6 months after surgery.

CONCLUSION

Dacryocystitis a common pathological entity in everyday clinical practice, more frequent in women above the age of 40.

Given the possible complications, inadequately administered antibiotic therapy and a broad spectrum of pathological entities which comprise the differential diagnosis, dacryocystorhinostomy with an adequate histopathological analysis and appropriate antibiotic therapy in the acute stage represents a right way for the treatment of dacryocystitis.

The success of the mentioned procedure, which statistically varies from 80% to 90%, confirms our choice of therapy in the treatment of DC.

Conflict of interest: None declared.

REFERENCES

1. Harish V, Benger RS. Origins of lacrimal surgery, and evolution of dacryocystorhinostomy to the present. *Clinical and Experimental Ophthalmology* 2014; 42: 284–287. [DOI: 10.1111/ceo.12161]
2. Wladis E.J., Shinder R., LeFebvre D., Sokol J., Boyce M. Clinical and microbiologic features of dacryocystitis-related orbital cellulitis. *Orbit* 2016; 35(5):258–261.[DOI: 10.1080/01676830.2016]
3. Goel R, Nagpal S, Kumar S, et al. Transcanalicular laser-assisted dacryocystorhinostomy with endonasal augmentation in primary nasolacrimal duct obstruction: our experience. *OphthalPlastReconstr Surg* 2017; 33:408–12.[DOI: 10.1097/IOP.0000000000000802]
4. Raposo A, Piqueras F, García-Purriños F, et al. Influence of septal deviation on the prognosis of transcanalicular diode laser-assisted dacryocystorhinostomy. *J Ophthalmol.* 2016; 2016:9573760 [DOI: 10.1155/2016/9573760]
5. Li EY, Wong ES, Wong AC, Yuen HK. Primary vs Secondary Endoscopic Dacryocystorhinostomy for Acute Dacryocystitis With Lacrimal Sac Abscess Formation: A Randomized Clinical Trial. *JAMA Ophthalmol.* 2017;135(12):1361-1366.[DOI: 10.1001/jamaophthalmol.2017.4798]
6. Pornpanich K, Luemsamran P, Leelaporn A, et al. Microbiology of primary acquired nasolacrimal duct obstruction: simple epiphora, acute dacryocystitis, and chronic dacryocystitis. *ClinOphthalmol* 2016; 10:337–342.[DOI: 10.2147/OPHTH.S100280]
7. Feijó ED, Caixeta JA, de Souza Nery AC, et al. A comparative study of modified transcanalicular diode laser dacryocystorhinostomy versus conventional transcanalicular diode laser dacryocystorhinostomy. *Eur Arch Otorhinolaryngol* 2017; 274:3129–3134.[DOI: 10.2147/OPHTH.S100280]
8. Pandya VB, Lee S, Benger R, et al. External dacryocystorhinostomy: assessing factors that influence outcome. *Orbit* 2010; 29(5):291-297. [DOI:10.3109/01676830.2010.485715]
9. Feng YF, Cai JQ, Zhang JY, Han XH. A meta-analysis of primary dacryocystorhinostomy with and without silicone intubation. *Can J Ophthalmol* 2011; 46(6):521-527.[DOI: 10.1016/j.cjjo.2011.09.008]
10. Ozsutcu M, Balci O, Tanriverdi C, Demirci G. Efficacy of adjunctive mitomycin C in transcanalicular diode laser dacryocystorhinostomy. *Eur Arch Otorhinolaryngol* 2017; 274:873–877.[DOI: 10.1007/s00405-016-4308-7]
11. Prakash R, GirishBabu RJ, Nagaraj ER, Prashanth HV, Jayashree SS. A Bacteriological study of dacryocystitis. *JCDR* 2012; 6(4):652–655.
12. Wong ES, Chow CW, Luk WK, Fung KS, Li KK. A 10-Year Review of Ocular Methicillin-Resistant *Staphylococcus aureus* Infections: Epidemiology, Clinical Features, and Treatment. *Cornea* 2017; 36:92–97.[DOI: 10.1097/ICO.0000000000001048]
13. Pfeiffer M., Hacopian A., Merritt H., Phillips M., Richani K. Complete vision loss following orbital cellulitis secondary to acute dacryocystitis. *Case Rep Ophthalmol Med* 2016; 9630698.[DOI: 10.1155/2016/9630698]
14. Anderson NG, Wojno TH, Grossniklaus HE. Clinicopathologic findings from lacrimal sac biopsy specimens obtained during dacryocystorhinostomy. *Ophthal Plast Reconstr Surg* 2003; 19(3):173-176.
15. Lefebvre DR, Dhar S, Lee I, Allard F, Freitag SK. External dacryocystorhinostomy outcomes in patients with a history of dacryocystitis. *Digit J Ophthalmol* 2015; 21(3):1–22.[DOI: 10.5693/djo.01.2014.08.001]
16. Pandit VK, Jehan M, Pathak N, et al. To analyse the success rate of external dacryocystorhinostomy related with anatomical osteotomy size made during surgery. *Int J Appl Res* 2018; 4:354–358.
17. Eshraghi B, Hashemian H, Fard MA, Safizadeh M. Lacrimal sac empyema incision and drainage followed by early external dacryocystorhinostomy. *Orbit* 2013; 32(5):278–280.[DOI: 10.3109/01676830.2013.799704]
18. Sodhi PK, Pandey RM, Malik KP. Experience with bicanalicular intubation of the lacrimal drainage apparatus combined with conventional external dacryocystorhinostomy. *J Craniomaxillofac Surg* 2003; 31:187–190.

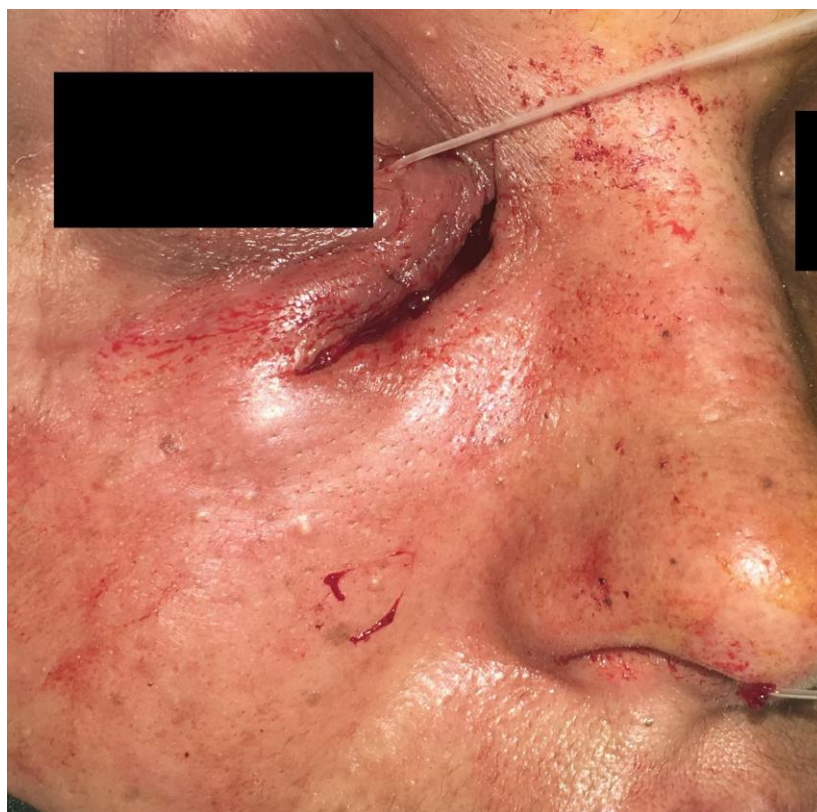

Figure 1. Condition after silicone single-channel tube placement; the photograph is used with the permission of the subject

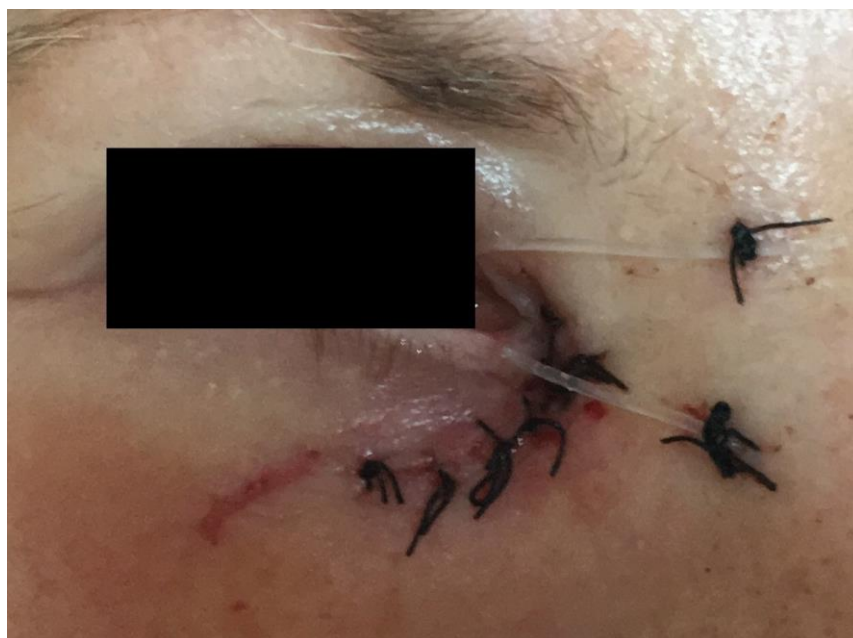

Figure 2. Condition after silicone double-channel tube placement; the photograph is used with the permission of the subject

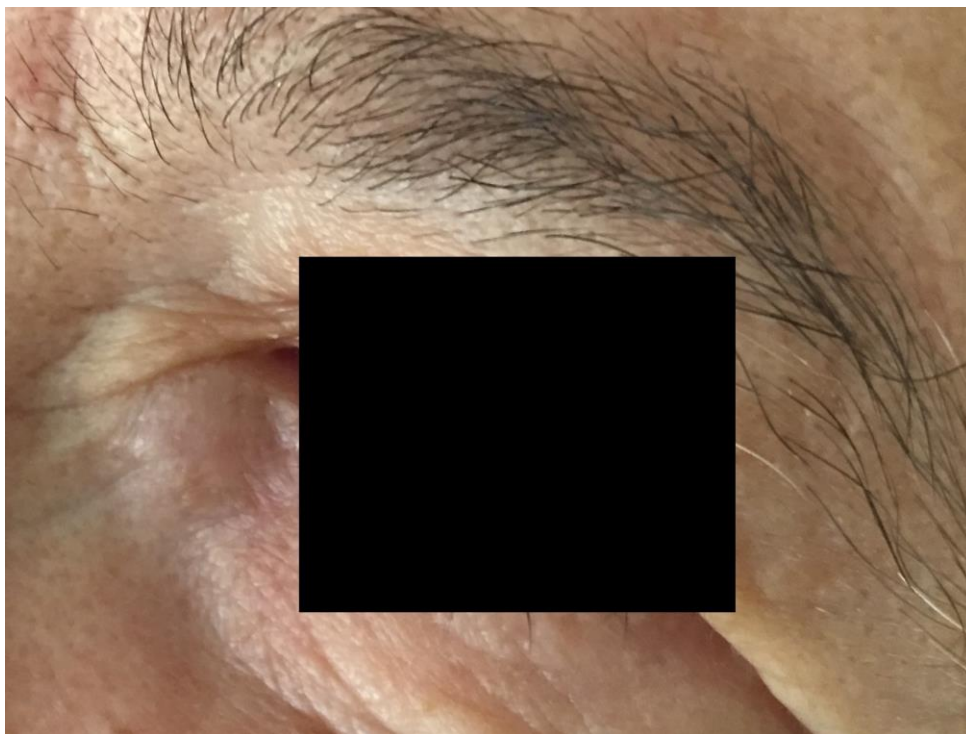

Figure 3. Chronic form of dacryocystitis; the photograph is used with the permission of the subject

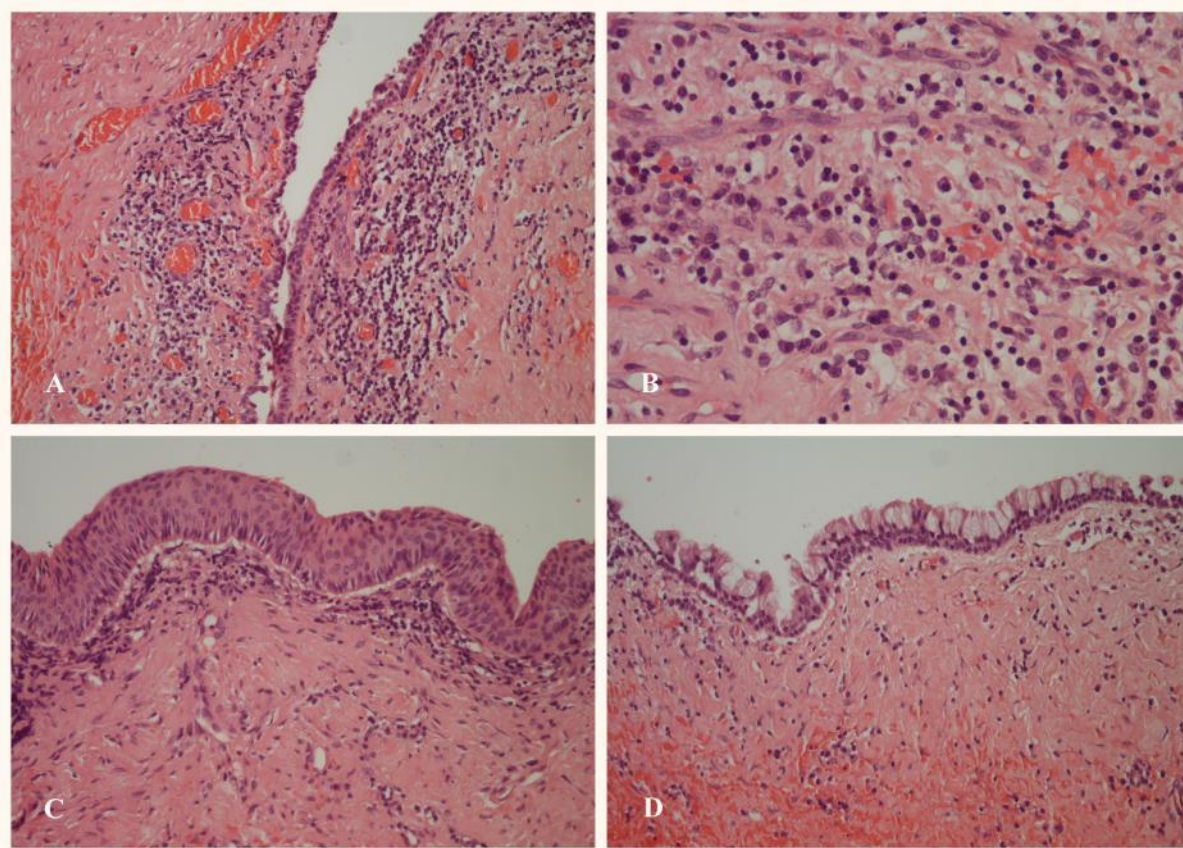


Figure 4. Pathohistological image of chronic dacryocystitis; the epithelium is usually cubical, with two layers (A) (H&E, $\times 10$); the submucosa contains a large number of blood vessels (neovascularization), as well as a thick, chronic inflammation infiltrate (lymphocytes, plasmacytes, histocytes) (B) (H&E, $\times 40$); the epithelium can show squamous metaplasia (C) and goblet cell hyperplasia foci (D) (H&E, $\times 20$)

Table 1. The occurrence of predisposing factors

Predisposing factors	Patients (n, %)
Rhinitis and the inflammation of paranasal sinuses	27 (72%)
Injuries and surgical interventions in the middle third of the face	9 (24%)
Lacrimal sac and nasolacrimal duct tumors	3 (8%)

Paper accepted