



СРПСКИ АРХИВ
ЗА ЦЕЛОКУПНО ЛЕКАРСТВО
SERBIAN ARCHIVES
OF MEDICINE

Address: 1 Kraljice Natalije Street, Belgrade 11000, Serbia

+381 11 4092 776, Fax: +381 11 3348 653

E-mail: office@srpskiarhiv.rs, Web address: www.srpskiarhiv.rs

Paper Accepted*

ISSN Online 2406-0895

Case report / Приказ болесника

Vladimir Milosavljević¹, Boris Tadić², Nikola Grubor^{2,3,†}, Đorđe Knežević^{2,3}, Slavko Matić^{2,3}

**Laparoscopic splenectomy in the treatment
of splenic artery aneurysm - case report and literature review**

Лапароскопска спленектомија у лечењу
анеуризме артерије лијеналис – приказ случаја и преглед литературе

¹Stefan Visoki General Hospital, Smederevska Palanka, Serbia

²Clinical Centre of Serbia, Clinic for Digestive Surgery, Belgrade, Serbia

³University of Belgrade, Faculty of Medicine, Belgrade, Serbia

Received: July 29, 2019

Accepted: September 16, 2019

Online First: September 20, 2019

DOI: <https://doi.org/10.2298/SARH190729101M>

* **Accepted papers** are articles in press that have gone through due peer review process and have been accepted for publication by the Editorial Board of the *Serbian Archives of Medicine*. They have not yet been copy edited and/or formatted in the publication house style, and the text may be changed before the final publication.

Although accepted papers do not yet have all the accompanying bibliographic details available, they can already be cited using the year of online publication and the DOI, as follows: the author's last name and initial of the first name, article title, journal title, online first publication month and year, and the DOI; e.g.: Petrović P, Jovanović J. The title of the article. *Srp Arh Celok Lek*. Online First, February 2017.

When the final article is assigned to volumes/issues of the journal, the Article in Press version will be removed and the final version will appear in the associated published volumes/issues of the journal. The date the article was made available online first will be carried over.

† **Correspondence to:**

Nikola GRUBOR

Klinika za digestivnu hirurgiju, Klinički Centar Srbije

Email: n.grubor@yahoo.com

Laparoscopic splenectomy in the treatment of splenic artery aneurysm - case report and literature review

Лапароскопска спленектомија у лечењу анеуризме артерије лијеналис – приказ случаја и преглед литературе

SUMMARY

Introduction Splenic artery aneurysm is the most common visceral aneurysm with prevalence from 0.2–10%. It is the third most frequent abdominal aneurysm as well. It can be true or false. It occurs more often in women than in men. We will present our experience with a 34-year-old female patient who underwent laparoscopic splenectomy due to the splenic aneurysm located in the splenic hilum.

Case outline We present a case of a 34-year-old female patient diagnosed with an enlarged splenic artery in routine abdominal ultrasound examination. Abdominal scan and CT angiography showed saccular aneurysm of splenic artery located in the hilum of the spleen, 24x17mm in size. Given the good general condition and age of the patient, we decided to perform laparoscopic splenectomy. The operation was performed without complications, as well as postoperative flow. The patient was discharged from the hospital on the third postoperative day.

Conclusion Laparoscopic splenectomy is a safe and effective modality for the treatment of splenic artery aneurysm, localized in the splenic hilum. Considering all the benefits of minimally invasive surgery, laparoscopic splenectomy should be the treatment of choice, over the classical open approach.

Keywords: spleen, aneurysm, splenic artery, laparoscopic splenectomy

САЖЕТАК

Увод Анеуризма лијеналне артерије је најчешћа висцерална анеуризма са преваленцом од 0,02–10%. Такође је на трећем месту по учесталости од свих абдоминалних анеуризми. Може бити права и лажна. Јавља се чешће код жена него код мушкараца. У овом тексту приказаћемо наше искуство са пацијенткињом старом 34 године којој је учињена лапароскопска спленектомија због анеуризме спленичне артерије локализоване у хилусу слезине.

Приказ случаја Код пацијенткиње старе 34 године је на рутинском ултразвучном прегледу абдомена дијагностиковано проширење лијеналне артерије. Компјутеризованом томографијом са ангиографијом потврђено је постојање сакуларне анеуризме лијеналне артерије у хилусу слезине, димензија 24x17 мм. Обзиром на опште стање и узраст пацијенткиње одлучили смо се лапароскопску спленектомију. Операција је протекла без компликација, као и постоперативни ток. Пацијенткиња је отпуштена са клинике трећег постоперативног дана.

Закључак Лапароскопска спленектомија представља сигуран и ефикасан модалитет лечења анеуризме спленичне артерије локализоване у хилусу слезине. Имајући у виду предности минимално инвазивног хируршког приступа, лапароскопска спленектомија се може сматрати процедуром избора односу на класичан, отворени приступ хируршког лечења анеуризме спленичне артерије локализоване у хилусу слезине.

Кључне речи: слезина, анеуризма, лијенална артерија, лапароскопска спленектомија

INTRODUCTION

Splenic artery aneurysm (SAA) is the most common visceral aneurysm with a prevalence of 0.2–10%. It is the third most frequent abdominal aneurysm [1]. According to standard classification criteria SAA can be true (involves all three layers of an artery) or false e.g pseudoaneurysm (collection of blood that forms between the two outer layers of an artery). It occurs more often in women than in men, by a ratio of 4:1. Most aneurysms are

less than 2 cm in diameter, saccular and commonly found in the center or distal part of the splenic artery [1, 2].

The main risk factors for lienal artery aneurysm that have been identified are female sex, fibromuscular dysplasia, vascular diseases, multiple pregnancies, and portal hypertension [2, 3]. Abdominal ultrasound or Doppler ultrasonography, computed tomography (CT), nuclear magnetic resonance (NMR), selective and CT angiography are used to diagnose this disease [4]. Aneurysms with a diameter larger than 2 cm require surgical treatment, as well as symptomatic aneurysms less than 2 cm in diameter. Aneurysms less than 2 cm and without symptomatology can be radiologically monitored [1, 4, 5].

There are several treatment modalities for splenic artery aneurysms: open resection, splenectomy, as well as endovascular treatment (graft, stent or embolization), depending on the patient's suitability for a particular type of treatment [6, 7].

In this paper, we present laparoscopic splenectomy as a safe and effective treatment modality for splenic artery aneurysm located in the splenic hilum.

CASE REPORT

A 34-year-old female patient diagnosed with an enlarged splenic artery in routine abdominal ultrasound was admitted to the Clinic for Digestive Surgery within the Clinical Center of Serbia on March 15, 2019. By examining her medical documentation, we found out that the patient is treated for hypertension with an ACE inhibitor. All laboratory findings on admission were within normal range with a body mass index of 31,67 kg/m². Abdominal CT scan and CT angiography verified enlarged, tortuous splenic artery and saccular aneurysm in the splenic hilum, 24x17 mm in size, with intimal calcification and thrombus (Figure 1).

Considering radiological findings, we decided to perform splenectomy. Because the patient was a young woman in good medical condition, we opted for a laparoscopic approach.

To prevent the formation of thromboembolic complications, the patient was preoperatively treated with low molecular weight heparin. After induction of general endotracheal anesthesia (GETA), the patient is positioned in the right hemilateral position, i.e. the "hanging or leaning spleen" technique [8]. After port placement and insertion of a laparoscope, the examination of the abdomen confirmed the preoperative finding. An aneurysm of the splenic artery in the hilum of the spleen was identified. We first mobilized the spleen by cutting the splenic ligaments and short gastric vessels with laparoscopic harmonic scalpel. After complete mobilization of the spleen, we started the preparation of aneurysm and its separation from the surrounding structures (Figure 2). After preparation of the artery, a few centimeters proximally from the aneurysm, we placed two hem-o-lok clips proximally and one distally, and then cut the artery (Figure 3). The splenic vein was treated the same way. After taking care of the elements of the hilum, the spleen was completely separated from the surrounding structures, placed in the endobag (Figure 4), and thus removed from the abdomen. Hemostasis was checked and the abdominal tube was placed. The splenic specimen was sent to the histopathological examination (Figure 5).

A definitive histopathological finding showed that the tissue of the spleen had preserved histomorphology and that the splenic artery had the aneurysmatic expansion, sclerosis, and focal calcification.

There were no postoperative complications. The nasogastric tube was removed on the first and the abdominal tube on the second postoperative day. The patient was discharged from a hospital on the third postoperative day with prescribed antibiotic prophylaxis and

postoperative immunization, according to the current literature and guidelines for the prevention and treatment of postsplenectomy complications [9, 10].

DISCUSSION

St. Leger Brockman reported the first surgical case of a splenic artery aneurysm in 1930 [1]. Saw et al. performed the first laparoscopic-assisted SAA operation in 1993 [11]. SAA is the third most common type of abdominal aneurysm that accounts for 60% of all visceral aneurysms with a prevalence of 0.8% in the adult population. Splenic artery aneurysm is defined as a segmental enlargement of the artery with a diameter of 10 mm. SAA rupture is a life-threatening condition with a mortality rate of up to 75% [1, 12].

Most SAAs are true aneurysms, with higher representation in women. The main risk factors are female sex, atherosclerosis, arterial hypertension, multiple pregnancies [2]. According to the literature data, 10% of the gigantic SAAs (> 5 cm) are associated with liver cirrhosis. 2.5% of patients has portal hypertension [2, 6, 13]. Pancreatitis is reported as the main risk factor for the emergency laparotomy to treat sudden rupture and bleeding from splenic artery pseudoaneurysms [6]. Pancreatic enzymatic autodigestion can cause weakening of the splenic artery wall architecture leading to pseudoaneurysm formation.

In most cases, SAA is asymptomatic. Most of them are discovered on routine examinations or as an incidental finding during the radiological imaging performed for another medical condition [2]. SAA can be diagnosed by abdominal ultrasonography, CT, NMR and CT angiography [1, 4, 5].

In symptomatic patients, the most common complaints are epigastric or back pain. Some authors consider that all symptomatic patients, as well as patients with no symptoms, whose SAA is > 20 mm in diameter, should be surgically treated because of the possibility of rupture [12]. Particularly risky groups of patients are pregnant women, patients with portal

hypertension, and patients in whom liver transplantation is planned [2, 12]. In patients without symptoms, in whom SAA is < 20 mm in diameter, radiological follow-up by abdominal CT every 6 months would be enough [1, 2, 12]. In our case, the patient was without symptoms. Because of the SAA of 24 mm in size, we opted for surgical treatment.

The modalities of the SAA management are open spleen-preserving aneurysm resection with splenic artery end-to-end anastomosis. Open or laparoscopic splenectomy is treatment choice for aneurysms located in the splenic hilum or immediately next to the hilum. Another option is endovascular management with stent placement or arterial embolization [6, 7, 14, 15]. The aim of surgical treatment should be the treatment of aneurysm with the splenic preservation or the preservation of a sufficient part of the organ (not less than 25% of the volume), enough to perform the immune function. According to the current literature, most authors advocate the performance of splenectomy in patients with aneurysms located in the hilum of the spleen [16].

In our patient, the aneurysm was in the hilum of the spleen, so we performed laparoscopic splenectomy.

Laparoscopic splenectomy in the treatment of a splenic artery aneurysm located in the splenic hilum or right next to the hilum of the spleen is a safe and effective method of treatment of this disease. Considering all the advantages and benefits of minimally invasive surgery, it should be given preference as to a method of choice, compared to open splenectomy.

Conflict of interest: None declared.

REFERENCES

1. Fieldman L, Munshi A, Al-Mahroos M, Fried G. The Spleen. Maingot's abdominal operations. 13th ed. New York: McGraw-Hill; 2019. p. 1239-49.
2. Tcbc-Rj RA, Ferreira MC, Ferreira DA, Ferreira AG, Ramos FO. Splenic artery aneurysm. *Rev Col Bras Cir.* 2016;43(5):398-400 DOI: 10.1590/0100-69912016005005
3. Davidovic L, Markovic M, Bjelovic M, Cvetkovic S. Splanchnic artery aneurysms. *Srpski arhiv za celokupno lekarstvo.* 2006;134(7-8):283-9 DOI: 10.2298/sarh0608283d
4. Adrian PE, Eduardo TM. Spleen. In: Brunicaardi FC, Andersen DK, Billiar TR, Dunn DL, Hunter JG, editors. *Schwartz's principles of surgery.* Tenth edition. ed. New York: McGraw-Hill Education; 2015. p. xviii, 2069 pages.
5. Sun C, Liu C, Wang XM, Wang DP. The value of MDCT in diagnosis of splenic artery aneurysms. *Eur J Radiol.* 2008;65(3):498-502 DOI: 10.1016/j.ejrad.2007.04.006
6. Kauffman P, Macedo ALV, Sacilotto R, Tachibana A, Kuzniec S, Pinheiro LL, et al. The therapeutic challenge of giant splenic artery aneurysm: a case report. *Einstein (Sao Paulo).* 2017;15(3):359-62 DOI: 10.1590/S1679-45082017RC3873
7. Colsa-Gutiérrez P, Kharazmi-Taghavi M, Sosa-Medina RD, Gutiérrez-Cabezas JM, Ingelmo-Setién A. Aneurisma de arteria esplénica. A propósito de un caso. *Cirugía y Cirujanos.* 2015;83(2):161-4 DOI: 10.1016/j.circir.2015.04.014
8. Delaitre B, Bonnichon P, Barthes T, Doussset B. [Laparoscopic splenectomy. The "hanging spleen technique" in a series of nineteen cases]. *Ann Chir.* 1995;49(6):471-6 PMID: 8526436
9. Buzelé R, Barbier L, Sauvanet A, Fantin B. Medical complications following splenectomy. *Journal of Visceral Surgery.* 2016;153(4):277-86 DOI: 10.1016/j.jvisc Surg.2016.04.013
10. Meriglier E, Puyade M, Carretier M, Roblot F, Roblot P. [Long-term infectious risks after splenectomy: A retrospective cohort study with up to 10 years follow-up]. *Rev Med Interne.* 2017;38(7):436-43 DOI: 10.1016/j.revmed.2016.12.023
11. Saw EC, Ku W, Ramachandra S. Laparoscopic resection of a splenic artery aneurysm. *J Laparoendosc Surg.* 1993;3(2):167-71 PMID: 8518472
12. Małczak P, Wysocki M, Major P, Pędziwiatr M, Lasek A, Stefura T, et al. Laparoscopic approach to splenic aneurysms. *Vascular.* 2016;25(4):346-50 DOI: 10.1177/1708538116682164
13. Akbulut S, Otan E. Management of Giant Splenic Artery Aneurysm: Comprehensive Literature Review. *Medicine (Baltimore).* 2015;94(27):e1016 DOI: 10.1097/MD.0000000000001016
14. Guang LJ, Wang JF, Wei BJ, Gao K, Huang Q, Zhai RY. Endovascular Treatment of Splenic Artery Aneurysm With a Stent-Graft: A Case Report. *Medicine (Baltimore).* 2015;94(52):e2073 DOI: 10.1097/MD.0000000000002073
15. Zhu C, Zhao J, Yuan D, Huang B, Yang Y, Ma Y, et al. Endovascular and Surgical Management of Intact Splenic Artery Aneurysm. *Ann Vasc Surg.* 2019;57:75-82 DOI: 10.1016/j.avsg.2018.08.088
16. Nasser HA, Kansoun AH, Sleiman YA, Mendes VM, Van Vyve E, Kachi A, et al. Different laparoscopic treatment modalities for splenic artery aneurysms: about 3 cases with review of the literature. *Acta Chirurgica Belgica.* 2018;118(4):212-8 DOI: 10.1080/00015458.2018.1459363

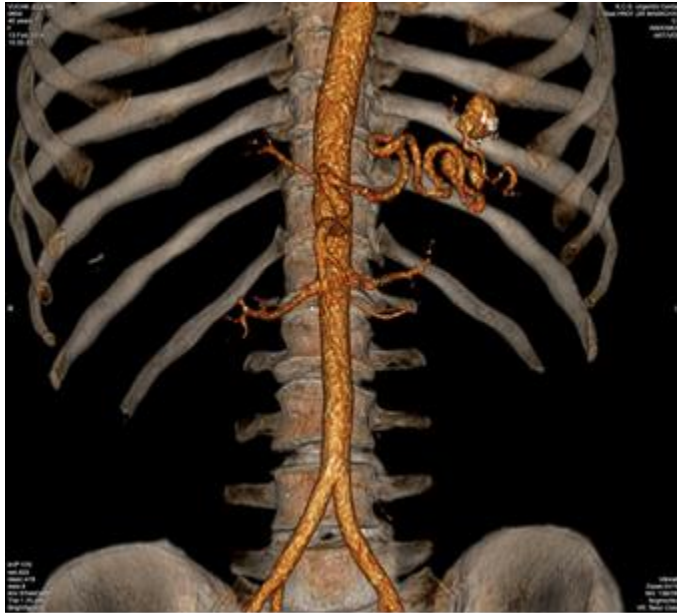

Figure 1 Multidetector computed tomography angiography showed splenic artery aneurysm in the splenic hilum.

Paper accepted

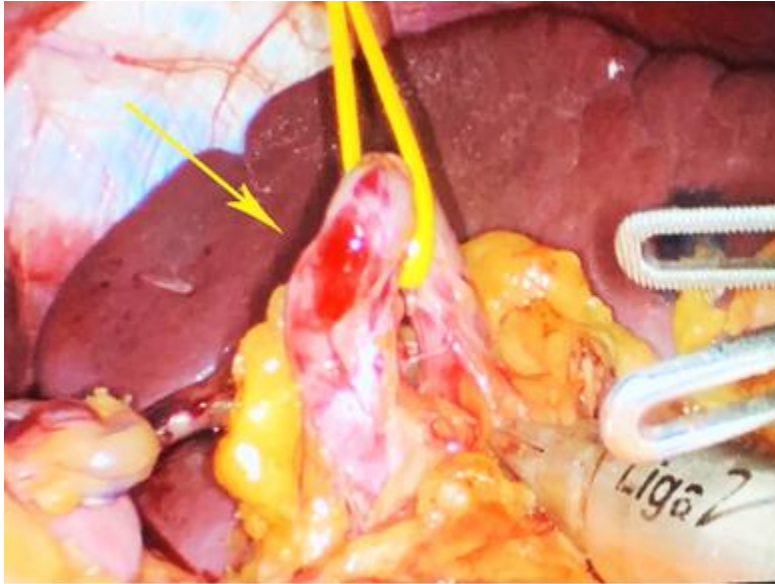


Figure 2. Intraoperative photo: Splenic artery aneurysm pulled with a yellow rubber band

Paper accepted

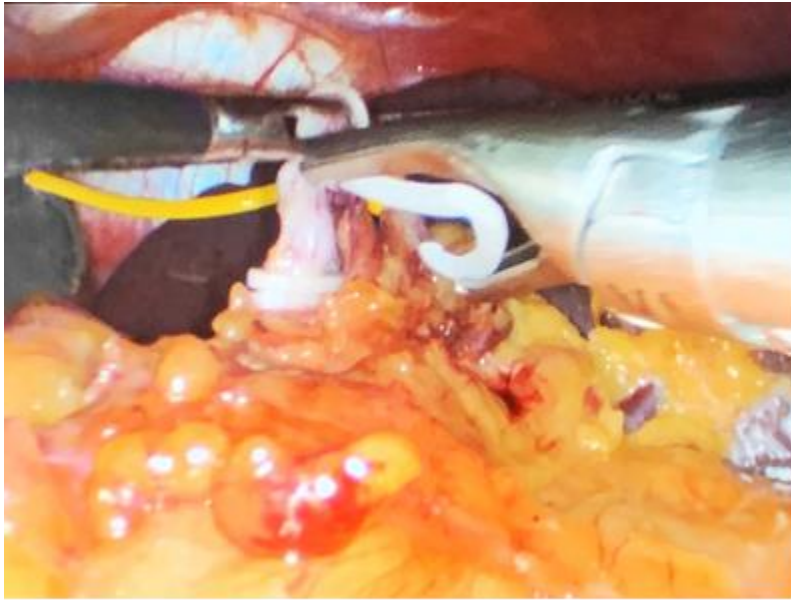


Figure 3. Intraoperative photo: Key step for aneurysm clipping with “Hemolock” clips

Paper accepted

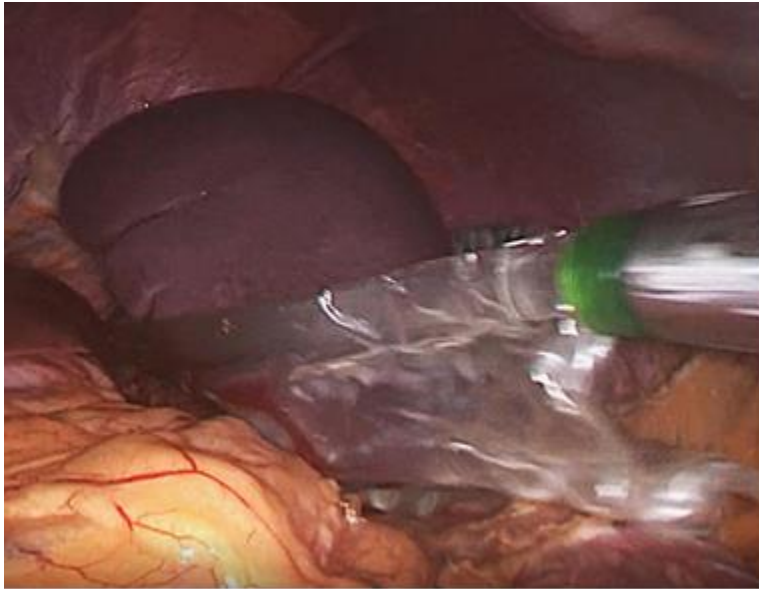


Figure 4. Removal of the spleen with endobag

Paper accepted

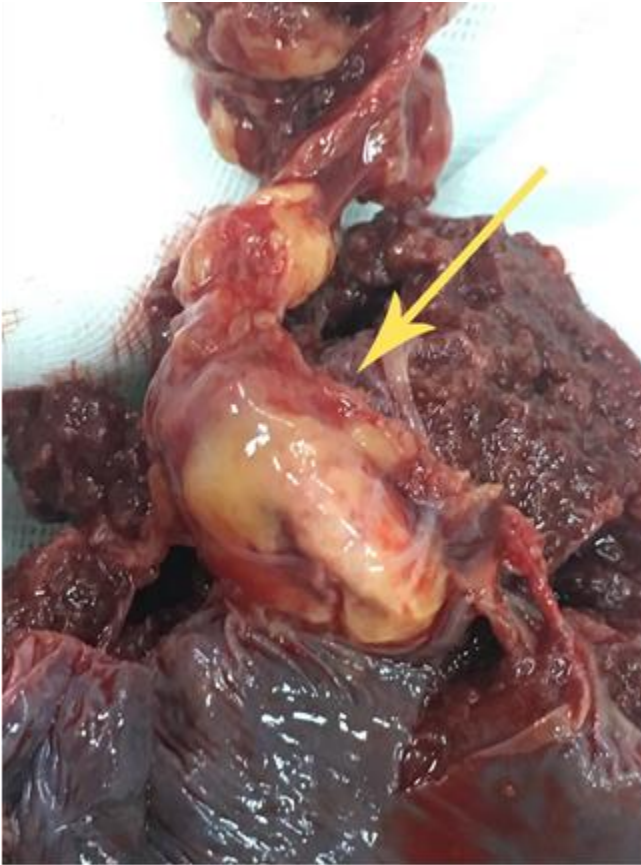

Figure 5. Operative specimen with splenic artery aneurysm