SERBIAN ARCHIVES OF MEDICINE Est.1872

Address: 1 Kraljice Natalije Street, 11000 Belgrade, Serbia
☏ +381 11 4092 776, Fax: +381 11 3348 653
E-mail: srparhiv@bvcom.net, Web address: www.srpskiarhiv.rs

Paper Accepted* **ISSN Online 2406-0895**

Original Article / Оригинални рад

Ljiljana Pejčić[1,†], Radmila Mileusnić-Milenović[2],
Marija Ratković-Janković[1], Ivana Nikolić[1]

Spontaneous closure of muscular ventricular septal defects

Спонтано затварање мускуларних вентрикуларних септалних дефеката

[1] Clinic for Children's Internal Diseases, Clinical Center Niš, Serbia
[2] Institute of neonatology, Belgrade, Serbia

Received: March 1, 2017
Accepted: March 17, 20117
Online First: March 28, 2017
DOI: 10.2298/SARH170301088P

* **Accepted papers** are articles in press that have gone through due peer review process and have been accepted for publication by the Editorial Board of the *Serbian Archives of Medicine*. They have not yet been copy edited and/or formatted in the publication house style, and the text may be changed before the final publication.
Although accepted papers do not yet have all the accompanying bibliographic details available, they can already be cited using the year of online publication and the DOI, as follows: the author's last name and initial of the first name, article title, journal title, online first publication month and year, and the DOI; e.g.: Petrović P, Jovanović J. The title of the article. Srp Arh Celok Lek. Online First, February 2017.
When the final article is assigned to volumes/issues of the journal, the Article in Press version will be removed and the final version will appear in the associated published volumes/issues of the journal. The date the article was made available online first will be carried over.

† **Correspondence to:**
Ljiljana PEJČIĆ
Clinic for Children's Internal Diseases, Clinical Center Niš, 18000 Niš, Serbia
E-mail: **ljiljasonja@yahoo.com**

Spontaneous closure of muscular ventricular septal defects

Спонтано затварање мускуларних вентрикуларних септалних дефеката

SUMMARY

Introduction/Objective Ventricular septal defect (VSD) is the most frequently diagnosed congenital heart anomaly. The prognosis is usually good as it has spontaneous closure evolution, especially small muscular VSDs.

The aim of this study was to determine the natural history of isolated muscular VSDs including frequency of spontaneous closure in relation to location in the muscular septum and age at time of closure.

Methods The study included 96 children (52 girls and 44 boys) with isolated muscular VSD diagnosed during the 1st month of life. We analyzed the tendency of spontaneous closure of these defects during childhood during a follow-up period of 16 years. Two-dimensional color Doppler echocardiography was performed to detect muscular VSD as a primary cardiac lesion. There were significant prevalence of small apical versus trabecular defects and their outcome were evaluated.

Results Our study evaluated 91 children, 49 (53.8%) girls and 42 (46.2%) boys who did not undergo surgery. Apically located VSD was diagnosed in 68 (74.7%), while trabecular defects were found in 23 (25.3%) children. Spontaneous closure occurred in 56 of 91 cases (61.5%). The time of spontaneous closure was most commonly recorded during the first 6 months after birth (46.4%). The overall rate of spontaneous closure was 81.3% by the end of the first year. Apically located ventricular defects underwent spontaneous closure in the majority of patients, in comparison to trabecular ventricular defects (χ^2=12.581; p<0.001). Kaplan-Maier analysis demonstrated significant difference in average time required for spontaneous closure between analyzed patient groups (Log Rank= 9.64, p=0.002).

Conclusion The frequency of spontaneous closure of muscular VSDs especially apically located, is very high in first 6 months, especially within the first year of life. It is advisable to detect them early using color flow imaging and follow up patients up to spontaneous closure.

Keywords: muscular ventricular septal defect; spontaneous closure; color Doppler echocardiography

САЖЕТАК

Увод/Циљ Вентрикуларни септални дефект (ВСД) је најчешћа урођена срчана мана. Прогноза је у највећем броју случајева добра, посебно ако се ради о малим мишићним дефектима, имајући у виду њихову склоност ка спонтаном затварању.

Циљ рада био је да утврди природну еволуцију изолованих мишићних ВСД, односно учесталост спонтаног затварања у зависности од њихове локације у мишићном септуму као и старости болесника у време затварања.

Методе Испитивање је обухватило 96 деце (52 девојчице и 44 дечака) са изолованим мишићним ВСД који је дијагностикован током првог месеца живота. Анализирана је тенденција спонтаног затварања током детињства, а време праћења износило је 16 година. За дијагнозу мишићног ВСД као примарног срчаног дефекта коришћена је дводимензионална колор Допплер ехокардиографија. Регистрована је значајно већа учесталост малих апикалних ВСД у односу на трабекуларне и анализирана је њихова природна еволуција.

Резултати Студијом је обухваћено 91 дете, 49 (53,8%) девојчица и 42 (46,2%) дечака који нису оперисани током праћења. Апикални мишићни ВСД дијагностикован је код 68 (74,7%) деце, а трабекуларни код 23 (25,3%) испитаника. До спонтаног затварања дошло је у 56/91 (61,5%) испитаника. Највећи број дефеката затворио се током првих шест месеци живота (46,4%). Укупна стопа спонтаног затварања до краја прве године била је 81,3%. Затворио се значајно већи број апикалних ВСД-а у поређењу са трабекуларним дефекатима (χ^2=12,581; *p*<0,001). Каплан-Мајерова анализа је показала је и значајну разлику у просечном времену спонтаног затварања ове две испитиване групе (Лог Ранк= 9,64, *p*=0,002).

Закључак Највећи број спонтаних затварања ВСД одвија се у првих шест месеци, односно до краја прве године живота. Чешће се затварају апикални мишићни дефекти и треба их на време откривати и континуирано пратити до њиховог затварања.

Кључне речи: мускуларни вентрикуларни септални дефект; спонтано затварање; колор Доплер ехокардиографија

INTRODUCTION

Ventricular septal defect (VSD) is the most common congenital cardiac anomaly which accounts for up to 42% of cardiac defects [1]. An isolated VSD is defined as a defect in the inter-ventricular septum without other sonographic abnormalities. Isolated VSD occurs in approximately 2-

6 of every 1000 live births, 1.5-3.5 per 1000 term infants and 4.5-7 per 1000 premature infants. VSDs are slightly more common in females; 46% occur in males, and 54% occur in females [2].

Since the eighties of the last century, real-time 2-dimensional echocardiography has dramatically improved the noninvasive anatomical assessment of VSD. Cross sectional echocardiography coupled with Doppler echocardiography and color flow imaging are the gold standard for determining the size and location of virtually all VSDs [3]. In muscular septal defect, all views that image the ventricular septum must be employed to detect the defect. Color Doppler echocardiography is critical to determine small asymptomatic defects [4].

The evolution of the VSD has been the focus of several studies. The natural history has a wide spectrum, ranging from spontaneous closure to congestive cardiac failure and death in early infancy. Spontaneous closure of VSD especially in the first years of life is a well-known phenomenon and it occurs in about one third of all cases [5]. Closure is most frequently observed in muscular defects (80%), particularly apical, followed by perimembranous defects (35–40%) [6].

We followed up all patients with a muscular VSD diagnosed in the first month of life over 16 years, to determine the frequency of spontaneous closure in relation to size, location in the muscular septum and age at time of closure.

METHODS

The study included 96 children (52 girls and 44 boys) with isolated muscular VSD diagnosed during the 1st month of life. We analyzed the tendency of spontaneous closure of these defects during childhood during a follow-up period of 1-16 years (from January 2000. to December 2016.).

All patients had a complete history and physical examination by pediatric cardiologist. Two-dimensional color Doppler echocardiography was performed using available equipment (Hewlett Packard Image Point and Acuson CV70) to detect muscular VSD as a primary cardiac lesion. Two subcostal views, parasternal long and short axis, and apical four chamber views were routinely performed to clearly check the complete ventricular septum (Figure 1). When color imaging showed

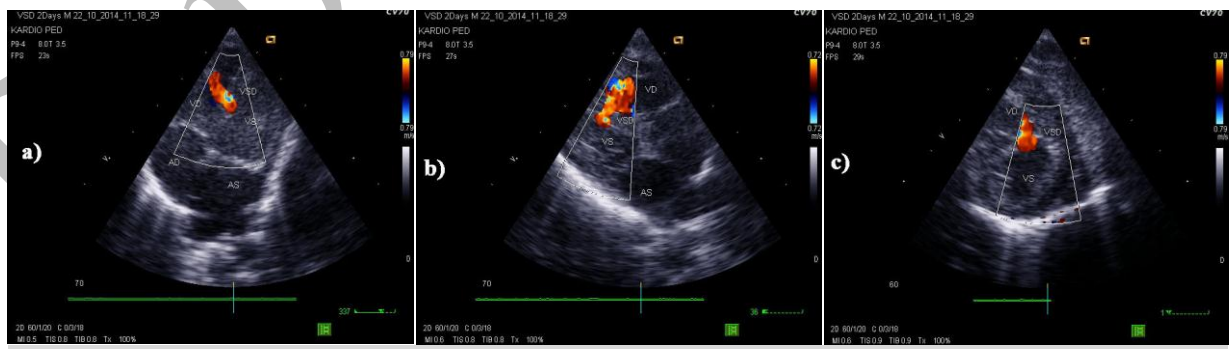

Figure 1. Trabecular muscular ventricular septal defect in a neonate; a) apical four chamber view; b) parasternal long axis view; c) parasternal short axis view.

inter-ventricular shunting, the diagnosis was confirmed by color Doppler flow mapping, which indicated velocity and direction of the flow.

The muscular defects were categorized as apical, trabecular, or outlet, according to the classification of Gatzoulis et al [7]. Defect sizes were measured in two dimensional images or as the maximum thickness of color jet at the level of ventricular septum. VSDs were deemed to be large if the defects were as large as or greater than half of the aortic orifice, and small if only seen in some parts of the cardiac cycle or not seen at all, but identified on color flow mapping (Figure 2). All other defects were classified as moderate.

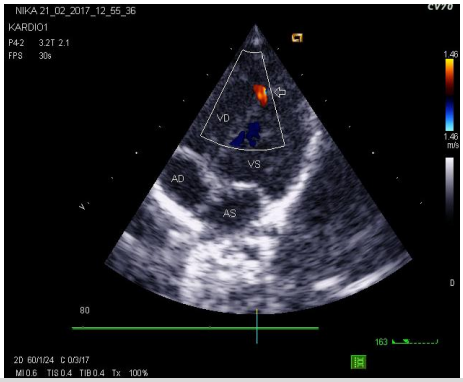

Figure 2. Small apical muscular ventricular septal defect.

The patients were follow-up at approximately 3, 6, 9, 12 months of age. After 1st year, follow-up intervals were 6 months. All patients received prophylaxis for infective endocarditis.

The Chi-square test was used to compare the difference between prevalence of VSDs in males and females. Actuarial event-free curves were obtained using Kaplan-Meier analysis to compare spontaneous closure rates of apical and trabecular VSDs. Log rank analysis was used to examine the significance between the curves for apical and trabecular VSD. A p value of less than 0.05 was regarded as statistically significant.

RESULTS

The study included 96 children (52 girls and 44 boys) with isolated muscular VSD. With regard to size, 88 defects were characterized as small, 6 as moderate and 2 as large defects. According to localization, in the small category there were 68 apical and 20 trabecular; among moderate there were 3 trabecular and 3 outlet, and in category large there were 2 outlet defects. Five outlet defects required surgical closure, 3 moderate and 2 large before the 3rd year of life. Of the 91 patients managed non-surgically, 56 muscular defects had spontaneously closed: 49 were apical and 7 were trabecular. Of 35 muscular VSDs that did not require surgical closure and remain open, 19 were apical and 16 were trabecular. Figure 2 summarizes the natural history of 96 muscular VSDs (Figure 3).

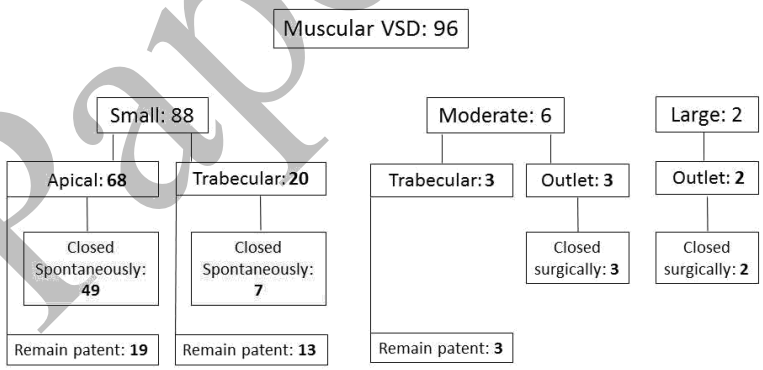

Figure 3. The natural history of the 96 muscular ventricular septal defects (VSDs) studied.

Our study evaluated 91 children, 49 (53.8%) girls and 42 (46.2%) boys who did not undergo surgery.

Apically located VSD was diagnosed in 68 (74.7%) patients, while trabecular defects were found in 23 (25.3%) children (Table 1). With regard to defect type the difference in frequency between girls and boys was not statistically significant ($\chi 2$=0.089; *p*=0.766).

Table 1. Defect type according to sex.

	Apical VSD	Trabecular VSD	χ^2	*p*
Girls	36 (52.9)	13 (56.5)	0.089	0.766
Boys	32 (47.1)	10 (43.5)		

Spontaneous closure occurred in 56 of 91 cases (61.5%). The average time required for spontaneous closure was 10.4±16.1 months, median 7 months (minimum 1 month and maximum time 117 months), where patient follow-up lasted for a total of 192 months (16 years). The time of spontaneous closure was most commonly recorded during the first 6 months after birth. At the 6th month, the 1st year and at the 18th month, spontaneous closure occurred in 43 (46.4%), 50 (89.3%) and 54 (96.4%) cases respectively. It was seen in all cases except 2 within the first 18 months; the other defects closed at the 42nd and 117th month (Table 2).

Table 2. Time of spontaneous closure during follow-up period.

Time of the spontaneous closure (months)	Number of patients	Ratio (%)	Cumulative ratio (%)
≤ 1	4	7.1	7.1
1 – ≤ 3	13	23.3	23.4
3 – ≤ 6	26	46.4	76.8
6 – ≤ 12	7	12.5	89.3
12 – ≤ 18	4	7.1	96.4
18 – ≤ 42	1	1.8	98.2
42 – ≤ 120	1	1.8	100.0
Total	**56**	**100**	–

Apically located ventricular defects underwent spontaneous closure in the majority of patients, in comparison to trabecular ventricular defects (χ^2=12.581; p<0.001) (Table 3).

Table 3. Defect type according to the outcome of the closure.

	Apical VSD	Trabecular VSD	χ^2	*p*
No closure	19 (27.9)	16 (69.6)	12.581	<0.001
Closure	49 (72.1)	7 (30.4)		

Among children in whom spontaneous VSD closure was confirmed, Kaplan-Maier analysis demonstrated that average time for closure of apical defects was 7.6 months (95% CI: 5.71 to 9.39), and 30.1 months in children with trabecular defects (95% CI: 1.44 to 58.84 months). A significant difference was found in average time required for spontaneous closure between analyzed patient groups (Log Rank= 9.64, p=0.002) (Figure 4).

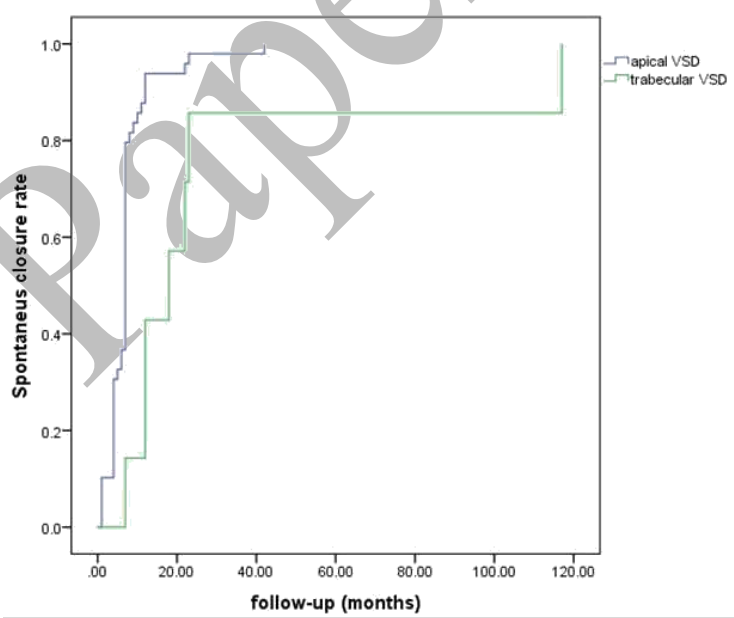

Figure 4. Kaplan-Meier survival curves comparing spontaneous closure rates of apical and trabecular ventricular septal defects.

There was no record of infective endocarditis in any patients.

DISCUSSION

Spontaneous closure is the main characteristic of the natural history of VSD. It is generally accepted that the prognosis of isolated VSD in the postnatal period is good, with a high rate of spontaneous closure during the first years of life. However, frequency of spontaneous closure varies greatly from one study to another, depending on size and location, the population-age studied and follow-up period [8]. In previous clinical studies, the rate of spontaneous closure of muscular VSD has been reported between 24% and 96%. These rates are quite different, but as a common result, most of the small defects close within the few months after birth [6, 9]. Some investigators suggested that small defects are not a malformation and that early spontaneous closure of these defects is a normal developmental process [10]. Our results show high rate of spontaneous closure of muscular defects (61.5%) and a relatively high rate of closure in the first year of life with cumulative ratio 89.3%. Chang published almost an identical frequency (89.2%) of spontaneous closure of muscular defects in the first year [3]. Similar results had Xu et al. who reported that up to 78.5% of the whole spontaneous closure events occurred when the patients were under 3 years old [11].

There are a few clinical reports related to the rate of closure for muscular VSDs, where closure rate is influenced by the location of the defect. The results are very different depending on the study. Turner et al. confirmed that the position of a ventricular septal defect is extremely relevant to its natural history [9]. The spontaneous closure rate for muscular defects was significantly greater than for perimembranous defects. Shirali and colleagues studied 156 cases for a mean of 28 months and also found a significantly higher spontaneous closure rate for muscular defects [6]. Ramaciotti et al. reported that the rate of closure for muscular VSDs and apical muscular VSDs was 24% and 23%, respectively. They emphasized that spontaneous closure of muscular VSDs was most commonly seen in the first 18 months of life. They also observed that the natural history of single muscular VSD is not influenced by location in the muscular septum [12]. Du et al. screened full-term neonates with color flow Doppler imaging for muscular VSDs. The rate of closure at the end of the first year was found as 84.8%, but only one-fourth of defects were located in the apical region. They found that defects localized in the apical region and defects greater than 4mm in size remain patent more than VSDs located elsewhere [10]. Hiraishi et al. found a very high frequency for isolated VSDs when term neonates were routinely investigated using echocardiography. Most of the defects were small muscular and 76% had closed by the 1st birthday, but 45% were apical muscular VSDs [4].

Our findings are very similar to ones reported by Turner et al. and Atalay et al [9, 13]. In Atalay's study a very high frequency of spontaneous closure of apical muscular VSDs was found. Spontaneous closure was seen in 24 of 42 cases (57.1%) between 1 and 36 months of age, and it was most commonly recorded during the first 6 months of life.

Spontaneous closure becomes less likely during adolescence and adult life. In the study by Gabriel et al. spontaneous closure occurred in 6% of patients [14].

In recent years, with the development of echocardiographic techniques, the time of diagnosis and monitoring of the VSD focuses to the prenatal period [15]. Le et al. concluded that birth weight and prenatal echocardiographic measurement of size and location of VSD enables the estimation of spontaneous closure probability in individual patients [16].

CONCLUSION

The high chance of spontaneous closure is one of the major reasons why small VSDs are followed conservatively. However, it is important to detect even a small VSD because of the risk of infective endocarditis. Most muscular defects underwent complete or substantial spontaneous closure during the 12-month follow-up period. Color Doppler echocardiography is a useful technique for establishing the natural course of VSD even from prenatal period. Because of the high closure rate of muscular VSDs, especially apical, and the absence of serious clinical signs, parental anxiety should be minimized.

REFERENCES

1. Samanek M, Voreskova M. Congenital heart disease among 815,569 children born between 1980 and 1990 and their 15-year survival: a prospective bohemia survival study. Pediatr Cardiol. 1999; 20(6): 411–7.
2. Lin MH, Wang NK, Hung KL, Shen CT. Spontaneous closure of ventricular septal defects in the first year of life. J Formos Med Assoc. 2001; 100(8): 539–42.
3. Chang JK, Jien WY, Chen HL, Hsieh KS. Color Doppler echocardiographic study on the incidence and natural history of early-infancy muscular ventricular septal defect. Pediatr Neonatol. 2011; 52(5): 256–60.
4. Hiraishi S, Agata Y, Nowatari M, Oguchi K, Misawa H, Hirota H, et al. Incidence and natural course of trabecular ventricular septal defect: two-dimensional echocardiography and color Doppler flow imaging study. J Pediatr. 1992; 120(3): 409–15.
5. Miyake T, Shinohara T, Inoue T, Marutani S, Takemura T. Spontaneous closure of muscular trabecular ventricular septal defect: comparison of defect positions. Acta Paediatr 2011; 100(10): e158–e162.
6. Shirali GS, Smith EO, Geva T. Quantitation of echocardiographic predictors of outcome in infants with isolated ventricular septal defect. Am Heart J. 1995; 130(6): 1228–35.
7. Gatzoulis MA, Li J, Ho SY. The echocardiographic anatomy of ventricular septal defects. Cardiol Young. 1997; 7(4): 471–84.
8. Zhang J, Ko JM, Guileyardo JM, Roberts WC. A review of spontaneous closure of ventricular septal defect. Proc (Bayl Univ Med Cent). 2015; 28(4): 516-20.
9. Turner SW, Hunter S, Wyllie JP. The natural history of ventricular septal defects. Arch Dis Child. 1999; 81(5): 413-6.
10. Du ZD, Roguin N, Wu XJ. Spontaneous closure of muscular ventricular septal defect identified by echocardiography in neonates. Cardiol Young. 1998; 8(4): 500–5.
11. Xu Y, Liu J, Wang J, Liu M, Xu H, Yang S. Factors influencing the spontaneous closure of ventricular septal defect in infants. Int J Clin Exp Pathol. 2015; 8(5): 5614–23.
12. Ramaciotti C, Vetter JM, Bornemeier RA, Chin AJ. Prevalence, relation to spontaneous closure, and association of muscular ventricular septal defects with other cardiac defects. Am J Cardiol. 1995; 75(1): 61–5.
13. Atalay S, Tutar E, Ekici F, Nacar N. Spontaneous closure of small apical muscular ventricular septal defects. Turk J Pediatr. 2005; 47(3): 247–50.
14. Gabriel HM, Heger M, Innerhofer P, Zehetgruber M, Mundigler G, Wimmer M, et al. Long-term outcome of patients with ventricular septal defect considered not to require surgical closure during childhood. J Am Coll Cardiol. 2002; 39(6): 1066–71.
15. Gomez O, Martínez JM, Olivella A, Bennasar M, Crispi F, Masoller N, et al. Isolated ventricular septal defects in the era of advanced fetal echocardiography: risk of chromosomal anomalies and spontaneous closure rate from diagnosis to age of 1 year. Ultrasound Obstet Gynecol. 2014; 43(1): 65–71.
16. Li X, Song GX, Wu LJ, Chen YM, Fan Y, Wu Y, et al. Prediction of spontaneous closure of isolated ventricular septal defects in utero and postnatal life. BMC Pediatr. 2016; 16: 207–17.

