



СРПСКИ АРХИВ
ЗА ЦЕЛОКУПНО ЛЕКАРСТВО
SERBIAN ARCHIVES
OF MEDICINE

Address: 1 Kraljice Natalije Street, Belgrade 11000, Serbia

+381 11 4092 776, Fax: +381 11 3348 653

E-mail: office@srpskiarhiv.rs, Web address: www.srpskiarhiv.rs

Paper Accepted*

ISSN Online 2406-0895

Case report / Приказ болесника

Marko Jović, Ivan Radosavljević, Jovan Mihaljević*, Jelena Jeremić,
Milan Jovanović

Breast implant rupture 37 years after breast augmentation

Руптура импланта 37 година након аугментације

University of Belgrade, Faculty of Medicine, University Clinical Center of Serbia, Clinic for Burns,
Plastic and Reconstructive Surgery, Belgrade, Serbia

Received: April 1, 2021

Revised: July 14, 2021

Accepted: August 1, 2021

Online First: August 4, 2021

DOI: <https://doi.org/10.2298/SARH210401069J>

***Accepted papers** are articles in press that have gone through due peer review process and have been accepted for publication by the Editorial Board of the *Serbian Archives of Medicine*. They have not yet been copy-edited and/or formatted in the publication house style, and the text may be changed before the final publication.

Although accepted papers do not yet have all the accompanying bibliographic details available, they can already be cited using the year of online publication and the DOI, as follows: the author's last name and initial of the first name, article title, journal title, online first publication month and year, and the DOI; e.g.: Petrović P, Jovanović J. The title of the article. *Srp Arh Celok Lek*. Online First, February 2017.

When the final article is assigned to volumes/issues of the journal, the Article in Press version will be removed and the final version will appear in the associated published volumes/issues of the journal. The date the article was made available online first will be carried over.

***Correspondence to:**

Jovan MIHALJEVIĆ

University Clinical Center of Serbia, Clinic for Burns, Plastic and Reconstructive Surgery,

Zvečanska 9, 11000 Belgrade, Serbia

Email: jovanmihaljevic17@gmail.com

Breast implant rupture 37 years after breast augmentation

Руптура импланта 37 година након аугментације

SUMMARY

Introduction Silicone implants have been used ever since the second half of the 20th century. Over that period several generations of implants have been developed that differed in thickness of the shell and viscosity of the silicone gel. Development of these generations of implants was accompanied with different complication rates. The first-generation implants had the lowest tendency to rupture, but were more prone to capsular contracture and calcification formation.

Case outline An 81-year-old female patient had her silicone implants placed in 1983. After a chest injury in 2015, on the lateral aspect of the left breast a tumefaction becomes palpable and she complains of pain. She denies any subjective problems before the injury. After pertinent diagnostic procedures and clinical examination, silicone implant rupture was suspected. Surgical findings confirmed ruptures of both implants so that they were extracted, capsulectomy was performed and the surrounding tissue imbued with silicone removed. Samples were sent for histopathological examination.

Conclusion Implant rupture is one of late complications of breast augmentation. The incidence of ruptures has changed with development of newer generations of silicone implants. We believe that our patient had the first-generation silicone implants, knowing the time from their placement to the occurrence of symptoms and macroscopic appearance of the shell after extraction. The fact is that these implants have proved to be very durable, but regardless of the lack of symptoms, current guidelines recommend regular screening for rupture, while possible preventive extraction, particularly in case of so old implants should be considered.

Keywords: implant rupture; silicone implants; breast augmentation

САЖЕТАК

Увод Силиконски импланти у употреби су од друге половине 20. века. Током тог периода развијено је више генерација импланата који су се разликовали на основу дебљине капсуле и вискозности силиконског гела. Кроз развој генерација импланата, мењала се и учесталост компликација. Импланти прве генерације показали су најмању тенденцију ка руптури, али су били склонији капсуларној контрактури и формирању калцификата.

Приказ болесника Пацијенткиња стара 83 године уградила је силиконске импланте 1983. године. Пацијенткиња је 2015. године пала и повредила леву страну грудног коша. Након повреде, долази до појаве палпабилног тумефакта у пределу леве дојке праћеног боловима. Пре повређивања негира постојање било каквих субјективних тегоба. Дијагностичким процедурама и клиничким прегледом постављења је сумња на руптуру силиконског импланта. Оперативним налазом потврђена је руптура оба импланта, те је учињена екстракција силиконских импланта, капсулектомија и уклањање околног силиконом имбибираног ткива, а препарати су послати на *PH* анализу.

Закључак Руптура импланта представља једну од касних компликације аугментације груди. Учесталост руптуре мењала са развојем генерација силиконских импланата. Мишљења смо да су код наше пацијенткиње уграђени силиконских импланти прве генерације, узимајући у обзир време протекло од њихове уградње до појаве симптома и макроскопски изглед опне након екстракције. Чињеница је да су се ови импланти показали као веома издржљиви, али без обзира на изостанак симптома, према савременим препорукама саветује се редован скрининг и евентуална превентивна екстракција, поготову овако старих импланата.

Кључне речи: руптура импланта; силиконски импланти; аугментација груди

INTRODUCTION

Augmentation mammoplasty is a surgical procedure where the use of silicone implants or transfer of fatty tissue result in breast enlargement, regaining of the volume or achieving the desired shape [1]. Augmentation mammoplasty is one of the most commonly performed procedures in esthetic surgery worldwide. Since 2006 it has been the most commonly

performed esthetic operation in the US. In 2019 only in the US 2.3 million esthetic operations were performed, excluding minimally invasive procedures. Out of these, 193 073 were augmentation mammoplasties, accounting for 8% of the total number [2].

Silicone implants have been used for over half a century. Generations of implants have been developed that differed in thickness of the shell and composition of the filling [3]. Complications after breast enlargement can be classified into early and late. Early complications include infection, asymmetry, hematoma, seroma, pain, altered sensations. Late complications include change of implant position, implant rupture, contracture and other [4, 5]. Implant rupture most commonly results from the implant age, trauma or can occur due to iatrogenic damage [6]. Silicone implant rupture could potentially require surgical treatment with extraction of the ruptured implant. Depending on whether it is an asymptomatic or symptomatic rupture, treatment options should be discussed with the patient while presenting the potential benefits, risks, and costs of implant removal. Patients with asymptomatic rupture should be presented with a choice between continued periodic imaging or surgical treatment [3], while those with symptomatic rupture should be advised to undergo surgical treatment in order to eliminate subjective symptoms or additional clinical problems [3]. Treatment of other complications that can potentially develop as a result of rupture and imbition of the surrounding tissue with silicone gel could also be required. The purpose of this report is to describe a potential longevity of older breast implant generations and absence of symptomatic rupture in the presented case for more than 37 years, with highlighting screening, diagnostic and treatment options.

CASE REPORT

An 81 years old female patient was admitted to the Hospital for Burns, Plastic and Reconstructive Surgery of the Serbian Medical Center in August 2020 complaining of pain

and presence of tumefaction in the area of her left breast. Her medical history revealed that she had breast implants placed in 1983 for augmentation purposes. She said that she had fell 5 years previously and injured her chest on the left. Ever since, she could feel a tumefaction of about 1 x 1 cm that had gradually grew. Clinical examination revealed breast asymmetry (Figure 1.). In the upper left quadrant, there was a tumefaction of about 5 x 5 cm, insensitive to palpation, partially fixated, of hard consistency, without signs of inflammation present (Figure 2.). Mammography suggested signs of herniation of the implant towards the axillary extension, i.e. differential diagnosis suggested a rupture. The right implant also had uneven edges. Ultrasound scan revealed blurred lines of the capsule in the external quadrant of the left breast above which there was a hyperechogenic area that was suggestive of imbibition of the surrounding tissue due to extravasation of the implant filling. In the upper external quadrant of the left breast, there was a non-homogenous area with mildly affected tissue architecture, 26 x 14 mm, along the implant itself. Towards the axillary extension of the left breast an oval discrete structure, about 68x46mm, suggestive of herniated part of the implant is seen. On the basis of mammography, echotomography and clinical examination surgical treatment was indicated. Both implants, both connective tissue capsules and silicone imbibed surrounding tissue were removed (Figure 3.). The tissue was sent for histopathological examination. The results verified the presence of hyalinized capsule with calcifications and multinuclear giant cells filled with polarized foreign matter (silicone). On follow-up patient was overall satisfied with the outcome (Figure 4.).

DISCUSSION

A rupture can be intracapsular or extracapsular. Normal body reaction to the presence of an implant as a foreign body is to produce a fibrous tissue capsule in order to limit it. Intracapsular rupture refers to spilling of the content within the fibrous capsule. With leaking of the content

beyond the fibrous capsule limits, it becomes an extracapsular rupture. An extracapsular rupture enables further spreading of the content and imbibing of the surrounding tissues. Possible symptoms of a rupture include breast asymmetry, change in the size, shape and firmness of breast, pain, palpable changes, when a rupture is symptomatic. Signs and symptoms of a silicone implant rupture usually develop later, due to slow leaking of silicone due to its higher density and lack of absorption. In most patients a rupture is not accompanied with any major signs and symptoms and is accordingly called a “silent” i.e. asymptomatic rupture [2]. Silicone implants are classified into generations on the basis of development of the external shell and gel material they are filled with. The first generation was used in the sixties and seventies. These implants had a thick shell and highly viscous gel, resulting in very firm and long-lasting implants. The incidence of ruptures was low, but the incidence of capsular contracture and calcification was high [7]. The second generation was designed with much thinner external shell and less viscous silicone gel. As a result of these design changes the incidence of rupture was much higher and was combined with the “silicone bleeding” phenomenon, i.e. leaking of silicone into the surrounding tissue through the shell itself due to increased fluidity of the implant filling [8, 9]. High incidence of ruptures resulted in discontinuation of use of this generation of implants. The third generation of implants was used from late eighties to 1992 when the FDA moratorium on the use of silicone implants came into force [10]. After pertinent trials the moratorium was lifted in 2006 and in the meantime two more generations of breast were developed, which are currently used [7].

In the management of symptomatic and asymptomatic patients several diagnostic modalities can be used in evaluation of a potential implant rupture. These are: MRI, ultrasound, CT, mammography with initial clinical examination. Clinical examination on its own is not an adequate method in assessment of a suspected rupture. MRI is broadly recommended and accepted diagnostic method worldwide. Numerous studies have established its sensitivity and

specificity in detection of implant ruptures at 72–94% and 85–100%, respectively [11, 12, 13]. The latest FDA recommendations relating to screening of implant patients specify the following: for asymptomatic patients, the first ultrasound or MRI should be performed at 5–6 years postoperatively, then every 2–3 years thereafter; for symptomatic patients or patients with equivocal ultrasound results for rupture at any time postoperatively, an MRI is recommended [14]. Patients with asymptomatic rupture are presented with a choice between continued periodic imaging or surgical treatment [3]. Due to the absence of scientific evidence to clearly support the benefit of removing an asymptomatic ruptured implant, the decision about whether or not to do so should be left to the patient [3]. In case of symptomatic ruptured implant patients should be motivated to undergo surgical treatment in order to eliminate subjective symptoms or additional clinical problems [3]. Surgical treatment implies implant extraction with complete capsulectomy. In the reported case, convincing clinical findings accompanied with ultrasound and mammography were sufficient to suspect ruptures and indicate surgical treatment. The implants were removed on both sides also complete capsulectomy was performed with removal of the surrounding tissue imbued with silicone. It was also noted that the right breast, preoperatively without signs or symptoms, also had some silicone gel in the capsule, together with connective tissue and macroscopically visible calcification. The patient in this particular case had an almost 40 years old implant. We believe that these were first generation implants, having the patient's history, age, late occurrence of symptoms of rupture and macroscopic appearance of implants after extraction [7]. We report this case to show that even in almost 40 years old implants the symptoms of rupture need not necessarily develop, having the macroscopic appearance of her right breast and absence of subjective symptoms relating to the right breast. Also, absence of symptoms did not correlate with the local and microscopic finding inside the right breast capsule. It remains to be answered how long the patient would remain symptom-free and without any further potential

complications if she had not suffered the left breast injury, as described above. The case report supports a possible need for a higher compliance with US FDA recommendations relating to periodic screening in order to identify asymptomatic ruptures and other implant-related complications, especially in older generation silicone implants. It is undeniable that throughout the years, breast implant technology has evolved, nevertheless implant rupture with intracapsular and extracapsular silicone leakage continues to be a problem plastic surgeons face in everyday practice. The impact of symptomatic and asymptomatic, particularly extracapsular implant rupture should be investigated further to learn more about development of further complications, overall health of patients alongside with further investigation of diagnostics, screening and management options for such complications.

Ethical compliance statement: We confirm that we have read the journal's position on issues involving ethical publication and affirm that this work is consistent with those guidelines.

Ethical standards: All procedures performed in studies involving human participants were in accordance with the ethical standards of the institutional and/or national research committee and with the 1964 Helsinki declaration and its later amendments or comparable ethical standards. Written consent to publish all shown material was obtained from the patient.

Conflict of interest: None declared.

REFERENCES

1. Fardo D, Sequeira Campos M, Pensler JM. Breast Augmentation. 2020 Oct 3. In: StatPearls [Internet]. Treasure Island (FL): StatPearls Publishing; 2021 Jan-. PMID: 29489168.
2. Plastic Surgery Statistics [Internet]. American Society of Plastic Surgeons. 2021 [cited 16 May 2021]. Available from: <https://www.plasticsurgery.org/news/plastic-surgery-statistics>
3. Hillard C, Fowler JD, Barta R, Cunningham B. Silicone breast implant rupture: a review. *Gland Surg*. 2017 Apr;6(2):163-168. doi: 10.21037/g.s.2016.09.12. PMID: 28497020; PMCID: PMC5409893.
4. Nahabedian MY. Round Form-Stable Breast Implants: Diagnosis and Management of Complications. *Plast Reconstr Surg*. 2019 Jul;144(1S Utilizing a Spectrum of Cohesive Implants in Aesthetic and Reconstructive Breast Surgery):73S-81S. doi: 10.1097/PRS.0000000000005953. PMID: 31246764.
5. Bachour Y, Bargon CA, de Blok CJM, Ket JCF, Ritt MJPF, Niessen FB. Risk factors for developing capsular contracture in women after breast implant surgery: A systematic review of the literature. *J Plast Reconstr Aesthet Surg*. 2018 Sep;71(9):e29-e48. doi: 10.1016/j.bjps.2018.05.022. Epub 2018 Jun 9. PMID: 29980456.
6. Hadad E, Klein D, Seligman Y, Wisner I, Heller L. Sub-muscular plane for augmentation mammoplasty patients increases silicone gel implant rupture rate. *J Plast Reconstr Aesthet Surg*. 2019 Mar;72(3):419-423. doi: 10.1016/j.bjps.2018.11.009. Epub 2018 Nov 22. PMID: 30616906.
7. Maxwell GP, Gabriel A. The evolution of breast implants. *Plast Reconstr Surg*. 2014 Jul;134(1 Suppl):12S-17S. doi: 10.1097/PRS.0000000000000348. PMID: 25057743.
8. Brown SL, Middleton MS, Berg WA, Soo MS, Pennello G. Prevalence of rupture of silicone gel breast implants revealed on MR imaging in a population of women in Birmingham, Alabama. *AJR Am J Roentgenol*. 2000 Oct;175(4):1057-64. doi: 10.2214/ajr.175.4.1751057. PMID: 11000165.
9. Collis N, Sharpe DT. Silicone gel-filled breast implant integrity: a retrospective review of 478 consecutively explanted implants. *Plast Reconstr Surg*. 2000 May;105(6):1979-85; discussion 1986-9. doi: 10.1097/00006534-200005000-00010. PMID: 10839395.
10. Patel BC, Wong CS, Wright T, Schaffner AD. Breast Implants. 2021 Feb 25. In: StatPearls [Internet]. Treasure Island (FL): StatPearls Publishing; 2021 Jan-. PMID: 28723027.
11. Hölmich LR, Vejborg I, Conrad C, Sletting S, McLaughlin JK. The diagnosis of breast implant rupture: MRI findings compared with findings at explantation. *Eur J Radiol*. 2005 Feb;53(2):213-25. doi: 10.1016/j.ejrad.2004.03.012. PMID: 15664285.
12. Di Benedetto G, Cecchini S, Grassetti L, Baldassarre S, Valeri G, Leva L, Giuseppetti GM, Bertani A. Comparative study of breast implant rupture using mammography, sonography, and magnetic resonance imaging: correlation with surgical findings. *Breast J*. 2008 Nov-Dec;14(6):532-7. doi: 10.1111/j.1524-4741.2008.00643.x. PMID: 19054000.
13. Everson LI, Parantainen H, Detlie T, Stillman AE, Olson PN, Landis G, Foshager MC, Cunningham B, Griffiths HJ. Diagnosis of breast implant rupture: imaging findings and relative efficacies of imaging techniques. *AJR Am J Roentgenol*. 1994 Jul;163(1):57-60. doi: 10.2214/ajr.163.1.8010248. PMID: 8010248.
14. Breast Implant Labeling Guidance [Internet]. U.S. Food and Drug Administration. 2021 [cited 16 May 2021]. Available from: <https://www.fda.gov/regulatory-information/search-fda-guidance-documents/breast-implants-certain-labeling-recommendations-improve-patient-communication>

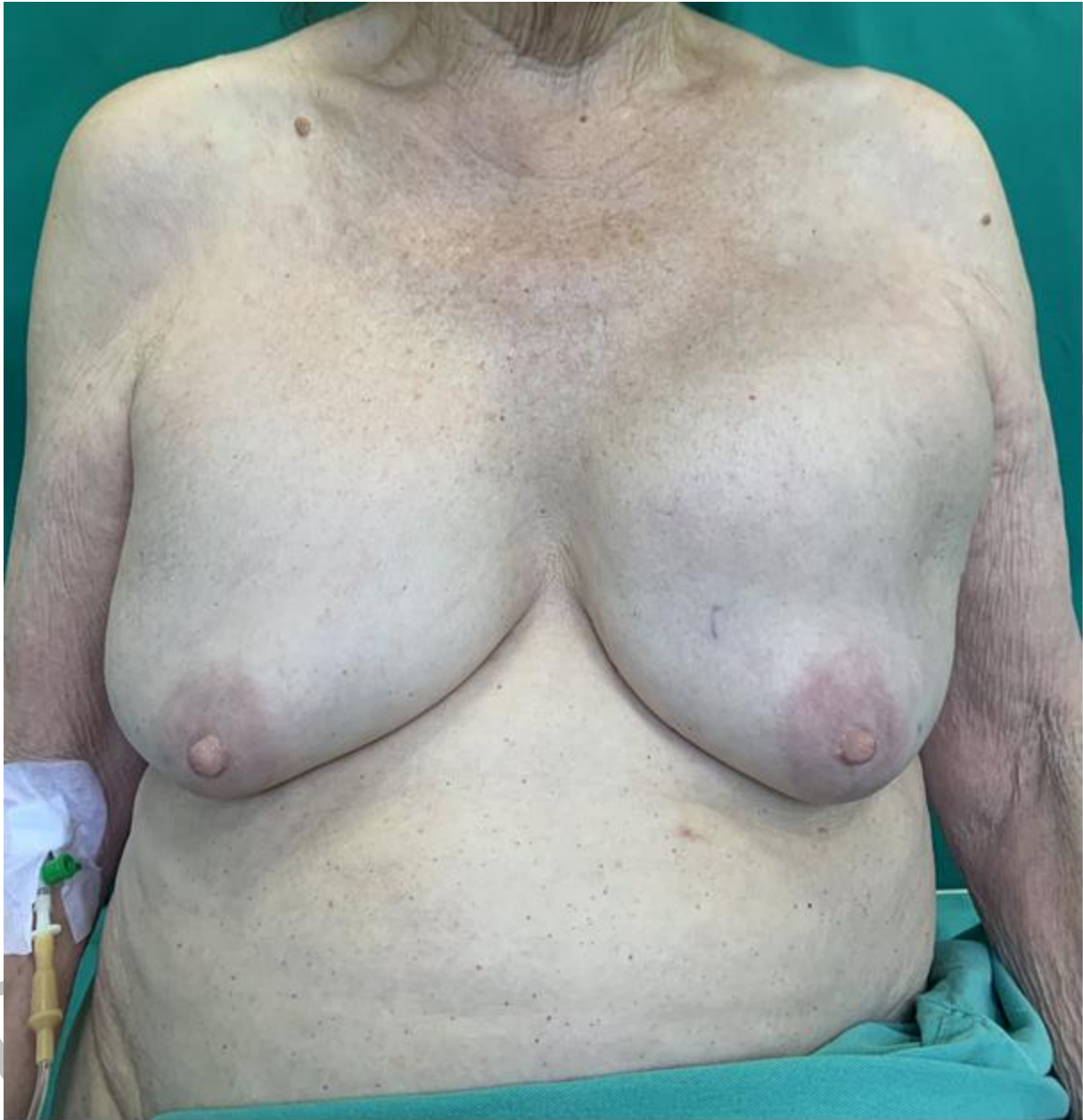


Figure 1. Clinical examination revealed breast asymmetry

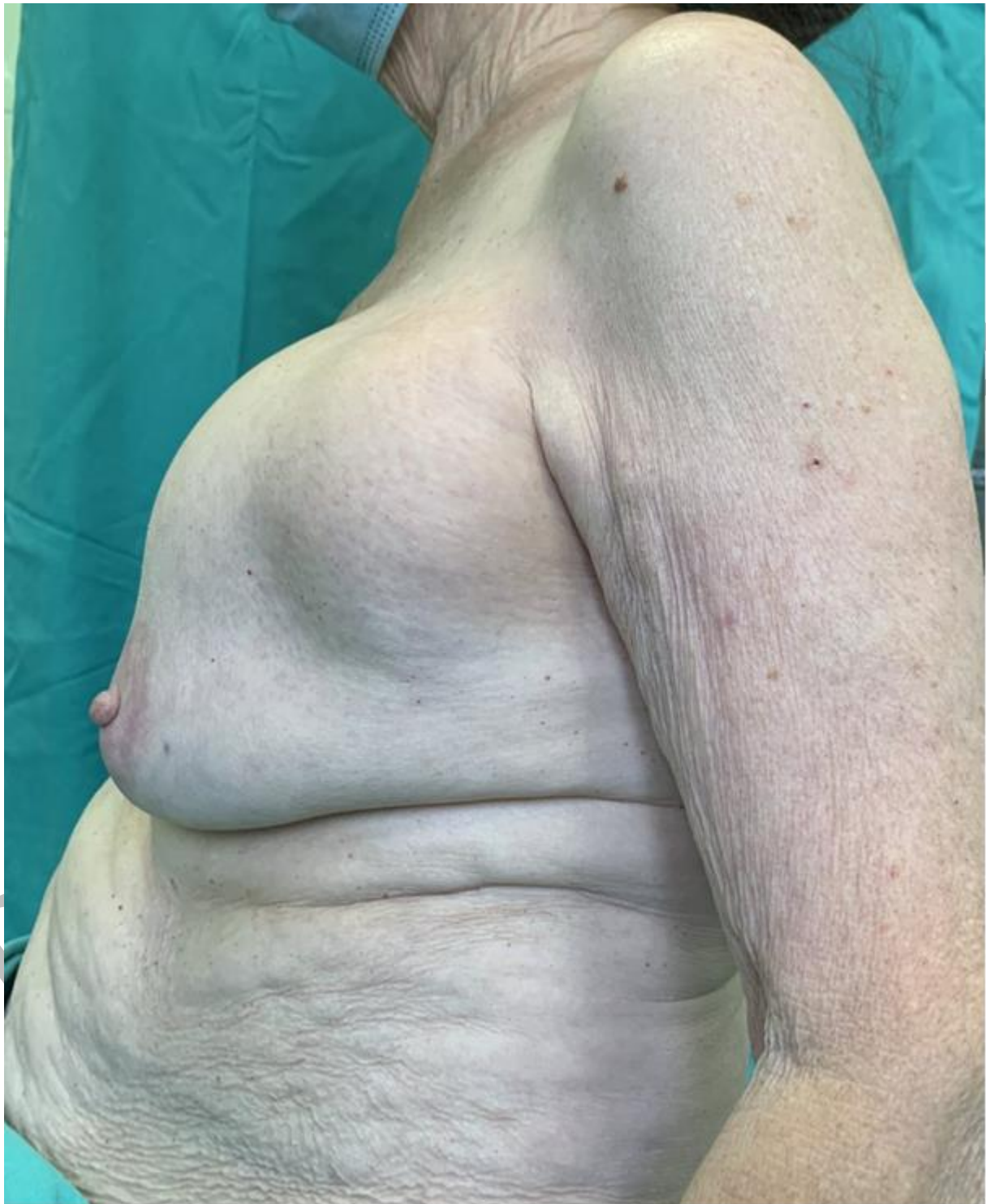

Figure 2. In the upper left quadrant, there was a tumefaction of about 5×5 cm, insensitive to palpation, partially fixated, of hard consistency, without signs of inflammation present

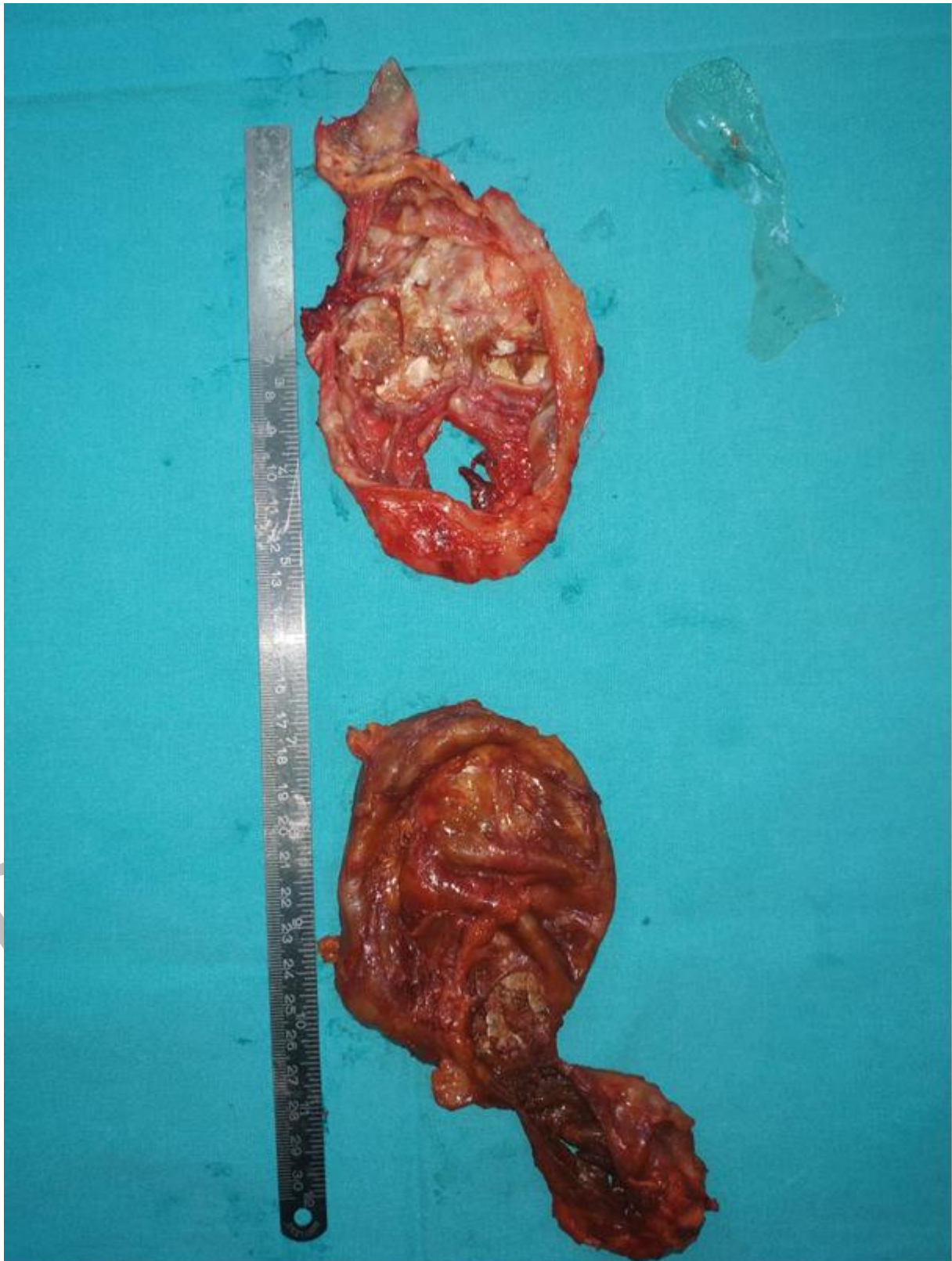


Figure 3. Both implants, both connective tissue capsules and silicone imbibed surrounding tissue were removed

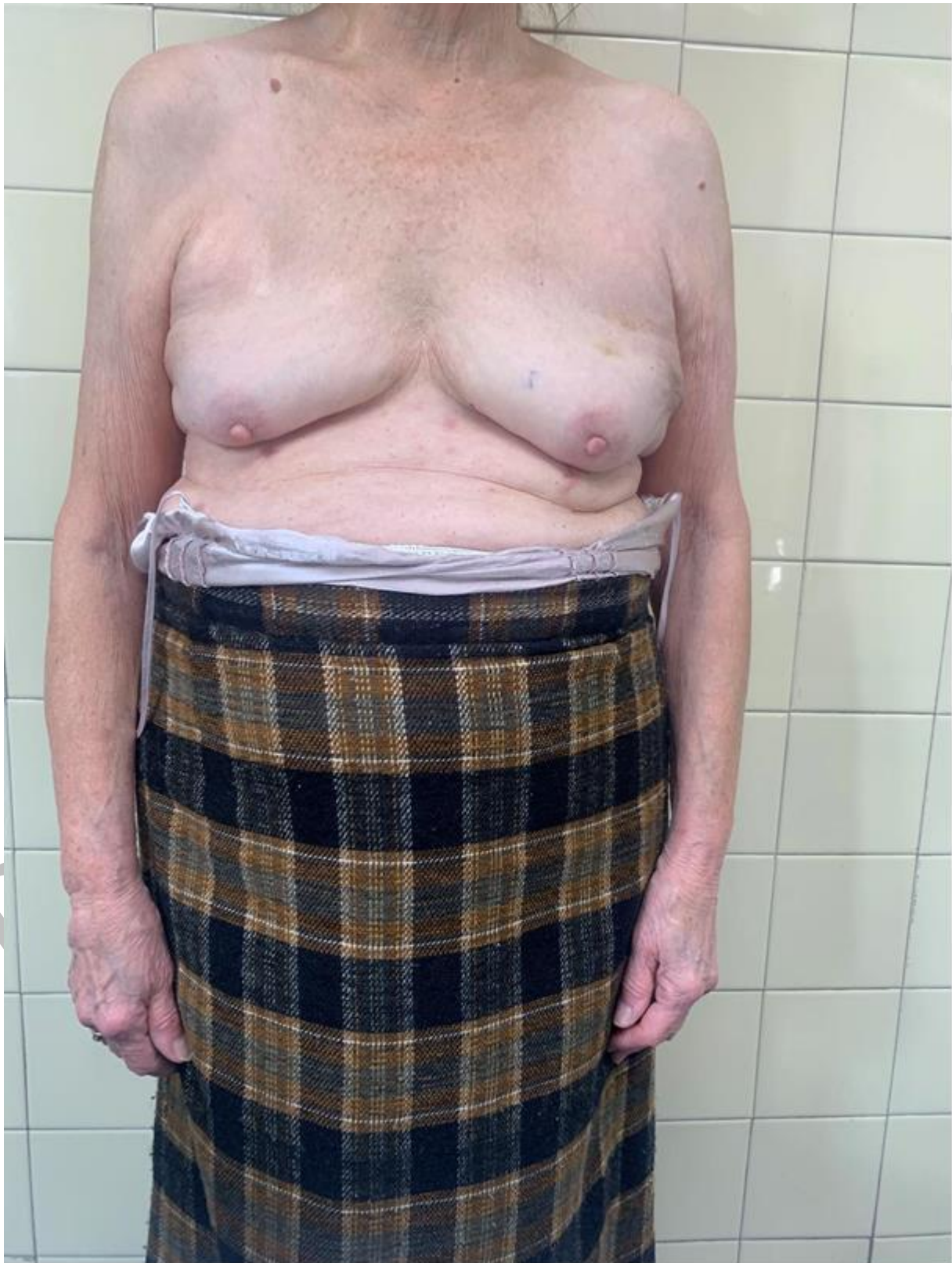

Figure 4. Postoperative follow-up