



СРПСКИ АРХИВ
ЗА ЦЕЛОКУПНО ЛЕКАРСТВО
SERBIAN ARCHIVES
OF MEDICINE

Address: 1 Kraljice Natalije Street, Belgrade 11000, Serbia

+381 11 4092 776, Fax: +381 11 3348 653

E-mail: office@srpskiarhiv.rs, Web address: www.srpskiarhiv.rs

Paper Accepted*

ISSN Online 2406-0895

Case report / Приказ болесника

Slobodan Tanasković^{1,2,*}, Predrag Gajin^{1,2}, Miodrag Ilic¹, Predrag Matić^{1,2},
Vladimir Kovačević^{1,3}, Igor Atanasijević¹, Nenad Ilijevski^{1,2}

**Spleen-preserving surgical treatment of splenic artery aneurysm secondary
to chronic pancreatitis and primary biliary cholangitis**

Хируршки третман анеуризме лијеналне артерије као последица
хроничног панкреатитиса и примарног билијарног холангитиса уз очување
слезине

¹Dedinje Vascular Surgery Clinic, Cardiovascular Institute, Belgrade, Serbia;

²University of Belgrade, Faculty of Medicine, Belgrade, Serbia;

³Dedinje Clinic for Radiology, Cardiovascular Institute, Belgrade, Serbia

Received: January 21, 2021

Accepted: July 1, 2021

Online First: July 5, 2021

DOI: <https://doi.org/10.2298/SARH210121060T>

* **Accepted papers** are articles in press that have gone through due peer review process and have been accepted for publication by the Editorial Board of the *Serbian Archives of Medicine*. They have not yet been copy-edited and/or formatted in the publication house style, and the text may be changed before the final publication.

Although accepted papers do not yet have all the accompanying bibliographic details available, they can already be cited using the year of online publication and the DOI, as follows: the author's last name and initial of the first name, article title, journal title, online first publication month and year, and the DOI; e.g.: Petrović P, Jovanović J. The title of the article. Srp Arh Celok Lek. Online First, February 2017.

When the final article is assigned to volumes/issues of the journal, the Article in Press version will be removed and the final version will appear in the associated published volumes/issues of the journal. The date the article was made available online first will be carried over.

***Correspondence to:**

Slobodan TANASKOVIĆ

Vascular Surgery Clinic, Dedinje Cardiovascular Institute

Heroja Milana Tepića 1, Belgrade 11000, Serbia

e-mail: drslobex@yahoo.com, drslobex@gmail.com

Spleen-preserving surgical treatment of splenic artery aneurysm secondary to chronic pancreatitis and primary biliary cholangitis

Хируршки третман анеуризме лијеналне артерије као последица хроничног панкреатитиса и примарног билијарног холангитиса уз очување слезине

SUMMARY

Introduction Splenic artery aneurysm (SAA) represents the third cause of abdominal aneurysms, just after abdominal aorta and iliac arteries aneurysms, with overall prevalence of 1%. Pancreatitis has been linked with pseudoaneurysm formation of SA due to destruction of arterial wall by pancreatic enzymes, however true SAA associated with pancreatitis hasn't been described yet. We are presenting the first case of true SAA in a patient with chronic pancreatitis and primary biliary cholangitis successfully treated by surgical excision, direct arterial reconstruction and spleen preservation.

Case outline A 74-years-old male patient was admitted for multidetector computed tomography (MDCT) angiography due to suspected SAA and renal artery aneurysm (RAA). He was previously treated for chronic pancreatitis and primary biliary cholangitis. Upon admission, CT arteriography showed SAA 32 mm in diameter and RAA 12 mm with SAA being in direct contact with superior margin of the pancreas. Surgical treatment of SAA was indicated while RAA was treated conservatively. Intraoperatively, SAA adherent to the superior margin of pancreas was noted, followed by complete exclusion of the aneurysm and end-to-end splenic artery anastomosis. Histopathology showed atherosclerotic degeneration of arterial wall with all three layers presenting as true aneurysm. Two years after the surgery control CT angiography showed regular postoperative findings without further progression of RAA.

Conclusion This is the first case to describe a true SAA aneurysm originated on the field of previous episodes of chronic pancreatitis and primary biliary cholangitis. Surgical treatment including aneurysm resection and direct arterial reconstruction with spleen preservation showed satisfactory results.

Keywords: splenic artery aneurysm; chronic pancreatitis; primary biliary cholangitis; spleen-preservation surgery

САЖЕТАК

Увод Анеуризма лијеналне артерије (АЛА) представља трећи узрок свих анеуризми абдомена, а након анеуризми трбушне аорте и илијачних артерија, са укупном преваленцијом од 1%. Познато је да је панкреатитис повезан са стварањем псеудоанеуризме ЛА, као последица деструкције артеријског зида панкреасним ензимима, али повезаност панкреатитиса и праве анеуризме ЛА још увек није описана. Приказујемо први случај праве АЛА код пацијента са хроничним панкреатитисом и примарним билијарним холангитисом, успешно решен хируршком екизијом, директном реконструкцијом артерије и очувањем слезине.

Приказ болесника 74-годишњи болесник мушког пола примљен је ради мултидетекторске компјутеризоване томографије (MDCT) ангиографије, а због сумње на АЛА и анеуризму бубрежне артерије (АБА). Претходно је лечен од хроничног панкреатитиса и примарног билијарног холангитиса. По пријему, ЦТ ангиографија је показала пречник АЛА 32 mm и АБА 12 mm, при чему је АЛА у директном контакту са горњом ивицом панкреаса. Индикувано је хируршко лечење АЛА, док је АБА лечена конзервативно. Интраоперативно је верификована АЛА адхерентна за горњу ивицу панкреаса, након чега је учињена комплетна ексклузија анеуризме и термино-терминална анастомоза лијеналне артерије. Хистопатологија је показала атеросклеротску дегенерацију артеријског зида са сватри слоја, што говори у прилог праве анеуризме. Две године након операције, контролни ЦТ ангиографија је показала уредан постоперативни налаз, без даље прогресије АБА.

Закључак Ово је први случај који описује праву анеуризму ЛА, настала на пољу претходних епизода хроничног панкреатитиса и примарног билијарног холангитиса. Хируршко лечење, укључујући ресекцију анеуризме и директну реконструкцију артерије уз очување слезине, показало је задовољавајуће резултате.

Кључне речи: анеуризма лијеналне артерије; хронични панкреатитис; примарни билијарни холангитис; хирургија очувања слезине

INTRODUCTION

Splenic artery aneurysm (SAA) represents the third cause of abdominal aneurysms, just after abdominal aorta and aneurysms of iliac arteries [1, 2]. SAA is defined as dilatation of splenic artery >1 cm in diameter while in patients with SA > 2 cm surgical or endovascular treatment should be indicated. [3] The majority of patients with SAA are asymptomatic, while unspecific symptoms such as epigastric abdominal or the left upper quadrant pain, nausea, melena and anemia, vomiting or anorexia hematemesis could be seen as well [4, 5].

The exact cause of SAA is not entirely known, however atherosclerosis, trauma, portal hypertension, medial degeneration or dysplasia, pregnancy, and the female gender are known risk factors [3, 4]. Spontaneous rupture could be seen in 2–10% of the patients associated with high mortality up to 40%, especially in patients with pseudoaneurysm (PSA) or during pregnancy [6, 7, 8]. Pseudoaneurysms of SA are rare, more prone to rupture than true aneurysms and mostly associated with pancreatitis, trauma, iatrogenic cause or rarely peptic ulcer disease [9]. Pancreatitis has been linked with PSA formation of SA [10, 11] due to destruction of arterial wall by pancreatic enzymes causing inflammation, fragmentation of elastic tissue and consequent PSA formation, however true SAA associated with pancreatitis hasn't been described yet. We are presenting the first case of true SAA in a patient with chronic pancreatitis and primary biliary cholangitis successfully treated by surgical excision and arterial reconstruction.

CASE REPORT

A 74-years-old male patient was admitted to our Institution for multidetector computed tomography (MDCT) angiography. Prior to admission, abdominal CT and ultrasonography showed splenic artery aneurysm (SAA) 31 mm in diameter and left renal artery aneurysm (RAA) 12 mm. The patient denied any abdominal or back pain. His past medical history

included hypertension and hyperlipidemia, two years earlier radiofrequency ablation was performed for persistent atrial fibrillation. He was also previously treated for chronic pancreatitis and primary biliary cholangitis. Echocardiography showed regular findings with ejection fraction >60% and aortic and mitral valve mild insufficiency. All laboratory values were within referent values including pancreatic enzymes and parameters of kidney function.

Clinical examination showed regular pulses on lower extremities, ankle-brachial index was 1.0 on both legs. MDCT arteriography (Philips®, 128 slice device, Amsterdam, Netherlands) showed SAA 32 mm in diameter (Figure 1 and 2) as well as left RAA 12 mm. Direct contact between superior margin of the pancreas and the aneurysmal sac was clearly visible (Figure 2).

Surgical treatment of SAA was indicated while RAA was treated conservatively. Prior to surgery, 24-hour Holter monitoring was performed that revealed insignificant number of supraventricular extrasystoles and occasional first-grade atrioventricular block.

Following medial laparotomy, SAA was approached through lesser sac (Figure 3).

Intraoperatively, close contact of SAA sac with the superior margin of pancreas was noted to which it was partially adherent. Complete exclusion of SAA was performed followed by end-to-end splenic artery anastomosis (Figure 4 and 5).

Surgical procedure went uneventfully, still the first postoperative day, due to low hemoglobin, abdominal pain and suspected intrabdominal hematoma the patient was returned to the operating room. Hematoma was evacuated and the bleeding was taken care of from the superior margin of the pancreas. In the further postoperative course elevated values of alpha amylase (1200 U/L) and total bilirubin (120 mmol/L) were verified. Six days after the procedure there was significant decrease of alpha-amylase (350 U/L) values while total bilirubin was normal as well as all other laboratory values. Histopathology showed atherosclerotic degeneration of arterial wall with all three layers presenting as true aneurysm.

The patient was discharged on the 13th postoperative day. After six months follow up patient was doing well, all laboratory findings were within the reference values. Two years after the surgery control MDCT angiography showed regular findings after SA reconstruction (Figure 6) without further progression of RAA.

Ethics Committee of Dedinje Cardiovascular Institute approved this case – number 127/20. Informed consent has been obtained from the patient for publication of the case report and accompanying images.

DISCUSSION

SAA accounts for nearly 60% of all visceral artery aneurysms with overall prevalence of 1% [3]. Splenic artery aneurysms are up to 4 times more common in females while overall incidence increases to 10% in patients > 60 years and in patients with portal hypertension [12, 13]. Spontaneous rupture is associated with high mortality, up to 40% for true aneurysms, and even 90% for PSAs [8, 9, 10]. In patients with intraperitoneal SAA rupture, acute abdomen and hypovolemic shock, splenectomy and SA ligation are mostly performed [14, 15]. Spontaneous rupture is more frequent in true aneurysms > 2 cm making this diameter cut-off point for surgical or endovascular treatment.

Pancreatitis, on the other hand, has been associated with SA pseudoaneurysm development with high risk of rupture up to 40% and mortality up to 90% [10, 16]. It has been proposed that in the case of pancreatitis, pancreatic enzymes are responsible for destruction of arterial wall architecture and disintegration of elastic tissues, leading to formation of pseudoaneurysm [17]. Apart from direct damage of vascular structures by severe inflammation, a longstanding pseudocyst may also induce a pseudoaneurysm formation, by compression, ischemia or vascular erosion from enzymes within the pseudocyst [18].

In the presented case, true aneurysm of SA was verified, that occurred due to repeated episodes of chronic pancreatitis as evident contact was seen between the pancreas and aneurysmal sac, both, on CT imaging and intraoperatively, with SAA being adherent to superior margin of pancreas. However, histopathology findings showed all three layers of arterial wall without any thrombotic mass, which speaks in favor of aneurysm rather than pseudoaneurysm of the SA. Local secretion of pancreatic enzymes appears to have led to a weakening of the artery wall, loss of elastic tissue and aneurysmal degeneration. Increased incidence of SAA has been also reported in cirrhosis [19] and the patient in the presented case was previously treated for primary biliary cholangitis (cirrhosis).

As for the treatment options, surgical, endovascular or conservative approach could be applied in the management of patients with SAA [20, 21, 22], although endovascular treatment might be followed by serious complications [23]. Open surgery remains the gold standard for SAA treatment, although endovascular treatment with coil embolization or covered stenting and laparoscopic surgery are increasingly used for SAAs treatment in recent years [2]. In case of ruptured splenic artery aneurysm, SA ligation and splenectomy could be justified, however, due to the important immune function of the spleen, spleen-preserving surgery is recommended whenever possible. In case of SAA that is sufficiently far away from the hilum, as seen in the presented case, aneurysm resection and direct arterial reconstruction with the spleen preservation should be a priority.

This is the first case to describe a true SAA aneurysm originated on the field of previous episodes of chronic pancreatitis and primary biliary cholangitis. Surgical treatment including aneurysm resection and direct arterial reconstruction with spleen preservation showed satisfactory results.

Conflict of interest: None declared.

REFERENCES

1. Tcbc-Rj RA, Ferreira MC, Ferreira DA, Ferreira AG, Ramos FO. Splenic artery aneurysm. *Rev Col Bras Cir.* 2016;43(5):398-400. doi: 10.1590/0100-69912016005005. PMID: 27982336.
2. Akbulut S, Otan E. Management of Giant Splenic Artery Aneurysm Comprehensive Literature Review. *Medicine* 2015;94(27):e1016. doi:10.1097/MD.0000000000001016. PMID: 26166071.
3. Mariúba JVO. Splenic aneurysms: natural history and treatment techniques. *J Vasc Bras.* 2019 Dec 4;19:e20190058. doi: 10.1590/1677-5449.190058. PMID: 31839799.
4. De Silva WSL, Gamlaksha DS, Jayasekara DP, Rajamanthri SD. A splenic artery aneurysm presenting with multiple episodes of upper gastrointestinal bleeding: a case report. *J Med Case Rep.* 2017;11(1):123. doi: 10.1186/s13256-017-1282-7. PMID: 28468689; PMCID: PMC5415772.
5. Pejkić S, Tomić I, Opačić D, Pejinović L, Grubor N, Činara I, Davidović L. Splenic Artery Aneurysms: Two Cases of Varied Etiology, Clinical Presentation and Treatment Outcome. *Srp Arh Celok Lek.* 2015;143(5-6):326-31. doi: 10.2298/sarh1506326p. PMID: 26259408.
6. Martin D, Teixeira Farinha H, Dattner N, Rotman S, Demartines N, Sauvain MO. Spontaneous non-traumatic splenic artery aneurysm rupture: a case report and review of the literature. *Eur Rev Med Pharmacol Sci.* 2018;22(10):3147-3150. doi: 10.26355/eurev_201805_15074. PMID: 29863260.
7. Schatz RA, Schabel S, Rockey DC. Idiopathic Splenic Artery Pseudoaneurysm Rupture as an Uncommon Cause of Hemorrhagic Shock. *J Investig Med High Impact Rep.* 2015;3(2):2324709615577816. doi: 10.1177/2324709615577816. PMID: 26425639.
8. Ballout RA, Ghanem R, Nassar A, Hallal AH, Ghulmiyyah LM. [Splenic Artery Aneurysm \(SAA\) Rupture in Pregnancy: A Case Report of a Rare but Life-Threatening Obstetrical Complication.](#) *J Womens Health Dev* 2019;2(1):19-27. doi: 10.26502/fjwhd.2644-2884004. PMID: 31432025.
9. Tessier DJ, Stone WM, Fowl RJ, Abbas MA, Andrews JS, Bower T et al. Clinical features and management of splenic artery pseudoaneurysm: case series and cumulative review of literature. *J Vasc Surg* 2003; 38:969–974. doi: 10.1016/s0741-5214(03)00710-9. PMID: 14603202.
10. [Parikh M, Shah A, Abdellatif A.](#) Splenic artery pseudoaneurysm complicating pancreatitis. *J Gen Intern Med.* 2011;26(3):343-4. doi: 10.1007/s11606-010-1538-z. PMID: 20967507.
11. Yashavanth HS, Jagtap N, Singh JR, Ramchandani M, Lakhtakia S, Tandan M, Gupta R, Vamsi M, Bhaware B, Rao GV, Reddy DN. Hemosuccus pancreaticus – a systematic approach. *J Gastroenterol Hepatol.* 2021 Jan 14. doi: 10.1111/jgh.15404. Epub ahead of print. PMID: 33445212.
12. Dave SP, Reis ED, Hossain A, Taub PJ, Kerstein MD, Hollier LH. Splenic artery aneurysm in the 1990s. *Ann Vasc Surg.* 2000;14(3):223–229. doi: 10.1007/s100169910039. PMID: 10796953.
13. Reardon PR, Otah E, Craig ES, Matthews BD, Reardon MJ. Laparoscopic resection of splenic artery aneurysms. *Surg Endosc.* 2005;19(4):488–493. doi: 10.1007/s00464-004-8916-8. PMID: 15959711.
14. Aydın MT, Fersahoğlu MM, Tezer S, Okuducu M, Ağca B, Memişoğlu K. Spontaneous rupture of the splenic artery aneurysm: a rare clinical presentation of acute abdomen. *Ulus Travma Acil Cerrahi Derg.* 2016;22(1):106–8. doi: 10.5505/tjtes.2015.32654. PMID: 27135088.
15. Papadomichelakis A, Anyfantakis D, Kastanakis M, Karona P, Bobolakis E. Rupture of a splenic artery aneurysm in a previously healthy 53-year-old male. *J Med Life.* 2014;7:69–70. PMID: 25870677.
16. [Zarrouki Y, Elhaouati R, Khallouki M, Boumzebra D, Samkaoui MA.](#) Ruptured splenic artery pseudoaneurysm complicating acute pancreatitis. *Ann Fr Anesth Reanim.* 2011;30(11):e77-8. doi: 10.1016/j.annfar.2011.07.011. PMID: 21981847.
17. Puri S, Nicholson AA, Breen DJ. Percutaneous thrombin injection for the treatment of a post-pancreatitis pseudoaneurysm. *Eur Radiol* 2003;13:L79–L82. doi: 10.1007/s00330-003-1836-5. PMID: 15018170.
18. Flati G, Andren-Sandberg A, La Pinta M, Porowska B, Carboni M. Potentially fatal bleeding in acute pancreatitis: pathophysiology, prevention and treatment. *Pancreas* 2003;26:8–14. doi: 10.1097/00006676-200301000-00002. PMID: 12499910.
19. [Kaya M, Baran S, Güya C, Kaplan MA.](#) Prevalence and predictive factors for development of splenic artery aneurysms in cirrhosis. *Indian J Gastroenterol.* 2016;35(3):201-6. doi: 10.1007/s12664-016-0670-z. PMID: 27256433.
20. Berek P, Štefanić P. Surgical Treatment of Splenic Artery Aneurysm. *Eur J Vasc Endovasc Surg.* 2017;54(1):11. doi: 10.1016/j.ejvs.2017.02.019. PMID: 28318996.
21. Ouchi T, Kato N, Nakajima K, Higashigawa T, Hashimoto T, Chino S, Sakuma H. Splenic artery aneurysm treated with endovascular stent grafting: a case report and review of literature. *Vasc Endovascular Surg.* 2018;52(8):663-668. doi: 10.1177/1538574418785252. PMID: 29940816.
22. Qiu P, Zhu H. Endovascular Repair of Anomalous Splenic Artery Aneurysm with Systemic Lupus Erythematosus. *Ann Vasc Surg.* 2019;55:309. doi: 10.1016/j.avsg.2018.06.025. PMID: 30217713.

23. Tipaldi MA, Pisano A, Krokidis M, Laurino F, Corradini LG, Lucatelli P, Venturini M, Laghi A, Rossi M. Extravascular Migration of Thrombosed Covered Stents after Endovascular Exclusion of Splenic or Hepatic Artery Aneurysms and Pseudoaneurysms: An Underestimated Phenomenon. *J Vasc Interv Radiol*. 2021;32(2):317-320. doi: 10.1016/j.jvir.2020.10.004. PMID: 33272816.

Paper accepted

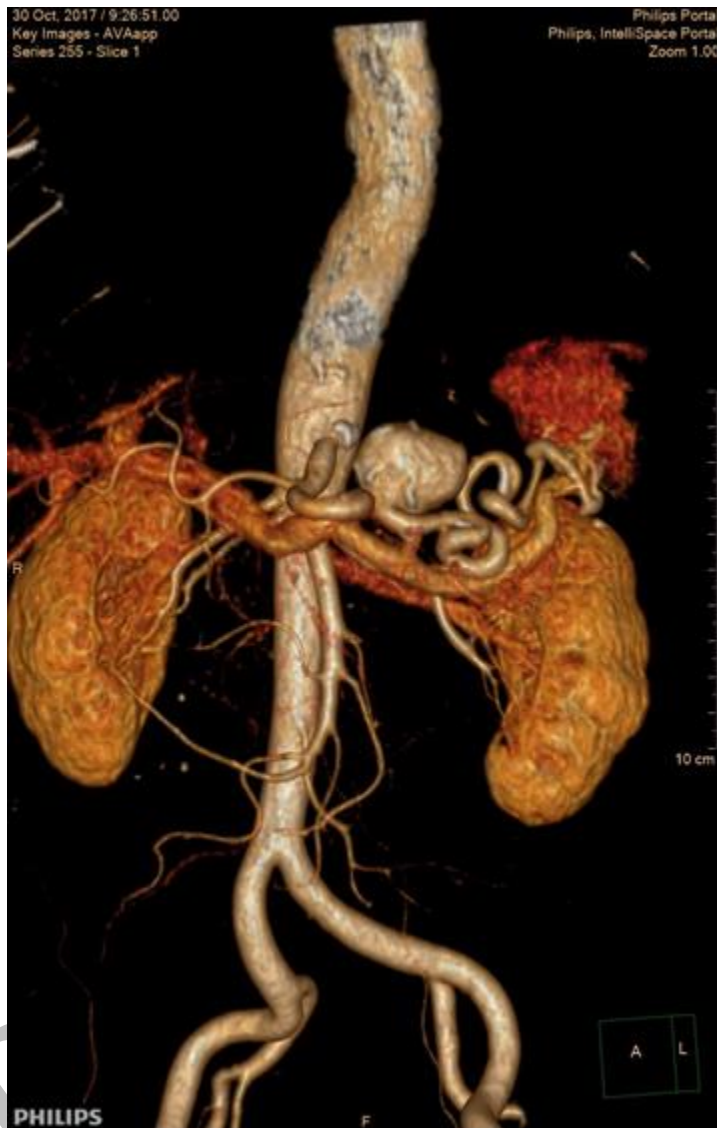

Figure 1. Multidetector computed tomography angiography; splenic artery aneurysm – 32 mm

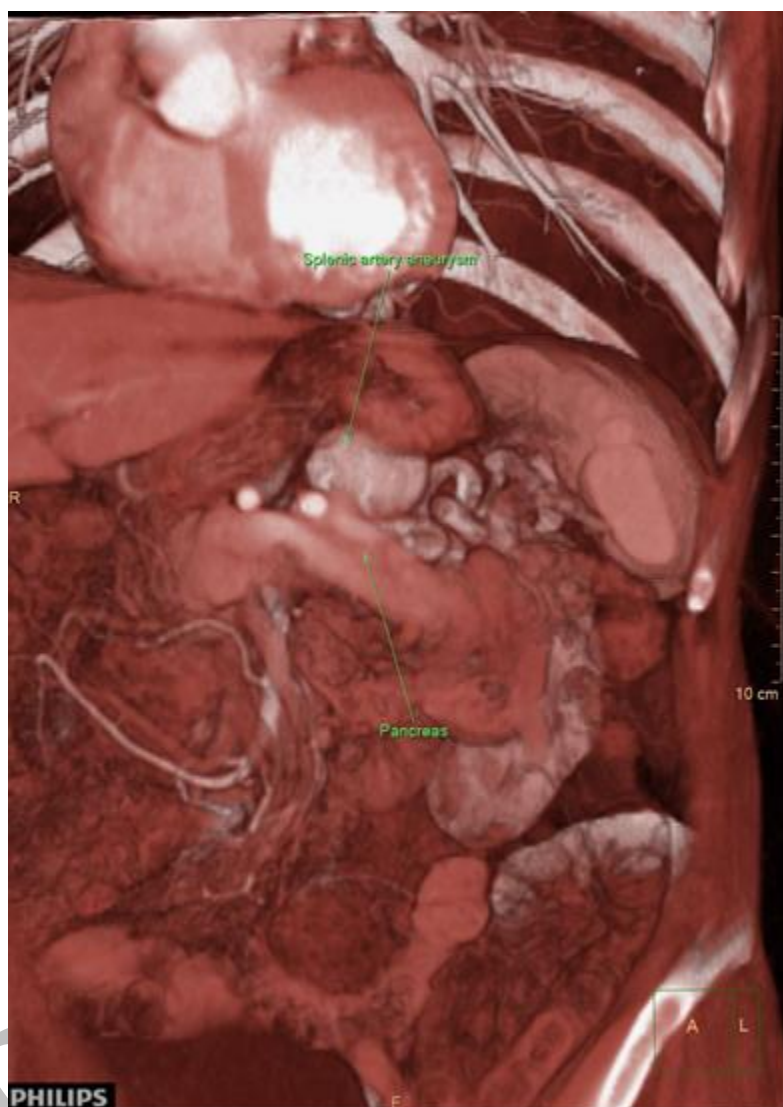

Figure 2. Multidetector computed tomography angiography; splenic artery aneurysm adherent to superior margin of the pancreas

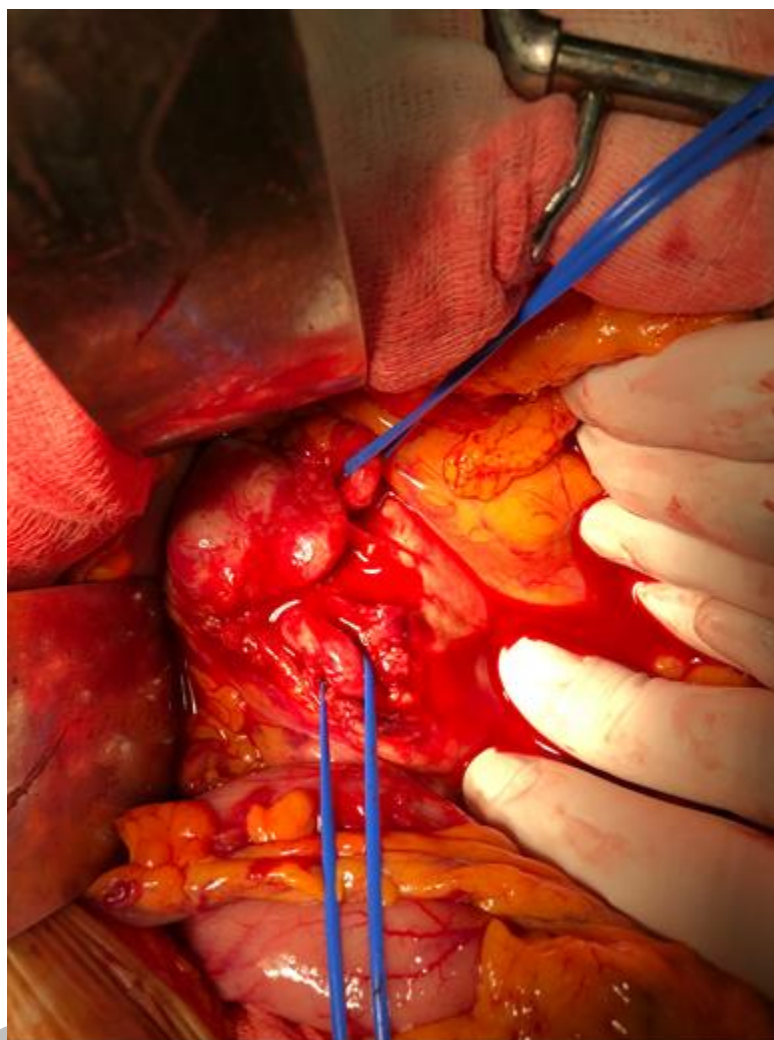


Figure 3. Intraoperative findings showing splenic artery aneurysm

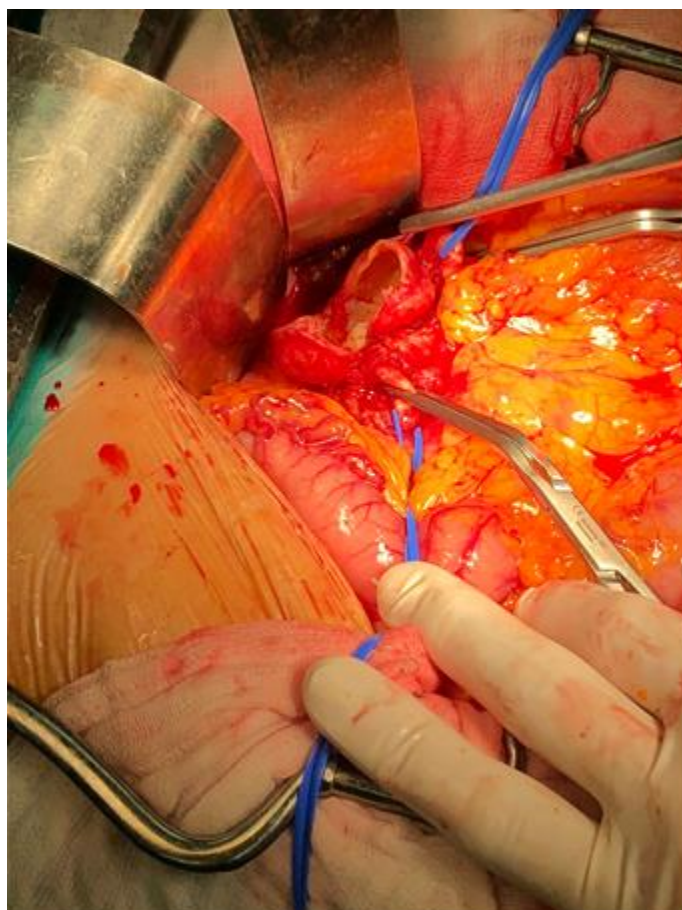


Figure 4. Intraoperative findings; resection of splenic artery aneurysm – thin arterial wall without thrombotic mass

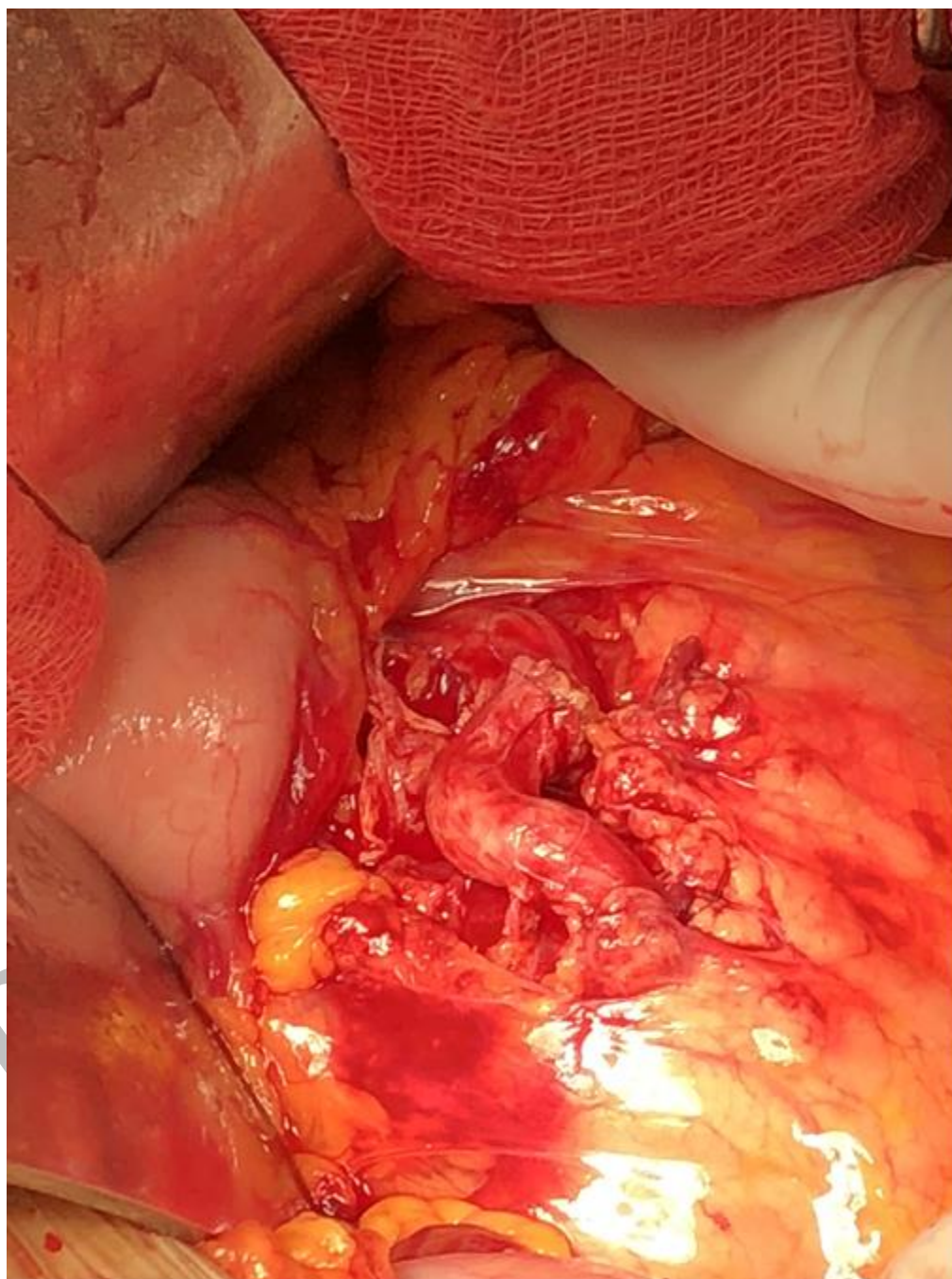


Figure 5. Intraoperative findings; successful splenic artery reconstruction by end-to-end anastomosis

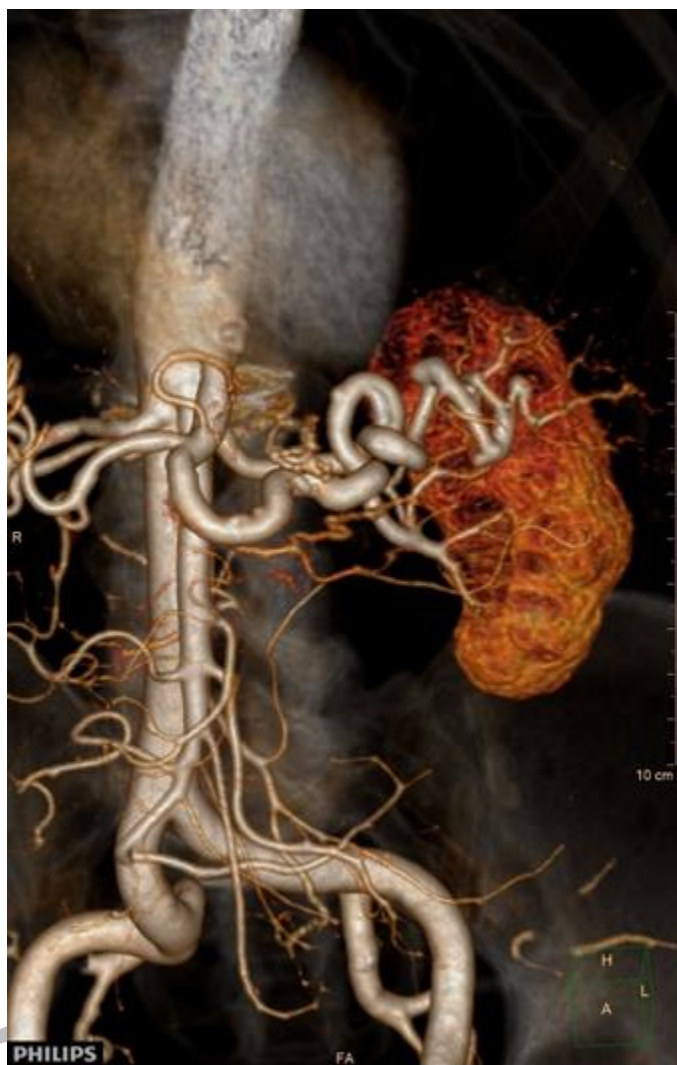

Figure 6. Multidetector computed tomography angiography; splenic artery after the reconstruction