



**СРПСКИ АРХИВ**  
ЗА ЦЕЛОКУПНО ЛЕКАРСТВО  
**SERBIAN ARCHIVES**  
OF MEDICINE

Address: 1 Kraljice Natalije Street, Belgrade 11000, Serbia

+381 11 4092 776, Fax: +381 11 3348 653

E-mail: [office@srpskiarhiv.rs](mailto:office@srpskiarhiv.rs), Web address: [www.srpskiarhiv.rs](http://www.srpskiarhiv.rs)

**Paper Accepted\***

**ISSN Online 2406-0895**

**Case report / Приказ болесника**

Bojan Janjić<sup>1</sup>, Branislav Ilić<sup>1,\*</sup>, Aleksa Marković<sup>1</sup>, Bojan Gačić<sup>1</sup>, Radojica Dražić<sup>1</sup>,  
Dušan Kosanović<sup>2</sup>

**Surgical extraction of the impacted mandibular third molar:  
vestibular bone window technique**

Хируршка екстракција импактираног доњег умњака:  
техника вестибуларног коштаног прозора

<sup>1</sup>University of Belgrade, School of Dental Medicine, Clinic for Oral Surgery, Belgrade, Serbia;

<sup>2</sup>University of Belgrade, School of Dental Medicine, Clinic for pediatric and preventive dentistry, Belgrade, Serbia

**Received: December 28, 2020**

**Revised: June 20, 2021**

**Accepted: June 21, 2021**

**Online First: July 1, 2021**

**DOI: <https://doi.org/10.2298/SARH201228057J>**

\* **Accepted papers** are articles in press that have gone through due peer review process and have been accepted for publication by the Editorial Board of the *Serbian Archives of Medicine*. They have not yet been copy-edited and/or formatted in the publication house style, and the text may be changed before the final publication.

Although accepted papers do not yet have all the accompanying bibliographic details available, they can already be cited using the year of online publication and the DOI, as follows: the author's last name and initial of the first name, article title, journal title, online first publication month and year, and the DOI; e.g.: Petrović P, Jovanović J. The title of the article. *Srp Arh Celok Lek*. Online First, February 2017.

When the final article is assigned to volumes/issues of the journal, the Article in Press version will be removed and the final version will appear in the associated published volumes/issues of the journal. The date the article was made available online first will be carried over.

\***Correspondence to:**

Branislav ILIĆ

Clinic for Oral Surgery, Doktora Subotića 4, 11000 Belgrade, Serbia

E-mail: [branislav.ilic@stomf.bg.ac.rs](mailto:branislav.ilic@stomf.bg.ac.rs)

## Surgical extraction of the impacted mandibular third molar: vestibular bone window technique

Хируршка екстракција импактираног доњег умњака:  
техника вестибуларног коштаног прозора

### SUMMARY

**Introduction** Surgical extraction of impacted mandibular third molar can lead to the periodontal defect on distal aspect of the mandibular second molar causing pocket formation, tooth sensitivity, food retention, postoperative infections. Different surgical techniques have been proposed to reduce periodontal complications.

**Case Outline** We presented five cases treated with Vestibular Bone Window Technique. Considering data from the literature review, benefits and limitations of the technique are discussed and compared to the Standard Surgical Technique.

**Conclusion** Vestibular Bone Window Technique might be recommended surgical procedure for the extraction of impacted mandibular third molar when bucco-distal bone wall is present preoperatively. Taking into account only five cases, future work should consider a randomized clinical trial with the larger stratified samples.

**Keywords:** Mandibular third molar, Periodontal defect, Vestibular Bone Window Technique

### САЖЕТАК

**Увод** Хируршко вађење импактираног доњег умњака може проузроковати појаву пародонталног дефекта дистално од другог молара. Он доводи до настанка пародонталног цела, осетљивости зуба, западања хране, постоперативне инфекције. Различите хируршке технике су предложене како би се спречио настанак ових компликација.

**Приказ случајева** У раду је приказано пет пацијената којима су хируршки извађени импактирани доњи умњаци техником вестибуларног коштаног прозора. Разматрајући податке из литературе, описали смо предности и мане ове технике поредећи је са стандардном хируршком техником.

**Закључак** Техника вестибуларног коштаног прозора може се препоручити за хируршку екстракцију импактираног доњег умњака онда када је буко-дистална кост присутна преоперативно. С обзиром на мали узорак од свега пет пацијената, препорука је да се будуће истраживање реализује као рандомизована клиничка студија на стратификованом узорку.

**Кључне речи:** Импактирани доњи умњак, Пародонтални дефект, Техника вестибуларног коштаног прозора

### INTRODUCTION

Surgical extraction of impacted mandibular third molar (M3M) is one of the most frequent procedures in oral surgery. It is followed by pain, swelling, trismus, or alveolitis that impairs the patient's overall quality of life [1, 2]. If the impaction is deep, periodontal defect on distal aspect of the mandibular second molar (M2M) can occur postoperatively resulting in tooth sensitivity/mobility, food retention, fetor, or postoperative infections. Different treatment strategies (such as Vestibular Bone Window Technique - VBWT) have been proposed to reduce secondary periodontal complications.[3]

## CASE REPORT

Five patients (20 to 29 years old) were treated at the Clinic for Oral Surgery, School of Dental Medicine in Belgrade, where surgical extraction of impacted M3M was performed using VBWT. The procedure was carried out under local anesthesia and full-thickness envelope flap (Figure 1). Prior to surgery, depth of periodontal pocket on the distal side of M2M was measured. Comparing to the standard surgical technique (SST) in which osteotomy is performed on the crestal part of the alveolar ridge (distally from M2M), in VBWT osteotomy is performed only as a small window on vestibular cortex (3-5mm below the highest point of bone). The procedure was done using the round bur and a handpiece with copious saline irrigation. The bone tunnel was prepared obliquely and downwards, till contact with the impacted tooth. If M3M was fully impacted, additional osteotomy above the crown was performed, on the bucco-distal side of the crown. Depending on the position, tooth was divided using a tungsten fissure bur. Throughout the bony window, a straight elevator was introduced pushing first the crown, and the roots upwards and dislodging them outside the alveolus (Figure 2). After the inspection and curettage of granulation tissue, the wound was rinsed with saline and single sutures were used. The postoperative period was uneventful in all five cases. Sutures were removed on the 7<sup>th</sup> day and additional periodontal probe measurement was conducted one month after the surgery (Figure 3).

All the subjects from the study had bucco-distal bony bridge present before the surgery. Using the VBWT, we managed to preserve it and prevent soft tissue from collapsing. The results of this approach were confirmed on periodontal measurements, one month after the surgery. The patients didn't declare any complaints postoperatively (short-term nor long-term). Postoperative pain, swelling, and trismus were recorded and estimated as acceptable (similar to the ones in SST) but were not evaluated additionally.

## DISCUSSION

Our findings indicate that VBWT preserves periodontal tissues on the distal aspect of M2M. The creation of a bony window on the vestibular aspect of the impacted third molar maintains bucco-distal bony bridge. That bone structure is essential because it supports soft tissues, preventing them from collapsing (Figure 4). Furthermore, in all of the five cases, periodontal pockets depth on the distal side of M2M were the same as before surgery. There were no changes in soft tissue architecture on one-month follow-up, and post-operative discomfort abated.

These findings correlate to the research of Peñarrocha and Galán [4]. The authors were the first to describe VBWT, stating that it minimizes the time required for ostectomy, postoperative pain, swelling, trismus, and periodontal risks for the second molar. However, they conducted the pilot study without the randomization on just four patients, so it is a little bit presumptuous to conclude all of that. Without the control group, there are doubts on the conclusions on postoperative pain, swelling, and trismus since they are not related to the ostectomy site. Then again, alteration of a bone window to the vestibular cortex and preservation of bucco-distal bony bridge inexplicably promote periodontal healing on distal aspects of M2M, maintaining the soft tissue structures, thus resulting in less postoperative complications.

Periodontal status of M2M after wisdom tooth surgical extraction is not only affected by ostectomy location but with flap design, alveolar preservation, or suturing techniques. When standard ostectomy is performed (bucco-distal from the second molar), the periodontal status of M2M is unpredictable. It depends on the patient's age, third molar impaction type and depth, and pre-surgical periodontal defects.[5] However, there are no clear scientific data to explain the outcome of third molar surgical extraction on M2M periodontal status [6-8]. It is also unclear how the flap design [9-11] or suturing technique [12] will alter the results.

Although we managed to maintain bucco-distal bone bridge in all of the five cases and retain periodontal health of M2M, this investigation was conducted only on the subjects that had this part of the bone present preoperatively. We assumed there was no point in testing VBWT on semi-impacted wisdom teeth that are already missing this part of the bone. However, SST in that clinical condition requires additional osteotomy that will generate larger post-extraction defect on alveolar bone distal to the second molar. In those assets, it is reasonable to anticipate the loss of periodontal support and periodontal pocket formation. We believe that VBWT could benefit periodontal health of the second molar in those impaction types where M3M undermines the second molar. Future work should consider a randomized clinical trial with the stratified samples that will compare M2M periodontal health (pre and postoperatively) between VBWT and SST groups in different preoperative clinical conditions.

Additionally, we observed that VBWT also differs from SST by its sensitivity since it requires additional surgical routine and skills. Bone osteotomy is performed on the vestibular cortex, mesial from the roots of the M3M. It is very important not to damage the distal root of M2M when creating this window. If the risk is too high or the surgeon is unable to extract the tooth this way, we suggest alteration of the protocol to SST.

Taken together the experience from case reports and literature review, VBWT might be a recommended surgical procedure for the extraction of impacted M3M when bucco-distal bone is present preoperatively and SST generates the risk for development of periodontal complications.

**Ethical compliance statement:** We confirm that we have read the journal's position on issues involving ethical publication and affirm that this work is consistent with those guidelines.

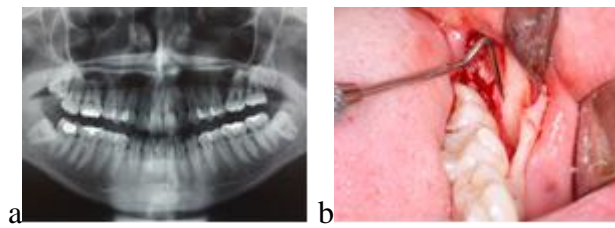
**Ethical standards:** All procedures performed in studies involving human participants were in accordance with the ethical standards of the institutional and/or national research committee and with the 1964 Helsinki declaration and its later amendments or comparable ethical standards. Written consent to publish all shown material was obtained from the patient.

**Conflict of interest:** None declared.

Paper accepted

## REFERENCES

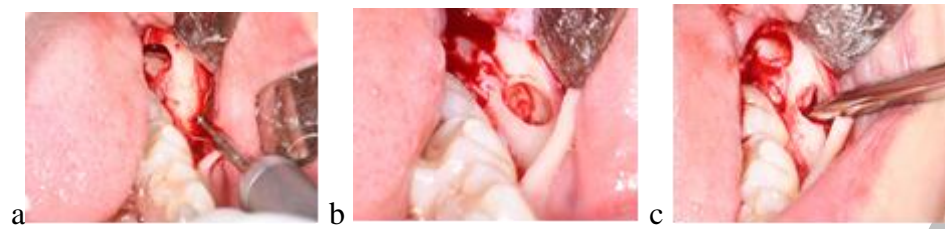1. L. Duarte-Rodrigues, E.F. Primo Miranda, T.O. Souza, H. Neves de Paiva, S.G. Moreira Falci, E.L. Galvão. Third molar removal and its impact on quality of life: systematic review and meta-analysis. *Qual Life Res.* 2018 Oct;27(10):2477-2489. PMID: 29797177. DOI: 10.1007/s11136-018-1889-1. Epub 2018 May 24.
2. H. Ghaemina, M. El Nienhuijs, V. Toedtling, J. Perry, M. Tummers, Th. Hoppenreijns, W. Jm Van der Sanden, T.G. Mettes. Surgical removal versus retention for the management of asymptomatic disease-free impacted wisdom teeth. *Cochrane Database Syst Rev.* 2020 May 4;5(5):CD003879. DOI:10.1002/14651858.CD003879.pub5. PMID: 32368796. PMCID: PMC7199383.
3. L. Barbato, Z. Kalemaj, J. Buti, M. Baccini, M. La Marca, M. Duvina, P. Tonelli. Effect of Surgical Intervention for Removal of Mandibular Third Molar on Periodontal Healing of Adjacent Mandibular Second Molar: A Systematic Review and Bayesian Network Meta-Analysis. *J Periodontol.* 2016 Mar;87(3):291-302. DOI: 10.1902/jop.2015.150363. Epub 2015 Nov 26. PMID: 26609696.
4. Peñarrocha Diago M, Galán Gil S, Peñarrocha Diago M. Vestibular bone window for the extraction of impacted lower third molars: four case reports. *Med Oral Patol Oral Cir Bucal.* 2008 Aug 1;13(8):E508-10. PMID: 18667986.
5. White RP, Jr, Fisher EL, Phillips C, Tucker M, Moss KL, Offenbacher S. Visible third molars as risk indicator for increased periodontal probing depth. *J Oral Maxillofac Surg.* 2011;69:92–103. [PubMed: 21050642]
6. Tabrizi R, Arabion H, Gholami M. How will mandibular third molar surgery affect mandibular second molar periodontal parameters? *Dent Res J (Isfahan).* 2013 Jul;10(4):523-6. PMID: 24130590; PMCID: PMC3793418.
7. Stella PEM, Falci SGM, Oliveira de Medeiros LE, Douglas-de-Oliveira DW, Gonçalves PF, Flecha OD, Dos Santos CRR. Impact of mandibular third molar extraction in the second molar periodontal status: A prospective study. *J Indian Soc Periodontol.* 2017 Jul-Aug;21(4):285-290. doi: 10.4103/jisp.jisp\_79\_17. PMID: 29456302; PMCID: PMC5813342.
8. Pham TAV, Nguyen NH. Periodontal Status of the Adjacent Second Molar after Impacted Mandibular Third Molar Surgical Extraction. *Contemp Clin Dent.* 2019 Apr-Jun;10(2):311-318. doi: 10.4103/ccd.ccd\_634\_18. PMID: 32308296; PMCID: PMC7145245.
9. Chen YW, Lee CT, Hum L, Chuang SK. Effect of flap design on periodontal healing after impacted third molar extraction: a systematic review and meta-analysis. *Int J Oral Maxillofac Surg.* 2017 Mar;46(3):363-372. doi: 10.1016/j.ijom.2016.08.005. Epub 2016 Sep 3. PMID: 27600798.
10. Leechanavanichpan P, Rodanant P, Leelarungsun R, Wongsirichat N. Postoperative Pain Perception and Patient's Satisfaction After Mandibular Third Molar Surgery by Primary Closure With Distal Wedge Surgery. *J Clin Med Res.* 2019 Jul;11(7):489-494. doi: 10.14740/jocmr3841. Epub 2019 Jun 11. PMID: 31236167; PMCID: PMC6575117.
11. Glera-Suárez P, Soto-Peñaloza D, Peñarrocha-Oltra D, Peñarrocha-Diago M. Patient morbidity after impacted third molar extraction with different flap designs. A systematic review and meta-analysis. *Med Oral Patol Oral Cir Bucal.* 2020 Mar 1;25(2):e233-e239. doi: 10.4317/medoral.23320. PMID: 32062667; PMCID: PMC7103454.
12. Cetinkaya BO, Sumer M, Tutkun F, Sandikci EO, Misir F. Influence of different suturing techniques on periodontal health of the adjacent second molars after extraction of impacted mandibular third molars. *Oral Surg Oral Med Oral Pathol Oral Radiol Endod.* 2009 Aug;108(2):156-61. doi: 10.1016/j.tripleo.2009.03.024. PMID: 19615653.



**Figure 1.** Preoperative X-ray and intraoperative insight: a – mandibular lower left third molar with Pell–Gregory II-b type of the impaction; b – bucco-distal bone is present preoperatively

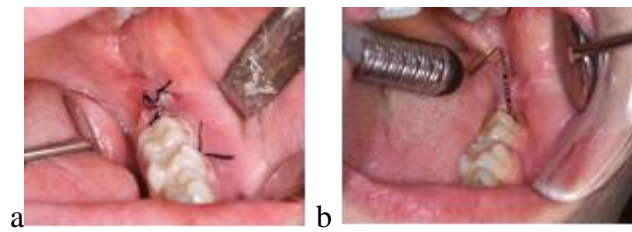
Paper accepted





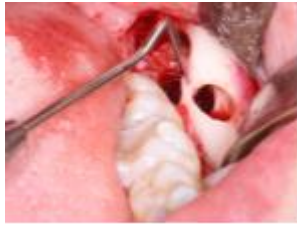**Figure 2.** Surgical procedure for vestibular bone window technique: a and b – bone tunnel preparation; c – tooth extraction through bony window

Paper accepted



**Figure 3.** Postoperative insight and periodontal measurement: a – the wound is sutured with single sutures; b – postoperative periodontal measurement on follow-up was conducted

Paper accepted



**Figure 4.** Bucco-distal bony bridge: using vestibular bone window technique, preservation of bucco-distal bony bridge was maintained

Paper accepted