



СРПСКИ АРХИВ
ЗА ЦЕЛОКУПНО ЛЕКАРСТВО
SERBIAN ARCHIVES
OF MEDICINE

Address: 1 Kraljice Natalije Street, Belgrade 11000, Serbia

+381 11 4092 776, Fax: +381 11 3348 653

E-mail: office@srpskiarhiv.rs, Web address: www.srpskiarhiv.rs

Paper Accepted*

ISSN Online 2406-0895

Case Report / Приказ болесника

Mariusz Chabowski^{1,2,†}, Wiktor Pawlowski^{1,2}, Michał Lesniak^{1,2}, Agnieszka Ziomek^{1,2},
Maciej Malinowski^{1,2}, Tadeusz Dorobisz^{2,3}, Dariusz Janczak^{1,2}

**Successful postoperative pancreatic fistula treatment
with the use of somatostatin infusion
after duodenal gastrointestinal stromal tumor resection**

Успешна постоперативна терапија фистуле панкреаса инфузијом
соматостатина после ресекције дуоденалног гастроинтестиналног
стромалног тумора

¹Division of Surgical Procedures, Department of Clinical Nursing, Faculty of Health Science, Wrocław Medical University, Wrocław, Poland;

²Department of Surgery, 4th Military Teaching Hospital, Wrocław, Poland;

³Department of Clinical Basics of Physiotherapy, Faculty of Health Science, Wrocław Medical University, Wrocław, Poland

Received: April 13, 2018

Revised: March 20, 2019

Accepted: May 17, 2019

Online First: May 24, 2019

DOI: <https://doi.org/10.2298/SARH180413053C>

*Accepted papers are articles in press that have gone through due peer review process and have been accepted for publication by the Editorial Board of the *Serbian Archives of Medicine*. They have not yet been copy edited and/or formatted in the publication house style, and the text may be changed before the final publication.

Although accepted papers do not yet have all the accompanying bibliographic details available, they can already be cited using the year of online publication and the DOI, as follows: the author's last name and initial of the first name, article title, journal title, online first publication month and year, and the DOI; e.g.: Petrović P, Jovanović J. The title of the article. *Srp Arh Celok Lek*. Online First, February 2017.

When the final article is assigned to volumes/issues of the journal, the Article in Press version will be removed and the final version will appear in the associated published volumes/issues of the journal. The date the article was made available online first will be carried over.

†Correspondence to:

Mariusz CHABOWSKI

Dept of Surgery, 4th Military Teaching Hospital, 5 Weigla Street, 50-981 Wrocław, Poland

E-mail: mariusz.chabowski@gmail.com

Successful postoperative pancreatic fistula treatment with the use of somatostatin infusion after duodenal gastrointestinal stromal tumor resection

Успешна постоперативна терапија фистуле панкреаса инфузијом
соматостатина после ресекције дуоденалног гастроинтестиналног
стромалног тумора

SUMMARY

Introduction According to the International Study Group on Pancreatic Fistula, a postoperative pancreatic fistula is defined as every case of fluid leak on the third (or later) postoperative day, in which the level of amylase in the collected fluid is at least three times higher than the serum amylase level. Depending on the stage and the designated management, pancreatic fistulas are divided into three categories: A (mild), B, and C (severe). Regardless of favorable conditions, exocrine pancreatic secretion is the key factor in fistula formation. The decrease in pancreatic secretion caused by somatostatin and its analogues combined with parenteral nutrition is a well-established treatment method in PF management.

Case outline The case of a 69-year-old patient who had undergone a resection of a duodenal gastrointestinal stromal tumor located directly above the major duodenal papilla is presented. An excessive drainage of amylase-rich fluid was observed in the postoperative period. Treatment comprised a continuous infusion of somatostatin and parenteral nutrition. Fistula closure was accomplished on postoperative day 14, confirmed by a radical decrease in the volume of drainage and low amylase levels in the collected fluid. The patient remained in a good clinical state and was discharged from hospital on postoperative day 20.

Conclusion This is an example of the early diagnosis of a postoperative pancreatic fistula, treated conservatively with the use of somatostatin. Clinical awareness after surgery of the stromal tumor in direct contact with pancreatic tissues in connection with routine amylase level assessment led to a quick diagnosis of the pancreatic fistula and the therapy led to uneventful outcome.

Keywords: pancreatic fistula; somatostatin; GIST; postoperative course

САЖЕТАК

Увод Према Међународној студијској групи за дефиницију панкреасне фистуле, постоперативна панкреасна фистула је сваки случај цурења течности на трећи (или каснији) постоперативни дан, где је ниво амилазе у испуштеној течности најмање три пута већи од нивоа амилазе у серуму. У зависности од степена и њиме условљеног третмана, панкреасне фистуле се деле у три категорије: А (благих симптоми), Б и Ц (тешки симптоми). Без обзира на повољне услове, екзокрино лучење панкреаса је кључни фактор у формирању фистуле. Смањење секреције панкреаса изазване соматостатином и његовим еквивалентима у комбинацији са парентералном исхраном добро је утемељен метод у третману панкреасне фистуле.

Приказ болесника У овом раду приказан је 69-годишњи болесник који је био подвргнут ресекцији дуоденалног гастроинтестиналног стромалног тумора, који се налазио непосредно изнад велике дуоденалне папиле. У постоперативном периоду је забележена прекомерна дренажа течности са високим нивоима амилазе. Конзервативни третман састојао се од континуиране инфузије соматостатина и парентералне исхране. Потпуно затварање фистуле је постигнуто 14. постоперативног дана, што је потврђено радикалним смањењем количине издрениране течности и ниским нивоом амилазе у сакупљеној течности. Болесник је остао у добром клиничком стању и отпуштен је из болнице 20. постоперативног дана.

Закључак Овај приказ представља пример рано дијагностиковане постоперативне панкреасне фистуле конзервативно лечене соматостатином. Постоперативно клиничко разумевање важности директног контакта стромалног тумора са ткивом панкреаса, у комбинацији са рутинским утврђивањем нивоа амилазе, довело је до брзе дијагнозе фистуле панкреаса, а терапија је довела до исхода без компликација.

Кључне речи: панкреасна фистула; соматостатин; гастроинтестинални стромални тумор; постоперативни ток

INTRODUCTION

A postoperative pancreatic fistula is defined according to International Study Group on Pancreatic Fistula Definition as every case of fluid leak on the third (or later) postoperative day, where the level of amylase in the collected fluid is at least 3 times higher than the serum

amylase level. Depending on the stage and therefore the designated management, pancreatic fistulas are divided into 3 categories: A (mild symptoms), B and C (severe symptoms). Regardless of favorable conditions, the effective exocrine pancreatic secretion is the key factor in the fistula formation. A decrease in pancreatic secretion caused by somatostatin and its analogues combined with parenteral nutrition is a well-established treatment method in PF management, and is suitable in most cases.

Postoperative pancreatic fistula (POPF) can either be the direct result of pancreatic surgery and its surroundings (as in our case) or trauma of the pancreas. POPF after a pancreatoduodenectomy remains the leading cause of morbidity and mortality after surgery. The true occurrence of POPF is difficult to assess; depending on the literature – it ranges from 6.2% to 75.6%. The lack of a uniform definition of a pancreatic fistula – or the exact moment of PF diagnosis – results in such an extreme discrepancy [1].

CASE REPORT

A 69-year-old man, without a previous history of illness, was admitted to the catheterization laboratory due to the fact that he had an inferior wall myocardial infarction with ST segment elevation. Percutaneous coronary intervention was performed with the insertion of a drug-eluting stent (DES). Three days after the procedure an incident of melaena with corresponding anemia was observed in laboratory tests. An upper GI endoscopy revealed a firm ulcerative duodenal inflammatory tumor located at the Vater's papilla, narrowing the lumen of the duodenum (Figure 1).

The subsequent abdominal CT scans presented a 42x28x30mm tumor with uneven margins and possible pancreas infiltration (Figure 2).

Biopsies taken during endoscopy of the tumor revealed that it was an undifferentiated inflammatory tumor. Due to the recent severe myocardial infarction, the placement of a DES in the coronary arteries and the necessity for anticoagulation therapy, the patient was offered the option of delaying the operation.

The patient was admitted to the surgical clinic 3 months later. One day before the operation, ERCP was performed and a 10 French stent was inserted in the common bile duct

as a precaution against preoperative bile duct injuries as a landmark. During the elective laparotomy, a firm duodenal tumor with an ulceration on top was observed above the Vater's papilla. The tumor tissues were oriented towards the head of the pancreas. The tumor was carefully dissected from the pancreas, although some preparation and resection of the pancreatic tissues was unavoidable in this case. Subsequently the proximal part of the duodenum with the tumor (just above the Vater's papilla) and the distal one third of the stomach was excised. The gastrointestinal tract was then restored with a side-to-side jejunogastric antecolic anastomosis, aided with Braun's anastomosis below. Anastomoses were performed with the use of absorbable mono-filament sutures in 1-2 layers. The postoperative histopathology revealed a 25x25mm gastrointestinal stromal tumor of the duodenum, with clean surgical margins (Figure 3).

A few hours after surgery and on post-op day one, serum amylase levels were 344 and 248 U/L. Drainage fluid amylase levels collected on the 1st, 3rd and later postoperative days were within the range of 1,100-3,000 U/L. Due to these findings acquired by the laboratory, the visual assessment of the drained abdominal fluid and intraoperative preparation of the pancreatic tissue, a pancreatic fistula was diagnosed. The conservative treatment comprised total and subsequently partial parenteral nutrition (10 days in total) together with a continuous somatostatin infusion of 6mg/24h. Laboratory indicators of fistula closure were successfully obtained on the 14th day after surgery. The somatostatin dosage was then reduced to 3mg/24h for the next 48 hours and subsequently discontinued. The patient remained in a good clinical status without any elevation of inflammatory indicators during the fistula treatment period. The man was discharged from hospital 20 days after surgery. The abdominal drains were removed four days prior to discharge.

A surprisingly high amylase level from the abdominal fluid collection was observed on the 7th day of fistula treatment (9,400 U/L). The laboratory findings were contradictory to the good overall condition of the patient. Therefore, we presumed that the drainage blockage and fluid concentration caused such laboratory test results.

DISCUSSION

In the past, the available studies defined PF individually, which made the comparison of treatment results difficult. In 2005, Bassi et al (ISGPF) developed a widely-accepted

definition of a postoperative pancreatic fistula [2]. According to ISGPF, the POPF is a drain output of any measurable volume of fluid on or after postoperative day 3 with an amylase content three times higher than the serum amylase activity [3]. Successful treatment of POPF depends on early diagnosis. Regardless of the ISGPF definition, additional useful predictors of fistula formation include: 1) serum amylase levels above 130U/l four hours after surgery or on post-operative day one; 2) amylase level in the drained abdominal fluid over 5000 U/l on post-operative day 1 [4,5].

The effective exocrine pancreatic secretion is the key factor in pancreatic fistula formation. The limitation of pancreatic secretion creates the desired conditions for fistula treatment and therefore is the key to PF therapy. Oral nutrition is restricted, followed by parenteral nutrition, aided with drugs like somatostatin and its analogues, reducing the exocrine secretion of the organ. The first successful use of somatostatin in the prevention of pancreatic fistulas dates back to the year 1979 [1,6,7].

Somatostatin is secreted in the central nervous system and the gastrointestinal tract (70%). This hormone inhibits the secretion of gastrin, secretin, vasoactive intestinal peptide and pancreatic enzymes as well as reducing both peristaltic intestine activity and gastric emptying. All of the above-mentioned results of somatostatin activity create a favourable environment for pancreatic fistula closure. Thanks to the inhibition of pepsin and hydrochloric acid production, somatostatin also plays a well-established role in the prevention and directed treatment of upper gastrointestinal bleeding caused by esophageal varices, gastric and duodenal ulcers. However, the most valuable effect of somatostatin infusion in these cases is the instant (a few minutes after administration) reduction of portal vein pressure and mesenteric circulation [8,9,10]. The recommended pancreatic fistula therapy includes a continuous intravenous somatostatin infusion of 6mg/24h until complete fistula closure, followed by a 50% reduction in the infusion to 3mg/24h for the next 48 hours in order to avoid a rebound effect. The only proper way to administer somatostatin is continuous infusion, because of its short, three-minute half-life. Patients with advanced kidney failure require lower doses, whereas liver failure does not affect somatostatin dosage.

The latest research on somatostatin therapy confirms its positive impact on pancreatic fistula treatment and prevention after pancreatic surgery. At the same time, a similar effect with the analogue of somatostatin – octreotide - is being questioned in terms of successful fistula treatment [1]. Parenteral nutrition is also an essential part of proper initial pancreatic

fistula therapy, although more detailed information on the subject is beyond the scope of this article.

The case report presented is a good example of POPF treatment with the use of somatostatin. Clinical awareness after surgery of the stromal tumor in direct contact with pancreatic tissues in connection with routine amylase level assessment led to a quick diagnosis of the pancreatic fistula and the therapy led to uneventful outcome.

This case report was approved by the local ethics committee, and written consent was obtained from the patient for the publication of this case report and any accompanying images. Written informed consent in Polish was obtained from the patient for the publication of this case report and any accompanying images.

Conflict of interest: None declared.

Paper accepted

REFERENCES

1. Anderson R, Dunki-Jacobs E, Burnett N, Scoggins C, McMasters K, Martin RC. A cost analysis of somatostatin use in the prevention of pancreatic fistula after pancreatectomy. *World J Surg.* 2014 Aug;38(8):2138-44. DOI: 10.1007/s00268-014-2512-4 PMID: 24663483
2. Bassi C, Dervenis C, Butturini G, Fingerhut A, Yeo C, Izbicki J, Neoptolemos J, Sarr M, Traverso W, Buchler M. Postoperative pancreatic fistula: An international study group (ISGPF) definition. *Surgery* 2005; 138(1): 8-13. PMID: 16003309 DOI: <https://doi.org/10.1016/j.surg.2005.05.001>
3. Matrella E, Valatas V, Notas G, Roumpaki H, Xidakis C, Hadzidakis A, Mouzas I, Kouroumalis E. Bolus somatostatin but not octreotide reduces hepatic sinusoidal pressure by a NO-independent mechanism in chronic liver disease. *Aliment Pharmacol Ther.* 2001;15(6):857-864. DOI: 10.1046/j.1365-2036.2001.00996.x
4. de Franchis R, Baveno VI Faculty. Expanding consensus in portal hypertension. Report of the Baveno VI Consensus Workshop: Stratifying risk and individualizing care for portal hypertension. *J Hepatol.* 2015;63(3):743-52. PMID: 26047908 DOI: 10.1016/j.jhep.2015.05.022
5. Gurusamy KS, Koti R, Fusai G, Davidson BR. Somatostatin analogues for pancreatic surgery. *Cochrane Database Syst Rev.* 2013;(4):CD008370 PMID: 23633353 DOI: 10.1002/14651858.CD008370.pub3
6. Jin K, Zhou H, Zhang J, Wang W, Sun Y, Ruan C, Hu Z, Wang Y. Systematic review and meta-analysis of somatostatin analogues in the prevention of postoperative complication after pancreaticoduodenectomy. *Dig Surg.* 2015; 32(3):196-207. PMID: 25872003 DOI: 10.1159/000381032
7. Palani Velu LK, Chandrabalan VV, Jabbar S, McMillan DC, McKay CJ, Carter CR, Jamieson NB, Dickson EJ. Serum amylase on the night of surgery predicts clinically significant pancreatic fistula after pancreaticoduodenectomy. *HPB (Oxford).* 2014; 16: 610–619. PMID: PMC4105898 doi: 10.1111/hpb.12184
8. Molinari E, Bassi C, Salvia R, Butturini G, Crippa S, Talamini G, Falconi M, Pederzoli P. Amylase Value in Drains After Pancreatic Resection as Predictive Factor of Postoperative Pancreatic Fistula. *Ann Surg.* 2007; 246(2): 281–287. PMID: PMC1933557 doi: 10.1097/SLA.0b013e3180caa42f
9. Katsourakis A, Oikonomou L, Chatzitheoklitos E, Noussios G, Pitiakoudis M, Polychronidis A, Simopoulos K, Sioga A. The role of somatostatin in 67 consecutive pancreatectomies: a randomized clinical trial. *Clin Exp Gastroenterol.* 2010;3(1):179-83. PMID: 21694864 DOI: 10.2147/CEG.S13984
10. Klempa I, Schwedes U, Usadel KH: [Prevention of postoperative pancreatic complications following duodenopancreatectomy using somatostatin]. *Der Chirurg.* 1979; 50(7): 427–431. PMID:477469

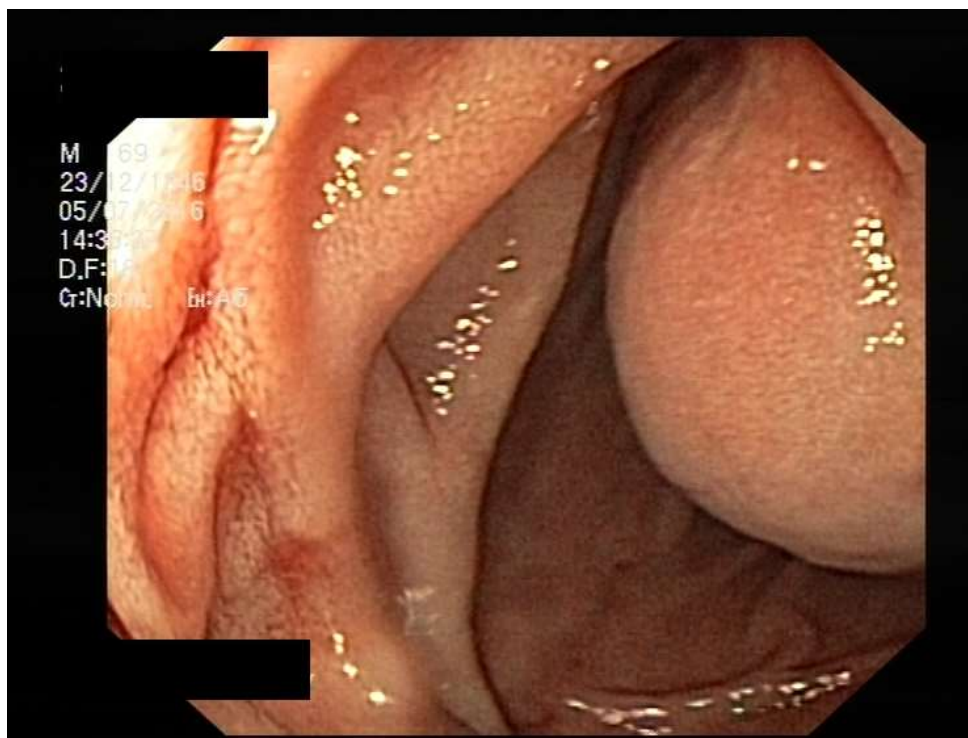


Figure 1. Upper gastrointestinal endoscopy shows the firm duodenal GIST-like tumor at the Vater's papilla

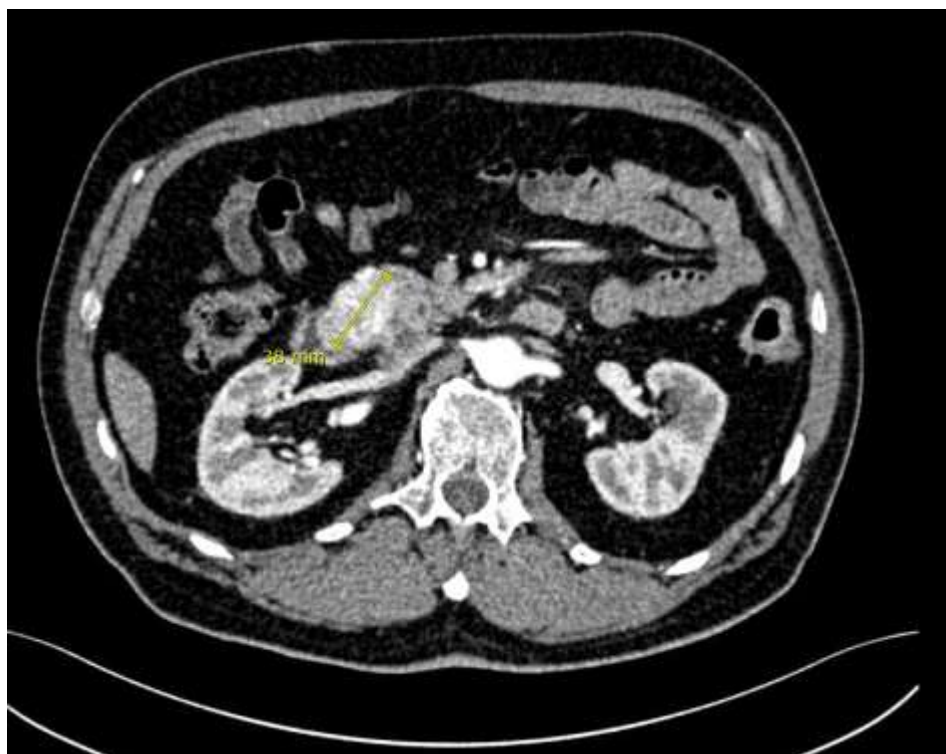

Figure 2. Abdominal computed tomography scan shows the tumor measuring 38 mm with uneven margins with possible infiltration of the pancreas

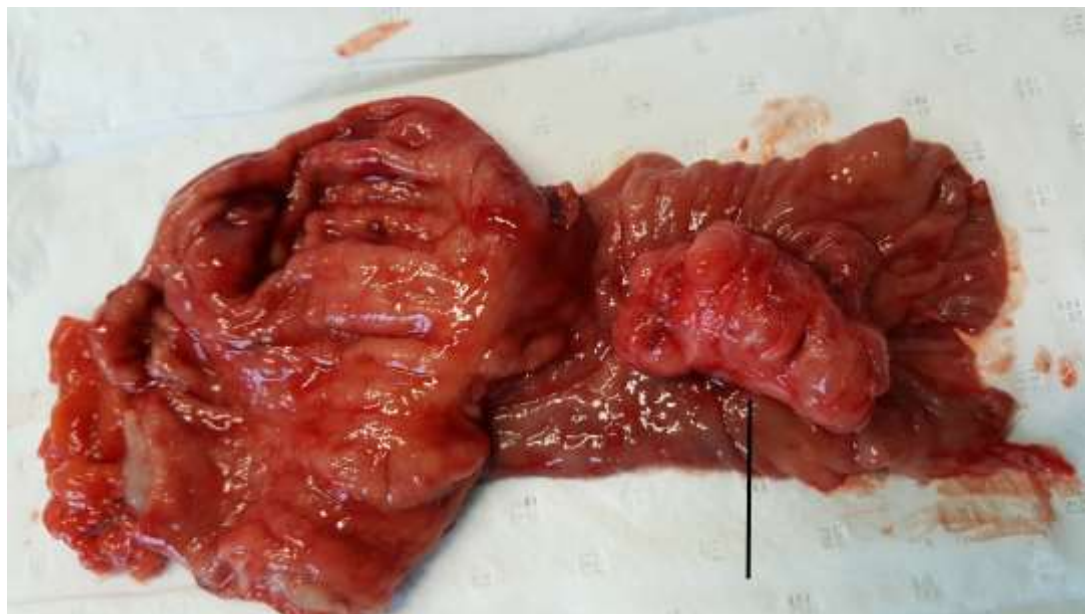

Figure 3. Postoperative view. The arrow shows the excised specimen with GIST tumor

Paper accepted