



СРПСКИ АРХИВ
ЗА ЦЕЛОКУПНО ЛЕКАРСТВО
SERBIAN ARCHIVES
OF MEDICINE

Address: 1 Kraljice Natalije Street, Belgrade 11000, Serbia

+381 11 4092 776, Fax: +381 11 3348 653

E-mail: office@srpskiarhiv.rs, Web address: www.srpskiarhiv.rs

Paper Accepted*

ISSN Online 2406-0895

Case Report / Приказ болесника

Aleksandar R. Karamarković^{1,2}, Jovan T. Juloski^{1,2,*}, Vladica V. Ćuk^{1,2}, Jovana M. Bojičić¹,
Nemanja A. Karamarković³, Vladimir R. Cijan¹

**Penetrating and blunt injuries of the heart –
an abdominal surgeon’s personal experience in Serbia**

Пенетрантне и тупе повреде срца –
лична искуства абдоминалног хирурга у Србији

¹Zvezdara University Clinical Center, Nikola Spasić Surgical Clinic, Belgrade, Serbia;

²University of Belgrade, Faculty of Medicine, Belgrade, Serbia;

³Clinical Center Serbia, Cardiosurgery Clinic, Belgrade, Serbia

Received: December 31, 2020

Accepted: June 7, 2021

Online First: June 21, 2021

DOI: <https://doi.org/10.2298/SARH201231052K>

***Accepted papers** are articles in press that have gone through due peer review process and have been accepted for publication by the Editorial Board of the *Serbian Archives of Medicine*. They have not yet been copy-edited and/or formatted in the publication house style, and the text may be changed before the final publication.

Although accepted papers do not yet have all the accompanying bibliographic details available, they can already be cited using the year of online publication and the DOI, as follows: the author’s last name and initial of the first name, article title, journal title, online first publication month and year, and the DOI; e.g.: Petrović P, Jovanović J. The title of the article. *Srp Arh Celok Lek*. Online First, February 2017.

When the final article is assigned to volumes/issues of the journal, the Article in Press version will be removed and the final version will appear in the associated published volumes/issues of the journal. The date the article was made available online first will be carried over.

***Correspondence to:**

Jovan JULOSKI

Nikola Spasić Surgical Clinic, Zvezdara University Clinical Center, Dimitrija Tucovica 161, 11000 Belgrade, Serbia

E-mail: jovan.juloski@gmail.com

Penetrating and blunt injuries of the heart – an abdominal surgeon's personal experience in Serbia

Пенетрантне и тупе повреде срца – лична искуства абдоминалног хирурга у Србији

SUMMARY

Introduction In the world with constantly increasing incidence of violence and trauma on one side, and more and more specialized surgeons on the other side; question about the role of abdominal surgeons in cardiac trauma emerges. Objective of this article is to show personal experience of an abdominal surgeon in managing heart trauma.

Outlines of cases We showed two penetrating injuries and one blunt trauma of the heart successfully managed by an abdominal surgeon.

Conclusion Abdominal surgeons should feel comfortable with the decision to operate on greatly physiologically deranged patients with penetrating chest trauma, and not to delay the operation with conservative measures or with time consuming transport to remote specialized facilities, since that could lead to greater death percentage of these patients.

Keywords: heart trauma; penetrating wound; abdominal surgeon

САЖЕТАК

Увод У свету у ком се стално повећава инциденца насиља и повреда са једне стране, а хирурзи се едукују за све уже хириршке гране; поставља се питање о улози абдоминалних хирурга у кардијалној траума. Циљ овог рада је да прикаже лична искуства абдоминалног хирурга у решавању повреда срца.

Прикази болесника: Приказана су два случаја пенетранте повреда срца и једна тупа повреда срца, која су успешно решена од стране абдоминалног хирурга.

Закључак: Абдоминални хирурзи би требали да се слободно упусте у операцију нхемодинамски нестабилних пацијената са пенетрантним повредама грудног коша. Не треба да одлажу операцију спровођењем конзервативних мера или транспортовањем у удаљене специјализоване центре, јер то може довести до веће смртности ових пацијената.

Кључне речи: повреде срца; пенетрантне повреде; абдоминални хирург

INTRODUCTION

Traumatic injuries are the leading cause of death among people younger than 45 years [1, 2]. Right after injuries of the brain and spinal cord, cardiac injuries are the second most common cause of lethal outcome of trauma victims [2].

Heart can be injured in two possible manners, by non-penetrating/blunt trauma (BCI) and penetrating trauma [3, 4].

Trauma caused from blunt forces can have a wide clinical presentation, from practically silent presentation or transient arrhythmias to fatal cardiac rupture [5, 6], with the latter as the most common cause of death in 64% of BCI cases, followed by tears at the venous-atrial confluence (33%) and dissection of coronary arteries (2%) [7]. The most common site of myocardial rupture is the wall of right ventricle, usually immediately fatal. In those who

survive long enough to reach to the hospital can present with cardiac tamponade or pseudoaneurysm [8, 9].

One of the most lethal medical emergencies is certainly penetrating injuries of the heart [10]. Estimations are that almost 94% of injured die before reaching the hospital [10]; reports about in-hospital death rate varies from 8.5% to 50% or even more [10–12]. The range of mortality in these reports can be explained by patient inclusion criteria, variety of conjoined injuries and mechanism of the occurrence. As in blunt cardiac injuries, also in penetrating injuries, right ventricle is the most common site of injury [2, 10], but with similar percentage of injury for both ventricle [10]. Cardiac tamponade is the common manifestation in initial survivors, who are usually young males, with stab/gunshot wound of the chest [3].

Objective of this article is to show personal experience of an abdominal surgeon in managing heart trauma.

Surgery of wounded heart: the beginnings.

First steps in cardio surgery were made in trauma, as lifesaving procedures [13, 14]. First attempt to suture a human heart was performed by Norwegian doctor Axel Hermansen Cappelen in 1895. The patient was a young male with a stab wound to the left ventricle. After initial improvement, patient died on the third postoperative day [15]. The first successful suture of the heart is considered to be the one performed by Ludwig Rehn on September 9th, 1896 in Frankfurt am Mein. He operated on a 22-year-old male with a stab wound to the right ventricle. As a peculiarity, the unfortunate patient got stabbed two days earlier, and Rehn operated after returning from a journey. After the procedure, the patient completely recovered [16]. First successful suture of the left ventricle that is describes in literature, was done in Rome, Italy, by Antonio Parrozzani on April 18th 1897. The patient was also a young male with a stab wound to the left side of the chest. After a 75 min long operation, the man recovered completely [17]. First large series of successfully managed heart wounds was published by Dwight Harken, American war surgeon [14, 15].

First steps in Serbia

The first successful operation of a wounded heart in Serbia was performed in 1928 by Jovan Mijuskovic, in the city of Valjevo [14, 18]. The patient was a 15-year-old male with a gunshot wound to the right ventricle. The operation was performed in local anesthesia, and lasted for only 35 minutes as the author described. The postoperative period was long and with numerous complications, but eventually the boy was discharged in good condition [18]. This operation was the very first step in surgery of the heart, decades before cardiac surgery even emerged as a separate field, in former Kingdom of Yugoslavia, now Serbia. Jovan Mijuskovic (1886–1944) studied medicine in Vienna, and conducted his surgery residency in Vienna and Belgrade. He was chief of surgery in cities of Cuprija and Valjevo. In 1936 he was appointed as a professor for subject History of medicine, at Faculty of Medicine, University of Belgrade. During his career, he published numerous papers in domestic and foreign scientific Journals [14]. Briefly he was Minister of health during World War II. In 1942 he founded Department of surgery in “City hospital of Belgrade”, currently Surgical Clinic “Nikola Spasic”, “Zvezdara” University Clinical Center in Belgrade [14]. In this institution, in which some of the authors of this paper practice surgery, one of the cases was managed.

The role of general surgeons in heart trauma, in the era of modern cardiac surgery

Several authors published results of specialized centers in managing heart wounds, combining interventional, radiologic and also surgical approach [19–22]. It is obvious that diagnosis that is made swiftly and very early, with an organized and available heart team (interventional cardiologists, radiologists and cardiac surgeons), which are available in specialized centers, provide favorable results [4, 22]. In some parts of the world, where trauma and cardiothoracic surgeons are not easily available, penetrating thoracic trauma is becoming more frequent, also the need for thoracotomy [10, 23]. It is also worth mentioning that general surgeons and general surgery residents are becoming more specialized by the day, and less “adventurous” when it comes to operating beyond their area of specialization [24]. Fear of being sued in case of failure, is the most frequent reason for referring chest

trauma to more specialized centers and staff [24]. In recent years some authors published results with intent to encourage general surgeons to engage in cardiac trauma [24], and emergency thoracotomy in general [24, 25]. Doll and colleagues in their work stated, that in all cardiac wounds they applied a simple direct suture of the heart wall, highlighting that there was no need for an expertise of a cardiac surgeon nor extracorporeal circulation. They speculated that patients with complicated injuries which would require bypass of the heart would most likely die before reaching the hospital. It is their strong opinion that, apart from mediastinal vessels and esophageal injuries, great majority of penetrating thoracic trauma can be managed with simple operative techniques. They concluded that general surgeons should feel comfortable with the decision to operate on greatly physiologically deranged patients with penetrating chest trauma, and not to delay the operation with conservative measures or with time consuming transport to remote specialized facilities, since that could lead to greater death percentage of these patients [24].

REPORTS OF CASES

Case 1

A young 23-old patient was immediately admitted to Clinic of Emergency surgery, Clinical Center of Serbia in Belgrade for suicide attempt, stabbed in the epigastrium. He was hemodynamically unstable with clinical signs of hemorrhagic shock. The emergency operation was performed. Abdominal cavity was opened by medial laparotomy, intraoperatively verified penetrating injuries of the liver left lobe, the diaphragm and the diaphragmatic side of the left heart ventricle. Furthermore, left ventricle penetrating hole was sewn by trans diaphragmatic approach with several interrupted stiches preserving left coronary artery (Figure 1, and Figure 2.). Then, the diaphragm was reconstructed and sutured left lobe of the liver.

Postoperative period was regular and the psychiatrist has been consulted. The hospital discharged was made on the tenth postoperative day. Patient was in good condition.

Case 2

A 75-year-old man with blunt thorax injuries, was hospitalized in Clinic of Emergency surgery, Clinical Center of Serbia in Belgrade, due to a fall from a height of approximately 2.5 m. In that case, there were the fractures of the V-VIII ribs and consequential hemopneumothorax. Firstly, the thoracic tube was placed through the second intercostal space rightward on the medio clavicular line. Initially, air and blood appeared on the tube, achieved the lung re-expansion and blood control.

The next day, massive hemothorax was performed and the patient underwent by emergency surgery.

Right posterolateral thoracotomy was performed through the fifth intercostal space. Intraoperatively verified hemothorax and laceration of the right atrium auricle as a consequence of previous adhesions following acceleration-deceleration injuries. A vascular clamp was placed under laceration and auricle sutured continuously (Figure 3. and Figure 4.).

The postoperative period was regular. The hospital discharged was made on the twelfth postoperative day. Patient was in relatively good condition.

Case 3

A young 17-year-old patient was found lying down on the street, in the close proximity to the Surgical Clinic "Nikola Spasic", with a penetrating wound through the left side of the chest, close to the sternum. According to eyewitness, no more than 10 minutes passed since the stabbing, by an unknown perpetrator, occurred. He was immediately admitted in intensive care unit, hemodynamically unstable and somnolent with hemoglobin values of 10.7g/dl and hematocrit 31.5%. Inotropes were administered along with massive fluid resuscitation, two units of fresh frozen plasma and two units of erythrocytes. A stab wound through the chest wall at the intersection of the fifth intercostal space and left midclavicular line was identified with moderate active bleeding. Immediately after the admission to the ICU, chest X ray revealed massive hemothorax, and a chest tube was inserted through the wound. After a short

period of observation, the tube evacuated total amount of 1500 l of blood, sudden drop in hemoglobin values to 4.9 g/dl, and hematocrit to 14.5% occurred. He was promptly transferred to the OR, with continuous norepinephrine and dopamine IV drip; two additional units of fresh frozen plasma and three units of blood were administered and also one unit of cryoprecipitate. Left hemithorax was opened via anterolateral thoracotomy through fifth intercostal space. A stab wound through the full thickness of left ventricle wall was identified, with the breach of endocardium and synchronous, pulsatile bleeding. The myocardial wound was approximately 4cm long, with much wider pericardial laceration. Also, left internal thoracic artery was incompletely transected, with lesion of the sternum at the same level and hemothorax and hemopericardium were present. Other intrathoracic and mediastinal organs were intact. The myocardium was closed with interrupted sutures with prolene 2.0 and 3.0., pericardium was sutured in same fashion with narrow drain inserted in the pericardial space (Figure 5.). Internal thoracic artery was suture ligated, and after thorough rinsing of the hemothorax and chest tube placements, the chest wall was closed. Postoperatively, regular transthoracic echocardiographs were performed on five occasions, with no rhythm or hemodynamic irregularities. Second postoperative day he was extubated. Due to renal impairment caused by massive blood loss, nephrologist was called into consult twice, but significant therapeutic changes and dialysis were not necessary. On the third postoperative day, due to right pleural effusion a pleural puncture and fluid evacuation was performed (Figures 5. and 7.). All drains and tubes were gradually pulled out. The patient received total amount 11 units of blood, 10 units of fresh frozen plasma, 1 unit of thrombocytes and 6 units of cryoprecipitate. Patient spent 7 days in the ICU and 4 more days in semi-ICU ward, and was finally discharged on the 12th postoperative day in good condition.

DISCUSSION

The incidence of cardiac injuries has risen in the past few decades several times. In civilian settings, most penetrating injuries are stab wounds, with increasing percentage of fire arm lesions [24, 26]. Already recognizes as one of the most lethal medical emergencies [10], penetrating heart injuries have an in-hospital death rate, as said earlier in this paper, from

8.5% to 50% or even more [10, 11, 12]. We had the fortune to see all three of our patients successfully discharged alive

“The Quadrangle of Death” is the most frequent localization of cardiac injuries on the chest wall. It goes above the diaphragm, under the clavicles and medial to the nipples. Previous authors reported that one chamber injury makes 70%, and multiple chamber injury accounts for 30% [27]. This complies with our small series, in which all three patients had one chamber injury, two left ventricle injuries and one right atrium auricle injury. According to previous findings, in penetrating injuries, both ventricles are affected with similar frequency [2], but with the right ventricle as more common site of the entry, since it forms most of the anterior surface of the heart. In only three cases, 66.66% were injuries of left ventricle, and 33.33%.

At least one of the three symptoms of Beck’s trinity (Hypotension, elevated CVP, dull heart murmurs) is present in penetrating heart injuries [4]. One must have in mind that tension pneumothorax, also a chest injury, can mimic all of these symptoms, but with auscultatory silence on the affected side. Full preoperative diagnostics can only be conducted in hemodynamically stable patients [4]. On the other hand, when we face with massive bleeding, cardiac tamponade, parasternal wounds, unstable patients in general, immediate thoracotomy, without detailed diagnostics, is mandatory [4, 24]. Echocardiography, if allowed by hemodynamic stability, is very useful in detecting trauma of the heart [28]. One of very informative, but time consuming, diagnostic procedure, heart catheterization is, by some authors, not necessary in the initial phase of diagnostic [4], but is very important in solving complex injuries [22], and practically mandatory in post-surgical phase, in order to exclude secondary complications [22], which can be expected in up to 10% of cases [4].

Swift and precise diagnosis, reanimation, expeditious transport and timely surgical intervention are of utmost importance in managing cardiac injuries. Equipped centers and specialized cardiac teams are certainly ideal for injured patients. But, even in the era of more and more specialized branches in medicine and surgery, role of abdominal surgeons in cardiac trauma is still important. Apart from mediastinal vessels and esophageal injuries, great majority of penetrating thoracic trauma can be managed with simple operative techniques. Abdominal surgeons should feel comfortable with the decision to operate on greatly physiologically deranged patients with penetrating chest trauma, and not to delay the

operation with conservative measures or with time consuming transport to remote specialized facilities, since that could lead to greater death percentage of these patients.

ACKNOWLEDGMENT

We would like to express our appreciation to prof. Dušan Velimirović, whose tremendous knowledge has helped greatly in writing this paper, and whose knowledge and skills will always represent one of the cornerstones of Serbian cardiac surgery.

Ethical standards: Written consent for publication of this article has been obtained by the patients or the patients' family members.

Conflict of interest: None declared.

REFERENCES

1. Yousef R, Carr JA. Blunt cardiac trauma: a review of the current knowledge and management. *Ann Thorac Surg.* 2014;98(3):1134–40. doi: 10.1016/j.athoracsur.2014.04.043. PMID: 25069684.
2. Restrepo CS, Gutierrez FR, Marmol-Velez JA, Ocazonez D, Martinez-Jimenez S. Imaging patients with cardiac trauma. *Radiographics.* 2012;32(3):633–49. doi: 10.1148/rg.323115123. PMID: 22582351.
3. Leite L, Gonçalves L, Nuno Vieira D. Cardiac injuries caused by trauma: Review and case reports. *J Forensic Leg Med.* 2017;52:30–4. doi: 10.1016/j.jflm.2017.08.013. PMID: 28850860
4. Velinovic M, Velimirovic D, Vranes M, Djukic P, Mikic A, Putnik S, et al. Heart Injuries - Still a Challenge for Cardiac Surgery. *The Open Cardiovascular and Thoracic Surgery Journal.* 2009;2:38–42. doi: 10.2174/1876533500902010038.
5. Bellister SA, Dennis BM, Guillaumondegui OD. Blunt and Penetrating Cardiac Trauma. *Surg Clin North Am.* 2017;97(5):1065–76. doi: 10.1016/j.suc.2017.06.012. PMID: 28958358.
6. Singh S, Angus LD. Blunt Cardiac Injury. *StatPearls.* Treasure Island (FL): StatPearls Publishing Copyright © 2020, StatPearls Publishing LLC.; 2020.
7. Turan AA, Karayel FA, Akyildiz E, Pakis I, Uzun I, Gurpinar K, et al. Cardiac injuries caused by blunt trauma: an autopsy based assessment of the injury pattern. *J Forensic Sci.* 2010;55(1):82–4. doi: 10.1111/j.1556-4029.2009.01207.x. PMID: 19895542.
8. El-Chami MF, Nicholson W, Helmy T. Blunt cardiac trauma. *J Emerg Med.* 2008;35(2):127–33. doi: 10.1016/j.jemermed.2007.03.018. PMID: 17976783.
9. Helmy TA, Nicholson WJ, Lick S, Uretsky BF. Contained myocardial rupture: a variant linking complete and incomplete rupture. *Heart.* 2005;91(2):e13. DOI: 10.1136/hrt.2004.048082. PMID: 15657203.
10. Campbell NC, Thomson SR, Muckart DJ, Meumann CM, Van Middelkoop I, Botha JB. Review of 1198 cases of penetrating cardiac trauma. *Br J Surg.* 1997;84(12):1737–40. PMID: 9448629.
11. Isaza-Restrepo A, Bolívar-Sáenz DJ, Tarazona-Lara M, Tovar JR. Penetrating cardiac trauma: analysis of 240 cases from a hospital in Bogota, Colombia. *World J Emerg Surg.* 2017 Jun 12;12:26. doi: 10.1186/s13017-017-0138-1. PMID: 28616061.
12. Rahim Khan HA, Gilani JA, Pervez MB, Hashmi S, Hasan S. Penetrating cardiac trauma: A retrospective case series from Karachi. *J Pak Med Assoc.* 2018 Aug;68(8):1285–1287. PMID: 30108408.
13. Alexi-Meskishvili V, Böttcher W. Suturing of penetrating wounds to the heart in the nineteenth century: the beginnings of heart surgery. *Ann Thorac Surg.* 2011;92(5):1926–31. doi: 10.1016/j.athoracsur.2011.07.056. PMID: 22051302
14. Velimirović D. dr Jovan Mijušković, precursor of cardiac surgery in Serbia. *Srp Arh Celok Lek.* 2020;148(1–2):124–8. doi: <https://doi.org/10.2298/SARH181228128V>.
15. Alivizatos PA. Dwight Emary Harken, MD, an all-American surgical giant: Pioneer cardiac surgeon, teacher, mentor. *Proc (Bayl Univ Med Cent).* 2018;31(4):554–7. doi: 10.1080/08998280.2018.1471896. PMID: 30949011.
16. Rehn L. Ueber penetrirende Herzwunden und Herznaht. *Archiv für klinische Chirurgie.* 1897;55:315–29.
17. Parrozzani A. I primi due casi di sutura del ventricolo sinistro. *uletino della Reale Accademia Medica Di Roma.* 1897;22:243–60.
18. Mijuskovic J. Jedan uspeo sav na srcu. *Srp Arh Celok Lek.* 1928;12:963–73.
19. Shioya N, Inoue N, Muto H, Tomita A, Tsukamoto Y, Kawashima N, Hazama K, Shichinohe Y. Delayed diagnosis of traumatic ventricular septal perforation in penetrating chest injury: hematoma formation in the ventricular septum in CT suggests perforation. *Acute Med Surg.* 2019 Apr 25;6(3):321–324. doi: 10.1002/ams2.419. PMID: 31304038.
20. Pracon R, Grygoruk R, Konka M, Kepka C, Demkow M. Percutaneous Closure of Ventricular Septal Defect Resulting From Chest Stab Wound in an 18-Year-Old Boy. *Circ Cardiovasc Imaging.* 2018 Nov;11(11):e008326. doi: 10.1161/CIRCIMAGING.118.008326. PMID: 30571322.
21. Han FY, Reyes KG, Bleiweis MS. Managing extensive mitral valve and ventricular septal injuries secondary to penetrating trauma. *Eur J Cardiothorac Surg.* 2018 Jan 1;53(1):284–285. doi: 10.1093/ejcts/ezx298. PMID: 28958060.
22. Cottini M, Pergolini A, Ranocchi F, Musumeci F. The Role of Heart Team Approach in Penetrating Cardiac Trauma: Case Report and Review of the Literature. *Braz J Cardiovasc Surg.* 2018;33(1):99–103. doi: 10.21470/1678-9741-2017-0150. PMID: 29617508.
23. Van Vledder MG, Van Waes OJF, Kooij FO, Peters JH, Van Lieshout EMM, Verhofstad MHJ. Out of hospital thoracotomy for cardiac arrest after penetrating thoracic trauma. *Injury.* 2017 Sep;48(9):1865–1869. doi: 10.1016/j.injury.2017.04.002. PMID: 28442204.
24. Doll D, Eichler M, Vassiliu P, Boffard K, Pohlemann T, Degiannis E. Penetrating Thoracic Trauma Patients with Gross Physiological Derangement: A Responsibility for the General Surgeon in the Absence of Trauma

- or Cardiothoracic Surgeon? *World J Surg.* 2017;41(1):170–5. doi: 10.1007/s00268-016-3703-y. PMID: 27553197.
25. Yoong IRW, Heng G, Mathur S, Lim WW, Goo TT. Outcomes of emergency thoracotomy for trauma in a general hospital in Singapore. *Asian Cardiovasc Thorac Ann.* 2018;26(4):285–9. doi: 10.1177/0218492318772221. PMID: 29667900
 26. Rashid MA, Wikström T, Ortenwall P. Cardiac injuries: a ten-year experience. *Eur J Surg.* 2000;166(1):18–21. doi: 10.1080/110241500750009645. PMID: 10688211.
 27. Takagi H, Mori Y, Murase K, Hirose H. Nail gun penetrating cardiac injury. *Eur J Cardiothorac Surg.* 2003;23(5):841. doi: 10.1016/s1010-7940(03)00071-x. PMID: 12754044.
 28. Saranteas T, Mavrogenis AF, Mandila C, Poularas J, Panou F. Ultrasound in cardiac trauma. *J Crit Care.* 2017 Apr;38:144–151. doi: 10.1016/j.jcrc.2016.10.032. PMID: 27907878.

Paper accepted

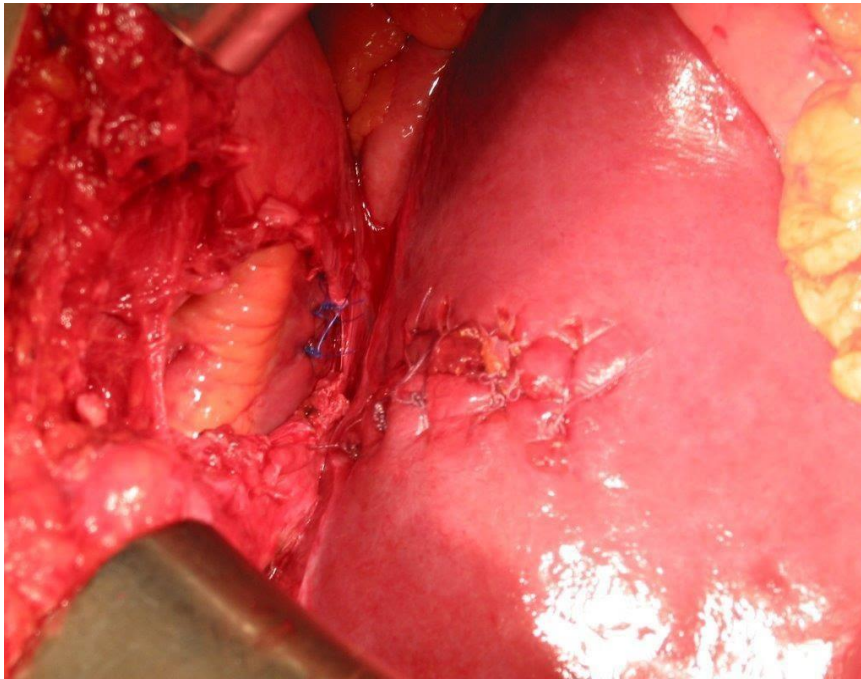


Figure 1. Case 1, transabdominal view of the sutured heart, sutured liver and the rupture point of the of the diaphragm

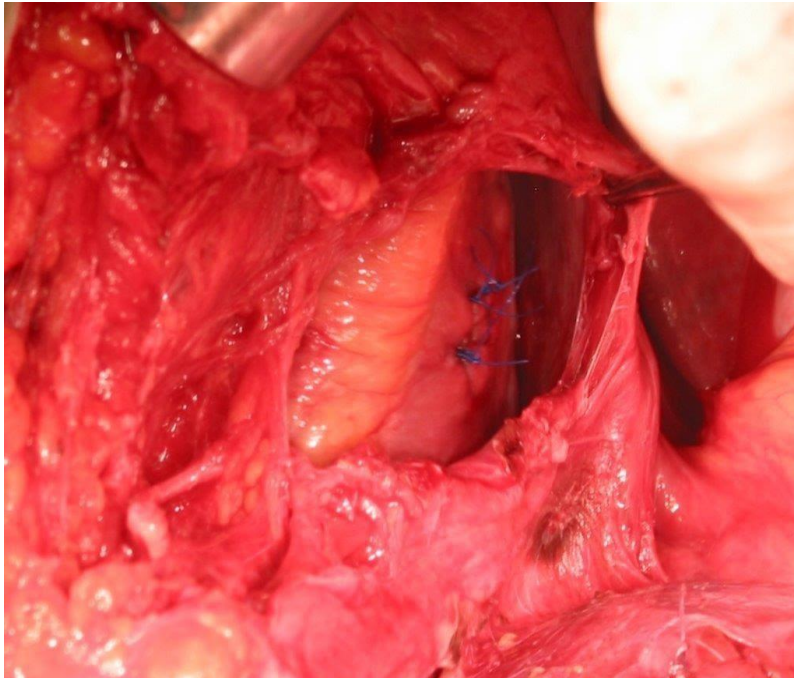


Figure 2. Case 1, view of the sutured heart as seen transabdominally through the ruptured diaphragm

Paper accepted

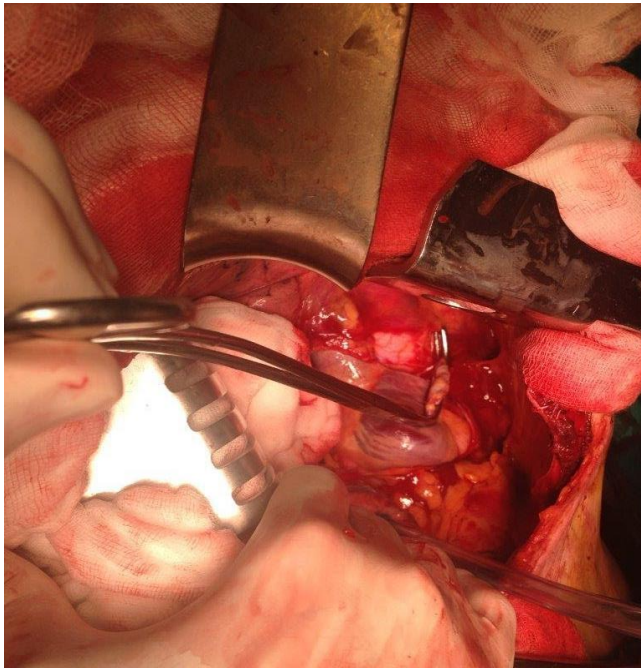


Figure 3. Case 2, clamped auricle of the right atrium of the heart

Paper accepted

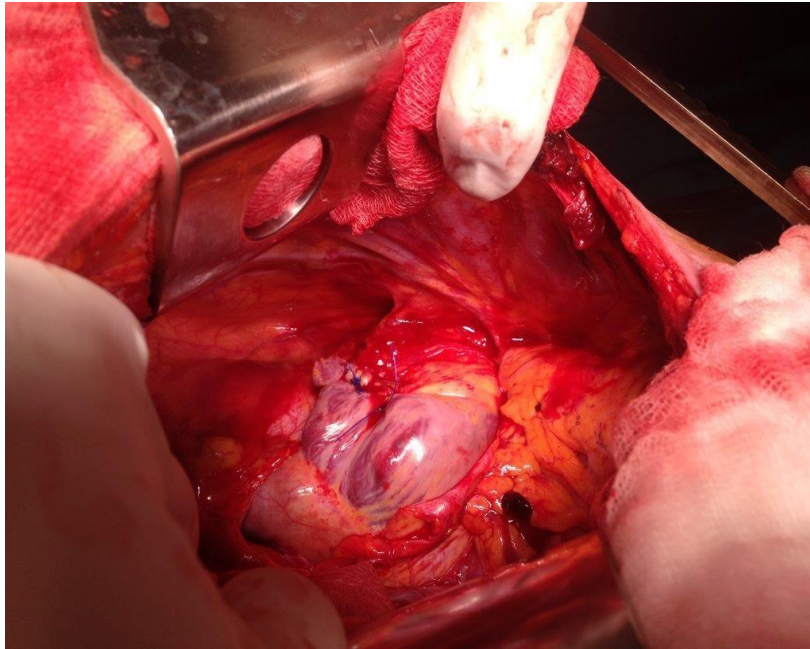


Figure 4. Case 2, sutured auricle of the right atrium of the heart

Paper accepted

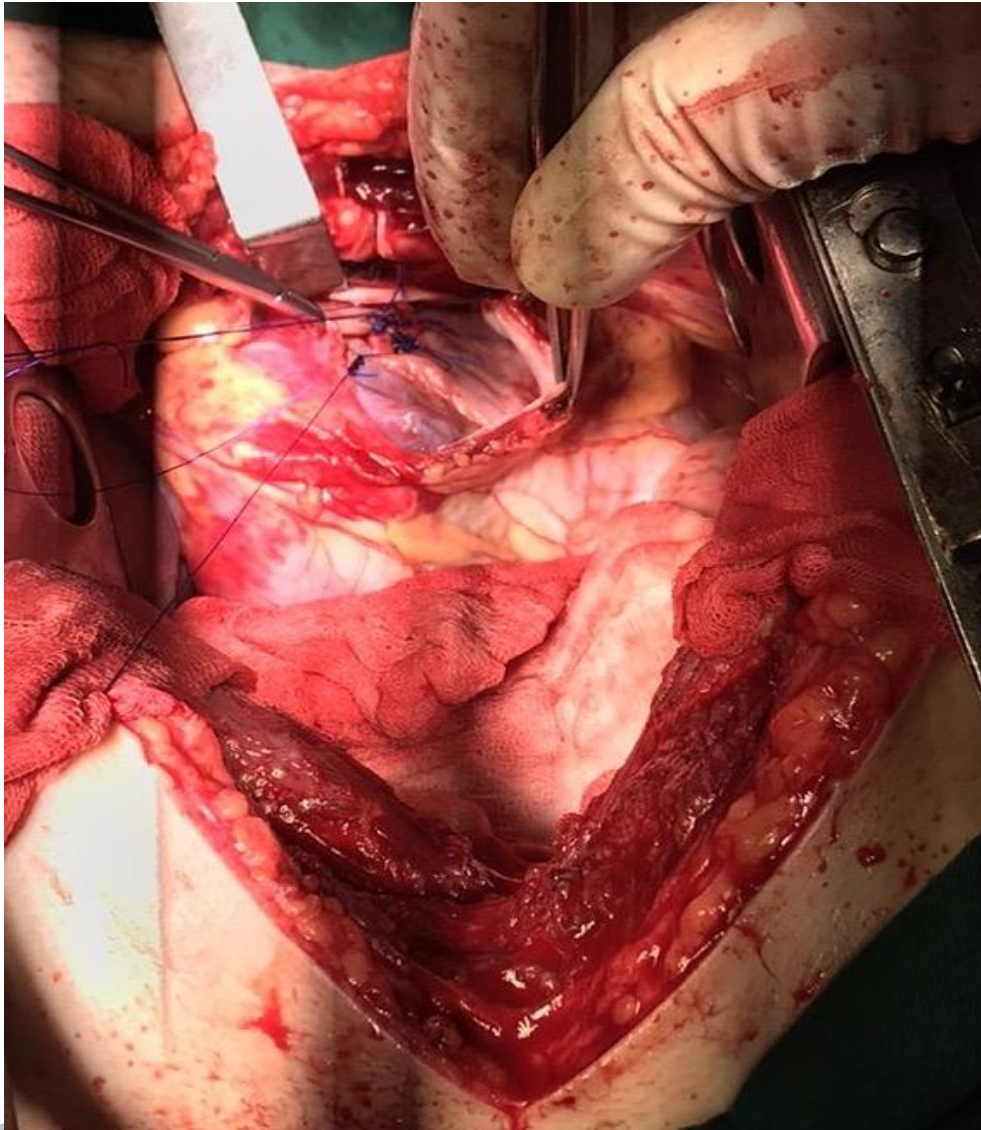


Figure 5. Case 3, interrupted sutures on myocardium of the left ventricle

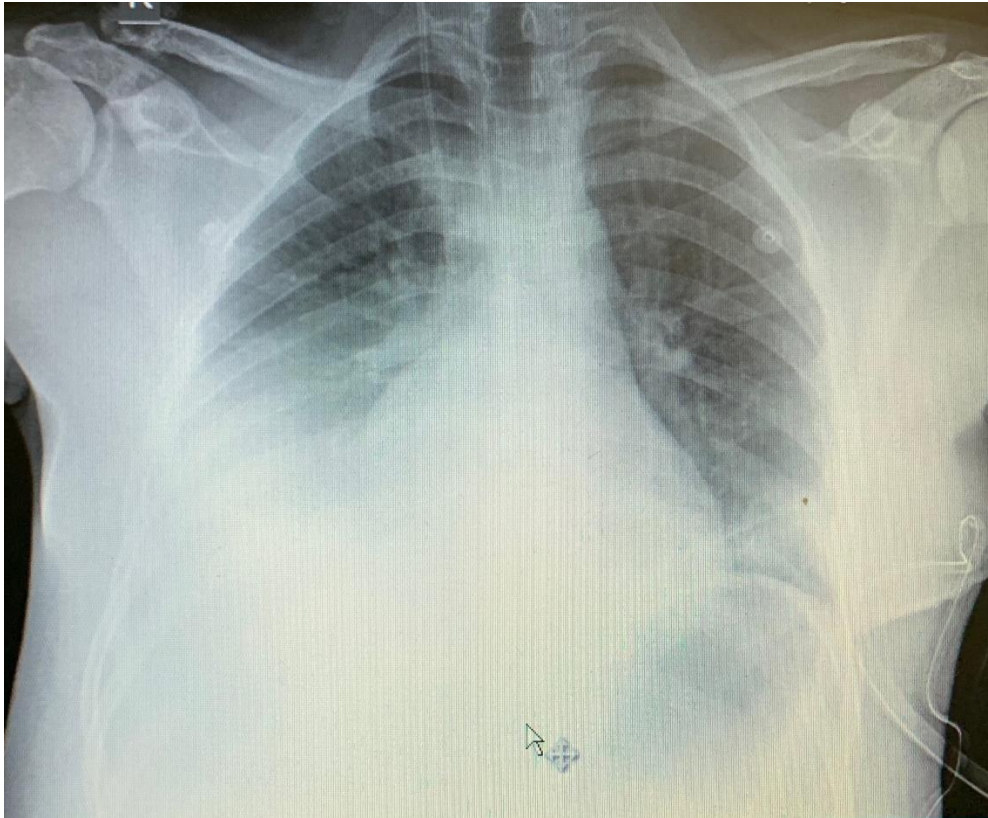


Figure 6. Case 3, chest X-ray before pleural puncture on the right side due to pleural effusion, third postoperative day

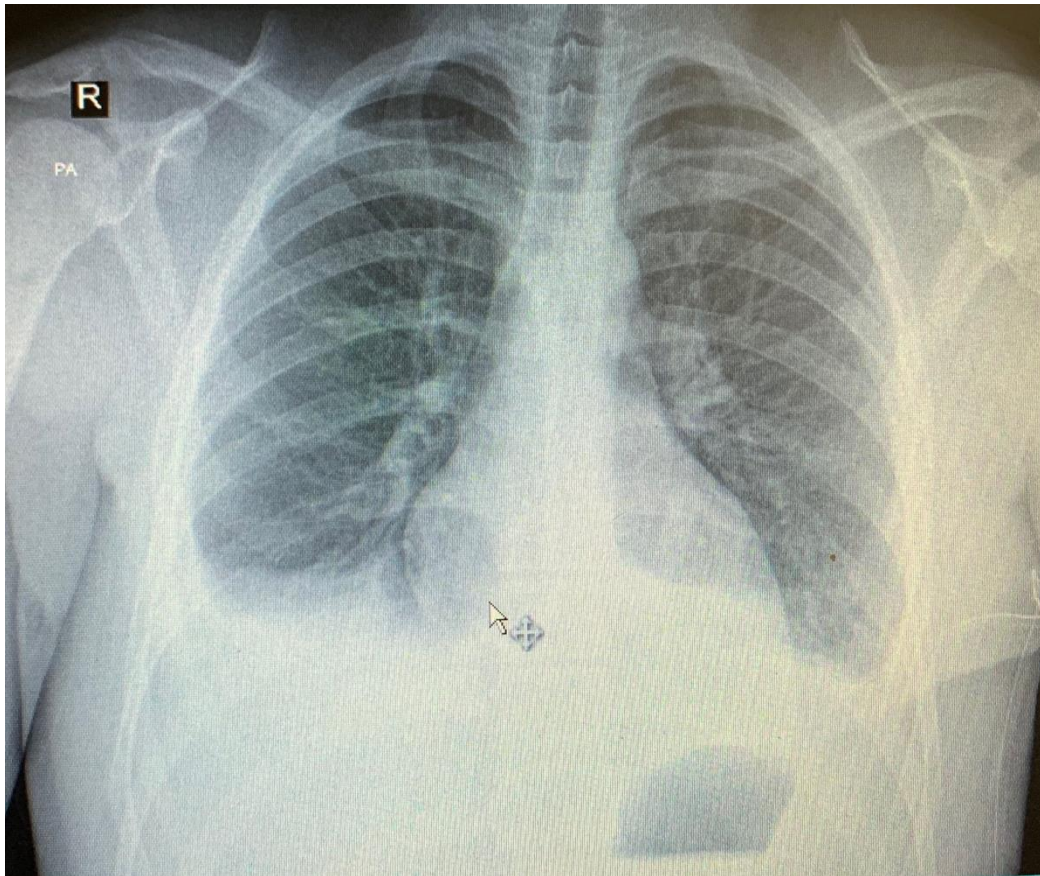


Figure 7. Case 3, chest X-ray after pleural puncture on the right side due to pleural effusion, third postoperative day