



СРПСКИ АРХИВ
ЗА ЦЕЛОКУПНО ЛЕКАРСТВО
SERBIAN ARCHIVES
OF MEDICINE

Address: 1 Kraljice Natalije Street, Belgrade 11000, Serbia

+381 11 4092 776, Fax: +381 11 3348 653

E-mail: office@srpskiarhiv.rs, Web address: www.srpskiarhiv.rs

Paper Accepted*

ISSN Online 2406-0895

Case report / Приказ болесника

Vladimir Milosavljević¹, Nikola Grubor^{2,3,*}, Slavko Matic^{2,3}, Dragan Eric⁴, Boris Tadic^{2,3}

**Report on four cases of the rarest benign splenic tumor – myoid
angioendothelioma, with literature review**

Приказ четири случаја најређега бенигног тумора слезине – миоидног
ангиоендотелиома са прегледом литературе

¹Gracia Medica Polyclinic, Belgrade, Serbia;

²Clinical Centre of Serbia, Clinic for Digestive Surgery – First Surgical Clinic, Belgrade, Serbia;

³University of Belgrade, Faculty of Medicine, Belgrade, Serbia;

⁴National Health Insurance Fund, Serbia

Received: November 13, 2020

Accepted: June 4, 2021

Online First: June 11, 2021

DOI: <https://doi.org/10.2298/SARH201113051M>

***Accepted papers** are articles in press that have gone through due peer review process and have been accepted for publication by the Editorial Board of the *Serbian Archives of Medicine*. They have not yet been copy-edited and/or formatted in the publication house style, and the text may be changed before the final publication.

Although accepted papers do not yet have all the accompanying bibliographic details available, they can already be cited using the year of online publication and the DOI, as follows: the author's last name and initial of the first name, article title, journal title, online first publication month and year, and the DOI; e.g.: Petrović P, Jovanović J. The title of the article. *Srp Arh Celok Lek*. Online First, February 2017.

When the final article is assigned to volumes/issues of the journal, the Article in Press version will be removed and the final version will appear in the associated published volumes/issues of the journal. The date the article was made available online first will be carried over.

***Correspondence to:**

Nikola GRUBOR

Clinical Centre of Serbia, Clinic for Digestive Surgery,

E-mail: n.grubor@yahoo.com

Report on four cases of the rarest benign splenic tumor – myoid angioendothelioma, with literature review

Приказ четири случаја најређег бенигног тумора слезине – миоидног ангиоендотелиома и литературни преглед

SUMMARY

Introduction Myoid angioendothelioma of the spleen is an extremely rare form of a benign splenic tumor. There is no characteristic symptomatology for this disease.

Case outline We present four patients operated on for myoid angioendothelioma of the spleen. Three patients were without problems while one had nonspecific problems. Two patients underwent laparoscopic surgery and two underwent open splenectomy. In all patients, the definitive diagnosis was confirmed by histopathological examination.

Discussion By reviewing the aforementioned medical databases of published papers in English, we found a total of eight cases of myoid angioendothelioma of the spleen. In addition to the mentioned number, we have added our series of cases.

Conclusion Twenty-one years after the discovery of myoid angioendothelioma of the spleen, the small number of cases presented in the literature is still a limiting factor in making conclusions and in learning lessons about this disease

Keywords: spleen; tumor of the spleen; splenectomy; laparoscopy

САЖЕТАК

Увод Миоидни ангиоендотелиом је веома редак бенигни тумор слезине. Не постоји карактеристична симптоматологија за ово обољење.

Приказ случаја Представљамо четири пацијента оперисана због миоидног ангиоендотелиома слезине. Три пацијента су била без тегоба док је један имао неспецифичне тегобе. Два пацијента су оперисана лапароскопски, а два отвореном спленектомијом. Код свих пацијената дефинитивна дијагноза је потврђена хистопатолошким прегледом.

Дискусија Прегледајући поменуте медицинске базе података објављених радова на енглеском језику, пронашли смо укупно осам случајева миоидног ангиоендотелиома слезине. Поред поменутог броја, додали смо и нашу серију случајева.

Закључак Двадесет и једну годину након открића миоидног ангиоендотелиома слезине, мали број случајева представљених у литератури је и даље ограничавајући фактор у доношењу закључака у доношењу закључака о овој болести.

Кључне речи: слезина; тумор слезине; спленектомија; лапароскопија

INTRODUCTION

Myoid angioendothelioma of the spleen (MEA) is an extremely rare form of benign splenic tumor. As most benign tumors of the spleen, vascular malformations in combination with stromal cells are responsible for the development of MEA [1].

There is no characteristic symptomatology for this disease. Patients are mostly asymptomatic, and sporadically there may be symptoms in the form of nonspecific pain below the left costal arch, abdominal discomfort, nausea and vomiting, which may occur sporadically [2].

MAE is diagnosed accidentally, most often as an incidental finding within other diagnostic foci. Initially, it can be detected by ultrasonography of the abdomen, although

computed tomography (CT), as well as magnetic resonance imaging (MRI) have much greater specificity and sensitivity. The most authoritative, and at the same time the most accurate diagnosis is histopathological verification (HP) [3,4].

Splenectomy (laparoscopic or open) is the only curative treatment modality. Laparoscopic splenectomy (LS) should certainly be preferred over open splenectomy (OS) because of the numerous advantages and benefits achieved by this approach [5].

Our study aims to implement our series of MAE cases into current literature data. We also wanted to show that, in addition to the already known benefits of LS over OS, preserving the integrity of the preparation does not affect the definitive HP finding, and that there is absolutely no difference whether the spleen is delivered in fragments or as a complete sample.

Case report

Case 1

A 54-year-old female patient was referred to our hospital for additional diagnostics and further treatment due to a lesion in the spleen, which had previously been verified with ultrasound. On admission, the patient's general health status was good, she had no comorbidities and reported no complaints. Within additional diagnostics, an abdominal CT scan was performed. The finding confirmed the existence of a lesion in the spleen, 52x50 mm in size, which was, according to its characteristics, most consistent with a splenic tumor. We indicated that surgical treatment was necessary and proceeded to perform laparoscopic splenectomy in the standard manner, with the use of hem-o-lok clips for the vascular elements of the splenic hilum (Figure 1). Hospitalization was uneventful, with no complications. On the third postoperative day the patient was prescribed appropriate therapy and discharged from hospital to complete recovery at home.

Case 2

A 26-year-old male patient was hospitalized for surgical treatment. Previous MRI of the abdomen showed tumorous lesions in the spleen, 45x40 mm (Figure 2). After adequate preoperative preparation, the patient was operated on in general anesthesia. Laparoscopic splenectomy was performed, in the standard manner, with the application of the hanging spleen technique, as was done in the previously described case. The surgery itself, as well as postoperative recovery, were uneventful, with no complications. The patient was discharged from hospital on the third postoperative day.

Case 3

A 58-year-old male patient was hospitalized for surgical treatment of a previously verified tumorous lesion in the spleen. This lesion had been diagnosed with an abdominal MRI scan, as an incidental finding within diagnostic procedures and testing focused on other health issues. The patient, whose general health status was good and who had no comorbidities, was treated surgically. The surgical procedure and postoperative recovery were uneventful, with no complications. The patient was discharged on the fifth postoperative day.

Case 4

A 69-year-old male patient was admitted to hospital for health status assessment and additional diagnostics. Prior to hospitalization, the patient felt discomfort in the upper left quadrant of the abdomen with occasional non-specific pain in the same region. Ultrasound of the abdomen showed a lesion in the spleen. The patient was then referred for further treatment. After hospital admission, a CT of the abdomen was performed. The scan verified a

lesion in the spleen, 55x60 mm in size, which, according to its characteristics, was consistent with a splenic tumor. Surgical treatment was indicated, and open splenectomy was performed, as in Case 3, described above. Postoperative recovery was uneventful and with no complications, and the patient was discharged from hospital for further recovery at home on the fifth day after the procedure.

All the patients whose cases are described above were prescribed prophylactic antibiotic therapy at discharge, and were also given instructions regarding necessary postoperative immunization, in keeping with the current guidelines found in literature and guidebooks on the prevention and treatment of postsplenectomy infections.

All the spleen samples were sent for definitive histopathological and immunohistochemical analysis, which confirmed that, in all four of the described cases, the lesions were myoid angioendotheliomas (MAE) of the spleen. In one of the patients, however, overlap was detected, i.e., in addition to MAE, the existence of splenic cord capillary hemangioma was also confirmed.

DISCUSSION

Myoid angioendothelioma of the spleen is an extremely rare form of a benign splenic tumor. It was described for the first time by Kraus and Dehner in 1999 [6]. By reviewing the aforementioned medical databases of published papers in English, we found a total of eight cases of MEA. In addition to the mentioned number, we have added our series of cases and showed it in Table 1, all of it to update and add to the current literature data.

Including data from our case series, the distribution by gender is slightly higher in men compared to women 7/5.

The symptomatology of this disease is mostly absent. Rarely, there may be a pain in the upper left quadrant of the abdomen, as well as a feeling of discomfort in the abdomen [7,8].

Due to the absence of specific symptoms, like other benign tumors of the spleen, MAE is a real diagnostic challenge. They are almost always discovered accidentally as an incidental finding as part of other diagnostic tests and foci [9,10]. They are initially detected by ultrasound examination of the abdomen, although it is certainly necessary to perform one of the more modern diagnostic methods such as CT, MRI, or positron emission tomography for better verification, determination of characteristics, and differential diagnosis [11].

The definitive and only authoritative diagnosis is made by histopathological and immunohistochemical examination [2,5,12].

All patients presented in our study underwent histopathological and immunohistochemical verification. Definitive HP findings revealed a well-circumscribed tumor composed of numerous capillary caliber vessels implanted in an eosinophilic matrix with pulp stromal cells. Further immunohistochemical examination revealed strongly positive staining of the vascular lining cells for CD34 and CD31, while stromal cells stained positive for SMA, desmin, actin, and myosin SM. Staining for S100, CD8 and CD21 was not present in either lining. Therefore, a diagnosis of myoid angioendothelioma of the spleen was confirmed.

Some authors advocate preoperative histopathological analysis of changes in the spleen using fine-needle aspiration [13].

From our previous experience in the treatment of benign tumors of the spleen, we do not share the opinion that the use of fine-needle aspiration is necessary if it is known that any tumor change in the spleen requires surgical treatment, ie splenectomy [2,5,14,15]. Special attention should certainly be paid to the fact that the fine-needle aspiration sample can often be inconclusive, and the intervention itself, like all other invasive procedures on the spleen, carries a certain type of risk for complications [16].

As in the case of other benign splenic tumors, splenectomy is the only curative

treatment modality to be applied for MAE [2,17]. According to the literature data presented so far in Table 1, out of a total of eight cases, only one underwent laparoscopic splenectomy. During that time, we performed laparoscopic splenectomy in two patients, and open splenectomy was performed in two patients due to technical reasons and to the insufficient experience of the surgeons who performed the operations.

Due to the numerous advantages and benefits that laparoscopic splenectomy provides, it should always be given priority over open splenectomy [2,5,14,16,18].

Since it is a benign tumor of the spleen, it is possible to perform partial splenectomy, especially in younger people [19]. In general, the small number of cases described so far, as well as the lack of reliable information on the application of partial splenectomy in the treatment of MAE, are a limiting factor [20].

CONCLUSION

Twenty-one years after the discovery of MAE, the small number of cases presented in the literature is still a limiting factor in making conclusions and in learning lessons about this disease. Each subsequent case should be approached individually to possibly gain new, significant, and necessary information and knowledge. Laparoscopic splenectomy has proven to be a safe, easily applicable, and effective treatment modality for MAE. It can be said that it is the modality of choice both as surgical treatment and as diagnostics and should always be applied when there are suitable conditions, technical equipment, and trained staff. It remains to be seen in the future whether there are conditions for the application of partial splenectomy in MAE on a larger sample of patients, which would certainly improve treatment and provide a better, more comfortable postoperative lifestyle, especially in younger patients.

Ethical standards: All procedures performed in studies involving human participants were

in accordance with the ethical standards of the institutional and/or national research committee and with the 1964 Helsinki declaration and its later amendments or comparable ethical standards. Written consent to publish all shown material was obtained from the patient

Funding sources: The authors declared that this work has received no financial support.

Conflict of interest: None declared.

Paper accepted

REFERENCES

1. Jang, Kyu Yun, et al. "Myoid Angioendothelioma of the Spleen Mimicking Metastatic Disease in a Patient with Rectal Cancer: A Radiologic-Pathologic Correlation." *Annals of Diagnostic Pathology*. 2013;1: 108–12. DOI: 10.1016/j.anndiagpath.2012.03.001
2. Fieldman L, Munshi A, Al-Mahroos M, Fried G. *The Spleen. Maingot's abdominal operations*. 13th ed. New York: McGraw-Hill; 2019. p. 1239-49.
3. Geramizadeh, Bita, Mohammadhossein Anbardar, and Seyed-Ali Malekhosseini. "Myoid Angioendothelioma of the Spleen: A Rare Case Report and Literature Review." *Iranian Journal of Medical Science*. 2017;1 :89–93. PMID: 28293056
4. Karim, Rooshdiya Z., Jenny Ma-Wyatt, Michael Cox, and Richard A. Scolyer. "Myoid Angioendothelioma of the Spleen." *International Journal of Surgical Pathology* 2004;1: 51–56. DOI: 10.1177/106689690401200110
5. Milosavljevic Vladimir, Boris Tadic, Nikola Grubor, Dragan Eric, and Slavko Matic. "Laparoscopic Vs. Open Surgery in Management of Benign Neoplasms of Spleen—Single Institution Experience." *Indian Journal of Surgery* 2020;3: 355–59. DOI: 10.1007/s12262-019-01974-5
6. Kraus, M. D., and L. P. Dehner. "Benign Vascular Neoplasms of the Spleen with Myoid and Angioendotheliomatous Features." *Histopathology*, 1999;35(4): 328–36. DOI: 10.1046/j.1365-2559.1999.00730.x
7. Chan, Yuen F., Beena Kumar, Alex Auldish, and Keith Waters. "Myoid Angioendothelioma of the Spleen in a Child after Successful Treatment of a Wilms' Tumour." *Pathology*. 2005; 37,(2): 181–84. DOI: 10.1080/00313020500058664
8. Renz DM, Mentzel HJ. *Bildgebung bei abdominalen Tumoren im Kindes- und Jugendalter : Teil I: Hintergründe, Leber-, Milz- und Pankreastumoren [Imaging of abdominal tumors in childhood and adolescence : Part I: Background, hepatic, splenic and pancreatic tumors]*. Radiologe. 2018;58(6):595-608. DOI: 10.1007/s00117-018-0395-3.
9. Siewert, Bettina, Noam Z. Millo, Kamaldeep Sahi, Robert G. Sheiman, Olga R. Brook, Maryellen R. M. Sun, and Robert A. Kane. "The Incidental Splenic Mass at CT: Does It Need Further Work-up? An Observational Study." *Radiology*. 2018; 287(1): 156–66. DOI: 10.1148/radiol.2017170293
10. Shah, Adil A, Luca Dragos, Timothy D Kane, and Mikael Petrosyan. "Splenic Myoid Angioendothelioma Mimicking Metastatic Disease in an 8-Year-Old with Stage IV Wilms' Tumour." *BMJ Case Reports*. 2018, bcr-2018-224550. DOI: 10.1136/bcr-2018-224550
11. Jang S, Kim JH, Hur BY, Ahn SJ, Joo I, Kim MJ, Han JK. Role of CT in Differentiating Malignant Focal Splenic Lesions. *Korean J Radiol*. 2018;19(5):930-937. DOI: 10.3348/kjr.2018.19.5.930.
12. Grubor, Nikica, Boris Tadic, Marjan Micev, Nikola Grubor, and Vladimir Milosavljevic. "Sclerosing Angiomatoid Nodular Transformation of the Spleen - An Uncommon Splenic Pseudotumor Variant." *Srpski Arhiv Za Celokupno Lekarstvo* 2019;147(9–10): 623–27. DOI:10.2298/SARH190325078G..
13. Hudson, Jena B., Faris M. Murad, Julie E. Kunkel, and Brian T. Collins. "Endoscopic Ultrasound Guided Fine-Needle Aspiration of a Splenic Hemangioma with Extramedullary Hematopoiesis." *Diagnostic Cytopathology*.2013; 41(12)1086–90. DOI: 10.1002/dc.21862
14. Adrian PE, Eduardo TM. Spleen. In: Brunicaardi FC, Andersen DK, Billiar TR, Dunn DL, Hunter JG, editors. *Schwartz's principles of surgery*. Tenth edition. ed. New York: McGraw-Hill Education; 2015. p. xviii, 2069 pages
15. Gonzalez-Urquijo M, Rodarte-Shade M, Gil-Galindo G. Splenic Primary Solid Tumors : Does a Preoperative Histopathology Diagnosis Really Matter? *Am Surg*. 2020 Sep 16:3134820951480. DOI: 10.1177/0003134820951480
16. Kusano T, Ryu C, Matsuo T, Hayashi H. Laparoscopic Splenectomy in a Patient with Sclerosing Angiomatoid Nodular Transformation. *Case Rep Gastroenterol*. 2020 Apr 22;14(1):212-219. DOI: 10.1159/000506934
17. Milosavljevic, Vladimir, Boris Tadic, Nikola Grubor, Dragan Eric, Milorad Reljic, and Slavko Matic. "Analysis of the Surgical Treatment of the Patients Operated on by Using Laparoscopic and Classic Splenectomy Due to Benign Disorders of the Spleen." *Turkish Journal of Surgery*.2019; 35 (2): 111–16. DOI: 10.5578/turkjsurg.4324
18. Milosavljevic V, Tadic B, Gonzalez-Urquijo M, Knezevic D, Grubor N. Myoid Angioendothelioma: A Rare Benign Splenic Tumor. *Balkan Med J*. 2021 Feb 17. doi: 10.5152/balkanmedj.2021.20100
19. Kimura K, Kurashima Y, Tanaka K, Nakanishi Y, Asano T, Ebihara Y, Noji T, Murakami S, Nakamura T, Tsuchikawa T, Okamura K, Shichinohe T, Kanno-Okada H, Hirano S. Laparoscopic partial splenectomy for splenic lymphangioma: a case report. *Surg Case Rep*. 2020 Jun 18;6(1):140. DOI: 10.1186/s40792-020-00882-1

20. Wang, Zhendan, Liang Zhang, Bo Zhang, Dianbin Mu, Kai Cui, and Sheng Li. "Hemangioendothelioma Arising from the Spleen: A Case Report and Literature Review." *Oncology Letters*.2015; 9(1): 209–12. DOI: 10.3892/ol.2014.2693

Paper accepted

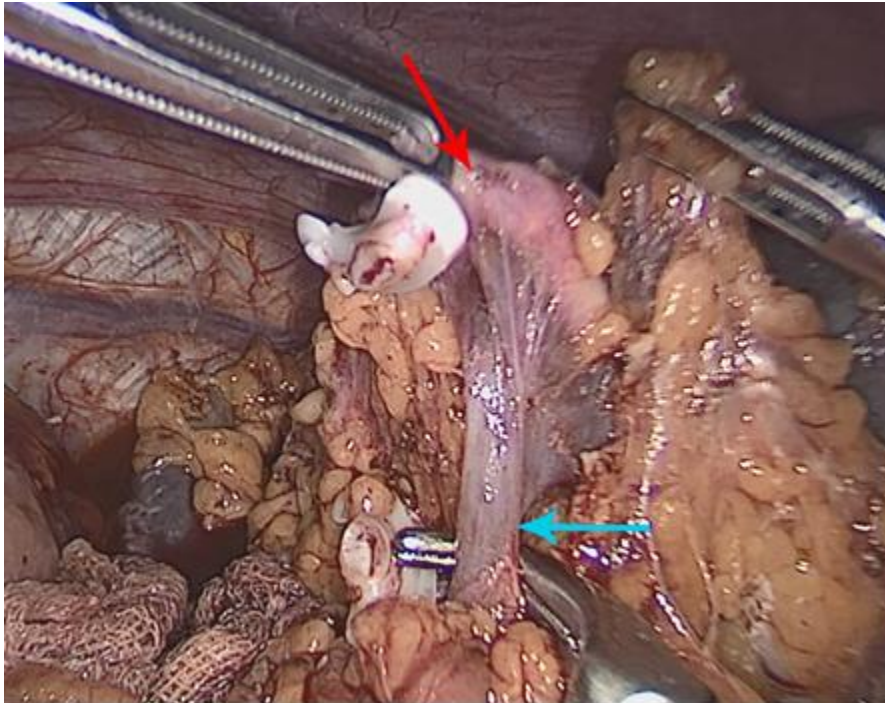


Figure 1. intraoperative presentation of the hemostatic technique for the vascular elements of the splenic hilum; the red arrow indicates the splenic artery and the blue arrow indicates a splenic vein

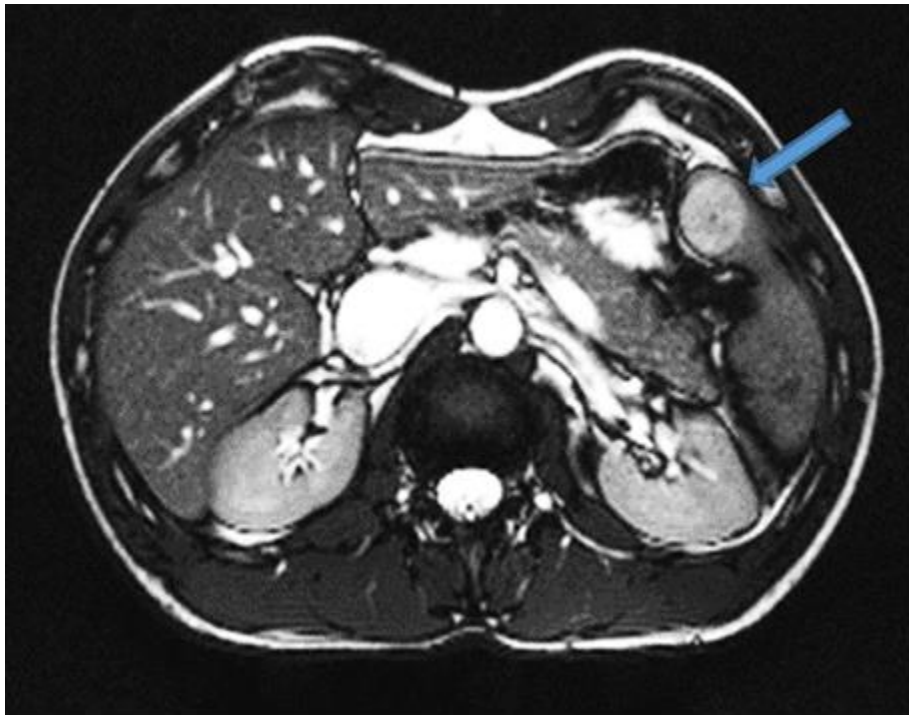


Figure 2. Magnetic resonance imaging examination showed a solitary lesion in the lower pole of the spleen, with peripheral rim enhancement on arterial phase

Table 1. Characteristics of all included studies and our studies

Author	Country	Year	Study design	Age	Gender	Histopathology confirmation	Treatment Laparoscopy or Open surgery	Accompanying disease	Signs and symptoms
Kraus M. D. (6)	USA	1999	Case series	3 7 43	Female Male Female	In all three cases: may represent proliferations of myoid elements native to the spleen	Case 1: not reported Case 2: not reported Case 3: open surgery	Case 1: Beckwith–Wiedemann syndrome Case 2: None Case 3: Cystic mucinous pancreatic neoplasm	Case 1: not reported Case 2: abdominal discomfort Case 3: not reported
Karim R. Z. (4)	Australia	2004	Case report	51	Male	Yes	Not clear	Renal calculi and degenerative spinal disc disease	Abnormal liver function test results
Chan Y. F. (7)	Australia	2005	Case report	8	Male	Yes	Partial splenectomy and removal of the splenic lesion	Wilms' tumor	Fever, lethargy, vomiting and bone pain
Jang K. Y. (1)	South Korea	2013	Case report	41	Female	Yes	Open surgery	Rectal cancer, hypertension and asthma	Incidentally discovered while searching for metastasis of rectal cancer
Geramizadeh B. (3)	Iran	2017	Case report	38	Female	Yes	Open surgery	None	Epigastric abdominal pain and fullness
Shah A. A. (10)	India	2018	Case report	11	Male	Yes	Laparoscopic splenectomy	Wilms tumor (kidney)	No symptoms and signs, discovered on routine ultrasound (follow up after Wilms tumor)
Milosavljević V.	Serbia	2020	Case series	57 32 65 74	Female Male Male Male	Yes	Case 1, 2. Laparoscopic splenectomy Case 3, 4. Open surgery	None	No symptoms and signs, discovered on routine ultrasound and incidentally on computed tomography, magnetic resonance