



**СРПСКИ АРХИВ**  
ЗА ЦЕЛОКУПНО ЛЕКАРСТВО  
**SERBIAN ARCHIVES**  
OF MEDICINE

Address: 1 Kraljice Natalije Street, Belgrade 11000, Serbia

+381 11 4092 776, Fax: +381 11 3348 653

E-mail: [office@srpskiarhiv.rs](mailto:office@srpskiarhiv.rs), Web address: [www.srpskiarhiv.rs](http://www.srpskiarhiv.rs)

**Paper Accepted\***

**ISSN Online 2406-0895**

**Original Article / Оригинални рад**

Milan Jovanović<sup>1,2</sup>, Biljana Čertić<sup>1</sup>, Lukas Rasulić<sup>2,3†</sup>

**Determination of follicular direction and preparation of micrograft holes  
for hair transplantation**

Одређивање правца фоликула и припремање рупа за микрографтовање  
код трансплантације косе

<sup>1</sup>Clinic for Burns, Plastic and Reconstructive Surgery, CCS, Belgrade, Serbia

<sup>2</sup>University of Belgrade, Faculty of Medicine, Belgrade, Serbia

<sup>3</sup>Clinic for Neurosurgery, CCS, Belgrade, Serbia

**Received: March 19, 2019**

**Accepted: April 12, 2019**

**Online First: May 10, 2019**

**DOI: <https://doi.org/10.2298/SARH190319039J>**

\* **Accepted papers** are articles in press that have gone through due peer review process and have been accepted for publication by the Editorial Board of the *Serbian Archives of Medicine*. They have not yet been copy edited and/or formatted in the publication house style, and the text may be changed before the final publication.

Although accepted papers do not yet have all the accompanying bibliographic details available, they can already be cited using the year of online publication and the DOI, as follows: the author's last name and initial of the first name, article title, journal title, online first publication month and year, and the DOI; e.g.: Petrović P, Jovanović J. The title of the article. *Srp Arh Celok Lek*. Online First, February 2017.

When the final article is assigned to volumes/issues of the journal, the Article in Press version will be removed and the final version will appear in the associated published volumes/issues of the journal. The date the article was made available online first will be carried over.

† **Correspondence to:**

Lukas RASULIĆ

Clinic for Neurosurgery, CCS, Koste Todorovića 4,  
Belgrade, Serbia

E-mail: [lukas.rasulic@gmail.com](mailto:lukas.rasulic@gmail.com)

## Determination of follicular direction and preparation of micrograft holes for hair transplantation

### Одређивање правца фоликула и припремање рупа за микрографтовање код трансплантације косе

#### SUMMARY

**Introduction/Objective:** Hair transplantation is one of the fastest evolving procedures in aesthetic surgery and is accompanied by continuous improvement of new techniques. Hairline planning is one of the most important steps in hair transplantation. The shape of the hair also varies depending on the variation of facial shape so it is very important when determining hair direction and making holes for future grafts.

**Methods:** We used ordinary 18 gauge injection needles whose number was the same as the number of micrographs we planned for transplantation.

Needles are administered in pile growth direction and angle, starting from the first row, and then proceeding to the second one and so on, until we insert all prepared needles. We insert them one in front of the other with a precision ease for future follicles.

**Results:** In all 56 patients, we obtained natural hair growth. Inserting the needles reduced bleeding and the average time of the operation was three hours. The success of grafting was 95%. We only had one infection in one patient. Hair growth corresponded to the needle insertion. After a year of transplantation at the last control, the patient's satisfaction was 100%.

**Conclusion:** By using the same number of needles as the number of grafts we reduced operating time, we had a better determination of the direction of hair growth, we can prevent follicular extraction that can be caused by new needle insertion, and this technique achieved a good aesthetic result.

**Keywords:** hair transplantation, follicular unit extraction, follicular unit transplantation

#### САЖЕТАК

**Увод/Циљ:** Трансплантација косе је једна од најбрже еволуирајућих процедура у естетској хирургији и праћена је сталним побољшањем нових техника. Планирање линије косе је један од најважнијих корака у трансплантацији косе. Облик косе такође варира у зависности од варијације облика лица тако да је одређивања правца косе и прављење рупа за будуће графтове врло важно.

**Метод:** Користили смо обичне ињекционе игле промила 18 *gauge* чији је број био исти са бројем микрографтова косе који смо планирали за трансплантацију. Игле убадамо тако да морају да прате правац и угао раста длаке у датој реципијентној регији, полазеће од првог реда, ка другом, трећем и тако даље, док не пласирамо све припремљене игле. Ми их пласирамо једну испред друге са прецизном лакоћом за будуће фоликуле.

**Резултати:** Код свих 56 пацијената смо добили природан раст косе. Убадањем игала смањили смо крварење и просечно време саме операција за три сата. Успешност примања графтова је био 95%. Инфекцију смо имали само код једног пацијента. Раст косе одговарао је правцу убадања игала. Након годину дана од трансплантације на последњој контроли задовољство пацијената је било 100%.

**Закључак:** Коришћењем истог броја игала са бројем графтова косе ми смањујемо операционо време, имамо бољу детерминацију правца раста косе, можемо спречити фоликуларну екстракцију која може бити изазвана са неким новим убодом игле и овом техником постижемо добар естетски резултат и смањујемо операционо време.

**Кључне речи:** Трансплантација косе, екстракција фоликуларне јединице, трансплантација фоликуларне јединице

#### INTRODUCTION

Hair transplantation has been one of the fastest evolving procedures in aesthetic surgery in the last 20 years, and has been accompanied by continuous improvement of new techniques. Recent advances in technology and the concept of the use of follicles of individual grafts have made this procedure reach a new height [1, 2]. Not surprisingly, the

ability to get very natural results by these techniques has encouraged a large number of bald men and sometimes women to opt for this surgical solution [3, 4].

Hair loss is usually accompanied by various psychological problems, such as lack of confidence, depression etc. Hair loss and baldness in men usually begins between the age of 20 and 40. Genetics is the most important factor causing baldness. It is the most common cause of hair loss and it is autosomal dominant inheritance. Like most tissues, hair is subject to constant renewal through life. Follicles are periodically replaced by new ones.

The total number of scalp hair in human beings is usually 100,000. Approximately 40–100 hairs per day drop; this rate increases at the end of summer and in early autumn, and is reduced at the end of winter and in early spring, due to the effects of temperature change. We used the seven phases of Norwood baldness classification [5, 6, 7]. Hair transplantation depends on the hair density and the dominance of the hair follicles of the donor region in androgenic alopecia.

Individual hair grafts are used to create natural hair. Two techniques are most commonly used today: follicular unit extraction (FUE) is a hair transplantation technique that uses small pinches (0.8–1 mm in diameter) to extract the follicular units and follicular unit transplantation (FUT) is a technique based on harvesting the follicular unit from a strip of tissue [2, 8–13].

During the last ten years, many authors have dealt with these two techniques and the way of harvesting follicular units from the donor region. However, a small number of authors have dealt with the method of making holes in the recipient region and determining the direction of future hair [2, 4, 14–17].

Hairline planning is one of the most important steps in hair transplantation [7, 8, 18]. The shape of hair also varies depending on the variation of facial shape so that determining hair direction and making holes for future grafts is very important [19, 20].

Hair transplantation can be accomplished by making holes for micrografts in the recipient region with incisional devices: punch graft instrument, 64 blade on a round beaver handle, 15 blade on a conventional scalpel handle, laser or Chois single-hair implantation [7, 21, 22, 23] needle and so on. There are two problems associated with these methods: one is bleeding, and the other is wrong determination of the direction of future hair growth.

We have solved this problem by using ordinary 18 gauge injection needles whose number was the same as the number of hair micrographs we planned for transplantation.

## METHODS

The transplantation was performed in 56 patients (of which 49 male and seven female). The patient was asked to shampoo his head with Betadine the day before and the morning before surgery. After removing donor strip with number 10 blade from occipital donor area, we prepared mini and micrografts. It is very important that during the excision of the donor skin area that the scalpel blades stay parallel with the hair direction so that the hair of the root is not damaged [12, 13, 22].

The recipient area was injected with prepared solution (160 ml Ringer lactate, 1 ml epinephrine, and 40 ml 2% xylocaine). Fifteen minutes after injecting the solution and making a plan for the distribution of grafts, we inserted needles (18 gauge), the number of which is the same as the planned number of hair micrografts, covering the whole recipient region (Figure 1).

Needles are administered in pile's growth direction and angle, starting from the first row, and then proceeding to the second one and so on, until we inserted all prepared needles. We inserted them one in front of the other with a precision ease for future follicles.

When all the needles are inserted, we started with transplantation working backwards, removing needles and placing mini and micrografts into every slit.

This study was done in accord with standards of the institutional Committee on Ethics.

## RESULTS

In all 56 patients, we obtained natural hair growth (Figure 2 and Figure 3). Inserting the needles reduced bleeding and the average operation time took three hours. The success of grafting was 95%. We only had one case of infection in one patient. Hair growth corresponded to the direction of needle insertion (Figure 4 and Figure 5). A year after transplantation at the follow-up, the patient's satisfaction was 100%.

## DISCUSSION

By injecting donor and recipient areas with prepared solution, we prevented bleeding. If it does happen in some slits, it can be stopped with a simple finger pressure for 1–2 minutes.

By using the same number of needles as the number of grafts, we can easily determine and control the direction of hair growth. With this method, there is no dropping of hair grafts caused by hematoma and pressure caused by needle insertion [24, 25, 26].

We think that this method is better than the use of lasers for making holes because CO<sub>2</sub> laser causes micro necrosis. In other methods, punch methods for example, it is more difficult to control the bleeding [12, 13, 16].

## CONCLUSION

By using the same number of needles as the number of grafts, we reduce operating time, we have a better determination of the direction of hair growth, we can prevent

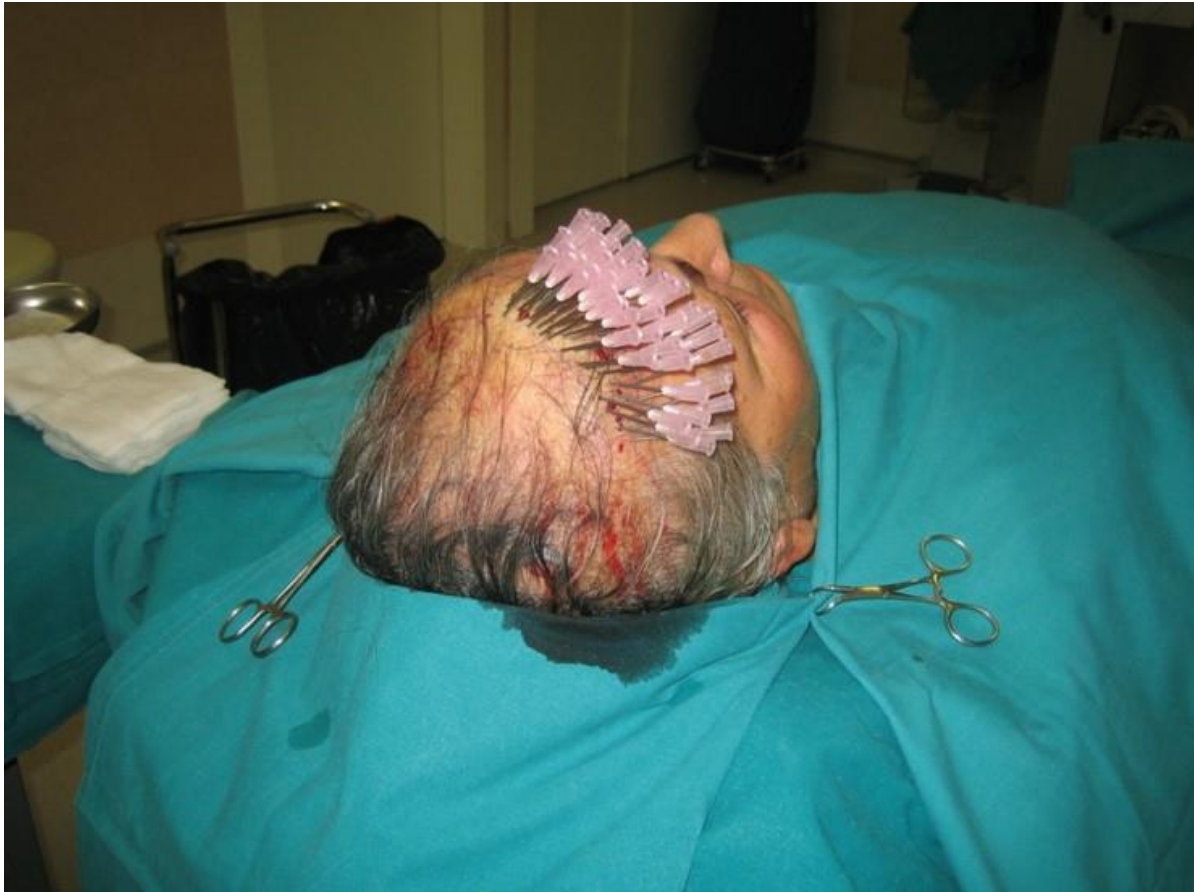follicular extraction that can be caused by new needle insertion, and this technique achieves a good aesthetic result.

**Conflict of interest:** None declared

Paper accepted


**REFERENCES**

1. Jiménez-Acosta F, Ponce-Rodríguez I. Follicular Unit Extraction for Hair Transplantation: An Update. *Actas Dermosifiliogr*. 2017; 108(6):532–7.
2. Farjo B, Farjo N, Williams G. Hair transplantation in burn scar alopecia. *Scars Burn Heal*. 2015; 1;1:20
3. Gho CG, Neumann HA. Advances in hair transplantation: longitudinal partial follicular unit transplantation. *Curr Probl Dermatol*. 2015; 47:150–7.
4. Gupta AK, Lyons DC, Daigle D, Harris JA. Surgical hair restoration and the advent of a robotic-assisted extraction device. *Skinmed*. 2014; 12(4):213–6.
5. Rogers NE, Callender VD. Advances and challenges in hair restoration of curly Afrocentric hair. *Dermatol Clin*. 2014; 32(2):163–71
6. Williams KL Jr. Current practices and controversies in cosmetic hair restoration. *Dermatol Surg*. 2013; 39(5):797–801.
7. Dua A, Dua K. Follicular unit extraction hair transplant. *J Cutan Aesthet Surg*. 2010; 3(2):76–81.
8. Onda M, Igawa HH, Inoue K, Tanino R. Novel technique of follicular unit extraction hair transplantation with a powered punching device. *Dermatol Surg*. 2008; 34(12):1683–8.
9. Rassman WR, Bernstein RM, McClellan R, Jones R, Worton E, Uyttendaele H. Follicular unit extraction: minimally invasive surgery for hair transplantation. *Dermatol Surg*. 2002; 28(8):720–8.
10. Park JH, You SH, Kim NR. Nonshaven Follicular Unit Extraction: Personal Experience. *Ann Plast Surg*. 2019; 82(3):262–8
11. Ghimire RB. Clinical Outcome and Safety Profile of Patients Underwent Hair Transplantation Surgery by Follicular Unit Extraction. *JNMA J Nepal Med Assoc*. 2018; 56(209):540–3.
12. Kim N, Park JH. Pubic Hair Restorative Surgery Using Grafts Harvested by the Nonshaven Follicular Unit Extraction Technique. *Dermatol Surg*. 2018; 44(8):1115–20.
13. Rose PT. Advances in Hair Restoration. *Dermatol Clin*. 2018; 36(1):57–62.
14. Navarro RM, Pino A, Martinez-Andres A, Molina C, Martinez AM, Martinez N, et al. The effect of plasma rich in growth factors combined with follicular unit extraction surgery for the treatment of hair loss: A pilot study. *J Cosmet Dermatol*. 2018; 17(5):862–73.
15. Ahmad M. A new practical classification for spatial distribution and morphology of human hair: Ahmad's LGMA classification. *J Cosmet Dermatol*. 2018; 17(5):881–4.
16. Saxena K, Savant SS. Body to Scalp: Evolving Trends in Body Hair Transplantation. *Indian Dermatol Online J*. 2017; 8(3):167–75.
17. Jiménez-Acosta F, Ponce-Rodríguez I. Follicular Unit Extraction for Hair Transplantation: An Update. *Actas Dermosifiliogr*. 2017; 108(6):532–7.
18. Park JH, You SH. Pretrimmed versus Direct Nonshaven Follicular Unit Extraction. *Plast Reconstr Surg Glob Open*. 2017; 16;5(3): 1261–5
19. Gharwade CR. Innovative modified hair follicle harvesting technique with reverse rake scalp elevator for lower occipital donor area in follicular unit extraction hair transplantation. *Indian J Plast Surg*. 2016; 49(3):390–6.
20. Umar S. Body Hair Transplant by Follicular Unit Extraction: My Experience With 122 Patients. *Aesthet Surg J*. 2016; 36(10):1101–10.
21. Zontos G, Williams KL Jr, Nikiforidis G. Minimizing injury to the donor area in follicular unit extraction (FUE) harvesting. *J Cosmet Dermatol*. 2017; 16(1):61–9.
22. Bernstein RM, Wolfeld MB. Robotic Follicular Unit Graft Selection. *Dermatol Surg*. 2016; 42(6):710–4
23. Kim DY, Choi JP, Hwang YJ, Kim HS. Hidden Transection of Follicular Unit Extraction in Donor Site. *Dermatol Surg*. 2016; 42(4):485–8
24. Mansur AT, Demirci GT, Uzunismail MA, Yildiz S. A rare complication of follicular hair unit extraction: Kaposi's varicelliform eruption. *Dermatol Pract Concept*. 2016; 31;6(1):15–7
25. Williams KL Jr, Gupta AK, Schultz H. Ergonomics in hair restoration surgeons. *J Cosmet Dermatol*. 2016; 15(1):66–71.
26. Umar S. Use of nape and peri-auricular hair by follicular unit extraction to create soft hairlines and temples: my experience with 128 patients. *Aesthet Surg J*. 2015; 35(8):903–9.

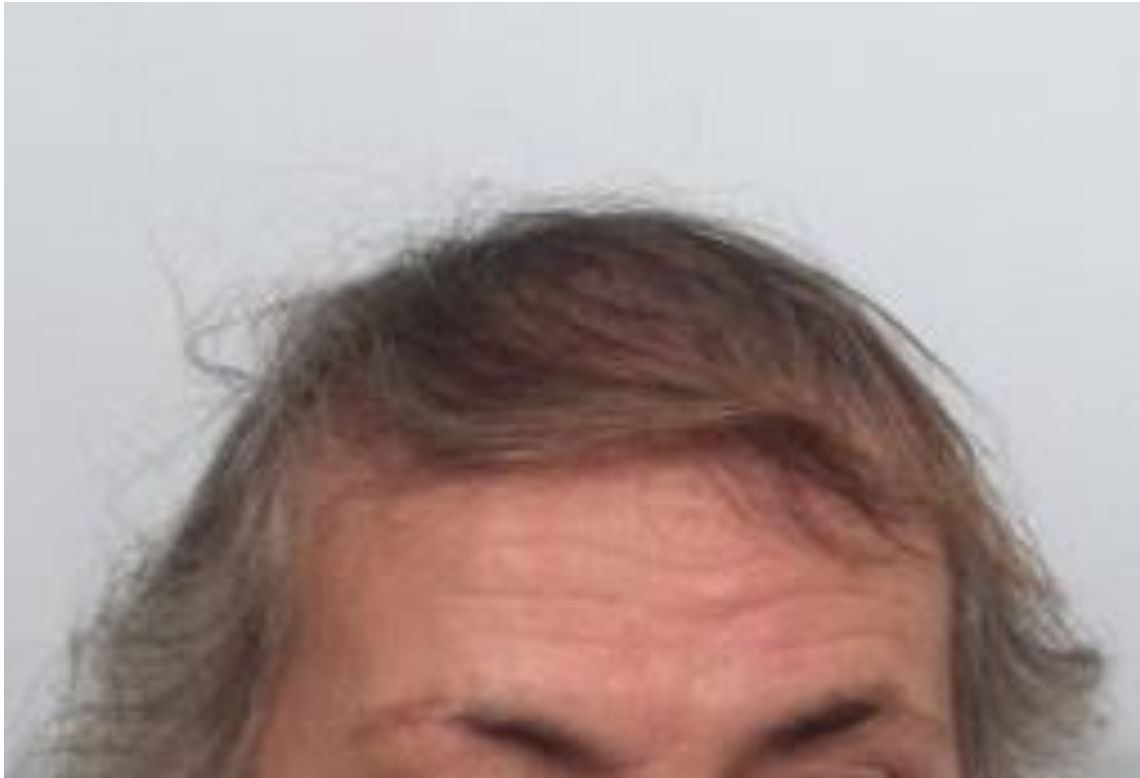

**Figure 1.** Needles are inserted in the direction of hair growth

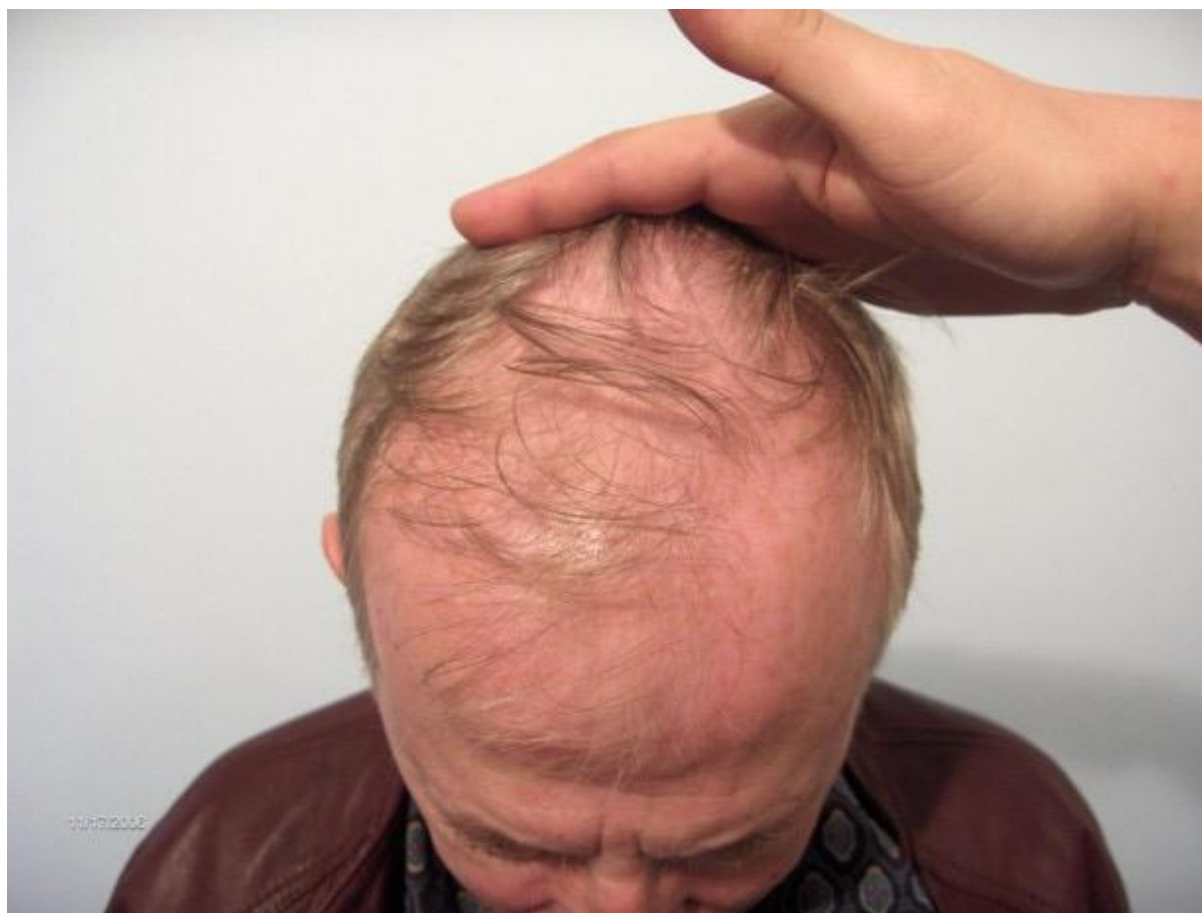



**Figure 2.** Patient before surgery with scaly hair in the frontal region

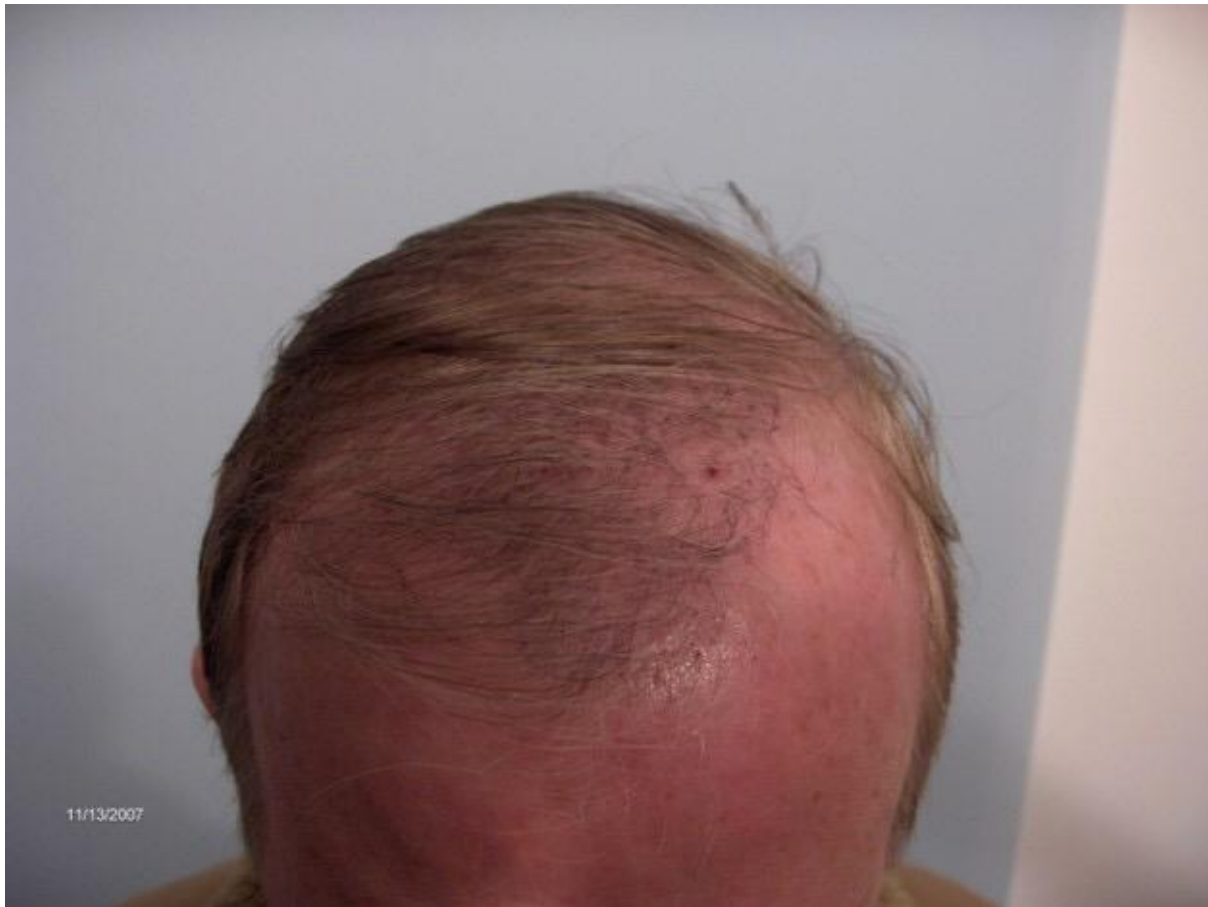

**Figure 3.** The same patient 10 months after transplantation



**Figure 4.** Patient before surgery

Paper 2



**Figure 5.** The same patient seven months after surgery