СРПСКИ АРХИВ
ЗА ЦЕЛОКУПНО ЛЕКАРСТВО
SERBIAN ARCHIVES
OF MEDICINE

Address: 1 Kraljice Natalije Street, Belgrade 11000, Serbia
☏ +381 11 4092 776, Fax: +381 11 3348 653
E-mail: office@srpskiarhiv.rs, Web address: www.srpskiarhiv.rs

Paper Accepted* **ISSN Online 2406-0895**

Case report / Приказ болесника

Džemail S. Detanac[1,♣], Mehmed Mujdragić[1], Dženana A. Detanac[1], Mersudin Mulić[2], Hana Mujdragić[1]

Necrotising Fascitis – a life-threatening infection: case reports and literature review

Некротизирајући Фасцитис – инфекција опасна по живот: прикази случаја и преглед литературе

[1]General hospital Novi Pazar, Serbia;
[2]State University Novi Pazar, Serbia

Received: April 20, 2020
Revised: March 21, 2021
Accepted: March 26, 2021
Online First: March 30, 2021
DOI: https://doi.org/10.2298/SARH200420023D

Paper accepted

*__Accepted papers__ are articles in press that have gone through due peer review process and have been accepted for publication by the Editorial Board of the *Serbian Archives of Medicine*. They have not yet been copy-edited and/or formatted in the publication house style, and the text may be changed before the final publication.
Although accepted papers do not yet have all the accompanying bibliographic details available, they can already be cited using the year of online publication and the DOI, as follows: the author's last name and initial of the first name, article title, journal title, online first publication month and year, and the DOI; e.g.: Petrović P, Jovanović J. The title of the article. Srp Arh Celok Lek. Online First, February 2017.
When the final article is assigned to volumes/issues of the journal, the Article in Press version will be removed and the final version will appear in the associated published volumes/issues of the journal. The date the article was made available online first will be carried over.

♣**Correspondence to:**
Džemail S. DETANAC
Sutjeska Str AD/III/44, 36300 Novi Pazar, Serbia
E-mail: **dzemail.detanac@gmail.com**

Necrotising Fascitis - a life-threatening infection: case reports and literature review

Некротизирајући Фасцитис – инфекција опасна по живот: прикази случаја и преглед литературе

SUMMARY

Introduction Necrotizing Fasciitis is a rare, severe, aggressive infection, life-threatening surgical emergency that spreads quickly, characterized by extensive necrosis of the deep and superficial fascia, associated with significant morbidity and mortality.

Case outline We are presenting two case reports with Necrotizing Fasciitis: a 54-year-old male patient, obese, with hypertension and untreated perianal fistula with severe infection of perianal region, perineum and scrotum, and 64-year-old female patient with diabetes mellitus and heart disease, with severe infection of the lower extremity, anterior abdominal wall, inguinal and gluteal region, in which the entry point of infection were microlesions of the skin after shaving. Both patients were treated by emergency extensive surgical necrectomy with eradication of the deep infection source, with all conservative treatment measures. The first patient was treated with hyperbaric oxygen therapy, the 2nd wasn't because of cardiac and pulmonary contraindications.

Conclusion Better treatment outcome requires a multidisciplinary approach (cardiologist, endocrinologist, nephrologist, orthopedist, surgeon). Rapid and extensive surgical necrectomy is necessary to increase the success of the treatment of patients with this infection.

Keywords: Necrotizing Fasciitis, surgical debridement, severe infection

САЖЕТАК

Увод Некротизирајући Фасцитис је ретка, тешка и агресивна инфекција која се брзо шири и представља ургентно хируршко стање опасно по живот, а карактерише се опсежном некрозом дубоких и површинских фасција, и повезана је са значајним морбидитетом и смртношћу.

Прикази болесника Представљамо два приказа случаја Некротизирајућих Фасцитиса: 54-годишњег мушког пацијента, гојазан, с хипертензијом и нелеченом перианалном фистулом, с тешком инфекцијом перианалне регије, перинеума и скротума и 64-годишњу пацијенткињу, са дијабетес мелитусом и срчаном болешћу, с тешком инфекцијом доњег екстремитета, предњег трбушног зида, ингвиналне и глутеалне регије, код које су улазно место инфекције представљале микролезије коже после бријања. Оба пацијента лечена су хитном опсежном хируршком некректомијом, уз ерадикацију извора инфекције, и уз све мере конзервативног лечења. Први пацијент је лечен и хипербаричном терапијом кисеоником, а други не, због срчаних и плућних контраиндикација.

Закључак Бољи исход лечења захтева мултидисциплинарни приступ (кардиолог, ендокринолог, нефролог, ортопед, хирург). Брза и опсежна хируршка некректомија потребна је како би се повећао успех лечења пацијената с овом инфекцијом.

Кључне речи: Некротизирајући Фасцитис, хируршки дебридман, тешка инфекција

Paper accepted

INTRODUCTION

Necrotizing Fasciitis (NF) is a rare, severe, bacterial life-threatening infection, characterized by spreading rapidly, affecting subcutaneous tissue, fascia and sometimes muscles, an infection with high mortality rate, especially in patients with comorbidities [1].

The incidence of this infection is 1–4/100.000 persons per year. Many studies present different mortality data for NF, but what they have in common is that it is still extremely high [1, 2, 3]. In a population-based study in US, it was reported that overall mortality was 7.5%.

 Copyright © Serbian Medical Society

Some studies reported mortality rate up to 70% with higher rates in underdeveloped countries. The most new and modern studies report mortality rate between 20–40% [4].

CASE REPORT 1

A 54-year-old man was admitted to the Department of general surgery in General hospital Novi Pazar, febrile, languid, hypotensive, tachycardic, obese, with changes on the skin of the perianal region, about 3×3 cm in size, a slight bullous change on the surface and palpatory evident tissue fluctuation below the change, in September 2019. History of the present illness: untreated perianal fistula. Past medical history was positive for hypertension.

When admitted, an incision was made and a large amount of green-brown liquid content was obtained with an extremely unpleasant odor. Laboratory findings during hospitalization are shown in Table 1. Intensive conservative treatment started with empirical antibiotics (*ceftriaxone, gentamicin and metronidazole)*, insulin therapy, fluid replacement, analgesics, and other supportive therapy, with monitoring of vital parameters. After 24 hours of treatment erythematous changes occurred on the skin with obvious rapid spread of infection to the perineum and scrotum, as well as to both gluteal regions, also increased local pain, biochemical inflammatory parameters and development of clinical signs of sepsis (s-Procalcitonin 21.08, LRINEC score 11). Extensive surgical excision of infected parts of the perianal region, broadly into each gluteal region was made, as well as excision of scrotal skin with opening of all testicular sheaths and opening inguinal canals on both sides. Wound left to heal *per secundam intentionem* [Figure 1].

Wound swab taken for microbiological analysis was positive for *Klebsiella spp*. Treatment was continued with antibiotics (*imipenem, vancomycin and metronidazole*) and regular wound dressing 2 to 3 times daily.

 Copyright © Serbian Medical Society

Postoperatively, after 48 hours surgical reintervention, necrectomy, was performed. On the 5th postoperative day there was a worsening of the patient's general condition which was complicated by the appearance of pulmonary edema and heart failure. After the improvement of the general condition, on the 10th postoperative day, hemodynamically stable, with neat vital parameters, the patient was transported to a tertiary health care institution for treatment with HBOT (hyperbaric oxygen therapy). Prior to HBOT, colon surgery was performed according to Hartman procedure. He was treated in a tertiary institution for 40 days after which he was discharged for outpatient treatment with a regular wound toilet and occasional surgeon's control. After four months of treatment the patient was fully recovered [Figure 2].

CASE REPORT 2

64-year-old female patient was admitted to the Department of General surgery in General hospital Novi Pazar, in September 2019. On admission she was febrile, languid, hemodynamically unstable, with pretibial edema, septic, less mobile. For over 15 years a diabetic on insulin therapy.

On admission, an infection of the skin of the groin region on the right, about 6x2 cm in size, was noticed, where the skin was erythematous, painful, with the presence of subcutaneous air enhancements.

Biochemical parameters during hospitalization are shown in Table 1 (s-Procalcitonin 23.12, LRINEC score 10). Four hours after admission an extensive excision of the skin and subcutaneous tissue was made, all the way to the fascia of right femoral and pubic region, anterior abdominal wall in the infraumbilical region, pubic and right gluteal region, to the macroscopically visible healthy tissue [Figure 3]. The wound left to heal *per secundam*

Paper accepted

 Copyright © Serbian Medical Society

intentionem. After necrectomy antibiotic treatment was started: *imipenem*, *vancomycin* and *metronidazole*, and other supportive therapy with daily wound toilets, 2–3 times a day.

Postoperatively, a decrease in biochemical inflammatory parameters occurs. Surgical reintervention, necrectomia, 48 hours after the first surgery, was performed. Microbiologically isolated Pseudomonas aeruginosa in the wound swab was sensitive to administered antibiotics. HBOT treatment was not performed due to cardiac and pulmonary contraindications. On the control swab the microbiological findings showed Staphylococcus aureus and Klebsiella. Due to a large skin defect, to prevent skin contracture, situational sutures were repeatedly placed on the skin [Figure 4] but to no avail. In good general condition, neat vital parameters, no local signs of infection, after 45 days of hospitalization, a skin defect was reconstructed by plastic surgeon.

Paper ac

DISCUSSION

Necrotizing Fasciitis (NF) is severe and potentially fatal, aggressive infection associated with significant morbidity and mortality. Some literature data reported that the prevalence of NF is about 1–4 cases per 100.000 populations; men are commonly affected, with a male-to-female ratio of 3:1 [1]. However, there are studies showing different results, so, male to female ratio by Eke et al is approximately 10:1 [5], and in the study of Kim et al, men accounted for 67.1% [6].

Most commonly it is a polymicrobial infection caused by aerobic and anaerobic bacteria, most commonly from the genitourinary and digestive tract, but also from the skin [7]. However, some recent studies suggests that the prevalence of monomicrobial NF is as high as 60–80% [8]. Tsai YH at al. state that the infections have more rapid and fulminant form if they are caused by Gram-negative microorganisms [8]. Jabbour et al. state that

 Copyright © Serbian Medical Society

Pseudomonas and Proteus infections were the most commonly associated microorganisms among non-survivors in their study [9].

In presented cases, Pseudomonas and Klebsiella were isolated as the only pathogenic microorganisms.

There is no age predilection for NF, but patient age is a significant predictive factor for treatment outcome. Patients in the middle-ages and older than 50 years of age are more likely to be infected [10], have a worse prognosis, especially if they have more comorbidities [1,11]. In the study by Chalya PL et al., the median age of patients was 34 years [11], while Schröder A at al. analyzed the occurrence of NF in children [12]. Advanced age is independent and strong predictor of mortality, mainly due to the increased incidence of comorbidities [13].

Diabetes mellitus is the most common comorbidity in patients with NF, and in addition to it, there are chronic alcoholism, chronic renal failure, arterial hypertension, immunosuppression, systemic disorders, cirrhosis, obesity, local trauma. Jabbour et al. stated that in their study diabetes was present in 64%, followed by hypertension and renal impairment, and compared to a survivor group, these comorbidities were higher among non-survivors [9]. In a study by Tarchouli M et al, diabetes was present in 38% of the cases and the mortality rate in heart disease was significantly higher [10]. In the study of Van Stigt et al. the most frequent comorbidity was cardiovascular disease [14].

The disease usually involves anterior abdominal wall (20%), the scrotum (30%) and perineum (50%) [1].

Patients usually have symptoms that manifest as local pain, fever, malaise, hypotension, poor general condition. Tissue swelling, erythema, crepitations, odor, skin necrosis, bullous changes can be seen. What is important is that the visible change of the skin is much smaller than the tissue infection under the skin, so it is necessary to recognize NF

Paper ac

 Copyright © Serbian Medical Society

when the cutaneous changes are small. Mitchell et al. reported that the lower limb was the most frequent site of infection, with 53%, and severe pain (76%) and swelling (83%) were the most common presenting features [15]. Jabbour et al. stated that the lower limb / thigh (53%) was the most frequent site of infection, followed by perineum (25%), and the sacral region had significantly higher frequency in non-survivors [9]. Misiakos et al. stated, the mostly infected site was perineum (46.8%), then lower limbs (35.5%), diabetes mellitus was the most common comorbidity (40.3%) and tenderness and local pain were the most common symptoms [13].

The symptomatology and local indicators of the infection in our cases mainly coincide with the literature data. Both patients were admitted in a serious condition with both local and systemic symptoms. The first patient presented with a history of comorbidity reported only arterial hypertension irregularly treated and untreated perianal fistula and obesity (BMI 37.6). A percussion abscess was present from which the infection may have spread. Patient No 2 was a cardiac patient with a long history of diabetes, on insulin therapy, with signs of diabetic angiopathy and neuropathy. Locally, in the groin region, a skin infection occurred with liquid secretion and unpleasant odor, after shaving, and infection began to spread.

For successful treatment of NF timely diagnosis or suspicion of NF, aggressive resuscitation of the patient, broad spectrum antibiotics administration, and early and radical surgical intervention are essential. A diagnosis is generally based on a clinical presentation. Laboratory tests and radiological imaging have a significant place in the prediction of infection severity and treatment outcome [16, 17, 18]. This is why scoring systems have been developed as predictors of the severity of infection. The Laboratory Risk Indicator for Necrotizing Fasciitis (LRINEC) proposed by Wong et al. is a scoring system designed to differentiate NF from other soft tissue infections [13]. The LRINEC score for the first patient was 11 and 10 for the second patient, which put them in the high-risk group.

 Copyright © Serbian Medical Society

Urgent and radical surgical treatment, with removal of necrotic and devitalized tissue, is mandatory and a major factor for good outcome in patients with NF. The mortality rate can be 9 times greater when primary surgery is performed 24 hours after the onset of symptoms [13]. Several studies stated that all patients underwent 1–10 radical surgical debridement, with an average of 2.5 [1]. HBOT is a useful procedure for some infections, but it has not been proved that it is essential part of the treatment [1].

Both our patients were with a high LRINEC score, probably due to late turning to the surgeon for examination. Radical surgical intervention was done 24 hours after admission in the first case and four hours after admission in the second. In both cases, surgical reinterventions were performed, but in the first case colon surgery (according to Hartman) was necessary due to rectal necrosis. HBOT was used in the first patient, however not in the second because of contraindications. In both cases intensive measures of conservative treatment and intravenous administration of antibiotics were applied. In both cases there was a complete recovery of the patients.

NF continues to be a serious disease with a high mortality rate and challenging diagnosis. Surgeons must be aware of the importance of rapid diagnosis and treatment to prevent mortality.

Conflict of Interests: No conflicts of interest related to this article. We obtained verbal and sign consent of the patients to publish the case report. This article was planned in compliance with the Patient Rights Directive and ethical rules by considering the principles of the Declaration of Helsinki.

Early accepted

 Copyright © Serbian Medical Society

REFERENCES

1. Detanac DS, Detanac DA, Mulić M, Ćeranić MA, Ademović AI. Severe infection of the anterior abdominal wall in a patient with diabetes mellitus: A case report. Medicinski pregled. 2017; 70(7–8):245-8. doi.org/10.2298/MPNS1708245D
2. Urbina T, Hua C, Sbidian E, Bosc R, Tomberli F, Lepeule L et al. Impact of a multidisciplinary care bundle for necrotizing skin and soft tissue infections: a retrospective cohort study. Ann Intensive Care. 2019;9(1):123. doi: 10.1186/s13613-019-0598-4, PMID:31650379
3. Kruppa C, Hutter DJ, Königshausen M, Gessmann J, Schildhauer TA, Coulibaly MO. Necrotizing fasciitis and the midterm outcomes after survival. SAGE Open Med. 2019; 7:2050312119842433. doi: 10.1177/2050312119842433, PMID: 31057795
4. Sorensen MD, Krieger JN. Fournier's Gangrene: Epidemiology and Outcomes in the General US Population. Urol Int. 2016;97(3):249-59. doi: 10.1159/000445695. PMID: 27172977.
5. Eke N. Fournier's gangrene: a review of 1726 cases. Br J Surg. 2000; 87(6): 718-28. doi: 10.1046/j.1365-2168.2000.01497.x, PMID: 10848848
6. Kim T, Park SY, Kwak YG, Jung J, Kim M-C, Choi S-H, et al. Etiology, characteristics, and outcomes of community-onset necrotizing fasciitis in Korea: A multicenter study. PLOS ONE. 2019 ;14(6):e0218668. doi: 10.1371/journal.pone.0218668, PMID: 31220158
7. Louro JM, Albano M, Baltazar J, Vaz M, Diogo C, Ramos S, et al. Fournier's gangrene: 10-year experience of a plastic surgery and burns department at a tertiary hospital. Acta Méd Port. 2019;32(5):368-74. doi: 10.20344/amp.11003, PMID: 31166897
8. Tsai YH, Shen SH, Yang TY, Chen PH, Huang KC, Lee MS. Monomicrobial necrotizing fasciitis caused by Aeromonas hydrophila and Klebsiella pneumoniae. Med Princ Pract. 2015;24(5):416-23. doi: 10.1159/000431094, PMID: 26066555
9. Jabbour G, El-Menyar A, Peralta R, Shaikh N, Abdelrahman H, Mudali IN, et al. Pattern and predictors of mortality in necrotizing fasciitis patients in a single tertiary hospital. World J Emerg Surg. 2016; 11:40. doi: 10.1186/s13017-016-0097-y, PMID: 27508002
10. Tarchouli M, Bounaim A, Essarghini M, Ratbi MB, Belhamidi MS, Bensal A, et al. Analysis of prognostic factors affecting mortality in Fournier's gangrene: A study of 72 cases. Can Urol Assoc J. 2015;9(11-12):E800-4. doi: 10.5489/cuaj.3192, PMID: 26600888
11. Chalya PL, Igenge JZ, Mabula JB, Simbila S. Fournier's gangrene at a tertiary health facility in northwestern Tanzania: a single centre experiences with 84 patients. BMC Res Notes. 2015;8:481. doi: 10.1186/s13104-015-1493-1, PMID: 26416258
12. Schröder A, Gerin A, Firth GB, Hoffmann KS, Grieve A, Oetzmann von Sochaczewski C. A systematic review of necrotising fasciitis in children from its first description in 1930 to 2018. *BMC Infect Dis*. 2019;19(1):317. Erratum in: BMC Infect Dis. 2019;19(1):469. doi: 10.1186/s12879-019-4003-6, PMID: 31132990
13. Misiakos EP, Bagias G, Papadopoulos I, Danias N, Patapis P, Machairas N, et al. Early diagnosis and surgical treatment for necrotizing fasciitis: a multicenter study. Front Surg. 2017;4:5. doi: 10.3389/fsurg.2017.00005, PMID: 28224127
14. van Stigt SF, de Vries J, Bijker JB, Mollen RM, Hekma EJ, Lemson SM, et al. Review of 58 patients with necrotizing fasciitis in the Netherlands. World J Emerg Surg. 2016;11:21. doi: 10.1186/s13017-016-0080-7, PMID: 27239222
15. Mitchell A, Williams A, Dzendrowskyj P. Necrotising fasciitis: an 8.5-year retrospective case review in a New Zealand intensive care unit. Crit Care Resusc. 2011;13(4):232–7. PMID: 22129284
16. Schmitz RP, Brunkhorst FM. Sepsis biomarkers and pathogen detection methods: State of the art. Sanamed. 2014; 9(1):49-61.
17. Huang TY, Tsai YH, Kuo LT, Hsu WH, Hsiao CT, Hung CH, et al Different types of bullae of limbs with necrotizing fasciitis predict different outcome: a prospective study. Infection. 2021;49(1):135-44. doi: 10.1007/s15010-020-01559-5. Epub 2021 Jan 3. PMID: 33389697;PMCID:PMC7851011.
18. Bruun T, Rath E, Madsen MB, Oppegaard O, Nekludov M, Arnell P, et al. Risk factors and predictors of mortality in Streptococcal Necrotizing Soft-tissue Infections: a multicenter prospective study. Clin Infect Dis. 2021;72(2):293-300. doi: 10.1093/cid/ciaa027. PMID: 31923305;PMCID:PMC7840107.

Paper accepted

 Copyright © Serbian Medical Society

Table 1. Laboratory parameters during the hospitalization

Parameters	Patient 1			Patient 2		
	1st day	2nd day	7th day	1st day	2nd day	7th day
Glycemia (mmol/L)	41	20	12	32	24	10
CRP (mg/L)	403.7	397	134	350	305	140
Creatinine (μmol/L)	222	160	103	158	142	122
Urea (mmol/L)	26.8	23	19	24	20	12
Na+ (mmol/L)	135	134	135	135	133	136
WBC (10on9/L)	26	28	16	27	23	15
RBC (10on12/L)	4.08	3.81	3.21	4.34	4.01	3.98
HGB (g/L)	121	114	101	129	123	124

Paper accepted

 Copyright © Serbian Medical Society

Figure 1. Infection of the scrotum and perineum after surgical necrectomy

 Copyright © Serbian Medical Society

Figure 2. At the end of the treatment for patient 1

Paper

 Copyright © Serbian Medical Society

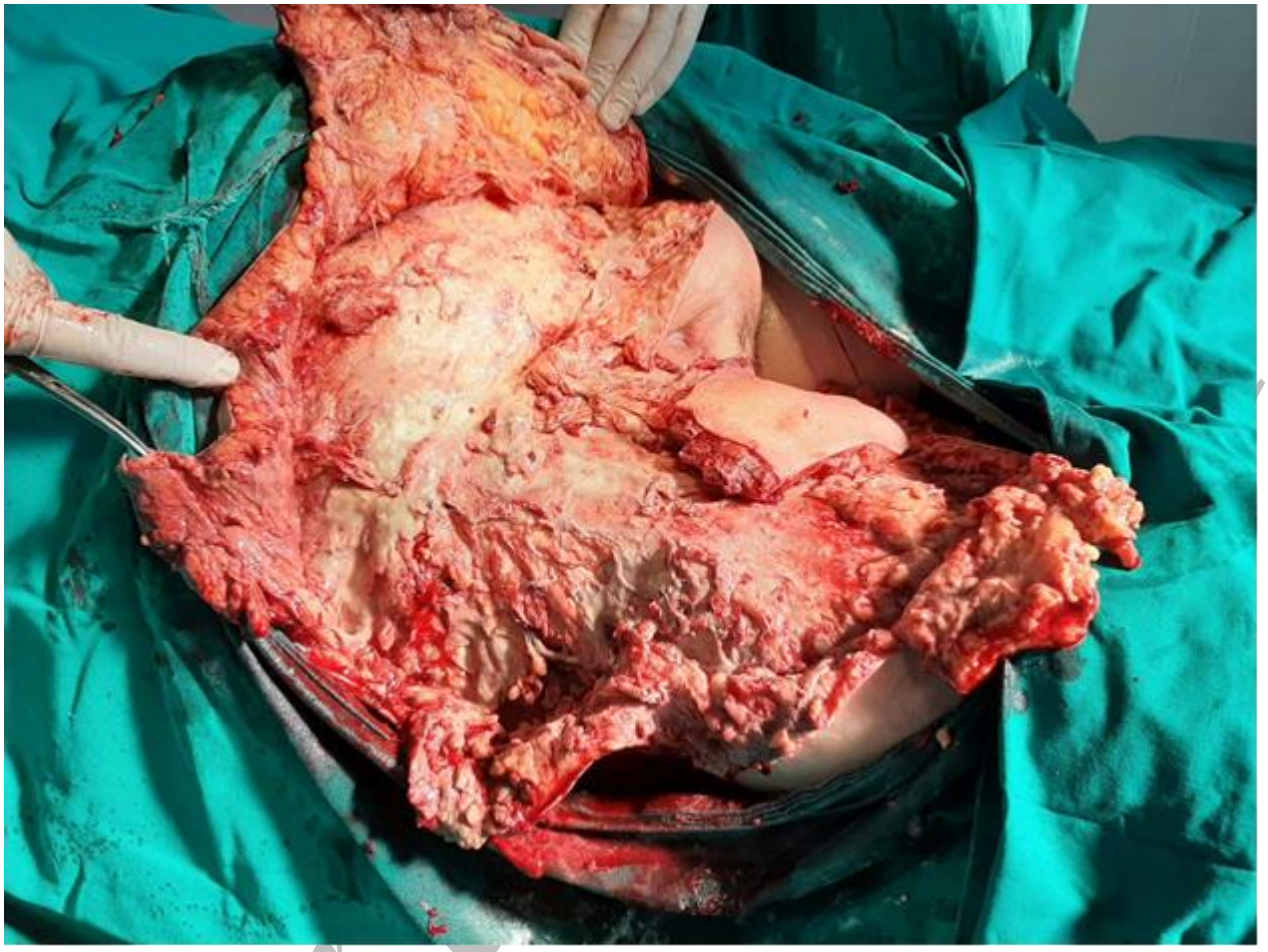

Figure 3. Local status of the infected area in the beginning of the treatment

Paper

 Copyright © Serbian Medical Society

Figure 4. At the end of the treatment for patient 2

Paper

 Copyright © Serbian Medical Society