



СРПСКИ АРХИВ
ЗА ЦЕЛОКУПНО ЛЕКАРСТВО
SERBIAN ARCHIVES
OF MEDICINE

Address: 1 Kraljice Natalije Street, Belgrade 11000, Serbia

+381 11 4092 776, Fax: +381 11 3348 653

E-mail: office@srpskiarhiv.rs, Web address: www.srpskiarhiv.rs

Paper Accepted*

ISSN Online 2406-0895

Case Report / Приказ болесника

Liana Karapetyan¹, Valeriy Svistushkin¹, Ekaterina Diachkova², Svetlana Tarasenko²,
Liudmila Shamanaeva^{3,†}

Multidisciplinary treatment of patients with chronic odontogenic maxillary sinusitis – a case series

Мултидисциплинарно лечење болесника са хроничном одонтогеном
упалом максиларног синуса – прикази болесника

¹Sechenov First Moscow State Medical University, ENT Department, Moscow, Russian Federation;

²Sechenov First Moscow State Medical University, Department of Dental Surgery, Moscow, Russian Federation;

³Sechenov First Moscow State Medical University, Maxillofacial Surgery Department, Moscow, Russian Federation

Received: August 22, 2019

Revised: February 3, 2020

Accepted: February 13, 2020

Online First: February 20, 2020

DOI: <https://doi.org/10.2298/SARH190822012K>

***Accepted papers** are articles in press that have gone through due peer review process and have been accepted for publication by the Editorial Board of the *Serbian Archives of Medicine*. They have not yet been copy-edited and/or formatted in the publication house style, and the text may be changed before the final publication.

Although accepted papers do not yet have all the accompanying bibliographic details available, they can already be cited using the year of online publication and the DOI, as follows: the author's last name and initial of the first name, article title, journal title, online first publication month and year, and the DOI; e.g.: Petrović P, Jovanović J. The title of the article. Srp Arh Celok Lek. Online First, February 2017.

When the final article is assigned to volumes/issues of the journal, the Article in Press version will be removed and the final version will appear in the associated published volumes/issues of the journal. The date the article was made available online first will be carried over.

†**Correspondence to:**

Liudmila SHAMANAeva

Sechenov First Moscow State Medical University, Maxillofacial Surgery Department, Trubetskaya 8/2,
Moscow 119991, Russian Federation

E-mail: shamanaeva@bk.ru

Multidisciplinary treatment of patients with chronic odontogenic maxillary sinusitis – a case series

Мултидисциплинарно лечење болесника са хроничном одонтогеном упалом максиларног синуса – прикази болесника

SUMMARY

Introduction The treatment of chronic odontogenic maxillary sinusitis remains an important problem for medicine due to the presence of numerous available techniques, number of complex surgical approaches, performed by ENT or maxillofacial surgeon or both

This study aims to analyse different methods of treatment of chronic maxillary sinusitis by several specialists for the choice of the optimal treatment technique.

Outline of cases We describe two clinical cases of multidisciplinary treatment of patients with chronic odontogenic maxillary sinusitis with the involvement of different specialists: ENT and maxillofacial surgeon. One patient was treated with endoscopic technique, and other underwent classic open sinusotomy using local tissues and xenogenic collagen membrane for removing of oroantral fistula. For assessment of results before and after treatment, clinical examination and computed tomography were used.

Conclusion According to the results of our study, endoscopic technique is the preferred method of treatment of patients with chronic maxillary sinusitis in the absence of connection with the oral cavity. If oroantral fistula is present, it is necessary to perform open operation by maxillofacial surgeon.

Keywords: chronic odontogenic maxillary sinusitis; surgical treatment; multidisciplinary treatment

САЖЕТАК

Увод Лечење хроничног одонтогеног максиларног синуситиса и даље је важан проблем за медицину због бројних расположивих техника, сложених хируршких приступа, које обављају оториноларинголошки или максилофацијални хирург или обојица.

Циљ ове студије је да се анализирају како различити специјалисти примењују различите методе лечења хроничног максиларног синуситиса како би се начинио избор оптималне технике лечења.

Прикази болесника Описујемо два клиничка случаја мултидисциплинарног лечења пацијената са хроничним одонтогеним максиларним синуситисом уз учешће различитих специјалиста: оториноларинголошког и максилофацијалног хирурга. Један пацијент је лечен ендоскопском техником, а други је подвргнут класичној отвореној синусотомији коришћењем локалних ткива и ксеногене мембране колагена за уклањање ороантралне фистуле. Клинички преглед и компјутеризована томографија коришћени су за процену резултата пре и после лечења.

Закључак Према резултатима наше студије, ендоскопска техника је пожељна метода лечења пацијената са хроничним максиларним синуситисом када није повезан са усном шупљином. Ако постоји ороантрална фистула, потребно је да отворену операцију изведе максилофацијални хирург.

Кључне речи: хронични одонтогени максиларни синуситис; хируршко лечење; мултидисциплинарни третман

INTRODUCTION

Chronic odontogenic sinusitis is a disease that requires the involvement of several specialists in diagnosis and treatment: ENT and maxillofacial and dental surgeon [1, 2]. Moreover, their intervention will depend on the patient's condition and the well-organised collaboration of specialists. In the case of chronic odontogenic sinusitis, both endoscopic sinus sanitation [2,3] and open surgery in the volume of traditional sinusotomy are possible. Treatment of patients with chronic perforated maxillary sinus is complex because of the absence of primary substrate for neo-osteogenesis and the presence of oroantral fistula. The process of healing and tissue regeneration is extremely slow due to persistent microbial contamination. Disease recurrence is frequent which then leads to the need for reoperation and reduction in overall quality of patient life.

There is no one common opinion among specialists on how and who should treat odontogenic maxillary sinusitis, ENT or maxillofacial or oral surgeon. This is one of the reasons why the results are often quite controversial.

To demonstrate our collective work based on Sechenov University, we describe two clinical cases with different modalities of surgical treatment depending on different approach.

The subjects' written consent was obtained, according to the Declaration of Helsinki, and the study has been approved by competent ethics committee (protocols of Local Ethics Committee N8 from May 26, 2014, and N10-12 from October 18, 2012) and conforms to the legal standards. Both patients have given oral and written agreement for using their computed tomography images and medical data.

CASE REPORT #1

Patient D., a 38-year-old woman, was admitted to the clinic of ENT diseases at the Sechenov University with bilateral nasal obstruction, intermittent mucopurulent discharges, mainly from the left side, and intermittent "pulling" pain in the left cheek.

The patient had dental treatment of the left upper jaw about 10 years ago, re-endodontic treatment of 2.5–2.6 teeth, followed by their extraction after 1 year because of exacerbation of chronic apical periodontitis and absence of success after therapeutic dental treatment.

The dental implantation in the area of these teeth was planned. After cone beam computed tomography of the paranasal sinuses, the patient was sent by a surgical dentist to the ENT clinic for the treatment of chronic left-side maxillary sinusitis. During the examination, nasal breathing was difficult through both halves of the nasal cavity and the mucous membrane of the nasal cavity was pink and moist. The nasal septum was deviated in both directions, more to the right with the formation of a crest in the bone and cartilage and compensatory diffuse hypertrophy of the left inferior nasal concha.

At the time of exam, there was no pathological discharge in the nasal cavity. When examining the oral cavity, 2.5 and 2.6 teeth were missing. The remaining ENT findings were normal. Based on the results of the clinical examination and computed tomography (CT), the

patient was diagnosed with chronic left side odontogenic maxillary sinusitis, foreign body of the left maxillary sinus, nasal septum deviation and hypertrophic rhinitis [Figure 1].

In the clinic of ENT diseases at the Sechenov University, the patient underwent septoplasty with a single-step endoscopic operation on the left maxillary sinus with removal of a foreign body and radio wave correction of the conchae under combined endotracheal anaesthesia. The postoperative period was uneventful. On the first day, the operation tampons were removed from the common nasal passages. On the second day, nasal packings were removed from the middle nasal meatus. Nasal and sinus irrigation through the extended natural ostium and applications of the vasoconstrictors were performed.

The patient was discharged on the 4th postoperative day with improvement. Giving the possible presence of postoperative oedema of the mucous membrane of the nasal cavity and the left maxillary sinus, dental implantation was recommended 2–3 months after surgery.

CASE REPORT #2

Patient S., a 21-year-old man, applied to the Sechenov University at the Department of Surgical Dentistry with facial oedema on the right side, and air and food getting from the oral cavity to the nose while eating.

Patient had tooth 1.8 removed before 3 weeks. A week later, he noted the appearance of these symptoms. His doctor at the dental clinic sutured the area of socket of the previously removed tooth 1.8 with a temporary positive effect. A week later, the buccal oedema appeared on the right side of the face and his body temperature rose to 38 degrees Celsius. The patient had again turned to the clinic where antimicrobial therapy was prescribed. His body temperature returned to normal, but the buccal oedema remained.

On the orthopantomogram, prior to the extraction of the tooth 1.8, the root tips were present in the maxillary sinus.

During the examination, swelling of the cheek on the right side was present with skin moderately hyperaemic, gathered in the fold. On palpation, the temperature of this area was higher (or was warmer) compared with the other side. The symptom of fluctuation was negative. Mouth opening was moderately limited to 3.5 cm and painful due to swelling of the

cheek on the right side. Swallowing was free and painless. Palpation marked a moderate increase in size of submandibular lymph nodes, more to the right. Examining the oral cavity, the mucous membrane of the right buccal region was swollen, hyperaemic and painful during palpation and the symptom of fluctuation was positive. When examining the area of a previously removed tooth 1.8, the defect of the alveolar process of the upper jaw was visualised in the retromolar region with a transition to the vestibular side up to 1.5–1.8 cm. The nasal test was positive. Puncturing the line of mucous membrane closure of the right buccal area pus was obtained. Abscess of the buccal region on the right and chronic odontogenic sinusitis with oroantral fistula on the right were diagnosed.

Under conditions of local infiltration and conductive anaesthesia, a purulent focus was reorganised: an opening of the abscess of the right buccal region, wound revision, washing with antiseptics and its drainage. The patient was under dynamic observation and underwent a course of antibacterial therapy. Daily dressing was performed. After condition improving, a course of physiotherapy was performed (magnetic therapy) to reduce swelling of the soft tissues of the buccal region. After 3 weeks (Figure 2), patient underwent sanitation of the sinus through the bone defect area. Plasty of oroantral bone fistula was done with local tissues, buccal flap and collagen xenogenic membrane. The postoperative period was uneventful. During the entire period of dynamic observation of the patient data for recurrent oroantral fistula or exacerbation of chronic sinusitis were not detected.

DISCUSSION

The method of treatment of patients with chronic maxillary sinusitis and oroantral fistula remains very important problem for otorhinolaryngology, maxillofacial and oral surgery.

This chronic sinusitis usually has odontogenic nature and is frequently iatrogenic. For example, Philipsen et al. [4] reported odontogenic cause of chronic sinusitis in 4.7% cases of 788 patients after treatment in dental clinics. Tooth extraction is the most common dental procedure that leads to sinusitis, in approximately 30%. The most common reason of perforated form of sinusitis during recent years was the open sinus lifting. Surgeons can damage Schneider membrane during detachment, thus leaving connection of maxillary sinus

with oral cavity in most severe cases. According to literature, the rate of similar situation is not less than 30%.

Due to the complex character of chronic odontogenic maxillary sinusitis (COMS), the surgical treatment requires multidisciplinary approach. There is no method that could be considered the standard of treatment for chronic maxillary sinusitis. Endoscopic surgical techniques promote the transition from extensive type of surgery to minimally invasive. Endoscopic approach allows saving important anatomical structures of the operated area and maintaining physiological function in maxillary sinus in the postoperative period [5].

During recognised odontogenic nature of maxillary sinusitis (MS) and the absence of the signs of acute inflammation, there is an opportunity for the primary endodontic preparation of canals followed by endoscopic sanitation of maxillary sinus (MS) by ENT. On other cases, when tooth roots do not penetrate mucous membrane of MS, maxillofacial surgeon (or dental surgeon) can work in collaboration with the ENT during one procedure. The first doctor performs tooth extraction, while the second removes changed mucous membrane of MS and foreign bodies. However, endoscopic treatment has its own limits associated with the angle of working instruments and endoscopes. This problem can be solved with changing the approach from transnasal to microsurgical intraoral approach under the upper lip.

For example, Karpischenko et al. [6] presented a case report of surgical treatment in a patient with exacerbation of chronic maxillary sinusitis. Due to multiple previous surgeries (two endoscopic surgeries and one radical sinusotomy of the left MS) 3D CT of paranasal sinuses presented multiple cells with abnormal contents, front wall sinus defect and scar retractions. The complex anatomy of the MS forced the authors to use electromagnetic navigation system during the surgical treatment of the patient. This device allowed the assessment of the sinus anatomy and adjacent structures and adequate surgical opening of all sinus cells. Control 3D reconstruction of CT scan of paranasal sinuses, all cells of MS on the side of operation were not damaged [6].

The more difficult case for surgical treatment is the partial location of the upper third molar in oral cavity where there isn't enough soft tissue to provide good impermeability of the surgical wound. This could lead to perforation after tooth extraction and then formation of oroantral fistula. Dental and maxillofacial surgeons must be prepared for these situations and

have available different additional instruments, suture and osteoplastic or barrier materials to prevent formation of oroantral fistula.

The difficulties of using different techniques for closing of acute perforation after tooth extraction are connected with wide spreading of microorganism in oral cavity and easy migration through the surgical wound to MS. Appearance of area inflammation, especially in the zone of intraoperative bleeding with later formation of hematoma, leads to development of acute maxillary sinusitis in postoperative period. The presence of microorganism increases the risk of suture failure and the inability of secondary wound healing during persistent infection. Thus, methods and materials for closing of acute perforation of MS and oroantral fistula should be chosen very carefully.

There are various techniques of repairing odontogenic perforations of the bottom of the MS using mucosal flap from the palatine and the vestibule side of the oral cavity, flaps from the lateral surface of the tongue, the mucous membrane of the cheek and the nasal cavity. All of them have their advantages and disadvantages and require further investigations.

Thus, the issue of treating patients with chronic odontogenic sinusitis remains open due to a rather large number of conditions for selecting a leading specialist. With COMS with a foreign body present, if the sinus anatomy is preserved and there is no communication with the oral cavity, it is preferable to conduct endoscopic sanitation of the MS by ENT specialist. In the presence of an oroantral fistula, additional involvement of the maxillofacial surgeon or dental surgeon by the ENT specialist is necessary to conduct a full-fledged sinusotomy and to perform reconstructive techniques using osteoplastic materials and flaps.

ACKNOWLEDGEMENT

The paper was supported by the “Russian Academic Excellence Project 5-100.”

Conflict of interest: None declared.

REFERENCES

1. Horowitz G., Koren I., Carmel N.N., Balaban S., Abu-Ghanem S., Fliss D.M., Kleinman S., Reiser V. One stagecombined endoscopic and per-oral buccal fat pad approach for large oro-antral-fistula closure with secondary chronic maxillary sinusitis. *Refu'at Ha-pehVehashinayim*. 2015; 32(3): 32-7, 68 PMID: 26548148
2. Naros A, Peters JP, Biegner T, Weise H, Krimmel M, Reinert S. Fungus Ball of the Maxillary Sinus-Modern Treatment by Osteoplastic Approach and Functional Endoscopic Sinus Surgery. *J Oral Maxillofac Surg*. 2019 Mar;77(3):546-554. doi: 10.1016/j.joms.2018.10.010. PMID: 30448431
3. Lopatin AS., Sysolyatin SP, Sysolyatin PG, Melnikov MN. Chronic maxillary sinusitis of dental origin: is external surgical approach mandatory? *Laryngoscope*. 2002 Jun;112(6):1056-9. PMID: 12160273 DOI: 10.1097/00005537-200206000-00022
4. Philipsen, B. B., Ghawsi, S., & Kjeldsen, A. D. Odontogenic sinusitis among patients surgically treated for maxillary sinus disease. *Rhinology Online*. 2018; 1: 60-66. DOI: 10.4193/RHINOL/18.004
5. Vishnyakov V., Yalymova D. Surgical treatment for chronic odontogenic maxillary sinusitis and posttreatment assessment of quality of life in patients. *Vrach*. 2015; 7: 78-80
6. Karpischenko S.A., Bolozneva E.V., Baranskaya S.V. Recurrent sinusitis and revision surgery in a patient with a multicells maxillary sinus. *Folia otorhinolaryngologiae et pathologiaerespiratoriae*. 2015; 21 (4): 41-46

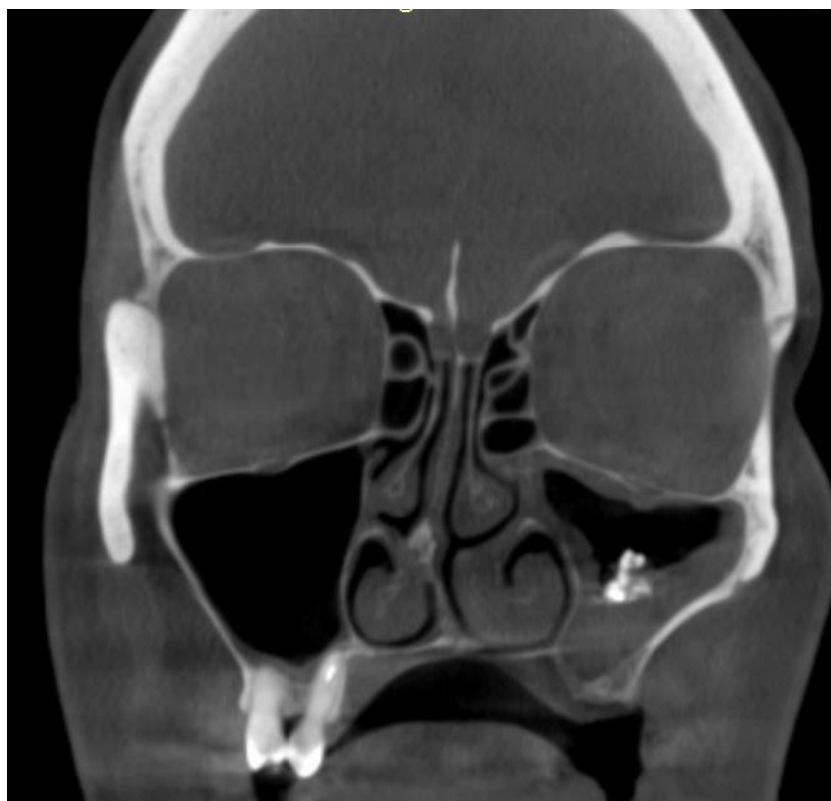


Figure 1. Patient D.; cone beam computed tomography of paranasal sinuses before surgery; the crest of the nasal septum, the decrease in pneumatization of the left maxillary sinus and the shadow of high density in the middle sections of the sinus (filling material and dense fungal inclusions) are determined

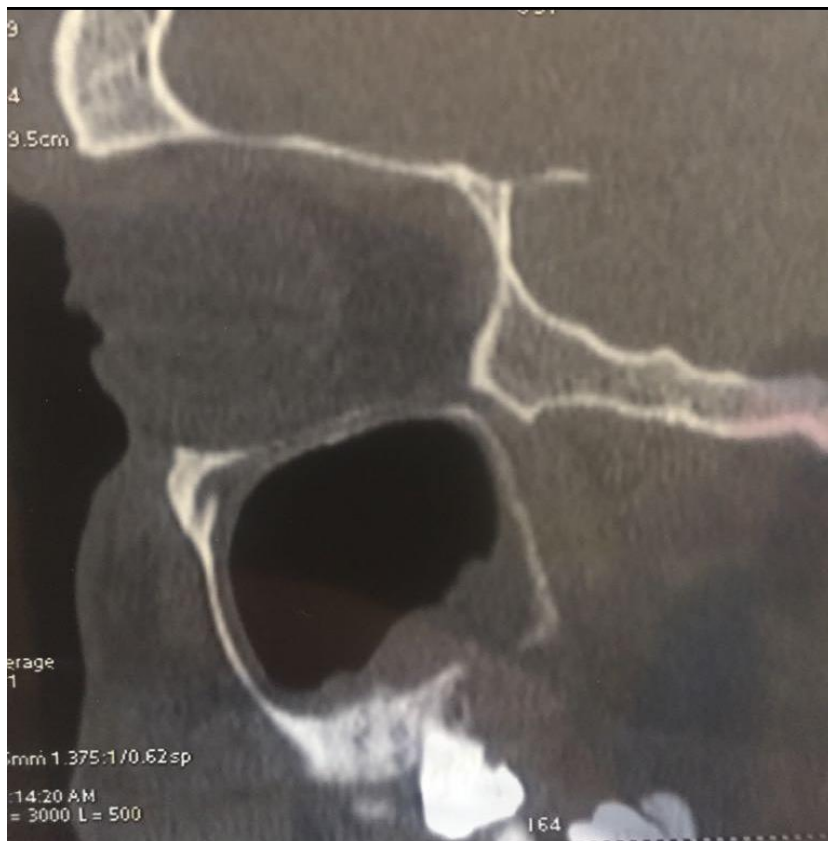

Figure 2. Computed tomogram of patient S; before surgery: the defect of the alveolar process of the right upper jaw, the fistula of the right maxillary sinus with the oral cavity, and thickening of the sinus mucosa are visualised