



**СРПСКИ АРХИВ**  
ЗА ЦЕЛОКУПНО ЛЕКАРСТВО  
**SERBIAN ARCHIVES**  
OF MEDICINE

Address: 1 Kraljice Natalije Street, Belgrade 11000, Serbia

+381 11 4092 776, Fax: +381 11 3348 653

E-mail: [office@srpskiarhiv.rs](mailto:office@srpskiarhiv.rs), Web address: [www.srpskiarhiv.rs](http://www.srpskiarhiv.rs)

**Paper Accepted\***

**ISSN Online 2406-0895**

**Original Article / Оригинални рад**

Braca Kundalić<sup>1,\*</sup>, Branka Marković<sup>2</sup>, Milan Mitković<sup>3,4</sup>, Slađana Ugrenović<sup>1</sup>,  
Ivan Jovanović<sup>1</sup>, Jovana Čukuranić Kokoris<sup>1</sup>, Ivana Graovac<sup>1</sup>, Rade Čukuranić<sup>1</sup>

**Olecranon aperture of the humerus: a morphometrical study**

Отвор лактичног наставка на раменици: морфометријска студија

<sup>1</sup>University of Niš, Faculty of Medicine, Department of Anatomy, Niš, Serbia;

<sup>2</sup>University of Belgrade, Faculty of Sport and Physical Education, Belgrade, Serbia;

<sup>3</sup>University of Niš, Faculty of Medicine, Department of Surgery, Niš, Serbia;

<sup>4</sup>University Clinical Center of Niš, Clinic for Orthopedics and Traumatology, Niš, Serbia

**Received: February 9, 2021**

**Revised: March 8, 2021**

**Accepted: March 9, 2021**

**Online First: March 11, 2021**

**DOI: <https://doi.org/10.2298/SARH210209011K>**

\***Accepted papers** are articles in press that have gone through due peer review process and have been accepted for publication by the Editorial Board of the *Serbian Archives of Medicine*. They have not yet been copy-edited and/or formatted in the publication house style, and the text may be changed before the final publication.

Although accepted papers do not yet have all the accompanying bibliographic details available, they can already be cited using the year of online publication and the DOI, as follows: the author's last name and initial of the first name, article title, journal title, online first publication month and year, and the DOI; e.g.: Petrović P, Jovanović J. The title of the article. *Srp Arh Celok Lek*. Online First, February 2017.

When the final article is assigned to volumes/issues of the journal, the Article in Press version will be removed and the final version will appear in the associated published volumes/issues of the journal. The date the article was made available online first will be carried over.

**\*Correspondence to:**

Braca KUNDALIĆ

Faculty of Medicine, Department of Anatomy,

Bulevar dr Zorana Đinđića 81, 18000 Niš, Serbia

[braca.kundalic@medfak.ni.ac.rs](mailto:braca.kundalic@medfak.ni.ac.rs)

## Olecranon aperture of the humerus: a morphometrical study

### Отвор лактичног наставка на раменици: морфометријска студија

#### SUMMARY

**Introduction/Objective** Olecranon aperture is a variable opening in the septum between the olecranon and coronoid fossae. Its frequency varies largely in different populations and knowledge of its presence may have clinical implications.

The objective of our study was to determine its prevalence in a sample of Serbian population and to investigate its morphology and morphometrical features, as well as its relation to the distal end of humerus.

**Methods** A material used were 70 human dry humeri from the bone collection of the Department of Anatomy, Faculty of Medicine, University of Niš. We analyzed the presence, shape, transverse and vertical diameter of the aperture, its distance to the tips of the epicondyles from medial (MB) and lateral border (LB), as well as the distance between epicondyles (EW) and translucency of the septum in the bones with no aperture. Vernier caliper was used for measurements of the diameters and distances.

**Results** Eight olecranon aperture were observed in seven bones (10%), seven on the left and one on the right side. Half of them were oval-shaped, while round, triangular, and irregular shape were found. Translucent septum in humeri with no aperture was present in 67.1% of the sample. There were no significant differences between MB and LB, neither between EW in bones with aperture and with septum.

**Conclusion** Our study presented the rare data about the frequency of olecranon aperture in Serbian population, suggesting that robusticity of the humerus is not related to the presence of the olecranon aperture.

**Keywords:** human anatomy, anthropology, supratrochlear foramen, septal aperture, fracture

#### САЖЕТАК

**Увод/Циљ** Отвор лактичног наставка је варијабил-ни отвор на прегради која раздваја јаму лактичног наставка и венчасту јаму раменице. Његово при-суство веома варира у различитим популацијама и познавање његовог присуства може бити од клиничког значаја.

Као циљ је постављено одређивање преваленце овог отвора на узорку српске популације, испитивање његове морфологије и морфометријских параметара, као и његовог односа према структурама доњег крајка раменице.

**Метод** Као материјал је коришћено 70 људских раменица из остеолошке колекције Катедре за анатомију Медицинског факултета Универзитета у Нишу. Анализирали смо присуство и облик отвора, његов попречни и вертикални пречник, растојање унутрашње (УР) и спољашње ивице (СР) отвора у односу на одговарајући чвор раменице (ЧР) као и рас-тојање између чворова раменице (ЧР) и провидно-ст преграде на костима без отвора. За мерење је коришћен нонијус.

**Резултати** Осам отвора је било присутно на седам костију (10%), од тога седам на левој и једна на десној страни. Половина отвора је била овалног облика, док су остали били округлог, троугластог и неправилног облика. Провидна преграда на кости-ма без отвора је забележена на 67,1% узорка. Није забележена значајна разлика између УР и СР, као ни између ЧР на костима са и без отвора.

**Закључак** Наше истраживање пружа ретке податке о заступљености и морфометријским карактери-стикама отвора лактичног наставка у српској популацији, указујући да робусност раменице није повезана са присуством овог отвора.

**Кључне речи:** анатомија човека, антропологија, супратрохлеарни отвор, септални отвор, фрактура

## INTRODUCTION

The coronoid fossa and the olecranon fossa of the distal epiphysis of humerus are separated by a thin bony septum which may occasionally be perforated, thus forming the variable opening [1, 2]. This inconstant perforation is commonly known as “septal aperture” [3, 4, 5], “olecranon aperture” [2], “olecranon foramen” [6], “supratrochlear aperture” [7, 8] or “supratrochlear foramen” [1, 9, 10], the last one being a term proposed to be incorporated into the Terminologia Anatomica [11], but it has not been added to its Second Edition which is

pending approval. Recent studies suggested that this opening should be considered aperture, not foramen [2, 8]. Foramen is rather a conduit for the passage of neurovascular elements, while aperture represents an opening in the bone [8]. Therefore, it is recently suggested that this anatomical variant is labelled as “olecranon aperture” [2], considering the fact that it is not giving passage to any anatomical structure. We also found this term more precise, due to relation of the aperture to the olecranon, as well as being more distinctive than “supratrochlear” one, which may be mistaken for the elements located on the frontal bone.

The incidence of the olecranon aperture of the humerus (OAH) among humans is highly variable and ranges from 0.3 to 58% in different populations [8]. The literature data shows substantial discrepancies between various human subpopulations and ethnicities, which varies from around 11% in European populations, the lowest regional prevalence according to the large meta-analysis [2, 12], to 58% in Native Americans from Arkansas, USA [8].

The thin lamina is present until the age of 7 years old, after which the bony septum may be absorbed and substituted by dense regular connective tissue [8]. The aperture is showed to be more frequent in women, on the left side [13]. There are many hypotheses on the origin of the OAH, based on mechanical features, robusticity, metabolic factors, genetics, and atavistic traits; yet none has offered an explanation plausible or convincing enough.

The olecranon aperture is a nonmetrical skeletal trait important in anthropology, which may be important for investigating familiar inheritance, whereas its analysis in medicine may find application in radiology and orthopedic surgery [5]. To the best of our knowledge, the only data reported within the area of Republic of Serbia is one archeological case, a skeleton from 4<sup>th</sup>-6<sup>th</sup> century (date estimated), excavated in Kikinda, with bilateral aperture found [10]. Therefore, this study aimed to determine the incidence of the OAH in a sample of Serbian population, as well as morphometric characteristics of the aperture in relation to its size, shape, and distance to the epicondyles, and to assess the relation between the epicondylar width, as a measure of bone size, and presence of the OAH.

## **METHODS**

The study included 70 bilateral dry humeri of unknown age and sex from the osteological collection of the Department of Anatomy, Faculty of Medicine, University of Niš, Serbia. The research is done in accord with the standards of the local ethics committee. The bones chosen for sample group were with no pathological changes and ante- or post mortem fractures. Bone healing features, such as a callus, indicated premortem

trauma, while sharp borders or surfaces were used to identify postmortem damage. With help of transmitted light from posterior to anterior, we analyzed the opacity and translucency of the bony septum in the bones with no OAH detected (Fig. 1), and determined presence and shape of the OAH, where applicable (Fig. 2). Vernier caliper with a scale division of 0.02 mm was used to measure the transverse (TD) and vertical diameter (VD), the distance of the medial epicondyle to the medial border of the OAH (MB), distance of the lateral epicondyle to the lateral border of the OAH (LB), and the epicondylar width (EW). The two observers took measurement three times independent of each other and the mean measurement was used. The epicondylar width was statistically compared between bones with and without the OAH. Student's t-test and descriptive statistics (mean, standard deviation, minimum and maximum value) were obtained using the SPSS 20.0 software.

## RESULTS

In the sample of 70 bones the olecranon aperture was detected in 7 humeri (10%). There were two apertures observed in one bone, which makes total of 8 measured OAH. Seven apertures were present on the left side, and only one case on the right side. The most common shape of the OAH was oval (4). We also noticed 2 round apertures, one triangular and one irregularly shaped OAH. The translucent septum was found in 47 humeri (67.1%), 28 on the left side, and 19 on the right side. The opaque septum was detected in 16 bones (22.9%), 8 on each side (Table 1).

Mean transverse diameter (TD) of the OAH was  $5.25 \pm 3.62$  mm and mean vertical diameter (VD) was  $3.33 \pm 1.93$  mm. Average distance of the medial epicondyle to the medial border of the OAH (MB) was  $26.92 \pm 5.03$  mm, while average distance from the lateral epicondyle to the lateral margin of the aperture (LB) was  $29.59 \pm 4.22$  mm, but not significantly larger ( $P = 0.13$ ; threshold of significance 0.05) (Table 2).

Mean epicondylar width (EW) in the bones with OAH present was  $58.97 \pm 5.53$  mm, which was not statistically different ( $P = 0.08$ ; threshold of significance 0.05) from average epicondylar width in the bones with no aperture ( $61.03 \pm 3.20$  mm) (Table 2).

## DISCUSSION

The debate in literature about the name of this opening between the olecranon and coronoid fossae of the humerus is whether it is an aperture or a foramen. It is reported that *in vivo* it is occupied by connective tissue which is not perforated by any nerve or blood vessel. Most studies were performed on cadaveric and archeological human remains, which are subjected to maceration and decomposition of softer tissues [8]

respectively, which misled earlier investigators to consider it constantly open and consequently name it as a foramen.

Meta-analysis showed that the overall pooled prevalence of the OAH was 21.9%, with studies conducted in African populations reporting the highest prevalence (31%). Data reported on the samples located in or descending from Europe had the lowest prevalence (11.1%) [2]. Table 3 shows frequencies in different populations all over the world, where the samples of Greek population strangely present minimum and maximum prevalence (0.3-21.6%). The results of our study (10%) are within a range expected for European populations, although more extensive sample would offer more information if the prevalence leans to lower numbers, such as medieval Slavic Polish population and neighboring Romanian one, or higher frequencies, such as Greek and Turkish groups, particularly along with analyzing population affinity and migrations [5] which were largely present in the history of our area.

We found the OAH to be dominant on the left humeri, which is in concordance with statistically significant difference shown in forty-one studies [2]. There are reports with the right side being more frequent [19] or bilateral compared to the left side [12]. Majority of the OAH found were oval, then round, and one triangular and irregular each. These findings and proportions strengthen earlier reports [2, 15, 19, 20], although some unusual shapes were also reported, such as sieve-like, rectangular or reniform [6, 18]. The female samples are usually shown as being more predilected for the OAH presence [1, 2, 5, 6, 13], and even slightly higher frequency in males is a rare finding [4].

The bones with no septum perforated were investigated for its translucency. Our results (67.1% translucent vs. 22.9% opaque) are among the ranges presented in the literature [7]. High frequency of the translucent septa in the present study may suggest higher probability of developing olecranon aperture present in the population, which should be investigated in a larger and more representative sample.

The size of the aperture seems to differ in various populations. Results by Turkish researchers presented the largest transverse diameter (average  $6.09 \pm 2.43$  mm and  $6.7 \pm 2.20$  mm in right male humeri [7, 9], as well as in Nigerian population ( $6.82 \pm 2.92$  mm in left side bones) [18], while the smallest ones are found in Chinese (mean  $3.26 \pm 1.15$  mm in right humeri) [15] and Brazilian cases (average  $2.33 \pm 1.23$  mm in left side samples) [1]. Smaller apertures in latter study are believed to be due to the heterogeneity of Brazilian population as a consequence of mixing native people with the colonizing and immigrating nations [1]. In our study, mean TD was  $5.25 \pm 3.62$  mm, which is similar to another Turkish study ( $5.23 \pm 3.74$  mm in right humeri,  $4.80 \pm 2.65$  mm in left humeri) [20], and in a range with the pooled results on 1086 bones ( $5.06 \pm 1.08$  mm,  $5.45 \pm 1.31$  mm,

for the right and left sides, respectively), with no significant difference shown between the right and left sides [2]. The only literature data from our country are from excavated remains dated from 4<sup>th</sup>-6<sup>th</sup> century where the transverse diameter was 18 mm on the right side, and 11 mm on the left side [10], which partially corresponds to our maximum value found in the left humerus (11.96 mm), as well as to the only finding within the recent bone material (10.4 mm), presented in the tabular literature data comparison [7]. This ancient material measurement may be also compared to the study on the medieval skeleton materials in England, where the values were up to 21 mm [3].

Mean vertical diameter in our research was  $3.33 \pm 1.93$  mm, which is smaller than pooled results ( $4.09 \pm 0.86$  mm on the right,  $4.43 \pm 0.83$  mm on the left side) and majority of the reported data ( $4.86 \pm 1.32$  mm;  $4.21 \pm 1.29$  mm;  $3.81 \pm 0.97$  mm) [7, 19, 20], only to be compared to the right male humeri ( $3.27 \pm 1.46$  mm) in Portuguese population [13], left side bones in Indian sample ( $3.37 \pm 1.25$  mm) [6] and right apertures in Nigerian group ( $3.33 \pm 1.04$  mm) [18].

The distance between the borders of the aperture and the tips of the epicondyles is suggested in the literature to determine the position of the OAH. Our results (MB  $26.92 \pm 5.03$  mm, LB  $29.59 \pm 4.22$  mm) indicate that the apertures in our study were more medially located, but the difference was not statistically significant ( $P = 0.13$ ). Other researchers have also observed the OAH to be positioned nearer to the medial epicondyle [7, 9, 16, 19]. South African study on several ethnic groups reported that the population group with the largest TD had significantly smaller MB and LB compared to the other investigated groups, which was speculated to be due to the smallest epicondylar breadth, as a feature of size and robustness, supporting the findings that the OAH is more prevalent on the left and among females [16]. Therefore, we included the epicondylar width (EW) in our morphometrical analysis and compared the bones with or without septum, to check if there is any significant relation between the width of the distal epiphysis and the presence of the aperture, as already reported [5]. Mean EW in the bones with the OAH in present study was  $58.97 \pm 5.53$  mm, which was not significantly smaller than in bones with the septum ( $61.03 \pm 3.20$  mm), so our data, supported by other researchers too [3, 13], could not provide evidence that olecranon aperture is more frequent in gracile bones, thus not being in accordance with the robusticity hypothesis of the origin of the olecranon aperture.

Prior knowledge of anatomical variants may have an importance in clinical practice, as it may be an unpleasant finding during a diagnostic or therapeutic procedure [21]. Radiologists and orthopedists could misinterpret the aperture as a lytic or cystic lesion, due to a relative radiolucency [1]. Assessment of the range of motion in the joint is a common method in physiotherapy to estimate a grade of an impairment [22]. Previous

studies reported that individuals with the OAH might present overextension in lax and very mobile elbow joint [1]. This hyperextension may be accounted on increased elasticity of the collagen fibers [13] or weaker triceps [23], but not on the size of the proximal ulna [13], as well as not on the strength of brachialis, which may indicate a supposed dominant role of the olecranon process in the OAH formation [23].

There was suggested that the presence of this aperture is associated with a narrow and short medullary canal of the humerus [24] thus may having the influence in the choice of adequate surgical procedure, although a recent study found no relation between the OAH presence and the width of the medullary canal [25]. Sahajpal and Pichora [26] suggested that an olecranon aperture might act as a stress riser in healthy humerus thus leading to an atypical fracture-in low energy injuries. Furthermore, increased stress may modify the fracture pattern of the distal humerus. Therefore, knowledge on the frequency and causes of the OAH may alter surgical plan in patients with this anatomic finding [13, 26].

Supracondylar fractures are among the most common elbow fracture in pediatric patients [27] where the intramedullary fixation is commonly indicated as a surgical treatment. Nevertheless, the entry point for intramedullary pin insertion is controversy in patients with the presence of the OAH in order to avoid the bone damage and the pin incarceration [1]. Antegrade insertion of intramedullary pins is suggested to have lower intraoperative and postoperative fracture potential [28] thus to be safer approach in relation to retrograde medullary nailing [9, 29].

The knowledge about OAH could have an importance in later studies about defining the safe zones for screw insertion in distal humeral fractures internal fixation [30]. There could be defined the minimal suggested distance between the screw and the border of the OAH during the intraoperative X-ray checks thus avoiding the threads to pass out of the cortical bone.

The anatomical finding of OAH could also have an impact in later elbow joint endoprosthesis constructions, suggesting that the hole of the prosthesis component may not have to be avoided in a position analog to the OAH anatomic position.

## CONCLUSION

The results of our study presented the frequency and morphometrical features of the variable olecranon aperture of the humerus. The prevalence of 10% is comparable to other populations and indicates that the knowledge of this variable opening should not be neglected in preoperative planning and choosing an adequate surgical approach, as well as in interpretation of radiological findings. Our morphometric analysis found no

relation between the presence of the olecranon aperture and robusticity of the humerus. In addition, our data contribute to the recent morphological, biomechanical, forensic, and anthropological studies, although etiological factors regarding this anatomical variant still remain uncertain.

#### **ACKNOWLEDGMENTS**

This work was supported by the grants of the Ministry of Education, Science and Technological Development of the Republic of Serbia (Grants No. 41018 and No. 43012), and of the Faculty of Medicine of the University of Niš (Grant No. 38/20).

**Conflict of interest:** None declared

Paper  
accepted



## REFERENCES

1. Chagas CA, Gutfiten-Schlesinger G, Leite TF, Pires LA, Silva JG. Anatomical and Radiological Aspects of the Supratrochlear Foramen in Brazilians. *J Clin Diagn Res.* 2016;10(9):AC10–3. (DOI: 10.7860/JCDR/2016/21846.8503; PMID: 27790415)
2. Pires LAS, Leite TFO, Fonseca Junior A, Babinski MA, Chagas CAA. The olecranon aperture of the humerus: a meta-analysis with anthropological and clinical discussion. *Homo.* 2019;70(1):75–84. (DOI: 10.1127/homo/2019/1025; PMID: 31475286)
3. Mays S. Septal aperture of the humerus in a mediaeval human skeletal population. *Am J Phys Anthropol.* 2008;136:432–40. (DOI: 10.1002/ajpa.20826; PMID: 18350584)
4. Myszka A. Septal aperture aetiology: still more questions than answers. *Folia Morphol (Warsz).* 2015;74(2):219–24. (DOI: 10.5603/FM.2015.0034; PMID: 26050810)
5. Kubicka AM, Myszka A, Piontek J. Geometric morphometrics: does the appearance of the septal aperture depend on the shape of ulnar processes? *Anat Rec (Hoboken).* 2015;298(12):2030–8. (DOI: 10.1002/ar.23272; PMID: 26402574)
6. Mathew AJ, Gopidas GS, Sukumaran TT. A Study of the Supratrochlear Foramen of the Humerus: Anatomical and Clinical Perspective. *J Clin Diagn Res.* 2016;10(2):AC05–8. (DOI: 10.7860/JCDR/2016/17893.7237; PMID: 27042437)
7. Bahşi İ. An Anatomic Study of the Supratrochlear Foramen of the Humerus and Review of the Literature. *Eur J Ther.* 2019;25(4):295–303. (DOI: 10.5152/EurJTher.2019.18026)
8. Ndou R, Pillay S, Schepartz LA. Characterization of the tissue crossing the supratrochlear aperture of the humerus using histochemical techniques. *Surg Radiol Anat.* 2018;40(12):1371–7. (DOI: 10.1007/s00276-018-2103-4; PMID: 30191286)
9. Erdogmus S, Guler M, Eroglu S, Duran N. The importance of the supratrochlear foramen of the humerus in humans: an anatomical study. *Med Sci Monit.* 2014;20:2643–50. (DOI: 10.12659/MSM.892074; PMID: 25515544)
10. Šarkić N, Milašinović L. A case of artificial cranial deformation from Kikinda (migration period). *Journal of Serbian Archaeological Society.* 2018;34:315–33.
11. Kachlik D, Musil V, Baca V. Contribution to the anatomical nomenclature concerning upper limb anatomy. *Surg Radiol Anat.* 2017;39(4):405–17. (DOI: 10.1007/s00276-016-1749-z; PMID: 27646642)
12. Koyun N, Aydinlioğlu A, Gümrukçüoğlu FN. Aperture in coronoid-olecranon septum: A radiological evaluation. *Indian J Orthop.* 2011;45(5):392–5. (DOI: 10.4103/0019-5413.83945; PMID: 21886918)
13. Bradshaw R, Eliopoulos C, Borrini M. Septal Aperture of the Humerus: Etiology and Frequency Rates in Two European Populations. *Anat Rec (Hoboken).* 2020;303(7):1821–30. (DOI: 10.1002/ar.24290; PMID: 31604362)
14. Varlam H, St Antohe D, Chistol RO. Le processus sus-condylien et le foramen sus-trochleen de l'humerus. Etude comparative et anatomo-clinique [Supracondylar process and supratrochlear foramen of the humerus: a case report and a review of the literature]. *Morphologie.* 2005;89(286):121–5. (DOI: 10.1016/s1286-0115(05)83248-5; PMID: 16444940)
15. Li J, Mao Q, Li W, Li X. An anatomical study of the supratrochlear foramen of the Jining population. *Turk J Med Sci.* 2015;45(6):1369–73. (DOI: 10.3906/sag-1407-44; PMID: 26775396)
16. Ndou R, Smith P, Gemell R, Mohatla O. The supratrochlear foramen of the humerus in a South African dry bone sample. *Clin Anat.* 2013;26(7):870–4. (DOI: 10.1002/ca.22132; PMID: 22855439)
17. Sablan AH, Calmon M. Supratrochlear foramen frequency in three Iraqi populations. *Forensic Science International: Reports.* 2020;2:100107. (DOI: 10.1016/j.fsir.2020.100107)
18. Sunday OO, Olusegun OS, Oluwabunmi BM. The supratrochlear foramen of the humerus: implications for intramedullary nailing in distal humerus. *J Biol Agric Healthc.* 2014;4(7):136–9.
19. Nayak SR, Das S, Krishnamurthy A et al: Supratrochlear foramen of the humerus: An anatomico-radiological study with clinical implications. *Ups J Med Sci.* 2009;114(2):90–4. (DOI: 10.1080/03009730802688819; PMID: 19396695)
20. Aydin Kabakci AD, Buyukmumcu MU, Yilmaz MT, Cicekcibasi AE, Akın D, Cihan E. An Osteometric Study on Humerus. *Int J Morphol.* 2017;35(1):219–26. (DOI: 10.4067/S0717-95022017000100036)
21. Kachlik D, Varga I, Bácsa V, Musil V. Variant Anatomy and Its Terminology. *Medicina (Kaunas).* 2020;56(12):713. (DOI: 10.3390/medicina56120713; PMID: 33353179)
22. Ndou R. The significance of the supratrochlear aperture (STA) in elbow range of motion: an anatomical study. *Anat Sci Int.* 2018;93(1):88–97. (DOI: 10.1007/s12565-016-0376-4; PMID: 27730491)
23. Myszka A, Kubicka AM, Tomczyk J. The mechanical hypothesis of septal aperture formation tested in an early medieval population from Ostrów Lednicki (Poland). *J Anat.* 2019;234(3):368–75. (DOI: 10.1111/joa.12933; PMID: 30628059)

24. Akpınar F, Aydinlioglu A, Tosun N, Dogan A, Tuncay I, Unal O. A morphometric study on the humerus for intramedullary fixation. *Tohoku J Exp Med.* 2003;199:35–42. (DOI: 10.1620/tjem.199.35; PMID: 12688558)
25. Ndou R, Maharaj S, Schepartz LA. A radiographic investigation of the relationships between humeral cortical bone thickness, medullary canal width and the supratrochlear aperture (STA). *Surg Radiol Anat.* 2017;39(1):57–68. (DOI: 10.1007/s00276-016-1701-2; PMID: 27241519)
26. Sahajpal DT, Pichora D. Septal aperture: an anatomic variant predisposing to bilateral low-energy fractures of the distal humerus. *Can J Surg.* 2006;49(5):363–4. (PMID: 17152577)
27. Rashid MS, Dorman S, Humphry S; POTS study collaborators. Management of acute paediatric fractures treated surgically in the UK: a cross-sectional study. *Ann R Coll Surg Engl.* 2021. (DOI: 10.1308/rcsann.2020.7035; PMID: 33682433)
28. Antoni M, Lazarus P, Kempf JF, Clavert P. Arthroscopic intramedullary nailing of humeral fractures through the rotator interval. *Orthop Traumatol Surg Res.* 2021;107(1):102750. (DOI: 10.1016/j.otsr.2020.102750; PMID: 33321228)
29. Schwarz GM, Zak L, Hirtler L, Wozasek GE. Anatomical Considerations of Intramedullary Humeral Nailing and Lengthening. *J Clin Med.* 2020;9(3):806. (DOI: 10.3390/jcm9030806; PMID: 32188086)
30. Hara A, Kudo T, Ichihara S, Iwase H, Nagao M, Maruyama Y, Kaneko K. Biomechanical evaluation of a transcondylar screw from the dorsolateral plate support on the stabilization of orthogonal plate configuration in distal humeral fracture. *Injury.* 2019;50(2):256–62. (DOI: 10.1016/j.injury.2018.12.017; PMID: 30579588)

**Table 1.** Frequency of olecranon aperture of the humerus (OAH) and translucent and opaque septum

N = 70 humeri	Left side	Right side	Total
OAH	6 (8.6%)	1 (1.4%)	7 (10%)
Translucent septum	28 (40%)	19 (27.1%)	47 (67.1%)
Opaque septum	8 (11.4%)	8 (11.4%)	16 (22.9%)

**Table 2.** Measurements of olecranon aperture and distal end of humerus (in mm)

Values	TD	VD	MB	LB	EW with OAH	EW with septum
Mean	5.25	3.33	26.92 <sup>a</sup>	29.59	58.97 <sup>b</sup>	61.03
SD	3.62	1.93	5.03	4.22	5.53	3.20
Min–max	1.32–11.96	1.22–7.68	19.92–35.48	24.14–35.50	50.50–65.74	56.14–67.86

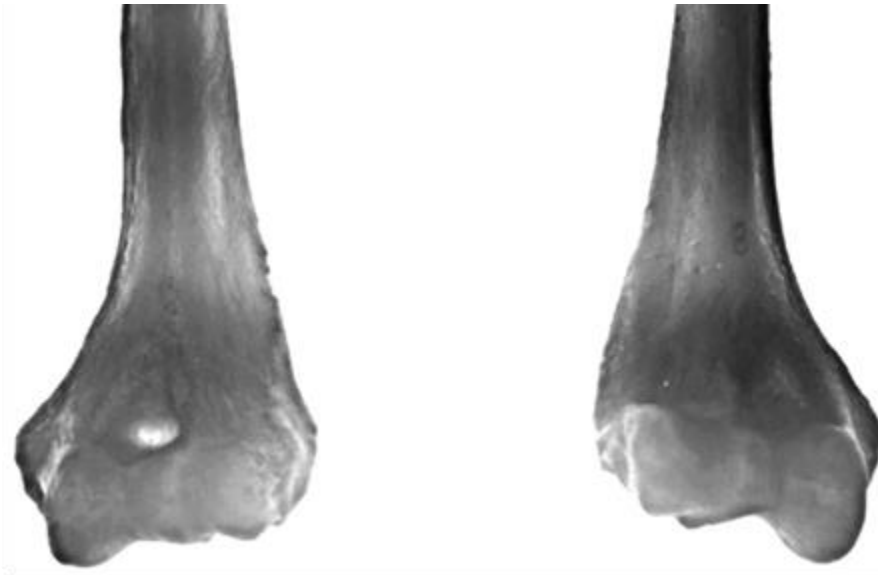
TD – transverse diameter, VD – vertical diameter, MB – distance from the medial border of the aperture to the tip of the medial epicondyle of the humerus, LB – distance from the lateral border of the aperture to the tip of the lateral epicondyle of the humerus, EW – epicondylar width; OAH – olecranon aperture of the humerus;

<sup>a</sup> P = 0.13 vs. LB (no statistical significance)

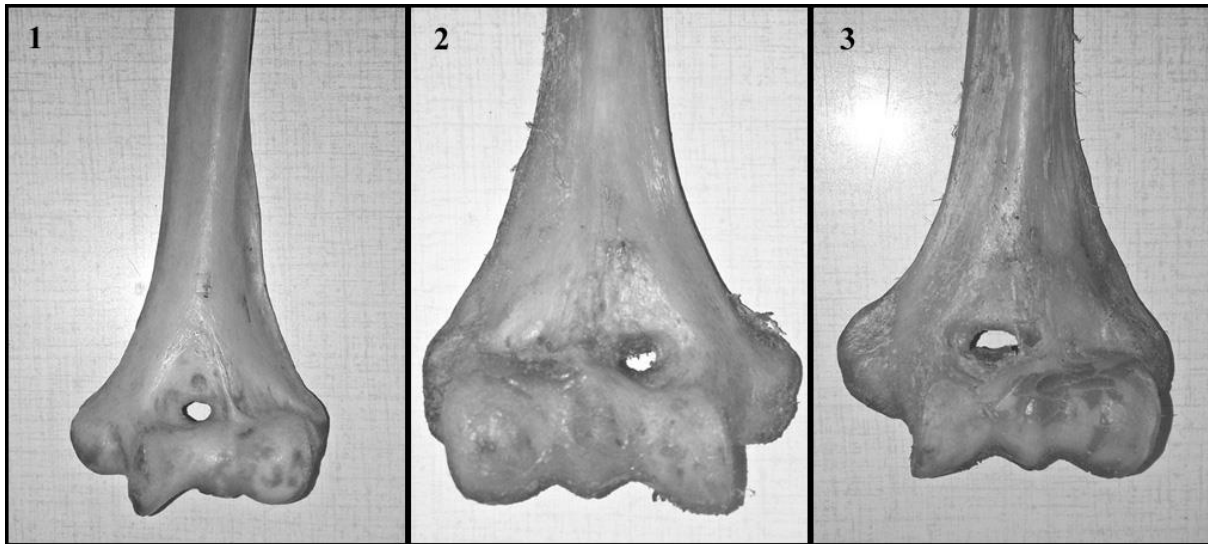
<sup>b</sup> P = 0.08 vs. EW with septum (no statistical significance)

**Table 3.** Frequencies of the olecranon aperture of the humerus in different populations

Study authors	Populations	Prevalence (%)
Papaloucas et al. [9]	Greek	0.3
Varlam et al. [14]	Romanian	1.8
Hirsh [15]	White American	4.2
Glanville [15]	European	6
Glanville[9]	Dutch	6.1
Benfer and McKern [9]	American	6.9
Mays [3]	English	6.9
Hrdlicka [15]	Irish	7.4
Myszka et al. [4]	Polish	7.5
Oztürk et al. [9]	Egyptian	7.9
Koyun et al. [9]	Turkish	8.6
Akabori [15]	Ainus	8.8
Hrdlicka [15]	German	8.8
Hrdlicka [9]	Italian	9.4
Li et al. [15]	Chinese	10.3
Erdogmus et al. [9]	Turkish	10.8
Akabori [9]	Korean	11
Ndou et al. [16]	European	16
Bradshaw et al. [13]	Portuguese	16.8
Ming-Tzu [9]	Chinese	17.5
Akabori [9]	Japanese	18.1
Krishnamurthy et al. [15]	Eskimo	18.4
Bradshaw et al. [13]	Greek	21.6
Sablan et al. [17]	Arab	21.6
Hirsh [15]	African American	21.7
Chagas et al. [1]	Brazilian	22.5
Mathew et al. [6]	Southern Indian	24.5
Sablan et al. [17]	Yazidi	26
Sunday et al. [18]	Nigerian	27.7
Sablan et al. [17]	Kurdish	30.6
Ndou et al. [16]	Xhosa	33
Nayak et al. [19]	Indian	34.4
Ndou et al. [16]	Zulu	37
Krishnamurthy et al. [15]	Mexican	38.7
Ndou et al. [16]	Tswana	39
Ndou et al. [16]	Sotho	41
Hrdlicka [15]	Australian	46.5
Glanville [9]	Tellem	47
Hirsh [9]	Native American	58



**Figure 1.** Translucent (left) and opaque (right) septum between the olecranon and coronoid fossae



**Figure 2.** Distal ends of humeri with various shapes of the olecranon aperture (1 – oval; 2 – triangular; 3 – irregular)