



## ORIGINAL ARTICLE / ОРИГИНАЛНИ РАД

# MRI-based clinical anatomical evaluation of vertebral morphometric changes associated with disc herniation stages at the L4–L5 level

Onur Seçgin Nişancı<sup>1</sup>, Rıdvan Yıldız<sup>2</sup><sup>1</sup>Kafkas University, Faculty of Medicine, Department of Anatomy, Kars, Türkiye;<sup>2</sup>Dicle University, Atatürk Vocational School of Health Services, Department of Medical Services and Techniques, Diyarbakır, Türkiye**SUMMARY**

**Introduction/Objective** This study aimed to evaluate vertebral body and intervertebral disc morphometry at the L4–L5 level in individuals with lumbar disc herniation, with a particular focus on identifying morphometric parameters relevant to radiological interpretation from a clinical anatomical perspective.

**Methods** Lumbar MRI scans of 98 individuals aged 40–60 with single-level L4–L5 disc herniation and 184 healthy individuals (defined as subjects with normal discs or disc bulging without protrusion or extrusion) were retrospectively reviewed. Anterior, middle, and posterior morphometric measurements of the L4–L5 intervertebral disc and the L4–L5 vertebral bodies were obtained on standardized sagittal planes and compared between groups as well as between protrusion and extrusion subgroups.

**Results** No significant differences were observed in L4 and L5 vertebral body heights between healthy and pathological groups ( $p > 0.05$ ). However, anterior, middle, and posterior disc heights at the L4–L5 level were all significantly reduced in the pathological group compared with healthy controls ( $p < 0.05$ ). Within the pathological group, posterior disc height and the percentage of posterior disc height loss were significantly lower in extruded cases than in protruded cases ( $p < 0.05$ ), whereas anterior and middle disc heights showed no significant differences ( $p > 0.05$ ). In addition, the disc height asymmetry ratio was significantly lower in extruded cases, reflecting a posterior-dominant disc collapse pattern ( $p < 0.05$ ).

**Conclusion** While a general reduction in disc height was observed in the pathological group, the decrease in posterior disc height was more pronounced, particularly in extruded cases. The preservation of vertebral body morphometry highlights morphometric changes specific to disc pathology. From a clinical anatomical perspective, posterior disc morphometry may be considered a supportive parameter in the radiological evaluation of lumbar disc herniation.

**Keywords:** lumbar disc herniation; L4–L5 level; disc height; vertebral morphometry; magnetic resonance imaging (MRI)

**INTRODUCTION**

Low back pain is a common musculoskeletal condition affecting a large proportion of the population at least once during their lifetime, with prevalence increasing with age [1]. Disc herniation is the displacement of the nucleus pulposus into the vertebral canal through a tear in the annulus fibrosus caused by intervertebral disc degeneration. Lumbar disc herniation (LDH) is considered one of the most common causes of low back pain and is seen in 50%–70% of the population, increasing with age [2, 3]. In the lumbar (L) region, the L4–L5 and L5–S1 discs are the most common levels of herniation, as they bear the greatest mechanical load due to the biomechanics of the spine [4, 5, 6].

Advances in magnetic resonance imaging (MRI) technology have enabled detailed examination of disc degeneration and geometric changes in vertebral structures owing to high-resolution soft tissue contrast, thereby making morphometric analysis of the lumbar spine more reliable [7–10]. In addition, there

is increasing evidence that disc herniation may affect not only the disc itself but also the morphometry of the lower and upper vertebrae, with recent MRI-based studies showing that disc herniation is associated with lumbar morphometric changes and adjacent vertebral endplate alterations [11, 12]. It has been reported that disc height, vertebral body height, and oblique angles may reflect biomechanical load distribution within the intervertebral space and may vary across herniation stages, with recent MRI-based evidence also linking lower lumbar endplate morphology to disc degeneration in lumbar disc herniation [13, 14]. However, studies specifically comparing the effects of different herniation stages at the L4–L5 level on the morphometry of adjacent vertebrae are limited in the literature [15, 16]. Current studies have generally evaluated the complete lumbar segment and have not focused specifically on particular segments [17, 18, 19]. However, the L4–L5 level has particular clinical significance as it is the segment that experiences the greatest biomechanical load and where herniation is

**Received • Примљено:**  
January 25, 2026

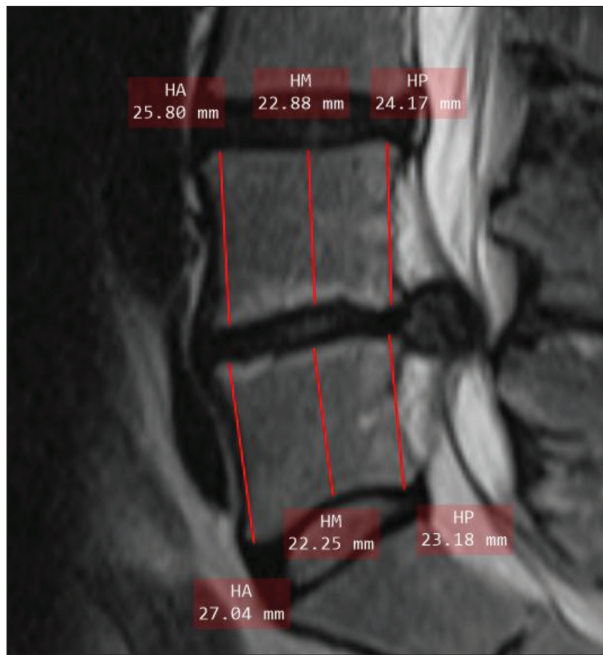
**Revised • Ревизија:**  
March 26, 2026

**Accepted • Прихваћено:**  
April 3, 2026

**Online first:** April 7, 2026

**Correspondence to:**

Onur Seçgin NIŞANCI  
Department of Anatomy  
Faculty of Medicine  
Kafkas University  
36000 Kars, Türkiye  
[onur.nisanci@kafkas.edu.tr](mailto:onur.nisanci@kafkas.edu.tr)



**Figure 1.** Sagittal T2-weighted lumbar MRI image of a 55-year-old female patient with an extruded disc herniation at the L4–L5 level

most frequently observed. From both a diagnostic assessment and surgical planning perspective, detailed examination of morphometric features at this level will significantly contribute to understanding the pathological processes. Thus, this study aimed to evaluate the effects of disc herniation stage at the L4–L5 level on the morphometry of the disc and adjacent vertebral bodies, with a segment-specific focus and a separate analysis of protrusion and extrusion stages, and by introducing novel morphometric indices (DHAR, PDI, and MDI).

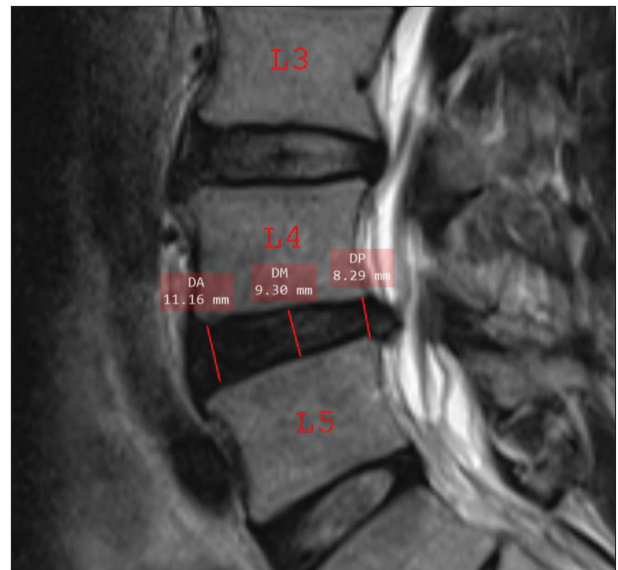
## METHODS

In this retrospective study, lumbar MRI scans obtained at Artvin State Hospital between 2020 and 2025 were reviewed in 282 eligible individuals. Participants were classified into a healthy group ( $n = 184$ ) and a pathological group ( $n = 98$ ) with single-level L4–L5 disc herniation (protrusion/extrusion).

Inclusion criteria were as follows: age between 40 and 60 years, having undergone a lumbar MRI scan, and the image quality being of an evaluable standard. Exclusion criteria were the following: history of lumbar surgery, detection of vertebral fracture, presence of scoliosis of  $20^\circ$  or greater, insufficient image quality, disc herniation at three or more levels, presence of sequestration (free fragment).

### Radiological evaluation and measurement protocol

Morphometric measurements were obtained from sagittal T2-weighted MRI sections by measuring the anterior (HA), middle (HM), and posterior (HP) heights of the L4 and L5 vertebral bodies, as well as the anterior (DA), middle



**Figure 2.** Sagittal T2-weighted lumbar MRI image of a 49-year-old male patient with a protruded disc herniation at the L4–L5 level

(DM), and posterior (DP) heights of the L4–L5 intervertebral disc. All measurements were performed on images acquired using an MRI scanner (Siemens Healthineers, Erlangen, Germany) and evaluated through the hospital's Picture Archiving and Communication System (PACS) using the built-in, calibrated measurement tools of the system under standardized window settings (contrast and brightness). Each measurement was performed twice, and mean values were used for statistical analysis.

In addition to absolute morphometric disc height measurements, four relative indices were defined to better capture the geometric architecture of disc height: disc height asymmetry ratio (DHAR), posterior disc index (PDI), middle disc index (MDI), and posterior–middle gap (P–M gap). The loss rate (%) was calculated using the following formula:  $[(\text{Healthy Group Average Value} - \text{Pathological Group Average Value}) / (\text{Healthy Group Average Value}) \times 100]$ .

Participants were divided into two groups: the healthy group and the pathological group. The healthy group included individuals with normal discs or disc bulging at the L4–L5 level, whereas the pathological group consisted of cases with disc herniation at the protrusion or extrusion stage. Disc bulging cases were included in the healthy group as they do not represent true herniation and were therefore considered separately from the pathological group. Example sagittal T2-weighted MRI images of extruded and protruded cases are presented in Figure 1 and Figure 2, respectively. Herniation staging was based on radiology reports archived in the PACS system and was cross-checked to minimize potential classification errors.

### Statistical analyses

Comparisons between protruded and extruded groups were carried out using the Mann–Whitney U test. To highlight not only statistical significance but also the practical relevance of the findings, effect sizes were calculated using

**Table 1.** Participants' demographic characteristics

Groups	n	Female (n)	Male (n)	Age (Mean ± SD)
Healthy	184	109	75	49.2 ± 5.1
Pathological (disc protrusion/extrusion)	98	59	39	52.5 ± 5.3
Total	282	168	114	50.3 ± 5.6

**Table 2.** Comparison of L4 and L5 vertebral body heights between the healthy group and the pathological groups

Vertebra	Measurement area	Healthy group Mean ± SD (mm)	Pathological group Mean ± SD (mm)	p*
L4	HA	25.9 ± 0.8	25.7 ± 0.9	0.462
	HM	23.4 ± 0.7	23.3 ± 0.8	0.317
	HP	24.1 ± 0.9	24 ± 1	0.411
L5	HA	27.6 ± 0.9	27.4 ± 1	0.274
	HM	23.8 ± 0.8	23.7 ± 0.9	0.233
	HP	24.1 ± 0.7	24 ± 0.8	0.361

HA – anterior vertebral height; HM – middle vertebral height; HP – posterior vertebral height;

\*Mann-Whitney U test

**Table 3.** Comparison of intervertebral disc heights at the L4–L5 level between healthy group and pathological groups

Level	Measurement Area	Healthy group (Mean ± SD, mm)	Pathological group (Mean ± SD, mm)	p*
L4–L5	DA	11.8 ± 0.7	10.9 ± 0.8	0.004
	DM	10.4 ± 0.6	9.6 ± 0.7	< 0.001
	DP	9.7 ± 0.8	8.9 ± 0.9	< 0.001

DA – anterior disc height; DM – middle disc height; DP – posterior disc height;

\*Mann-Whitney U test

**Table 4.** Comparison of L4–L5 disc heights in protruded (n = 59) and extruded (n = 39) cases

Measurement area	Protruded (Mean ± SD, mm)	Extruded (Mean ± SD, mm)	p*
DA	11 ± 0.9	10.8 ± 0.95	0.284
DM	9.8 ± 0.72	9.5 ± 0.82	0.091
DP	9.1 ± 0.85	8.8 ± 0.81	0.041*

DA – anterior disc height; DM – middle disc height; DP – posterior disc height;

\*Mann-Whitney U test

**Table 5.** Comparison of disc height loss rates in protruded and extruded cases

Measurement area	Protruded average loss (%) ± SD	Extruded average loss (%) ± SD	p*
Anterior	5.1 ± 2.3	7.6 ± 2.5	0.29
Middle	7.7 ± 2.4	11.5 ± 2.8	0.078
Posterior	10.3 ± 2.7	16.5 ± 3	0.037*

\*Mann-Whitney U test

the rank-biserial correlation coefficient ( $r$ ) and interpreted as small ( $\approx 0.1$ ), moderate ( $\approx 0.3$ ), or large ( $\geq 0.5$ ). A  $p$  value of  $< 0.05$  was set as the threshold for statistical significance. All analyses were performed using IBM SPSS Statistics, Version 22.0 (IBM Corp., Armonk, NY, USA).

**Ethics:** This study was conducted retrospectively following approval by the Artvin Çoruh University Scientific Research and Publication Ethics Committee (Decision No: E-18457941-050.99-168439, Date: February 13, 2025).

## RESULTS

A total of 282 individuals were included in the study. Of the participants, 168 were female and 114 were male. The mean age in the pathological group was  $52.5 \pm 5.3$  years, while the mean age in the healthy group was  $49.2 \pm 5.1$  years (Table 1).

When comparing the anterior, middle, and posterior corpus heights of the L4 and L5 vertebrae between the healthy group and the pathological group, no statistically significant difference was observed ( $p > 0.05$ ) (Table 2).

In the healthy group, anterior, middle and posterior disc height values were found to be significantly higher than those in the pathological group ( $p < 0.05$ ) (Table 3).

When comparing disc heights between protruded and extruded cases within the pathological group, posterior disc height was found to be significantly lower in extruded cases ( $p = 0.041$ ). No statistically significant difference was observed between these groups regarding anterior and middle disc heights ( $p > 0.05$ ) (Table 4).

No statistically significant difference was observed in anterior and middle disc heights in protruded and extruded cases; however, a significantly greater percentage of posterior disc height loss was observed in extruded cases compared with protruded cases ( $p = 0.037$ ) (Table 5).

The disc height asymmetry ratio (DHAR) was significantly lower in extruded cases compared with protruded cases ( $p = 0.048$ ), indicating a disproportionate reduction in posterior disc height relative to the anterior segment. No statistically significant differences were observed between groups for the posterior disc index (PDI), middle disc index (MDI), or the posterior–middle height gap (P–M gap) ( $p > 0.05$ ) (Table 6).

When the morphometric profiles of extruded and protruded cases were compared, posterior disc height, the percentage of posterior disc height loss, and the disc height asymmetry ratio showed significant differences between the groups. No statistically significant differences were observed for the remaining parameters (Table 7).

## DISCUSSION

The most important finding of the present study is that disc height reduction at the L4–L5 level is particularly pronounced in the posterior segment in patients with disc herniation, and that this reduction is more evident in extruded cases compared with protruded cases. When the healthy and pathological groups were compared, no significant differences were observed in vertebral body heights; however, intervertebral disc heights were reduced across all segments in the pathological group, with the posterior disc segment showing the greatest decrease. Within the pathological cohort, posterior disc height was significantly lower in extruded cases than in protruded cases, whereas the percentage of posterior disc height loss was significantly greater in extruded cases than in protruded cases. In addition, relative indices reflecting the geometric distribution of disc height were evaluated, and among

**Table 6.** Novel posterior-dominant disc collapse indices in protruded and extruded cases

Index (Novel)	Formula	Protruded (Mean ± SD)	Extruded (Mean ± SD)	p*
DHAR	DP/DA	0.83 ± 0.09	0.81 ± 0.08	0.048*
PDI (%)	(DA – DP) / DA × 100	17.3 ± 4.1	18.5 ± 4.4	0.094
MDI (%)	(DA – DM) / DA × 100	10.9 ± 3.6	12 ± 3.9	0.081
P–M Gap (mm)	DM – DP	0.7 ± 0.28	0.7 ± 0.31	0.992

DHAR – disc height asymmetry ratio (DP/DA); PDI – posterior dominance index, percentage of posterior disc height loss relative to anterior disc height; MDI – middle drop index, percentage of middle disc height loss relative to anterior disc height; P–M Gap – absolute difference between middle and posterior disc heights; DA – anterior disc height; DM – middle disc height; DP – posterior disc height;  
\*Mann–Whitney U test

**Table 7.** Morphometric profile distinguishing protrusion and extrusion at the L4–L5 Level

Parameter	Protruded (Mean ± SD)	Extruded (Mean ± SD)	p*	Effect size (r)
DA (mm)	11 ± 0.9	10.8 ± 0.95	0.284	0.02
DM (mm)	9.8 ± 0.72	9.5 ± 0.82	0.091	0.03
DP (mm)	9.1 ± 0.85	8.8 ± 0.81	0.041*	0.13
Loss DA (%)	5.1 ± 2.3	7.6 ± 2.5	0.290	0.03
Loss DM (%)	7.7 ± 2.4	11.5 ± 2.8	0.078	0.03
Loss DP (%)	10.3 ± 2.7	16.5 ± 3	0.037*	0.12
DHAR	0.83 ± 0.09	0.81 ± 0.08	0.048*	0.10
PDI (%)	17.3 ± 4.1	18.5 ± 4.4	0.094	0.05
MDI (%)	10.9 ± 3.6	12 ± 3.9	0.081	0.02
P–M Gap (mm)	0.7 ± 0.28	0.7 ± 0.31	0.992	~0.00

DA – anterior disc height; DM – middle disc height; DP – posterior disc height; Loss DA (%) – percentage loss of anterior disc height relative to the healthy group; Loss DM (%) – percentage loss of middle disc height relative to the healthy group; Loss DP (%) – percentage loss of posterior disc height relative to the healthy group; DHAR – disc height asymmetry ratio (DP/DA); PDI (%) – posterior dominance index, percentage of posterior disc height reduction relative to anterior disc height; MDI (%) – middle drop index, percentage of middle disc height loss relative to anterior disc height; P–M Gap – absolute difference between middle and posterior disc heights;  
\*Mann–Whitney U Test

these indices, only the disc height asymmetry ratio demonstrated a significant difference between protruded and extruded cases. Although the associated effect sizes were small, posterior disc-related parameters showed consistent differences between the two herniation stages, whereas no significant differences were observed in anterior and middle disc measurements or in the remaining relative indices.

Our findings indicate a reduction in disc height in lumbar disc degeneration and related pathologies, which is consistent with studies in the current literature. In some imaging-based studies, a correlation was found between disc degeneration and a decrease in disc height, and this condition was found to be particularly pronounced at the L4–L5 and L5–S1 disc levels [20, 21]. In a study conducted by Zheng et al. [21], the relationship between lumbar disc degeneration and intervertebral disc height was examined in 85 patients with back pain. It was found that as the severity of degeneration and herniation increased, a significant decrease in disc height occurred. The Pfirrmann classification was used in the study, and an average decrease of 1.25–1.76 mm in disc height at each degree of degeneration was found. They reported that this decrease occurred independently of age, gender, and smoking status. In addition, a positive correlation was observed between the increase in

VAS (Visual Analog Scale) score and the decrease in disc height. This finding demonstrates that the increase in the degree of disc degeneration has an effect not only on disc morphometry but also on the severity of clinical symptoms. In another study, lumbosacral MRI images of 72 individuals were evaluated according to the Pfirrmann grading system [20]. A significant decrease in disc height was observed with increasing degeneration severity, independent of age, gender, body mass index, and smoking, with an average reduction of 0.98–1.60 mm per Pfirrmann grade. Similarly, in our study, the fact that anterior, middle, and posterior disc height values were significantly reduced in the pathological group compared with the healthy group supports the clinical implications of this quantitative reduction in disc height that occurs with increasing degeneration. In a study by Singh et al. [22], the lumbar spine parameters of individuals with chronic low back pain were compared with those of a healthy control group using MRI. Significant reductions in disc angle and disc cross-sectional area were observed in the group with chronic low back pain, particularly at the L3–L4 and L4–L5 levels, in relation to the healthy control group [22]. Furthermore, degenerative changes in the intervertebral discs were observed in 54% of patients, whereas these findings were not observed in the healthy group. It was found that reductions in disc angles and disc cross-sectional area may lead to early degeneration due to abnormal load transfer and stress distribution [22]. These results are in correlation with the significant reduction observed in the posterior segment of the disc, particularly in pathological cases in our study. Since changes in the spinal angle directly affect the load distribution in the posterior segment of the disc, the disruption of geometric balance in this region may weaken spinal stability, leading to mechanical imbalance. Thus, morphometric losses occurring in the posterior segment may be associated with the early appearance of clinical symptoms. In another study by Näther et al. [23], the number of degenerated discs in the spine was evaluated according to age, sex, and disc levels. The study showed that disc degeneration increases with age, with the L4–L5 and L5–S1 levels being the most commonly affected. Degenerative disc disease was present in 91.6% of individuals aged 50–61. Although no significant gender differences were identified, a reduction in disc height appears to be associated with a higher likelihood of both disc herniation and bony degenerative changes such as spondylosis. Bakar et al. [24] examined mature single-level lumbar disc herniations in a study evaluating the vertebral disc morphometrics and spinal balance parameters of 30 operated patients and 15 healthy individuals. In the surgical group, L1–L2 and L5–S1 disc heights were found to be significantly reduced compared to the healthy group. In addition, significant decreases were observed in parameters representing sagittal balance, such as the T12 angle of inclination and the L4–S1 Cobb angle.

ROC and regression analyses revealed that a decrease in the average height of the L5–S1 disc below 8.15 mm is a significant morphometric indicator of the presence of lumbar disc herniation. In another study, the morphometric and stereological analysis of the vertebrae of patients with lumbar intervertebral disc herniation and healthy individuals was performed [25]. In the study, although no significant difference was observed in disc heights in the early period between the healthy and patient groups, a marked difference was detected in disc volumes. This finding indicates that disc height can be preserved in patients with herniation in the early stages, but volume loss is an early indicator of degeneration. The study observed that although posterior disc height in particular showed a tendency to differ significantly, it did not confirm statistical significance in the early stages. In light of all these findings, the significant reduction observed in posterior disc height in our study suggests that it may represent an important morphometric marker of advanced lumbar disc herniation.

A study examining the relationship between lumbar disc herniation and vertebral morphometry investigated 249 middle-aged Finns [26]. It was found that for every 1 cm<sup>2</sup> increase in the cross-sectional area of the L4 vertebral axial diameter, the likelihood of disc displacement increased by 10%. Hornung et al. [27] found that one of the strongest morphometric indicators predicting early resorption in patients with lumbar disc herniation was the height of the L4 posterior vertebral body. The study reported that a higher posterior vertebral height would accelerate the resorption process by expanding the space between the disc material and the epidural space. This finding indicates that vertebral morphometrics may play a role not only in disc pathologies but also in the natural healing of the disc. In another study on vertebral body morphometry, it was reported that a geometric difference of more than 10% in the anteroposterior dimension between adjacent vertebral bodies, particularly at the L5–S1 level, increases the risk of disc herniation by sixfold [28]. These findings suggest that disproportionality in vertebral morphometry may lead to an imbalance in axial load transmission, resulting in increased stress accumulation in the posterior fibers of the disc [28]. In our study, no significant change was observed in the supero-inferior heights of the vertebral body in disc herniation. This finding may be explained by the fact that in the early stages of degenerative loading, the pathology primarily manifests at the intervertebral disc level, and the vertebral body morphometry remains stable in the short term. Furthermore, with the reduction in disc height, part of the axial load may be partially compensated by the posterior elements and facet joints, thereby reducing the impact on the corpus and preserving vertebral height. Furthermore, factors such as the MR slice geometry, lordosis angle, and sample size used in the evaluation may have prevented small differences in the corpus from becoming statistically significant. Therefore, our findings may suggest that structural changes develop primarily at the disc level at the onset of the degenerative process, while effects on vertebral corpus morphometry may require longer-term remodeling to become detectable. Very recent MRI-based

studies published in 2026 have further strengthened the clinical and biomechanical relevance of disc morphometry in lumbar disc herniation. Šprláková-Puková et al. [29] demonstrated that specific morphometric parameters, particularly middle disc height, may serve as significant predictors of clinical symptom resolution, and that patients with favorable morphometric profiles may have a substantially higher likelihood of spontaneous recovery without surgical intervention. Furthermore, a long-term longitudinal MRI study by Lund et al. [30] revealed that intervertebral disc degeneration progresses in a level-specific and age-dependent manner and is associated with future low back pain outcomes. Taken together, these findings support the concept that morphometric evaluation of the intervertebral disc, especially segment-specific and posterior disc measurements, may provide valuable insight into both the progression and clinical implications of lumbar disc herniation.

From a clinical perspective, a marked reduction in posterior disc height on MRI can offer a simple and objective way to better understand the severity of lumbar disc herniation. Beyond traditional disc degeneration grading systems, measuring posterior disc height provides a clear, segment-specific, and quantitative description of disc morphology, particularly in cases of extrusion. While this finding should not be interpreted as a definitive staging criterion or a factor determining treatment choice, it may help clinicians achieve a more detailed anatomical and radiological appreciation of herniation patterns. Posterior disc morphometry can serve as a supportive anatomical reference during routine clinical assessment and follow-up of patients with lumbar disc herniation.

The limitations of this study include the fact that only L4–L5 level disc herniation was addressed, with other lumbar segments excluded from the assessment. The participants were aged 40–60 years; therefore, the results are limited to a single age group. Measurements were performed manually; automatic or three-dimensional segmentation techniques were not used. Furthermore, information that could affect morphometric measurements, such as participants' physical activity level, occupational stress, history of chronic disease, and regular medication use, could not be obtained due to the retrospective nature of the analysis. For these reasons, the findings need to be supported by further prospective studies with larger samples and multivariate analyses.

## CONCLUSION

The findings of this study indicate that intervertebral disc height is markedly reduced in the presence of lumbar disc herniation, with this reduction becoming more pronounced in the posterior disc segment as the disease progresses. Posterior disc segment is more susceptible to collapse in advanced stages of herniation. Degenerative alterations initially occur at the intervertebral disc level, while vertebral corpus morphometry remains relatively preserved. Among the relative indices reflecting the

geometric distribution of disc height, only the disc height asymmetry ratio is expected to be different between protruded and extruded cases. Taken together, these findings suggest that posterior disc morphometry may represent a

supportive morphometric parameter in the radiological assessment of lumbar disc herniation severity.

**Conflict of interest:** None declared.

## REFERENCES

- Zhou T, Salman D, McGregor AH. Recent clinical practice guidelines for the management of low back pain: a global comparison. *BMC Musculoskelet Disord.* 2024;25(1):344. [DOI: 10.1186/s12891-024-07468-0] [PMID: 38693474]
- Huang Z, Zhao P, Zhang C, Wu J, Liu R. Value of imaging examinations in diagnosing lumbar disc herniation: a systematic review and meta-analysis. *Front Surg.* 2023;9:1020766. [DOI: 10.3389/fsurg.2022.1020766] [PMID: 36704505]
- Sun BL, Zhang Y, Zhang N, Xiong X, Zhong YX, Xing K, et al. Prevalence of lumbar disc herniation in populations with different symptoms based on magnetic resonance imaging study. *J Clin Neurosci.* 2024;129:110839. [DOI: 10.1016/j.jocn.2024.110839] [PMID: 39326345]
- Eremina G, Smolin A, Xie J, Syrkashev V. Development of a computational model of the mechanical behavior of the L4–L5 lumbar spine: application to disc degeneration. *Materials (Basel).* 2022;15(19):6684. [DOI: 10.3390/ma15196684] [PMID: 36234026]
- Mahmutović E, Doder R, Dolićanin Z, Bošković K. The quality of life of patients after lumbar microdiscectomy. *Srp Arh Celok Lek.* 2018;146(9–10):554–60. [DOI: 10.2298/SARH171002189M]
- Rodić D, Dilvesi Đ, Jelača B, Rodić J, Lasica N, Vuleković P. Early outcomes of surgical treatment with microdiscectomy in patients with lumbar disc herniation. *Med Pregl.* 2023;76(7–8):192–6. [DOI: 10.2298/MPNS2308192R]
- Kaul R, Kumar K, Jeyaraman M, Goswami B, Choudhary MC, Chhabra HS, et al. MRI-based morphometric study regarding operative windows of oblique lumbar interbody fusion in Indian population. *Indian J Orthop.* 2021;55(Suppl 2):366–73. [DOI: 10.1007/s43465-021-00393-7] [PMID: 34306549]
- Molinares DM, Davis TT, Fung DA. Retroperitoneal oblique corridor to the L2–S1 intervertebral discs: an MRI study. *J Neurosurg Spine.* 2016;24(2):248–55. [DOI: 10.3171/2015.8.SPINE15453] [PMID: 26451662]
- Khasawneh R, Abu El-Rub E, Allouh M. Human lumbosacral root and ligamentum flavum thicknesses: a magnetic resonance study. *Folia Morphol (Warsz).* 2023;82(1):72–8. [DOI: 10.5603/FM.a2021.0120] [PMID: 34783005]
- Li XB, Wang L, Deng Q, Wang B, Wang ZR, Zhao CM, et al. What are the differences in paraspinal muscle morphometry among degenerative spondylolisthesis patients, isthmic spondylolisthesis patients, and healthy individuals? A propensity score matching analysis. *BMC Musculoskelet Disord.* 2024;25(1):410. [DOI: 10.1186/s12891-024-07532-9] [PMID: 38783277]
- Yang D, Becker L, Hoehl BU, Mödl L, Zhang T, Liu S, et al. Association between MRI findings of lumbar morphometric changes and the characteristics of low back pain, pain-related disability, and quality of life: a cross-sectional study. *Acad Radiol.* 2025;32(10):6000–8. [DOI: 10.1016/j.acra.2025.06.026] [PMID: 40640053]
- Torabi P, Jamalipour Soufi G, Hekmatnia A, Ravanbod H, Teimouri M, Shahsavan M, et al. Association between lumbar disc herniation and vertebral endplate Modic changes: an MRI-based study. *Adv Biomed Res.* 2025;14:100. [DOI: 10.4103/abr.abr\_480\_23] [PMID: 41132229]
- Tavana S, Shek C, Rahman T, Baxan N, Newell N. The influence of geometry on intervertebral disc stiffness. *J Biomech.* 2024;163:111915. [DOI: 10.1016/j.jbiomech.2023.111915] [PMID: 38233311]
- Yu Y, Xu C. Correlation between sagittal morphology of lower lumbar end plate and degenerative changes in patients with lumbar disc herniation. *J Craniovertebr Junction Spine.* 2024;15(3):298–302. [DOI: 10.4103/jcvjs.jcvjs\_95\_24] [PMID: 39483825]
- Çetin T, Kahraman S, Kızılöz V, Aydın S. The comparison between herniated and non-herniated disc levels regarding intervertebral disc space height and disc degeneration: a magnetic resonance study. *Diagnostics (Basel).* 2023;13(20):3190. [DOI: 10.3390/diagnostics13203190] [PMID: 37892011]
- Chen X, Shi HG, Wan D, Deng XG, Song SM, Cao M. Relationship between lumbar disc herniation and Roussoouly classification in the sagittal alignment of the spine and pelvis in young people. *Quant Imaging Med Surg.* 2023;13(7):4687–98. [DOI: 10.21037/qims-22-503] [PMID: 37456276]
- Abbas J, Peled N, Hershkovitz I, Hamoud K. The role of vertebral morphometry in the pathogenesis of degenerative lumbar spinal stenosis. *Biomed Res Int.* 2021;2021:7093745. [DOI: 10.1155/2021/7093745] [PMID: 34527742]
- Singh K, Samartzis D, Vaccaro AR, Nassr A, Andersson GB, Yoon ST, et al. Congenital lumbar spinal stenosis: a prospective, control-matched, cohort radiographic analysis. *Spine J.* 2005;5(6):615–22. [DOI: 10.1016/j.spinee.2005.05.385] [PMID: 16291100]
- Kitab SA, Alsulaiman AM, Benzel EC. Anatomic radiological variations in developmental lumbar spinal stenosis: a prospective, control-matched comparative analysis. *Spine J.* 2014;14(5):808–15. [DOI: 10.1016/j.spinee.2013.09.012] [PMID: 24314904]
- Teichtahl AJ, Urquhart DM, Wang Y, Wluka AE, Heritier S, Cicuttini FM. A dose-response relationship between severity of disc degeneration and intervertebral disc height in the lumbosacral spine. *Arthritis Res Ther.* 2015;17:297. [DOI: 10.1186/s13075-015-0820-1] [PMID: 26498120]
- Zheng J, Shen C. Retracted: quantitative relationship between the degree of lumbar disc degeneration and intervertebral disc height in patients with low back pain. *Contrast Media Mol Imaging.* 2022;2022:5960317. [DOI: 10.1155/2022/5960317] [PMID: 35953310]
- Singh R, Yadav SK, Sood S, Yadav RK, Rohilla R. Magnetic resonance imaging of lumbar trunk parameters in chronic low backache patients and healthy population: a comparative study. *Eur Spine J.* 2016;25(9):2864–72. [DOI: 10.1007/s00586-016-4698-7] [PMID: 27421282]
- Näther P, Kersten JF, Kaden I, Irga K, Nienhaus A. Distribution patterns of degeneration of the lumbar spine in a cohort of 200 patients with an indication for lumbar MRI. *Int J Environ Res Public Health.* 2022;19(6):3721. [DOI: 10.3390/ijerph19063721] [PMID: 35329406]
- Bakar B, Özdemir A, Erdoğan AM, Çevik ME, Aydın Ö, Sivuk S, et al. Morphometric analysis of the spine in patients with single-level lumbar disc herniations: clinical study. *Anatolian Curr Med J.* 2025;7(3):311–9. [DOI: 10.38053/acmj.1675007]
- Köksal V, Avnioğlu S, Atay E. Is there effect of intervertebral disc herniation on the lumbar spine in early period? A morphometric and stereological study. *Int J Morphol.* 2020;38(2):374–81. [DOI: 10.4067/S0717-95022020000200374]
- Ollila L, Oura P, Karppinen J, Niinimäki J, Junno JA. Association between vertebral cross-sectional area and lumbar disc displacement – a population-based study. *Eur Spine J.* 2024;33(3):900–5. [DOI: 10.1007/s00586-023-07853-8] [PMID: 37452838]
- Hornung AL, Barajas JN, Rudisill SS, Aboushaala K, Butler A, Park G, et al. Prediction of lumbar disc herniation resorption in symptomatic patients: a prospective, multi-imaging and clinical phenotype study. *Spine J.* 2023;23(2):247–60. [DOI: 10.1016/j.spinee.2022.10.003] [PMID: 36243388]
- Läubli R, Brugger R, Pirvu T, Hoppe S, Sieroń D, Szyluk K, et al. Disproportionate vertebral bodies and their impact on lumbar disc herniation. *J Clin Med.* 2021;10(14):3174. [DOI: 10.3390/jcm10143174] [PMID: 34300340]
- Špráková-Puková A, Straka M, Habas T, Čellár A, Dostál M, Barusová T, et al. MRI predictors for improvement without any intervention of clinical symptoms in patients with lumbar disc herniation, questioning the true need for surgery. *Radiol Res Pract.* 2026;2026:4954622. [DOI: 10.1155/rpp/4954622] [PMID: 41496763]
- Lund T, Aavikko A, Ristolainen L, Kautiainen H, Lohman M, Schlenzka D. Progression of lumbar disc degeneration: a 26-year follow-up study of healthy individuals from childhood to adulthood. *Spine J.* 2026 Mar 3;S1529-9430(26)00074-4. Online ahead of print. [DOI: 10.1016/j.spinee.2026.03.001] [PMID: 41786224]

## Клиничко-анатомска евалуација морфометријских промена пршљенова повезаних са стадијумима дискус херније на нивоу L4–L5 заснована на магнетној резонанци

Онур Сечгин Нишанци<sup>1</sup>, Ридван Јилдиз<sup>2</sup>

<sup>1</sup>Универзитет Кафкас, Медицински факултет, Катедра за анатомију, Карс, Турска;

<sup>2</sup>Универзитет Дицле, Висока школа здравствених услуга „Ататурк“, Одељење за медицинске услуге и технике, Дијарбакир, Турска

### САЖЕТАК

**Увод/Циљ** Циљ ове студије био је да се процени морфометрија тела пршљенова и интервертебралног диска на нивоу L4–L5 код особа са лумбалном дискус хернијом, са посебним фокусом на идентификацију морфометријских параметара релевантних за радиолошку интерпретацију из перспективе клиничке анатомије.

**Метод** Ретроспективно су анализирани лумбални магнетнорезонантни снимци 98 особа старости 40–60 година са једнонивојском дискус хернијом на нивоу L4–L5 и 184 здрава испитаника (са нормалним дисковима или дискус бублгингом на нивоу L4–L5). Предња, средња и задња морфометријска мерења интервертебралног диска L4–L5 и тела пршљенова L4 и L5 добијена су на стандардизованим сагиталним равнима и упоређена између група, као и између подгрупа са протрузијом и екструзијом.

**Резултати** Нису уочене значајне разлике у висини тела пршљенова L4 и L5 између здравих и патолошких група ( $p > 0,05$ ). Међутим, предња, средња и задња висина диска

на нивоу L4–L5 биле су значајно смањене у патолошкој групи у поређењу са здравом контролном групом ( $p < 0,05$ ). Унутар патолошке групе, задња висина диска и проценат губитка задње висине диска били су значајно нижи у случајевима екструзије у односу на протрузију ( $p < 0,05$ ), док предња и средња висина диска нису показале значајне разлике ( $p > 0,05$ ). Поред тога, однос асиметрије висине диска био је значајно нижи у случајевима екструзије, што одражава образац колапса диска који је доминантан у задњем делу ( $p < 0,05$ ).

**Закључак** Иако је у патолошкој групи уочен општи пад висине диска, смањење његове задње висине било је израженије, нарочито у случајевима екструзије. Очување морфометрије тела пршљенова указује на морфометријске промене специфичне за патологију диска. Из перспективе клиничке анатомије, постериорна морфометрија диска може се сматрати додатним параметром у радиолошкој евалуацији лумбалне дискус херније.

**Кључне речи:** лумбална дискус хернија; ниво L4–L5; висина диска; морфометрија пршљенова; магнетна резонанца