

ORIGINAL ARTICLE / ОРИГИНАЛНИ РАД

Influence of femoral shaft fracture extension into subtrochanteric or supracondylar region on operation and fluoroscopy time in dynamic extramedullary fixation

Milan M. Mitković^{1,2}, Saša S. Milenković^{1,2}, Predrag M. Stojiljković^{1,2}, Mladen J. Stojanović¹, Nikola J. Kostić¹, Miloš A. Nagorni¹

¹University Clinical Center Niš, Academician Prof. Dr. Milorad Mitković Clinic for Orthopedics and Traumatology, Niš, Serbia;

²University of Niš, Faculty of Medicine, Niš, Serbia



SUMMARY

Introduction/Objective Although femoral shaft fractures are mostly treated by intramedullary fixation today, certain situations indicate extramedullary fixation for these fractures. The aim of this study was to evaluate the influence of femoral shaft fracture extension into the subtrochanteric or supracondylar region on operation time and intraoperative fluoroscopy time while performing dynamic extramedullary fixation.

Method A total of 90 cases of femoral shaft fractures treated using Selfdynamizable Internal Fixator (SIF) were analyzed. Patients were divided into three groups according to the applied implant type: femoral shaft fractures with proximal extension (SIF-troch), femoral shaft fractures without proximal or distal extension (SIF-shaft), and femoral shaft fractures with distal extension (SIF-cond).

Results The shortest mean operation time was observed in the SIF-shaft group, while the longest was recorded in fractures extending into the supracondylar region (SIF-cond group). The shortest average fluoroscopy time occurred in the SIF-shaft group, while the longest in the group with the fracture extension into the subtrochanteric region (SIF-troch group). Operation time was mainly influenced by the technique of lag screws and locking screws insertion and by the fracture reduction maintenance in the subtrochanteric and supracondylar regions.

Conclusion Extension of femoral shaft fractures into the subtrochanteric or supracondylar region is associated with increased operation and fluoroscopy times. SIF allows for dynamic extramedullary fixation, but also provides a relatively simple and fast performing surgical technique for femoral shaft fractures fixation, especially when the fracture does not extend beyond the shaft area.

Keywords: Selfdynamizable Internal Fixator; shaft; fluoroscopy

INTRODUCTION

Closed femoral shaft fractures are today most often treated by intramedullary fixation [1–5]. However, extramedullary fixation has also its place in the treatment of these fractures [6–10]. Extramedullary fixation would be preferred, or the only feasible option of internal fixation, in the following situations of a femoral shaft fracture: narrow medullary canal, closed or deformed medullary canal (after fracture healing, after intramedullary nail removal, etc.), intramedullary presence of an implant (endoprosthesis, nail, screw, etc.), some comminuted fractures requiring better control of length and rotation, pathologic fractures (reaming and insertion of the nail can lead to comminution of weakened bone; reaming can lead to dissemination of malignant cells), extremely obese patients (reaming and pin insertion can be technically challenging), patients with severe cardiorespiratory diseases (reaming can increase the risk of embolism), etc. [9, 10]. Denisiuk et al. [10] reported that extramedullary fixation is recommended for femoral shaft

fractures extending into the proximal or distal femur, where intramedullary fixation may be contraindicated.

Extramedullary fixation of femoral shaft fractures with plates is generally accompanied by higher risk of mechanical complication (implant failure/loosening) [11, 12]. High bending forces acting on a rigid extramedullary implant (such as a plate) may be the main causal factor for these complications and it could be considered as a reason why the fixation of femoral shaft fractures is more often being performed today by an intramedullary nailing. In order to transform implant bending forces as more as possible into translational and compression forces between fracture fragments (compression stimulates the fracture healing), a special type of extramedullary implant – Selfdynamizable Internal Fixator (SIF) was developed. This implant provides an initially rigid fixation, with the feature of subsequent spontaneous transition into a dynamic mode, reducing the implant load, and thereby its risk of bending or breaking [13–16]. Delayed dynamization has been considered a desirable

Received • Примљено:

October 31, 2025

Accepted • Прихваћено:

November 26, 2025

Online first: November 28, 2025

Correspondence to:

Milan M. MITKOVIĆ
Romanijaska 19/52
18000 Niš
Serbia
milanmitkovic@hotmail.com

factor in promoting healing of the shaft fractures, especially in delayed-union [15, 17, 18]. Thus, wider use of a such dynamic implants could increase the prevalence of extramedullary fixation in femoral shaft fractures treatment, and there is the need to examine its clinical aspects, both intraoperatively and postoperatively.

Femoral fracture extending from the shaft region into the adjacent area proximally (subtrochanteric region) or distally (supracondylar region) requires the applied extramedullary fixation implant to be longer [10]. These implants contain screws not only for the shaft but also for the proximal or distal region of the femur.

The aim of this study was to examine the effect of femoral shaft fractures extending into the subtrochanteric or supracondylar region on the operation time and the intraoperative fluoroscopy time, as well as the relationship between these parameters.

METHODS

A total of 90 patients treated surgically for a femoral shaft fracture were analyzed in this study. The fixation was performed in all patients using SIF, a specific type of extramedullary implant for dynamic fixation. There were three groups of patients: SIF-troch group included 22 patients with femoral shaft fracture extending into subtrochanteric region, SIF-shaft included 35 patients with femoral shaft fracture without extending into any adjacent area, and SIF-cond group included 33 patients with femoral shaft fracture extending into supracondylar region (Table 1). In the first group, patients were treated by SIF type containing a “trochanteric unit”, through which sliding screws for the femoral neck and head are inserted. Patients from the second group were treated by the type of SIF that did not contain any additional unit. In patients from the third group, a SIF with the “condylar unit” had been used, involving locking screws for the femoral condylar region, being locked in the threads of this unit. The main part of the SIF implant is cylindrical, providing axial sliding and rotational contact with the clamps. Some screws pass through the clamps, and when these screws are fully tightened, the clamps are rigidly fixed to the cylindrical part. At one end of the fixator, there is a dynamic slot through which a dynamic anti-rotation screw is inserted. This assembly allows for initially rigid fixation of fractures in the shaft, subtrochanteric, and supracondylar region. However, it also permits that, if biomechanical forces loosen the contact between the screw and the clamp, spontaneous transformation into dynamic fixation occurs, allowing compression at the fracture site and thereby stimulating the healing process. In addition to dynamic anti-rotation screw, the SIF-shaft (type of SIF without additional “unit”) at the other end contains a static anti-rotation screw. The number of clamps may vary depending on the surgeon’s assessment (Figure 1) [13, 14].

There are SIF implants of different lengths. For fractures extending proximally or distally from the shaft region, SIF-troch and SIF-cond implants with lengths of 250 mm and

Table 1. Distribution of patients and their age

Group	Patients (n)			Age [mean ± SD (min–max)] (years)
	Male	Female	Total	
SIF-troch	9	13	22	69.6 ± 14.5 (39–89)
SIF-shaft	11	24	35	69.9 ± 17 (22–91)
SIF-cond	8	25	33	73.2 ± 11.9 (23–90)
Total	28	62	90	71.0 ± 14.6 (22–91)

SIF-troch – femoral shaft fractures with proximal extension; SIF-shaft – femoral shaft fractures without proximal or distal extension; SIF-cond – femoral shaft fractures with distal extension

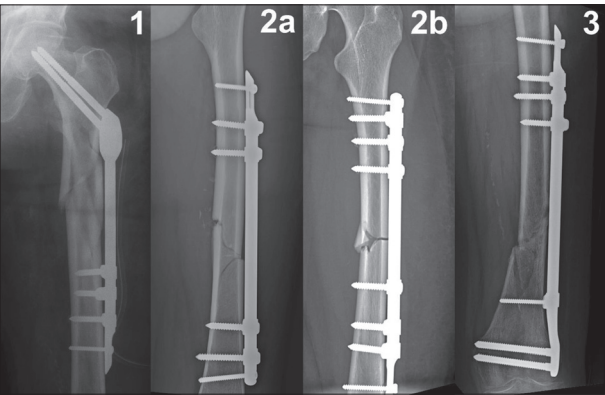


Figure 1. Types of Selfdynamizable Internal Fixator (SIF) used in fixation of femoral shaft fractures; 1 – SIF-troch (containing trochanteric unit in the implant) in the fracture extending into the subtrochanteric region; 2a, 2b – SIF-shaft (without additional unit in the implant) in fractures confined to the shaft region, with different SIF orientations and different numbers of clamps; 3 – SIF-cond (containing condylar unit in the implant) in the fracture extending into the supracondylar region

300 mm are used SIF-troch and SIF-cond implants of 150 mm or 200 mm are used only for fractures that do not extend from the subtrochanteric or supracondylar region into the femoral shaft). Therefore, only the patients with these longer implant lengths were analyzed in this study.

The values of operation time (minutes) and intraoperative fluoroscopy time (seconds) were analyzed among the groups, as well as the correlation between these parameters, for consecutive patients with available data, treated over a three-year period between 2022 and 2025. Operation time was defined as the time from initial skin incision to the wound suture completion. Statistical analysis was performed by IBM SPSS Statistics for Windows, Version 22.0. (IBM Corp., Armonk, NY, USA) using t-test and Mann–Whitney U test (to compare values), and Pearson’s and Spearman’s correlation coefficients (to analyze bivariate correlation). The level of significance set at $p < 0.05$.

Ethics: The study was performed in line with the Declaration of Helsinki and approved by the Ethics Board of the University Clinical Center Niš (Decision No. 29879).

RESULTS

The average operation time was the shortest in SIF-shaft group (where the fracture did not extend beyond the shaft region), while it was the longest in SIF-cond group. The

Table 2. Average values of operation time and fluoroscopy time in the groups (mean \pm SD), and parameters of their correlation

Group	Operation time (minutes)	Fluoroscopy time (seconds)	Correlation
SIF-troch	83.4 \pm 18.7	44.5 \pm 14.2	p = 0.139 r = 0.325
SIF-shaft	76.1 \pm 13.9	16.3 \pm 6.9	p = 0.012 rs = 0.418
SIF-cond	91.2 \pm 21.3	34.2 \pm 14	p = 0.104 r = 0.288

SIF-troch – femoral shaft fractures with proximal extension; SIF-shaft – femoral shaft fractures without proximal or distal extension; SIF-cond – femoral shaft fractures with distal extension

Table 3. Comparison of operation time and fluoroscopy time between the groups

Compared groups	Operation time	Fluoroscopy time
SIF-shaft, SIF-troch	p = 0.152*	p < 0.001*
SIF-shaft, SIF-cond	p = 0.001*	p < 0.001*
SIF-troch, SIF-cond	p = 0.001*	p = 0.010**

SIF-troch – femoral shaft fractures with proximal extension; SIF-shaft – femoral shaft fractures without proximal or distal extension; SIF-cond – femoral shaft fractures with distal extension;

*Mann-Whitney U Test;

**t-test

average fluoroscopy time was also shortest in SIF-shaft group, but longest in SIF-troch group (Table 2). The difference among the groups in terms of both operation time and fluoroscopy time was confirmed in all cases ($p < 0.05$), except for the comparison of operation times between SIF-shaft and SIF-troch groups ($p > 0.05$) (Table 3). A positive correlation between operation time and fluoroscopy time was confirmed in SIF-shaft group ($p < 0.05$), whereas in the other groups the correlation did not reach statistical significance but was close to ($p < 0.2$) (Table 2). The groups did not differ significantly with respect to gender or age distribution ($p > 0.05$).

DISCUSSION

In patients with fractures confined to the femoral shaft (SIF-shaft group), only shaft screws were used. Placement of these screws does not require strict fluoroscopic control during the positioning of each screw. If the second cortex is felt while screwing, just a single fluoroscopy after several screws placement could be sufficient. Furthermore, reduction of the fractures confined to the femoral shaft can be achieved quite easily while applying the SIF-shaft implant. The procedure begins with setting the rotation of the distal fragment through positioning on the traction table. Then two peripheral antirrotational screws are placed, followed by control of the fracture angulation in coronal and sagittal planes using bone-holding forceps while the remaining screws (screws for clamps) are inserted [14, 15]. The open technique does not necessarily require a single long incision; it can also be performed through the two smaller incisions, one of which includes both the fracture site and the screws at one end of the implant [19]. This can explain why, in fractures confined to the femoral shaft, both the operative time and fluoroscopy time were the

shortest. Since this approach provides good visual control of the fracture alignment, it also explains why the variability of the operative time was minimal and correlated to the fluoroscopy time.

Fixation of the femoral shaft fractures extending into the subtrochanteric region was performed in this study by the SIF type containing sliding screws for the proximal femur (SIF-troch). Sliding screws placement requires more fluoroscopic controls to prevent protrusion of the sliding screw outside the femoral neck and head [13, 15]. Since the proximal parts of the sliding screws are not directly visible intraoperatively, fluoroscopic verification is often repeated, resulting in the longest fluoroscopy time among the patient groups. Longer fluoroscopy time in this group is also influenced by the need for careful and occasionally challenging control of fracture angulation in proximal part while performing extramedullary fixation. The unconfirmed correlation between operative time and fluoroscopy time in this patient group could be explained by shorter duration of surgical steps that require frequent fluoroscopic verification (sliding screws setting) compared to the other steps of the surgery that do not involve frequent imaging (e.g., placement of the shaft screws and wound closure). For this reason, it could be considered that there was no significant difference in average operative times between the SIF-shaft and SIF-troch groups.

Operative time was longest in femoral shaft fractures extending into the supracondylar region, likely due to the difficulty of reduction, as the hamstrings tend to pull the fracture into recurvatum [11, 20]. Consequently, a traction table was not used in most patients in this study, further complicating the reduction and prolonging the surgery. Placement of distal locking screws in the condylar region requires fluoroscopic verification, sometimes repeated, explaining the longer fluoroscopy time compared to the SIF-shaft group. Nevertheless, inserting these screws usually requires fewer repeated fluoroscopic checks than inserting the sliding screws for the proximal femur, which may explain the shorter fluoroscopy time in the SIF-cond group compared to the SIF-troch group.

Concerning extramedullary fixation of femoral shaft fractures, few data are available in the literature regarding operation time and fluoroscopy time, and these mostly refer to the plate fixation. Park et al. [7] reported that plate fixation of femoral shaft fractures was associated with an average operative time of 104 minutes and an average fluoroscopy time of 109 seconds, both longer than in our study. However, Meccariello et al. [9] and Rollo et al. [21] reported shorter average operative times for plate fixation of femoral shaft fractures (62 min and 61 min). Regarding extramedullary fixation of the fractures extending in the subtrochanteric region, Yadav et al. [22] reported longer operation time (105 min) and fluoroscopy time (140 seconds) when using plates than in our study. El-Desouky et al. [19] compared conventional and biological plate fixation of subtrochanteric fractures and found that the operative time was longer (129 minutes vs. 92 minutes), while the fluoroscopy time was shorter (47 seconds vs. 80 seconds) when performing biological plate fixation [19].

In this regard, operative time in our study, for fractures extending into subtrochanteric region, corresponded more closely to conventional, while fluoroscopy time corresponded more closely to biological plate fixation. Erinc et al. [23] analyzed extramedullary plate fixation for supracondylar femoral fractures and reported longer operative time (126 minutes) compared to our findings for fractures extending into the supracondylar region. Comparative to the results in our study using SIF, the literature data listed above indicate both operative and fluoroscopy times tend to be longer when plate fixation is used for fractures extending into the subtrochanteric region, compared to fractures limited to the femoral shaft. It is noteworthy that similar trends have been reported for intramedullary fixation as well, with generally shorter operative times but longer fluoroscopy times than those observed in our study [5, 7, 9, 21, 22, 24, 25, 26].

Kelly et al. [27] found that the radiation dose received is significantly higher if the cumulative fluoroscopy time is less than 50 seconds. Considering this finding, the average results in our study suggest that the radiation dose in extramedullary fixation of femoral shaft fractures is generally lower (average fluoroscopy time was < 50 seconds) when using the SIF, in contrast to extramedullary fixation by plate reported in the literature, where the dose may be higher.

An earlier study by Mitkovic et al. [13] analyzed subtrochanteric fractures treated with SIF and reported that the average fluoroscopy time was almost the same (43 seconds) as in the present study on femoral shaft fractures extending into the subtrochanteric region, while the operative time was shorter (62 minutes). This difference in operative time may be explained by the fact that the subtrochanteric fracture study included various types of these fractures

– not only femoral shaft fractures extending into the subtrochanteric region, but also those treated by SIF-troch implants shorter than 250 mm (subtrochanteric fractures that do not extend into the shaft region). The similarity between these studies regarding fluoroscopy time confirms that fluoroscopy is primarily used for lag screw placement when using an SIF-troch implant.

CONCLUSION

Operation time in extramedullary fixation of femoral shaft fractures using SIF is shortest when the fracture is confined to the shaft region only and longest when the fracture extends into the supracondylar region. Intraoperative fluoroscopy time is shortest for fractures limited to the femoral shaft, and longest for fractures extending into the subtrochanteric region. Considering the average fluoroscopy time, the use of SIF generally results in a low expected radiation dose, regardless of whether the femoral shaft fracture extends into an adjacent region or not.

ACKNOWLEDGEMENTS

This study is supported by the project “Virtual human osteoarticular system and its application in pre-clinical and clinical practice” [No. III41017 and 451-03-137/2025-03/200113], funded by the Ministry of Science, Technological Development and Innovation of Republic of Serbia.

Conflict of interest: None declared.

REFERENCES

- Luthfi APWY, Hendarji A, Dalitan IM, Wedhanto S. Primary dynamic interlocking nail in femoral shaft fracture: A case series. *Int J Surg Case Rep.* 2023;105:108051. [DOI: 10.1016/j.ijscr.2023.108051] [PMID: 36996712]
- Fu BS, Zheng ZH. Surgical treatments for femoral shaft fractures: A narrative review. *Malays Orthop J.* 2023;17(3):5–8. [DOI: 10.5704/MOJ.2311.002] [PMID: 38107348]
- Salman LA, Al-Ani A, Radi MFA, Abudalou AF, Baroudi OM, Ajaj AA, et al. Open versus closed intramedullary nailing of femur shaft fractures in adults: a systematic review and meta-analysis. *Int Orthop.* 2023;47(12):3031–41. [DOI: 10.1007/s00264-023-05740-x] [PMID: 36864184]
- Gupte D, Axelrod D, Worthy T, Woolnough T, Selznick A, Johal H. Management of femoral shaft fractures: The significance of traction or operative position. *Cureus.* 2023;15(1):e33776. [DOI: 10.7759/cureus.33776] [PMID: 36798626]
- Ziegenhain F, Canal C, Halvachizadeh S, Mittlmeier A, Pape HC, Hierholzer C, et al. Outcome of femoral fractures treated with cerclages and intramedullary nailing. *Eur J Trauma Emerg Surg.* 2025;51(1):211. [DOI: 10.1007/s00068-025-02883-x] [PMID: 40392364]
- Strait RT, Pankey C. Submuscular plating versus elastic intramedullary nailing in children with femoral shaft fracture; a systematic review and meta-analysis. *J Clin Orthop Trauma.* 2023;42:102203. [DOI: 10.1016/j.jcot.2023.102203] [PMID: 37529550]
- Park KC, Oh CW, Byun YS, Oh JK, Lee HJ, Park KH, et al. Intramedullary nailing versus submuscular plating in adolescent femoral fracture. *Injury.* 2012;43(6):870–5. [DOI: 10.1016/j.injury.2011.10.032] [PMID: 22154047]
- Hosseini H, Heydari S, Domari AA, Raesi R, Hushmandi K, Faryabi R, et al. Comparison of treatment results of femoral shaft fracture with two methods of intramedullary nail (IMN) and plate. *BMC Surg.* 2024;24(1):318. [DOI: 10.1186/s12893-024-02590-1] [PMID: 39425143]
- Meccariello L, Bisaccia M, Ronga M, Falzarano G, Caraffa A, Rinonapoli G, et al. Locking retrograde nail, non-locking retrograde nail and plate fixation in the treatment of distal third femoral shaft fractures: radiographic, bone densitometry and clinical outcomes. *J Orthop Traumatol.* 2021;22(1):33. [DOI: 10.1186/s10195-021-00593-9] [PMID: 34350532]
- Denisiuk M, Afsari A. *Femoral Shaft Fractures.* Treasure Island (FL): StatPearls Publishing; 2021. [PMID: 32310517]
- Court-Brown C, McQueen M. M, Tornetta P. *Trauma.* Philadelphia: Lippincott Williams & Wilkins; 2006.
- May C, Yen YM, Nasreddine AY, Hedequist D, Hresko MT, Heyworth BE. Complications of plate fixation of femoral shaft fractures in children and adolescents. *J Child Orthop.* 2013;7(3):235–43. [DOI: 10.1007/s11832-013-0496-5] [PMID: 24432082]
- Mitkovic MM, Milenkovic S, Micic I, Kostic I, Stojiljkovic P, Mitkovic MB. Operation time and intraoperative fluoroscopy time in different internal fixation methods for subtrochanteric fractures treatment. *Srp Arh Celok Lek.* 2018;146(9–10):543–8. [DOI: 10.2298/SARH180220042M]
- Zivanovic D, Radovanovic Z, Slavkovic A, Marjanovic Z. Internal fixator Mitkovic in the treatment of fractures of femoral shaft - a possible solution for fractures in heavier children and adolescents. *Acta Chir lug.* 2015;62(1):45–7. [DOI: 10.2298/ACI1501045Z]

15. Mitkovic MB, Milenkovic S, Micic I, Mladenovic D, Mitkovic MM. Results of the femur fractures treated with the new selfdynamisable internal fixator (SIF). *Eur J Trauma Emerg Surg*. 2012;38(2):191–200. [DOI: 10.1007/s00068-011-0157-7] [PMID: 22611442]
16. Canciglieri OJ, Trajanovic MD, editors. *Personalized orthopaedics*. Cham: Springer; 2022. [DOI: 10.1007/978-3-030-98279-9]
17. Fu R, Liu Y, Song F, Fu J, Du T, Liu Y, et al. Effects of dynamization timing and degree on bone healing of different fracture types. *J Orthop Res*. 2023;41(11):2394–404. [DOI: 10.1002/jor.25583] [PMID: 37138390]
18. Fu R, Feng Y, Liu Y, Willie BM, Yang H. The combined effects of dynamization time and degree on bone healing. *J Orthop Res*. 2022;40(3):634–43. [DOI: 10.1002/jor.25060] [PMID: 33913530]
19. El-Desouky II, Mohamed MM, Kandil AE. Clinical outcome of conventional versus biological fixation of subtrochanteric fractures by proximal femoral locked plate. *Injury*. 2016;47(6):1309–17. [DOI: 10.1016/j.injury.2016.03.016] [PMID: 27015752]
20. Streubel PN, Gardner MJ, Morshed S, Collinge CA, Gallagher B, Ricci WM. Are extreme distal periprosthetic supracondylar fractures of the femur too distal to fix using a lateral locked plate? *J Bone Joint Surg Br*. 2010;92-B(4):527–34. [DOI: 10.1302/0301-620X.92B3.22996] [PMID: 20357329]
21. Rollo G, Bisaccia M, Rinonapoli G, Caraffa A, Pace V, Irimia JC, et al. Radiographic, bone densitometry and clinic outcomes assessments in femoral shaft fractures fixed by plating or locking retrograde nail. *Med Arch*. 2019;73(3):195–200. [DOI: 10.5455/medarh.2019.73.195-200] [PMID: 31404125]
22. Yadav S, Sinha S, Luther E, Arora NC, Prasad M, Varma R. Comparison of extramedullary and intramedullary devices for treatment of subtrochanteric femoral fractures at tertiary level center. *Chin J Traumatol*. 2014;17(3):141–5. [DOI: 10.3760/cma.j.issn.1008-1275.2014.03.004] [PMID: 24889976]
23. Erinc S, Cam N, Kanar M, Mustafa Ozdemir H. Comparison of two surgical techniques for periprosthetic supracondylar femoral fractures: Minimally invasive locking plate versus retrograde femoral nails. *Sisli Etfal Hastan Tip Bul*. 2021;55(4):477–85. [DOI: 10.14744/SEMB.2021.34270] [PMID: 35317368]
24. Kang SJ, Bao FL, Huang DS, Jiang T, Hu YM, Li JM, et al. Percutaneous cerclage wiring combined with cephalomedullary nailing for irreducible subtrochanteric fractures. *Orthop Surg*. 2021;13(6):1899–911. [DOI: 10.1111/os.13144] [PMID: 34435729]
25. White M, Dejenie R, Tse S, Brooks B, Scott M, Chavez G, et al. Radiographic and clinical outcomes of traumatic subtrochanteric femur fracture fixation and reduction methods. *Eur J Orthop Surg Traumatol*. 2025;35(1):352. [DOI: 10.1007/s00590-025-04478-z] [PMID: 40826299]
26. Zhu Y, Lu B, Ouyang C, Gu S. Application of anterior minimally invasive clamping technique combined with lower extremity axial bone traction device in irreducible intertrochanteric fractures. *Front Surg*. 2025;12:1584651. [DOI: 10.3389/fsurg.2025.1584651] [PMID: 40969307]
27. Kelly GA, Rowan FE, Hurson C. Factors influencing radiation exposure during internal fixation of hip fractures. *Eur J Orthop Surg Traumatol*. 2017;27(5):637–41. [DOI: 10.1007/s00590-017-1951-7] [PMID: 28396949]

Утицај ширења прелома дијафизе бутне кости у суптрохантерну или супракондиларну регију на трајање операције и интраоперативне флуороскопије при динамичкој екстрамедуларној фиксацији

Милан М. Митковић^{1,2}, Саша С. Миленковић^{1,2}, Предраг М. Стојиљковић^{1,2}, Младен Ј. Стојановић¹, Никола Ј. Костић¹, Милош А. Нагорни¹

¹Универзитетски клинички центар Ниш, Клиника за ортопедију и трауматологију „Академик проф. др Милорад Митковић“, Ниш, Србија;

²Универзитет у Нишу, Медицински факултет, Ниш, Србија

САЖЕТАК

Увод/Циљ Иако се преломи дијафизе бутне кости данас најчешће лече интрамедуларном фиксацијом, постоје ситуације у којима је пожељније извршити њихову екстрамедуларну фиксацију. Циљ овог рада било је испитивање утицаја ширења прелома дијафизе бутне кости у суседну анатомску регију на трајање операције и интраоперативне флуороскопије.

Метод У раду је анализирано 90 случајева код којих је прелом дијафизе бутне кости лечен самодинамизирајућим унутрашњим фиксатором (*SIF*). Испитаници су подељени у три групе – преломи дијафизе бутне кости који се шире проксимално (*SIF-troch*), преломи дијафизе бутне кости који се не шире ни проксимално ни дистално (*SIF-shaft*) и преломи дијафизе бутне кости који се шире дистално (*SIF-cond*).

Резултати Просечно трајање операције било је најкраће код прелома који се нису ширили у суседну регију (*SIF-shaft* група), а најдуже код прелома који су се ширили у супра-

кондиларну регију (*SIF-cond* група). Просечно трајање флуороскопије било је најкраће у *SIF-shaft* групи, а најдуже код прелома који су се ширили у суптрохантерну регију (*SIF-troch* група). Сматра се да су на дужину операције у примењеним хируршким процедурама утицали техника контроле увођења клизних завртњева у проксимални део и закључавајућих завртњева у дистални део бутне кости, као и техника интраоперативног одржавања репозиције прелома у суптрохантерној и супракондиларној регији.

Закључак Ширење прелома дијафизе бутне кости у суптрохантерну или супракондиларну регију праћено је просечно дужим трајањем операције и флуороскопије. Уз пружање могућности динамизације у екстрамедуларној фиксацији, *SIF* пружа и релативно једноставну и брзо изводљиву технику фиксације прелома дијафизе бутне кости, нарочито када се прелом не шири у суседну анатомску регију.

Кључне речи: самодинамизирајући унутрашњи фиксатор; дијафиза; флуороскопија