



CURRENT TOPIC / AKTUELNA TEMA

Acute pericarditis and cardiac tamponade – bridging the gap between diagnosis and management

Dejan Simeunović^{1,2}, Stefan Juričić¹, Nina Gatarić¹, Marko Ristić¹, Filip Simeunović², Ivan Milinković^{1,2}, Valerija Perić¹, Ratko Lasica^{1,2}, Arsen Ristić^{1,2}

¹University Clinical Center of Serbia, Clinic for Cardiology, Belgrade, Serbia;

²University of Belgrade, Faculty of Medicine, Belgrade, Serbia

SUMMARY

Acute pericarditis arises from an inflammatory process affecting the pericardial tissue, leading to the subsequent formation of pericardial effusion as part of the body's inflammatory response. Cardiac tamponade occurs when a significant volume of fluid accumulates within the pericardial cavity, resulting in increased intrapericardial pressure and impaired diastolic filling, ultimately obstructing blood flow into the heart. Notably, even a relatively small pericardial effusion can precipitate tamponade, depending on the rate of fluid accumulation and the compliance of the pericardium. Pericardiocentesis remains the preferred intervention for the emergent management of patients presenting with cardiac tamponade. This procedure is typically performed via a subxiphoid or apical approach, with the selection of the access site guided by the distribution of the effusion as visualized on imaging. The timely execution of pericardiocentesis during the acute phase of tamponade is of paramount importance; failure to perform the procedure promptly may result in cardiovascular collapse, cardiac arrest, and ultimately, a potentially fatal outcome.

Keywords: acute pericarditis; pericardial effusion; cardiac tamponade; pericardiocentesis

INTRODUCTION

Pericardial diseases are most often categorized based on their duration and clinical course into three main types: acute (lasting less than six weeks), subacute, and chronic (lasting more than six months). These conditions are further classified into distinct syndromes according to their clinical presentation, which includes acute pericarditis, pericardial effusion, cardiac tamponade, recurrent pericarditis, and constrictive pericarditis – either transient or chronic in nature [1]. In routine clinical practice, patients diagnosed with acute pericarditis, provided the condition does not progress to pericardial effusion, generally exhibit a favourable prognosis. However, even a minimal accumulation of fluid within the pericardial space has the potential to induce cardiac tamponade, with clinical manifestations often occurring within hours of fluid build-up. These patients frequently present with symptoms and signs such as dyspnea, hypotension, tachycardia, jugular venous distention, diminished heart sounds, and paradoxical pulse. Cardiac tamponade is regarded as a medical emergency that calls for immediate intervention, typically in the form of pericardiocentesis. Failure to address this condition promptly can result in severe complications, including cardiac arrest and, ultimately, a fatal outcome if left untreated [2].

ACUTE PERICARDITIS

The pericardium, often referred to as the heart sac, consists of two primary layers: the visceral pericardium, a serous membrane that is separated by a small amount of fluid (ranging from 15–50 mL) from the fibrous parietal pericardium. In healthy individuals, the pericardium serves several critical functions, including the prevention of sudden and excessive expansion of the heart chambers during physical exertion or states of hypervolemia, which can impose a significant hemodynamic load on the heart due to the increased circulating blood volume. Under normal physiological conditions, the pressure within the pericardial space remains negative, which facilitates the smooth filling of the atria during systole. Moreover, the pericardium plays a vital role in maintaining the heart's anatomical position within the chest cavity, reducing friction between the heart and adjacent mediastinal structures, preventing the kinking or distortion of large blood vessels, and acting as a barrier to prevent the spread of inflammatory processes from the lungs or pleural space to the heart [1, 2].

Acute pericarditis represents the most prevalent pathological condition involving the pericardium, with its occurrence in the general population estimated to range from 0.2% to 0.5%. Autopsies reveal its incidental presence in up to 1% of cases. The etiology of acute pericarditis is multifactorial, with the most common cause being viral infections, especially those

Received • Примљено:

September 27, 2024

Accepted • Прихваћено:

May 13, 2025

Online first: May 14, 2025

Correspondence to:

Nina GATARIĆ
University Clinical Center of Serbia
Clinic for Cardiology,
Pasterova 2
11000 Belgrade
Serbia
gataricnina@gmail.com

caused by cardiotropic viruses such as Coxsackie, adenoviruses, and echoviruses. Additionally, the condition may arise from local or systemic autoimmune disorders, various metabolic disturbances, or, in more severe instances, from the infiltration of malignant cells into the pericardium [3, 4]. Acute pericarditis can also occur less frequently following chest radiotherapy, or as a result of fungal or parasitic infections, further emphasizing the broad spectrum of underlying causes for this condition [5–8].

The inflammatory process affecting the pericardial tissue induces severe pain due to the dense network of nerve endings derived from the phrenic nerve. This neural involvement also explains the characteristic radiation of pain to the trapezius muscle. Furthermore, any electrocardiographic changes, as well as potential rhythm disturbances and conduction abnormalities observed in acute pericarditis, stem from the inflammatory response in the myocardium, given that the pericardium itself is electrically neutral [9, 10]. The inflammatory involvement of the myocardium may further contribute to transient arrhythmias or alterations in cardiac conduction, necessitating close monitoring in affected patients.

Under normal physiological conditions, the pericardium exhibits selective permeability to water and electrolytes, which are integral components of pericardial fluid. This fluid remains in a state of dynamic equilibrium with the circulating blood. However, inflammation disrupts this delicate balance, leading to the localized release of pro-inflammatory mediators that stimulate excessive fluid secretion from the visceral pericardium. Additionally, the inflammatory response results in the accumulation of large molecular substances that further draw fluid into the pericardial space while simultaneously impairing its reabsorption, ultimately leading to the development of pericardial effusion [11, 12, 13]. The progressive accumulation of fluid may exert pressure on the heart chambers, potentially compromising hemodynamic stability.

The diagnosis of acute pericarditis necessitates the presence of at least two of the following clinical criteria: chest pain that worsens with deep inspiration, changes with body movement, and radiates to the trapezius muscle; auscultation of a pericardial friction rub; characteristic electrocardiographic changes, such as diffuse concave ST-segment elevation and PR-segment depression; low voltage in standard electrocardiogram leads (Figure 1); radiographic and echocardiographic evidence of pericardial effusion (Figure 2); and elevated inflammatory markers, particularly C-reactive protein [14, 15]. Early recognition and diagnosis are essential for timely intervention, to prevent potential complications associated with pericardial inflammation.

Accurate detection of clinical symptoms and signs that manifest during pericardial effusion or cardiac tamponade can often provide crucial diagnostic insights into the underlying etiology. The presence of cardiac tamponade without a concomitant elevation in inflammatory markers is associated with up to a threefold higher probability of a malignant origin. Additionally, patients with recurrent pericarditis who experience acute episodes that do not respond to nonsteroidal anti-inflammatory drugs (NSAIDs)

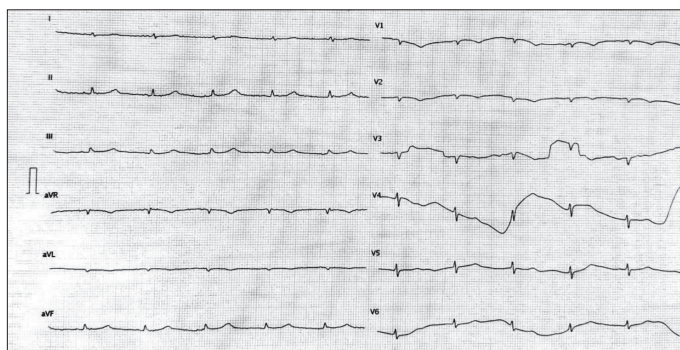


Figure 1. Typical electrocardiographic findings in cardiac tamponade (low voltage in standard leads)

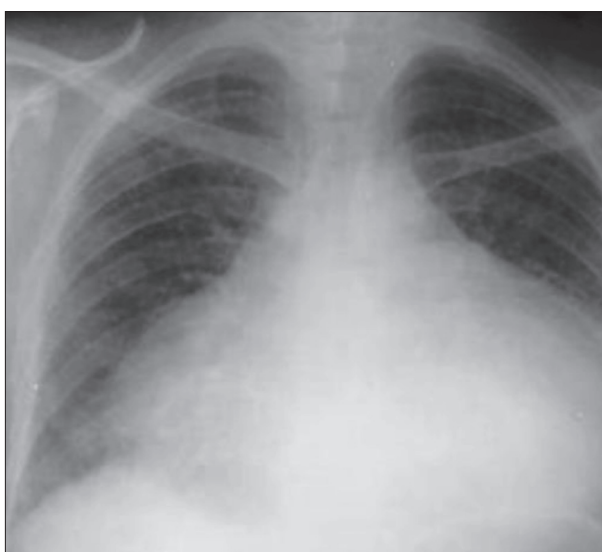

Figure 2. Radiography finding in pericardial effusion

exhibit a tenfold increased likelihood of pericardial effusion of malignant etiology. Furthermore, in oncological patients, the etiology of pericardial effusion is up to 20 times more likely to be malignant compared to individuals without a known malignancy, underscoring the need for thorough evaluation and appropriate management [16, 17].

The treatment of acute pericarditis of viral origin primarily focuses on symptom relief, the prevention of complications, and the management of the underlying cause. The initial approach includes the administration of analgesics and anti-inflammatory medications, which are gradually tapered as clinical symptoms improve. High-dose NSAIDs remain the cornerstone of acute pericarditis therapy, with commonly prescribed regimens including ibuprofen (600–800 mg, three times daily), indomethacin (25–50 mg, three times daily), or aspirin (750–1000 mg, three times daily). Adequate hydration and gastroprotective agents, such as proton pump inhibitors, are often recommended alongside NSAID therapy to mitigate gastrointestinal side effects [18, 19].

In addition to NSAIDs, colchicine is administered for a minimum duration of three months at a dose of 0.5 mg twice daily, or a reduced dose of 0.25 mg twice daily for patients weighing less than 70 kg. In recurrent pericarditis, Colchicine therapy may be extended to six months or

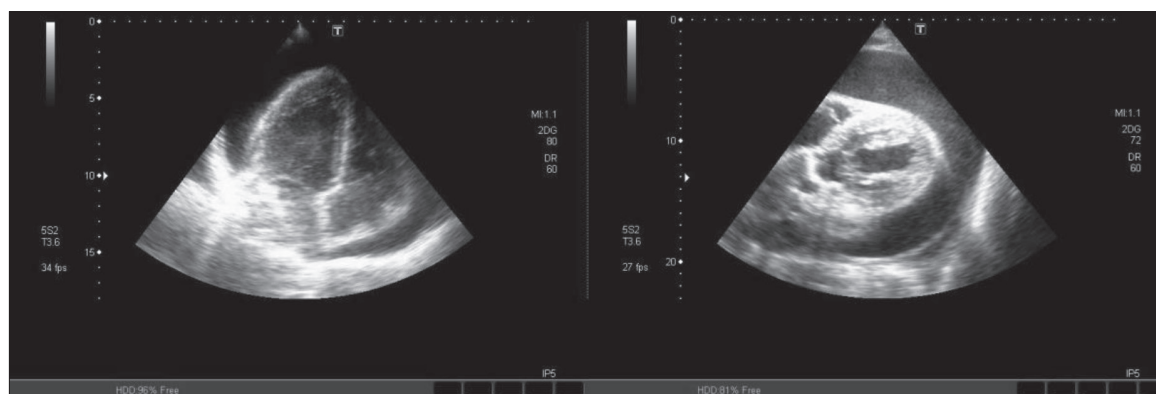


Figure 3. Echocardiographic findings in threatening cardiac tamponade; “Swinging heart” sign, where the heart moves like a pendulum within a massive pericardial effusion

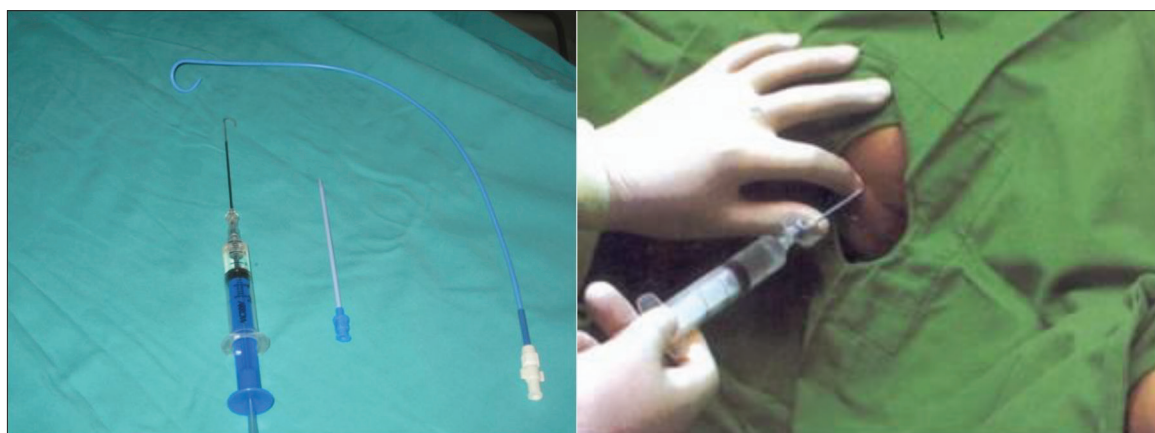


Figure 4. Pericardiocentesis set (left figure); intercostal puncture is performed along the upper edge of the lower rib not to harm the intercostal arteries (right figure)

longer to reduce the risk of relapse. The use of corticosteroids is generally discouraged during the acute phase due to their potential to increase the risk of recurrence. However, in cases where patients fail to respond to NSAIDs and colchicine, corticosteroids (0.2–0.5 mg / kg / day of methylprednisolone) may be introduced with caution, with careful monitoring for potential complications such as opportunistic infections [20, 21].

Biologic therapy, particularly the interleukin-1 receptor antagonist anakinra (2 mg / kg / day up to 100 mg/day), is an emerging treatment option that has demonstrated efficacy in refractory or recurrent pericarditis. Ongoing clinical studies continue to evaluate its long-term benefits and safety profile. In patients with frequent and disabling relapses persisting for more than two years despite optimal medical therapy, surgical intervention in the form of pericardiectomy is often considered as a definitive treatment to prevent further episodes [22–25].

CARDIAC TAMPONADE

Cardiac tamponade refers to the accumulation of a significant volume of fluid within the pericardial cavity, resulting in hemodynamic compromise due to the obstruction of venous return and subsequent impairment of cardiac filling. This leads to reduced cardiac output and, if left untreated, can progress to cardiovascular collapse. The most common

etiologies of cardiac tamponade include neoplastic and viral pericarditis, although it can also arise from intrapericardial hemorrhage due to trauma, malignancy, aortic dissection, post-myocardial infarction free wall rupture, or iatrogenic cardiac perforation during interventional procedures such as catheter-based interventions or pacemaker lead placement [26].

In some cases, even a relatively small volume of pericardial fluid (approximately 200 mL) can precipitate tamponade if it accumulates acutely, as the pericardium has limited time to adapt to the increased intrapericardial pressure. In contrast, chronic fluid accumulation over an extended period may allow the pericardium to stretch and accommodate volumes of up to 2000 mL, depending on factors such as myocardial compliance, pericardial elasticity, and intracardiac pressures. The classic “Beck’s triad” of hypotension, elevated jugular venous pressure, and muffled heart sounds is typically observed only in cases of severe, rapidly developing cardiac tamponade. When tamponade develops more gradually, the clinical presentation often mimics that of congestive heart failure, manifesting as dyspnea, orthopnea, hepatomegaly, and jugular venous distension. Notably, pulmonary auscultation in these patients typically reveals no evidence of congestion, distinguishing tamponade from primary pulmonary causes of heart failure [27].

The earliest echocardiographic indication of evolving cardiac tamponade is right atrial collapse, followed

by right ventricular diastolic collapse, and in more severe cases, compression of the left atrium or left ventricle. In large pericardial effusions, the heart may appear to “swing” within the pericardial sac, a phenomenon referred to as the “swinging heart” or “floating heart” sign [14] (Figure 3). Given its life-threatening nature, cardiac tamponade constitutes an absolute indication for emergent pericardial drainage, which can be performed via pericardiocentesis (Figure 4) or, in select cases, surgical pericardial window creation (pericardotomy). Pharmacological interventions are considered adjunctive and should not delay definitive drainage of the effusion. Patients with hypovolemia should receive continuous intravenous fluid resuscitation to maintain preload, while those with hypoxia or impending respiratory failure should be promptly intubated and mechanically ventilated in preparation for pericardiocentesis [28].

Following pericardiocentesis, it is imperative to conduct a comprehensive biochemical, bacteriological, and cytological analysis of the evacuated pericardial fluid in all patients presenting with pericardial effusion. This step is critical for identifying the underlying etiology and guiding further therapeutic management. In cases where malignancy is suspected, additional diagnostic measures such as pericardial biopsy or advanced molecular testing may be warranted to confirm the diagnosis and tailor treatment strategies [26, 27, 28].

CONCLUSION

The overall prognosis for patients with acute pericarditis is generally favorable, particularly when the condition is promptly diagnosed and appropriately managed. Although acute pericarditis can occur at any age, it is more commonly observed in younger individuals and males. The clinical presentation varies, with most patients experiencing mild to moderate symptoms. However, in some cases, the initial

symptoms can be severe, and a characteristic pericardial friction rub is frequently detected upon auscultation. The duration of the illness typically ranges from a few days to four weeks, but approximately 25% of patients may experience one or more recurrences. While some individuals may develop significant pericardial effusion, progression to cardiac tamponade remains uncommon.

Constrictive pericarditis, though rare, is a potential long-term complication often associated with recurrent episodes of the disease. This condition is characterized by pericardial thickening and fibrosis, leading to impaired diastolic filling of the heart. Given the severity of this complication, urgent clinical evaluation by an experienced invasive cardiologist is essential for optimal management. Echocardiography remains the gold standard for the rapid identification of acute cardiac tamponade, complemented by clinical assessment, electrocardiographic findings, and radiographic imaging. In cases of hemodynamically significant tamponade, immediate pericardial drainage is required. Pericardiocentesis, typically performed via a subxiphoid or apical approach under echocardiographic or fluoroscopic guidance, is the preferred intervention for emergent relief of pericardial pressure. Delayed intervention during the acute phase of cardiac tamponade may result in cardiovascular collapse, cardiac arrest, and potentially a fatal outcome. Therefore, prompt recognition and timely management are critical in reducing morbidity and mortality associated with this life-threatening condition.

Ethics: The authors hereby declare that this article was prepared in full compliance with the ethical standards set forth by the journal Serbian Archives of Medicine, as well as the ethical guidelines and institutional policies adhered to by each author involved in the research and writing process.

Conflict of interest: None declared.

REFERENCES

- Sathirareungchai S, Armstrong S. The pathology of pericarditis. *Diagn Histopathol*. 2022;28(4):191–8. [DOI: 10.1016/j.mpdhp.2022.01.002]
- Ismail TF. Acute pericarditis: Update on diagnosis and management. *Clin Med (Lond)*. 2020;20(1):48–51. [DOI: 10.7861/clinmed.cme.20.1.4] [PMID: 31941732]
- Nassar AH, Abou Alaiwi S, El Zarif T, Denu R, Macaron W, Abdel-Wahab N, et al. Safety and efficacy of immune checkpoint therapy for the treatment of patients with cardiac metastasis: a multicenter international retrospective study. *J Immunother Cancer*. 2025;13(3):e009364. [DOI: 10.1136/jitc-2024-009364] [PMID: 40032601]
- Michaels KC, Dougherty SC, Kurpiel BR, Douvas MG. Primary Mediastinal Synovial Sarcoma with Pericardial Involvement: A Case Report. *Case Rep Oncol*. 2024;18(1):76–84. [DOI: 10.1159/000542680] [PMID: 39980501]
- Prakash A, Rawat SS, Russal Starlet A, Kumar A. Pericardial thymoma presenting as cardiac tamponade in an adult. *BMJ Case Rep*. 2025;18(1):e262379. [DOI: 10.1136/bcr-2024-262379] [PMID: 39890412]
- Zamora KDV, Vera-Chávez JS, Aranda-Fraustro A, Duarte-Gutiérrez MA, Vargas-Guerrero A, Altamirano-Solorzano GA, et al. Recurrent Cardiac Tamponade by Pulmonary Artery Intimal Sarcoma. *Echocardiography*. 2025;42(1):e70068. [DOI: 10.1111/echo.70068] [PMID: 39737669]
- Nakajima T, Mukawa K, Kouzu H, Kamada A, Kawaharada N. Prevention of cardiac tamponade by left intercostal Pericardiotomy for massive recurrent pericardial effusion: a case report. *Oxf Med Case Reports*. 2024;2024(1):omae139. [DOI: 10.1093/omcr/omae139] [PMID: 39588504]
- Andreis A, Dossi FC, De Ferrari GM, Alunni G, Imazio M. Anakinra-Dependent Recurrent Pericarditis: The Role of the R202Q Variant of the MEFV Gene. *J Clin Med*. 2024;13(20):6051. [DOI: 10.3390/jcm13206051] [PMID: 39458001]
- Klein AL, Wang TKM, Cremer PC, Abbate A, Adler Y, Asher C, et al. Pericardial Diseases: International Position Statement on New Concepts and Advances in Multimodality Cardiac Imaging. *JACC Cardiovasc Imaging*. 2024;17(8):937–88. [DOI: 10.1016/j.jcmg.2024.04.010] [PMID: 39111992]
- Cremer PC, Klein AL, Imazio M. Diagnosis, Risk Stratification, and Treatment of Pericarditis: A Review. *JAMA*. 2024;332(13):1090–100. [DOI: 10.1001/jama.2024.12935] [PMID: 39235771]
- Kivity S, Baran TZ, Reuveni MM, Irony A, Adler L, Alder Y, et al. The Longitudinal Incidence of Pericarditis in 1.6 Million Patients: A 20-Year Study. *Am J Cardiol*. 2024;223:70–2. [DOI: 10.1016/j.amjcard.2024.05.012] [PMID: 38777208]

12. Wan Muhamad Hatta SS, Mirza AR, Sunni N, Bashir A. Heart-breaking tumours: a case series of malignant pericardial effusion. *Eur Heart J Case Rep.* 2025;9(3):yaf009. [DOI: 10.1093/ehjcr/yaf009] [PMID: 40046975]
13. Buckley LF, Libby P. Colchicine's Role in Cardiovascular Disease Management. *Arterioscler Thromb Vasc Biol.* 2024;44(5):1031–41. [DOI: 10.1161/ATVBAHA.124.319851] [PMID: 38511324]
14. Collini V, Andreis A, De Biasio M, De Martino M, Isola M, Croatto N, et al. Efficacy of colchicine in addition to anakinra in patients with recurrent pericarditis. *Open Heart.* 2024;11(1):e002599. [DOI: 10.1136/openhrt-2023-002599] [PMID: 38490715]
15. Toker Dincer Z, Karup S, Yilmaz E, Corbali O, Azman FN, Melikoglu M, et al. Anakinra in idiopathic recurrent pericarditis: a comprehensive case series and literature review. *Z Rheumatol.* 2024;83(7):587–96. [DOI: 10.1007/s00393-023-01471-x] [PMID: 38277021]
16. Yesilyaprak A, Kumar AK, Agrawal A, Furqan MM, Verma BR, Syed AB, et al. Predicting Long-Term Clinical Outcomes of Patients With Recurrent Pericarditis. *J Am Coll Cardiol.* 2024;84(13):1193–204. [DOI: 10.1016/j.jacc.2024.05.072] [PMID: 39217549]
17. Adler Y, Ristić AD, Imazio M, Brucato A, Pankuweit S, Burazor I, et al. Cardiac tamponade. *Nat Rev Dis Primers.* 2023;9(1):36. [DOI: 10.1038/s41572-023-00446-1] [PMID: 37474539]
18. Imazio M, Andreis A, Lubian M, Lazaros G, Lazarou E, Brucato A, et al. The Torino Pericarditis Score: a new-risk stratification tool to predict complicated pericarditis. *Intern Emerg Med.* 2021;16(7):1921–6. [DOI: 10.1007/s11739-021-02803-y] [PMID: 34275095]
19. Lazaros G, Oikonomou V, Oikonomou E, Aznaouridis K, Vlachopoulos C, Vogiatzi G, et al. Recurrence of Pericardial Effusion After Pericardiocentesis: Does Catheter-Induced Acute Pericardial Inflammation Play a Role? *Am J Med Sci.* 2021;361(5):676–8. [DOI: 10.1016/j.amjms.2020.10.012] [PMID: 33243434]
20. Othon-Martinez D, Lopez OJ, Daza J, Malaga-Espinoza BX, Ganiyu S, Tijani A. Unlocking the Mystery: Resident-Led POCUS Intervention in Community Hospital Revealing Pericardial Tamponade in a Complex Case. *J Investig Med High Impact Case Rep.* 2025;13:23247096241298172. [DOI: 10.1177/23247096241298172] [PMID: 40019160]
21. Ebrahimi P, Taheri H, Bahraie P, Rader F, Siegel RJ, Mandegar MH, et al. Incidence of secondary pericardial effusions associated with different etiologies: a comprehensive review of literature. *J Cardiothorac Surg.* 2025;20(1):141. [DOI: 10.1186/s13019-025-03370-5] [PMID: 39987086]
22. Mandyam S, Onteddu J, Ray R, Basso R, Bader F, Onteddu NK. Multicentric Reticulohistiocytosis Presenting As Acute Pericarditis With Moderate-Sized Pericardial Effusion: A Case Report and Review of Multicentric Reticulohistiocytosis Treatment. *Cureus.* 2023;15(6):e39953. [DOI: 10.7759/cureus.39953] [PMID: 37416020]
23. Simeunović DS, Milinković I, Polovina M, Trifunović Zamaklar D, Veljić I, Zaharijev S, et al. Safety and Efficacy of Echo- vs. Fluoroscopy-Guided Pericardiocentesis in Cardiac Tamponade. *Medicina.* 2025;61(2):265. [DOI: 10.3390/medicina61020265] [PMID: 40005382]
24. Lasica R, Asanin M, Vukmirovic J, Maslac L, Savic L, Zdravkovic M, et al. What Do We Know about Peripartum Cardiomyopathy? Yesterday, Today, Tomorrow. *Int J Mol Sci.* 2024;25(19):10559. [DOI: 10.3390/ijms251910559] [PMID: 39408885]
25. Lasica R, Djukanovic L, Mrdovic I, Savic L, Ristic A, Zdravkovic M, et al. Acute Coronary Syndrome in the COVID-19 Era-Differences and Dilemmas Compared to the Pre-COVID-19 Era. *J Clin Med.* 2022;11(11):3024. [DOI: 10.3390/jcm11113024] [PMID: 35683411]
26. Milinkovic I, Ašanin M, Simeunovic DS, Seferović PM. In the search for an ideal registry: Does the cloud have a silver lining? *Eur J Prev Cardiol.* 2018;25(9):956–9. [DOI: 10.1177/2047487318774420] [PMID: 29719967]
27. Milinković I, Polovina M, Simeunović DS, Ašanin M, Seferović PM. Oxidative stress and inflammation in heart failure: The best is yet to come. *Eur J Prev Cardiol.* 2020;27(5):490–3. [DOI: 10.1177/2047487319900294] [PMID: 32013599]
28. Shawamri S, Šačić D, Ristić M, Milivojević I. Concurrent Acute Myocardial Infarction and Stroke: Challenges in Diagnosis and Treatment. *Int Heart J.* 2024;65(5):956–9. [DOI: 10.1536/ihj.24-204] [PMID: 39343598]

Акутни перикардитис и тампонада срца – премошћавање јаза између дијагностике и лечења

Дејан Симеуновић^{1,2}, Стефан Јуричић¹, Нина Гатарић¹, Марко Ристић¹, Филип Симеуновић², Иван Милинковић^{1,2}, Валерија Перић¹, Ратко Ласица^{1,2}, Арсен Ристић^{1,2}

¹Универзитетски клинички центар Србије, Клиника за кардиологију, Београд, Србија;

²Универзитет у Београду, Медицински факултет, Београд, Србија

САЖЕТАК

Акутни перикардитис настаје као последица запаљенског процеса у перикардном ткиву, а као одговор на инфламацију долази до развоја перикардног излива. Срчана тампонада представља накупљање значајне количине течности у перикардном простору, што онемогућава адекватан прилив крви у срце. Акутно накупљање чак и мање количине течности у перикардном простору може довести до срчане тампонаде. Перикардиоцентеза представља најчешће коришћени

поступак за ургентно збрињавање болесника са срчаном тампонадом и обично се изводи субкисиформидним или апи-калним приступом, у зависности од дистрибуције излива. Правовремено извођење овог захвата током акутне фазе болести је од суштинског значаја, јер у супротном срчана тампонада може довести до срчаног застоја и тиме, потенцијално, до фаталног исхода.

Кључне речи: акутни перикардитис; перикардни излив; срчана тампонада; перикардиоцентеза