

## CASE REPORT / ПРИКАЗ БОЛЕСНИКА

# Diffuse large B-cell type of the primary non-Hodgkin's lymphoma of the liver – a diagnostic problem

Dragan Basarić<sup>1,2</sup>, Stefan Milošević<sup>3</sup>, Nebojša Lekić<sup>1,2</sup>, Dušan Šaponjski<sup>2,3</sup>, Milica Mitrović-Jovanović<sup>2,3</sup><sup>1</sup>University Clinical Center of Serbia, Clinic for Digestive Surgery, Belgrade, Serbia;<sup>2</sup>University of Belgrade, Faculty of Medicine, Belgrade, Serbia;<sup>3</sup>University Clinical Center of Serbia, Center of Radiology, Belgrade, Serbia**SUMMARY****Introduction** Primary Non-Hodgkin lymphoma of the liver is an extremely rare disease. It most often occurs as a diffuse large B-cell type.**Case outline** We present the case of a 75-year-old patient who was admitted to our clinic with right-sided subcostal pain accompanied by malaise, weakness, and elevated body temperature. Laboratory analyzes were within normal limits. Ultrasonography and computed tomography findings showed a sharply marginated inhomogeneous lesion in the right liver lobe with central necrosis. Intraoperatively and pathohistologically, it was confirmed that it was diffuse large B-cell lymphoma of the liver. Surgery, chemotherapy, radiotherapy and their combination are the methods of treatment.**Conclusion** Surgical treatment with chemotherapy allows for a significantly higher survival rate.**Keywords:** Non-Hodgkin lymphoma; liver; diagnosis; treatment**INTRODUCTION**

Lymphomas are a type of malignant disease that develops in lymph nodes and lymphatic tissue of other organs [1]. There are two main types of lymphoma: Hodgkin's disease and non-Hodgkin's lymphoma. Non-Hodgkin's lymphoma is divided into two types: diffuse large B-cell lymphoma (DLBCL) and follicular type [1, 2]. They are manifested by lymphadenopathy that can occur in any part of the body [2]. Lymph nodes are enlarged, hard in consistency and painless [3].

Extranodal forms of non-Hodgkin's lymphoma (about 40%) occur most often at the head and neck [3]. Primary non-Hodgkin lymphoma of the liver is an extremely rare disease. The tumor is most often solitary and located in the right lobe of the liver [4, 5]. The most common form of primary non-Hodgkin's lymphoma of the liver is the DLBCL [3, 4]. Secondary liver lymphomas are usually multiple and correspond to the progression of the primary nodal form of the disease (50%) [5, 6].

Middle-aged men are most often affected, especially those with underlining immunocompromising diseases [6, 7, 8]. Weight loss, elevated body temperature, sweating, dull abdominal pain in the upper part of the abdomen or epigastric discomfort, weakness, vague febrile state are the most common symptoms [6, 8] Physical examination does not provide a lot of information's and lymphadenopathy can be rarely detected [6]

Laboratory analyzes are within normal limits [4, 7]. Tumor markers (CEA, CA 19-9, AFP)

and serology are normal. Hepatitis C (HCV) may be the basis for the development of primary liver lymphoma, although there are no real studies and results to confirm that [8, 9].

The diagnosis of primary liver lymphoma is considerably difficult [6, 9]. Ultrasonography (US), computed tomography (CT) and magnetic resonance imaging (MRI) are the basic diagnostic procedures [9].

Surgery, chemotherapy and radiotherapy alone or in combination represent treatment modalities of choice [9, 10].

The prognosis of the disease is poor [10]. A small number of patients are treated operatively, but with mandatory postoperative chemotherapy with an increase in the survival rate [11].

Multidisciplinary approach is advised in treatment of primary liver lymphoma for optimal effect [10].

**CASE REPORT**

A 75-year-old patient was admitted to our clinic due to dull intermittent pain under the right rib cage, accompanied by malaise, weakness, and an occasional elevated body temperature of around 38 degrees for 3–4 months. Anamnesis data speak of cholecystectomy due to calculus 30 years ago, appendectomy and ovariectomy, as well as stable cardiological status – hypertension. Physical examination did not establish any pathological findings. Tumor markers (CEA, CA 19-9, AFP), serological

**Received • Примљено:**

July 27, 2024

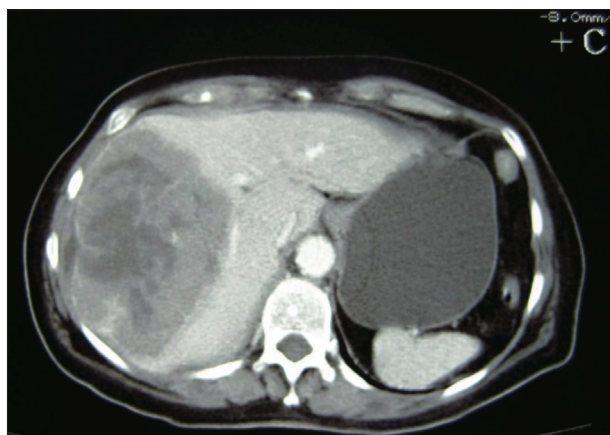
**Accepted • Прихваћено:**

December 24, 2024

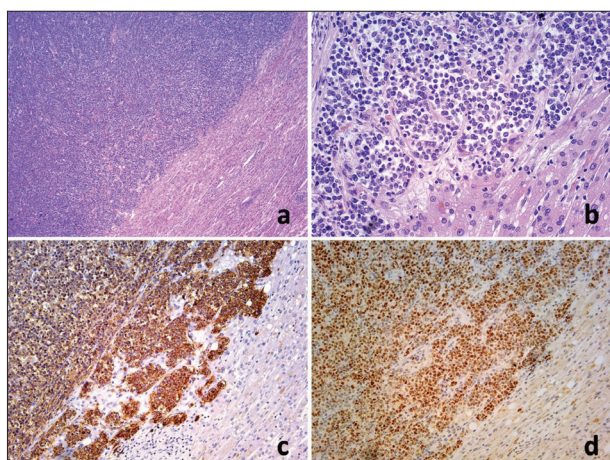
**Online first:** December 30, 2024**Correspondence to:**Stefan MILOŠEVIĆ  
Dimitrija Tucovića 108/8  
11000 Belgrade

Serbia

[drstefanmilosevic@gmail.com](mailto:drstefanmilosevic@gmail.com)



**Figure 1.** Computed tomography (CT) of the abdomen, arterial phase, axial section shows a predominantly hypodense, centrally necrotic lesion located in the right liver lobe, without CT signs of invasion of vascular structures



**Figure 2.** Histology of hepatic diffuse large B-cell lymphoma: a. mass forming lymphoma presented well defined boundaries towards hepatic parenchyma (HE, 10 ×), b. typical centробlastic cytomorphology (HE, 40 ×), c. strong immunoexpression of CD20 antibody (SAB+/DAB, 20 ×) and d. strong immunostaining with Bcl-6 antibody (SAB+/DAB, 20 ×) depicting GCB-type of this lymphoma

tests, laboratory analyzes (“hepatogram”, complete blood count, leukocyte formula, bleeding times, electrolyte status, glycemia) were within normal limits except for SE 90, coagulation factor II 125, V 166, VII 128, IX 148. Esophagogastroduodenoscopy, colonoscopy, and radiography of the lungs were within normal parameters for the patient's age. Ultrasonographic and CT examination of the abdomen indicated a clearly demarcated inhomogeneous and predominantly hypodense lesion involving the greater part of the right lobe of the liver, diameter 165 × 130 × 110 mm with a zone of pronounced central necrosis (Figure 1).

After opening the abdomen by laparotomy, exploration of the abdomen verifies a large lesion with a diameter of about 15 cm, which completely destroys the V, VI, VII and part of the VIII segment of the liver with compression of the right hepatic vein. Through an anterior approach, a radiofrequency (RF) system resection of V, VI, VII, and part of segment VIII of the liver was performed with preservation of the remaining part of segment VIII and the medial hepatic vein. Other findings in the abdomen and liver were

normal. The abdomen was drained with four drains. On the third postoperative day, a right-sided pulmonary effusion was detected, which was treated conservatively. The patient started with oral intake on the fourth postoperative day, and the abdominal drains were removed on the sixth postoperative day. On the ninth postoperative day, the patient was discharged from the hospital in good shape and with proper laboratory analyses, X-ray findings of the lungs and ultrasound of the abdomen.

The definitive pathohistological finding with immunohistochemical analysis was: DLBCL of the liver: DLBCL, GCB-type with Ki-67 index of 70% and R1 resection (Figure 2). Tumor cells were small to intermediate in size, round, with scant cytoplasm, mostly vesicular nuclei, coarsely granulated chromatin, with central tumor necrosis and mucoid degeneration of the stroma.

One month after the operation, the patient had no complaints, laboratory tests, US of the abdomen and X-ray of the chest were normal. In the first three years, after the operation, the patient regularly attended periodic surgical examinations with laboratory analyzes and accompanying US or CT examination. During that period no relapse of the disease was detected. The patient declined chemotherapy treatment immediately after the operation, as suggested by the hematological oncology council.

This study was done in accordance with standards of the institutional Committee on Ethics. Patient's written consent was obtained.

## DISCUSSION

Lymphomas are a heterogeneous type of malignant disease that develops from lymph nodes and lymphatic tissue of other organs. There are two main types of lymphoma: Hodgkin's disease (with four subtypes) and non-Hodgkin's lymphoma (25 subtypes) [1, 2]. The two most common subtypes of non-Hodgkin's lymphoma (over 50%), which make up about 5% of all malignancies, are: DLBCL and follicular type [1]. There are also transitional forms of these subtypes [2]. Most subtypes of both forms of lymphoma are manifested by lymphadenopathy that can occur in any part of the body [1]. One form is MALT lymphoma (mucosa-associated lymphoid tissue) that usually develops in the stomach (85%) to infectious and autoimmune agents [3]. Lymph nodes are enlarged, hard in consistency and painless. In the pathogenesis of the disease, there is the development of abnormal lymphocytes that multiply uncontrollably and accumulate in the lymphatic tissue [1].

Extranodal forms of non-Hodgkin's lymphoma (about 40%) occur most often on the head and neck [1, 2]. Primary non-Hodgkin lymphoma of the liver is an extremely rare disease [3]. The right lobe of the liver is more commonly affected than the left lobe, with an average size of the lesion about 11.5 cm [3, 4, 5]. Macroscopically the tumor is gray-white in color, soft in consistency, clearly demarcated, with lobulated contour, and with focal bleeding and necrosis [3, 6]. DLBCL is the most common form (0.016% of all non-Hodgkin's lymphomas or 0.4%

of extranodal non-Hodgkin's lymphomas) [4, 10]. It was first described in 1965 [5]. Secondary liver lymphoma is more frequent than primary form and corresponds to the progression of the primary nodal form of the disease [5]. Establishing a definitive diagnosis of the disease clinically and pathohistologically is difficult [6].

Middle-aged men are most often affected, although in some individual small studies, women over 60 years of age appear more often [4, 7, 12]. The disease occurs more often in people suffering from immunocompromising diseases [8].

The most common symptoms are weight loss, elevated body temperature, sweating, so-called "B symptoms" (37–86%), dull abdominal pain in the upper parts of the abdomen or epigastric discomfort, weakness are the most common symptoms [2, 4, 11]. Sometimes it occurs as a vague febrile condition or icterus (4%) [11].

Physical examination can be scanty in terms of hepatomegaly and always without lymphadenopathy [7].

Laboratory analyzes may be within the limits of normal values or with a slight "hepatogram" disorder, coagulation factor disorder, anemia, thrombocytopenia, sedimentation, lactate dehydrogenase [8, 13]. Tumor markers (CEA, CA 19-9, AFP) are normal. Serologically, the affected patient is usually HBsAg and HCV negative [3, 14]. In some cases (20–67%) patients can be HCV positive [14]. HCV can be the basis for the development of primary lymphoma of the liver, but there are no real studies to support that. Sometimes hypercalcemia can occur (parathyroid hormone-related peptide is elevated in lymphoma cells) [14].

Diagnostic modalities such as ultrasound examination of the abdomen, CT and MRI examination are highly sensitive in detecting these lesions, which are mostly solitary and hypovascular [15]. On cross-sectional imaging, they appear as hypodense or hypointense infiltrative lesions and are initially often misdiagnosed as primary tumors of hepatic origin [10]. Ultrasound examination detects a hypoechoic mass within the liver parenchyma, which in some cases, due to extensive necrosis (60%), may look like a cystically degraded structure [10, 15]. Color Doppler (CD) signal is present around the periphery of the lesion. CT examination can precisely localize the lesion and can show the relationship with the vascular structures [15]. There is no pronounced post-contrast opacification of the lesion in the arterial phase of the examination nor the wash-out effect typical of hepatocellular carcinoma [12]. The tumor is predominantly hypodense due to hypovascularity with discretely higher density around the perimeter of the lesion [13]. Rarely, they can be complicated by intratumor hemorrhage, which can be seen on a CT scan as a zone of higher intralesional density. MRI characteristics of the

lesion are lower signal intensity (IS) in T1 weighted image, higher IS in T2 weighted image, conspicuous restrictive diffusion without postcontrast viability and no uptake of liver specific contrast agent [15].

Very often a wrong diagnosis is made (non-specific symptomatology, normal laboratory values, difficult and unclear diagnostics, numerous subtypes of lymphoma) [10]. Differential diagnosis of primary liver lymphoma should include active form of chronic hepatitis, granulomatous cholangitis, inflammatory pseudotumor, anaplastic carcinoma, metastatic process [6, 7, 11].

Definitive diagnosis is made on the basis of pathohistological and immunohistochemical analysis while taking into account the remaining results [3, 10, 14, 15]. Therefore, it is necessary to exclude other lymphoproliferative, systemic, immunodeficient and other diseases [5, 11].

Surgery, chemotherapy and radiotherapy alone or in combination are treatment modalities of choice [4, 10]. Regardless of the type, the disease has a very aggressive course and the prognosis is usually poor. A massive liver tumor, high proliferative index, advanced age and liver cirrhosis are poor prognostic factors [5, 11]. Treatment with only chemotherapy, gives the patient prognosis of six months [14]. Monoclonal antibodies have great potential for the treatment of this disease [14]. If, over time, diagnostic procedures verify new liver lesions, it is necessary to change the chemotherapy. Each chemotherapy must be adapted to the age and general condition of the patient and the liver, stage of the disease, histopathological findings and phenotyping [10].

A relatively small number of patients were treated operatively, but with mandatory postoperative chemotherapy, after three weeks of surgery (cyclophosphamide, doxorubicin, vincristine, prednisone) [9, 12]. Survival of patients with primary liver lymphoma (DLBCL) increases from 54% to 80% with a combination of operative treatment and chemotherapy with an average survival of 39 months (5–124 months) [10, 13].

Multidisciplinary approach in treatment of primary liver lymphoma should be applied, if possible, because of its proven effects in overall patient average survival rate [5, 10].

In summary, primary liver lymphoma is a rare disease that poses challenges in both diagnosis and treatment. Advancements in diagnostic techniques, innovative treatment methods, and a collaborative multidisciplinary approach can help address the challenges of accurately diagnosing and promptly treating liver lymphoma, ultimately leading to improved average survival rates for patients.

**Conflict of interest:** None declared.

## REFERENCES

1. Wang Q, Wu K, Zhang X, Liu Y, Sun Z, Wei S, et al. Primary hepatopancreatobiliary lymphoma: Pathogenesis, diagnosis, and management. *Front Oncol.* 2022; 12:951062. [DOI: 10.3389/fonc.2022.951062] [PMID: 36110965]
2. Jaffe ES. Diagnosis and classification of lymphoma: Impact of technical advances. *Semin Hematol.* 2019;56(1):30–6. [DOI: 10.1053/j.seminhematol.2018.05.007] [PMID: 30573042]
3. Jiang M, Jiang S, Yang Y, Yao R, Hu M. Primary hepatic lymphoma a case report and literature review. *Medicine (Baltimore).* 2023;102(50):e36688. [DOI: 10.1097/MD.00000000000036688] [PMID: 38115256]
4. Tung RT, Heyns J. Primary Hepatic Lymphoma: A Rare Form of Diffuse Large B-Cell Lymphoma of the Liver. *Fed Pract.* 2023;40(Suppl 1):S40–S44. [DOI: 10.12788/fp.0365] [PMID: 37727830]
5. Patkar S, Dutt K, Shah A, Sengar M, Goel M. Primary Lymphoma of Liver—a Rare Space-Occupying Lesion. *J Gastrointest Cancer.* 2020;51(3):1057–60. [DOI: 10.1007/s12029-020-00381-4] [PMID: 32333249]
6. Dantas E, Santos J, Coelho M, Sequeira C, Santos I, Cardoso C, et al. Primary hepatic lymphoma in a patient with cirrhosis: a case report. *J Med Case Rep.* 2020;14(1):168. [DOI: 10.1186/s13256-020-02471-0] [PMID: 32977834]
7. Wang RL, Wang J, Li YS, Wang Y, Su Q. Primary hepatic lymphoma of MALT type mimicking hepatic adenoma treated by hepatectomy: a case report and literature review. *Front Surg.* 2023;10:1169455. [DOI: 10.3389/fsurg.2023.1169455] [PMID: 37251580]
8. García-Bermúdez V, Morales-Ortega A, Jaquero-Valero M, Khedaoui R, Tardío JC, Bernal-Bello D. Primary liver lymphoma and systemic sclerosis. *Rheumatology (Oxford).* 2022;61(8):e247–e248. [DOI: 10.1093/rheumatology/keac026] [PMID: 35022683]
9. Yaka M, Chehab F, Allaoui M, Ait Ali A, Zentar A. Postsurgical Diagnosis of an Unusual Case of Primary Hepatic Lymphoma Presenting as Liver Abscess with an Uncommon Complication: A Hepatogastric Fistula. *Case Rep Hematol.* 2021;2021:6647558. [DOI: 10.1155/2021/6647558] [PMID: 33680521]
10. Dias E, Marques M, Macedo G. Post-transplant primary liver lymphoma: always to remember. *J Gastrointest Liver Dis.* 2022;31(2):254–5. [DOI: 10.15403/jgld-4239] [PMID: 35694984]
11. Daniel T, Sweeney R, Haag A, Morrissey S. Diffuse Large B Cell Lymphoma Raising Suspicion for an Infection: A Case Report. *Cureus.* 2023;15(2):e34750. [DOI: 10.7759/cureus.34750] [PMID: 36909035]
12. Xu ZY, Pan Y, Ye WJ, Liu JL, Wu XJ, Tang CL. Primary hepatic lymphoma presenting as pyogenic liver abscess: A case report. *World J Clin Cases.* 2024;12(21):4742–7. [DOI: 10.12998/wjcc.v12.i21.4742] [PMID: 39070821]
13. Lohana AK, Tariq MA, Abid S. Hepatic Lymphoma. 2023. In: *StatPearls* [Internet]. Treasure Island (FL): StatPearls Publishing; 2024 Jan–. [PMID: 30969672]
14. Liu X, Cao X, Pang Y, Min F. Primary hepatic mucosa-associated lymphoid tissue lymphoma with HP and previous HBV infection: A case report and literature review. *J Infect Chemother.* 2022;28(8):1182–8. [DOI: 10.1016/j.jiac.2022.04.014] [PMID: 35459609]
15. Ippolito D, Porta M, Maino C, Pecorelli A, Ragusi M, Giandola T, et al. Diagnostic approach in hepatic lymphoma: radiological imaging findings and literature review. *J Cancer Res Clin Oncol.* 2020;146(6):1545–58. [DOI: 10.1007/s00432-020-03205-x] [PMID: 32296934]

## Дифузни крупноћелијски Б тип примарног нехочкинског лимфома јетре – дијагностички проблем

Драган Басарић<sup>1,2</sup>, Стефан Милошевић<sup>3</sup>, Небојша Лекић<sup>1,2</sup>, Душан Шапоњски<sup>2,3</sup>, Милица Митровић-Јовановић<sup>2,3</sup>

<sup>1</sup>Универзитетски клинички центар Србије, Клиника за дигестивну хирургију, Београд, Србија;

<sup>2</sup>Универзитет у Београду, Медицински факултет, Београд, Србија;

<sup>3</sup>Универзитетски клинички центар Србије, Центар за радиологију, Београд, Србија

### САЖЕТАК

**Увод** Примарни нехочкински лимфом јетре је изузетно ретко обољење. Најчешће се јавља као дифузни крупноћелијски Б тип.

**Приказ болесника** Приказан је случај болеснице старе 75 година која је примљена због болова испод десног ребарног лука праћених малаксалошћу, слабошћу и повишеном телесном температуром. Лабораторијске анализе биле су у границама нормалних вредности. Ултрасонографски и компјутеризованом томографијом се верификује јасно ограни-

чена нехомогена туморска промена у десном лобусу јетре са централном зоном некрозе. Интраоперативно и патохистолошки потврђено је да се ради о дифузном крупноћелијском Б лимфому јетре. Хирургија, хемотерапија, радиотерапија и њихова комбинација су начини лечења.

**Закључак** Хируршки третман са хемотерапијом омогућава знатно вишу стопу преживљавања.

**Кључне речи:** нехочкински лимфом; јетра; дијагностика; лечење