



## ORIGINAL ARTICLE / ОРИГИНАЛНИ РАД

# The predictive role of tumor infiltrating lymphocytes and pathohistological parameters for the occurrence of metastases in the clinical N0 neck of early-stage oral squamous cell carcinoma

Miloš Trajković<sup>1</sup>, Dragan Krsić<sup>1,2</sup>, Tatjana Jeftović Stojmenov<sup>2</sup>, Nikola Živković<sup>1,3</sup>, Predrag Radović<sup>1,2</sup>, Miloš Stojanović<sup>1</sup>, Simona Stojanović<sup>2,4</sup>

<sup>1</sup>Clinic for Dental Medicine, Maxillofacial Surgery Department, Niš, Serbia;

<sup>2</sup>University of Niš, Faculty of Medicine, Niš, Serbia;

<sup>3</sup>Niš University Clinical Centre, Pathology and Pathological Anatomy Institute, Niš, Serbia;

<sup>4</sup>Clinic for Dental Medicine, Oral Surgery Department, Niš, Serbia

## SUMMARY

**Introduction/Objective** With 337,173 registered cases worldwide in 2020, oral squamous cell carcinoma is the most common malignant tumor of the head and neck region. The status of lymph nodes in the neck is the most important isolated prognostic factor for the five-year survival of patients. This study aimed to determine the pathohistological predictors of the occurrence of occult neck metastases in early-stage oral squamous cell carcinoma.

**Methods** The study included 40 patients (mean age  $62.8 \pm 10.7$ ) with early-stage oral squamous cell carcinoma and clinical N0 findings in the neck. All patients underwent radical transoral tumor ablation and elective neck lymphadenectomy. Based on pathohistological findings, the patients were divided into two groups: a group with occult metastases present and a group without occult metastases.

**Results** Occult metastases were present in 13 patients (32.5%). The results indicate a significant difference in the desmoplastic reaction of the stroma ( $p < 0.001$ ), depth of invasion ( $p < 0.001$ ), lymphocytic infiltration ( $p < 0.001$ ), and lymphovascular invasion in univariate (OR 24,  $p = 0.004$ ) and multivariate (OR 32.713,  $p = 0.017$ ) logistic regression analyses in the group with occult metastases compared to the group without metastases.

**Conclusion** The values of the analyzed pathohistological predictors indicate a high degree of correlation with the occurrence of occult metastases in the neck. Their predictive significance strongly supports including these parameters as part of the standard pathohistological examination of oral squamous cell carcinoma.

**Keywords:** oral squamous cell carcinoma; occult metastases; pathohistological analysis; surgical treatment; observation

## INTRODUCTION

With 337,713 registered cases worldwide in 2020, oral squamous cell carcinoma (OSCC) is the most common malignant tumor of the head and neck region [1]. Given that it accounts for up to 90% of the total number of intraoral malignant tumors, it is by far the most common intraoral malignancy [2]. Aggressive behavior towards the surrounding anatomical structures and their rapid infiltration, early appearance of metastases in the neck, and frequent recurrence are some of the key clinical characteristics of OSCC. The five-year survival rate of early-stage OSCC patients varies from 80–90%, in contrast to advanced forms characterized by a five-year survival of 30–50% [3]. The fundamentals of OSCC treatment include radical tumor ablation, neck lymphadenectomy, adequate reconstruction of the resulting defect, and postoperative oncological therapy.

The status of lymph nodes in the neck (LNs) represents the most important isolated

prognostic factor for the survival of patients with OSCC. The presence of metastases in the neck significantly reduces the five-year survival of patients to below 50% [4]. The treatment of N0 neck in the early stages of OSCC (pT1-N0-M0 and pT2-N0-M0) is still the subject of many debates in head and neck surgery without a clearly defined viewpoint for conducting elective neck lymphadenectomy (END) or the so-called watchful-waiting method, i.e., the observation of patients. The presence of occult metastases (OM) in the range of 16–36%, pathohistologically verified in postoperative dissections of the neck, significantly affects the five-year survival of patients [5]. Sentinel lymph node biopsy (SNB) is a routine surgical procedure for the detection of OM in the neck in OSCC. The use of SNB proves high sensitivity for detecting micrometastases and isolated tumor cells (ITC), a lower degree of morbidity of the surrounding tissue, and a considerably more positive economic aspect compared to END [6]. The sensitivity of SNB in the range

**Received • Примљено:**  
June 23, 2024

**Revised • Ревизија:**  
January 6, 2025

**Accepted • Прихваћено:**  
January 24, 2025

**Online first:** January 28, 2025

### Correspondence to:

Miloš TRAJKOVIĆ  
Department of Maxillofacial  
Surgery  
102 Ratko Jović Blvd  
Niš 18000, Serbia  
[dr.mtrajkovic@yahoo.com](mailto:dr.mtrajkovic@yahoo.com)

of 75–87% for registering OM in the early stage of OSCC defines the method as safe and rational [7].

Literature data suggest that based on the pathohistological analysis of OSCC preparations, which includes depth of invasion (DOI), desmoplastic stromal reaction (DR), tumor budding, lymphovascular invasion (LVI), perineural invasion (PNI), and density of tumor-infiltrating lymphocytes (TILs), the occurrence of extranodal extension (ENE) of OSCC, which is directly related to the occurrence of metastases in the neck, can be predicted [8, 9].

This study aimed to determine whether the aforementioned pathohistological parameters can be reliable predictors for OM occurrence in OSCC stage pT1-N0-M0 and pT2-N0-M0.

## METHODS

The study included 40 consecutive patients of both sexes treated at the Clinic for Maxillofacial Surgery in Niš from 2019 to 2022, in whom the presence of OSCC stage cT1-N0-M0 and cT2-N0-M0 was determined based on medical history, clinical examination, initial biopsy, and additional radiological examinations.

The criteria for excluding patients from the study included patients with higher T stages (cT3-cT4), recurrent OSCC that was in rT1-rT2 stage at the time of examination, radiologically confirmed the presence of secondary deposits (M1 stage), initially inoperable forms of OSCC turned into an operable state after oncological treatment, patients in whom the progression of the disease occurred from the verification of OSCC stage cT1-cT2 to the surgical procedure, and patients in whom, due to general condition or comorbidities, intervention in general endotracheal anesthesia was contraindicated.

The analysis of anamnestic data determined age, gender and risk factors in terms of alcohol consumption and tobacco smoking.

The clinical examination determined the precise location of the suspicious lesion in the oral cavity as well as its clinical form (exophytic or endophytic). The clinical examination also determined the Karnofsky score (Karnofsky Performance Status Scale – KPS) of the patients, which ranged 90–100 in all subjects (Figure 1).

After the anamnestic and clinical examination, punch biopsy of the suspicious lesion in the oral cavity was performed for the pathohistological verification of OSCC.

Radiological examinations included multi-slice computerized tomography of the head and neck, magnetic resonance imaging of the head and neck, lung imaging, and ultrasound of the neck and abdomen. Radiological examinations determined the precise diameter of the tumor, as well as its relation to the surrounding soft tissue and bone structures.

Surgical treatment of patients included radical transoral tumor ablation and END of neck levels I, II, and III (Figure 2).

The pathohistological analysis of postoperative OSCC preparations was done after the fixation of the preparations

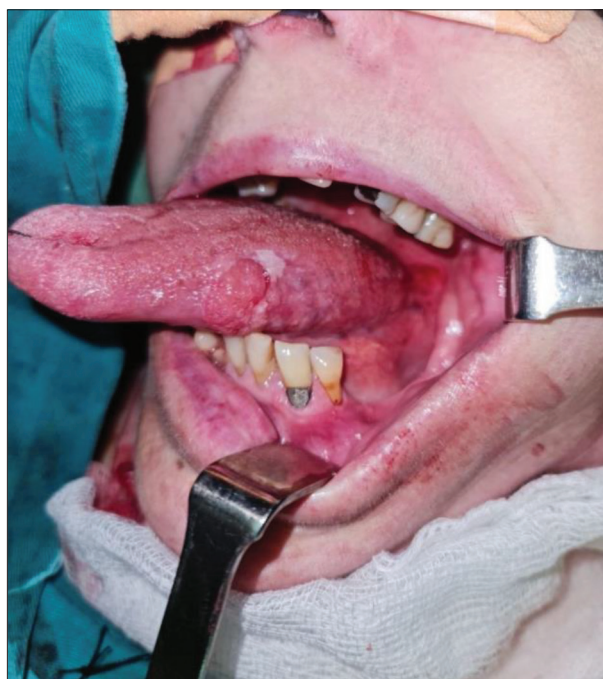

Figure 1. Oral squamous cell carcinoma of the tongue

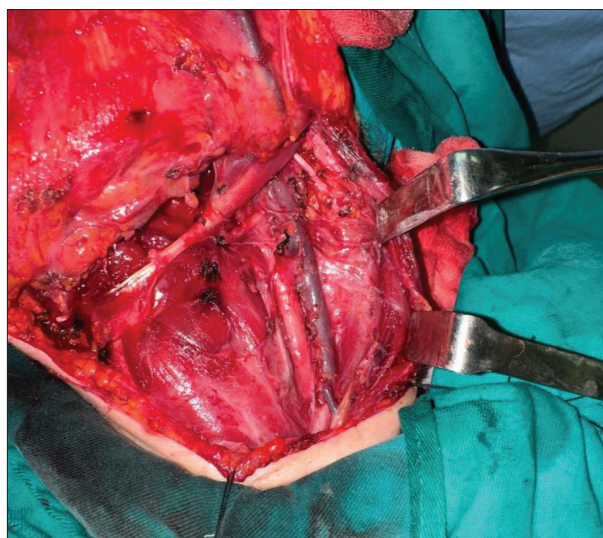


Figure 2. Elective neck lymphadenectomy of levels I, II, and III

in a 10% solution of buffered formalin. The micromorphological analysis of histological sections made with the standard hematoxylin-eosin (H&E) method included the analysis of the status of resection margins, analysis of DOI, DR, LVI, PNI, tumor grade, and density of TILs. Immunohistochemical analyses were performed by determining the expression of pan-cytokeratin (pan-CK) (AE1/AE3) in suspicious lymph nodes of postoperative neck dissections to identify occult metastatic changes.

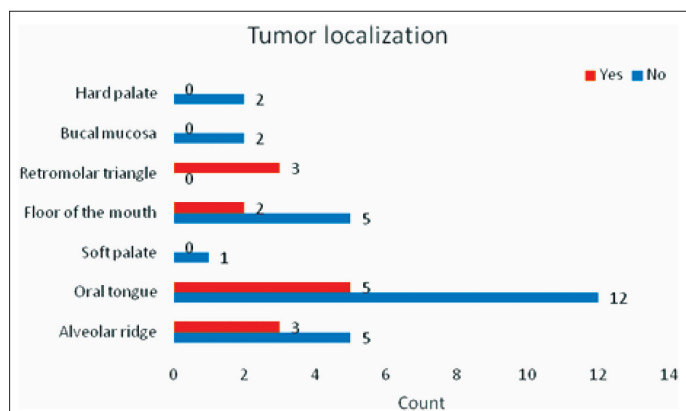
The statistical processing of data involved presentation in the form of arithmetic mean, standard deviation, minimal and maximal values, and ratio in the form of absolute and relative numbers. Numerical variables were compared using the t-test, whereas categorical characteristics were compared with the  $\chi^2$  test or Fisher's exact probability test. Logistic regression analysis was used to assess the

**Table 1.** Demographic and clinical characteristics of patients regarding the presence of metastases

Characteristic		Total		Occult metastases				p <sup>1</sup>
				Yes		No		
Sex	male	25	62.5	9	69.2	16	59.3	0.794
	female	15	37.5	4	30.8	11	40.7	
Age (years)	< 55	10	25	3	23.1	7	25.9	1.000*
	55+	29	75	10	76.9	20	74.1	
Smoking		29	72.5	13	100	16	59.3	0.007*
Alcohol		22	55	9	69.2	13	48.1	0.312
Growth type	exophytic	21	52.5	5	38.5	16	59.3	0.370
	endophytic	19	47.5	8	61.5	11	40.7	
Tumor grade	I	12	30	1	7.7	11	40.7	0.114*
	II	20	50	9	69.2	11	40.7	
	III	8	20	3	23.1	5	18.5	
Tumor stage	T1	12	30	6	46.2	6	22.2	0.238
	T2	28	70	7	53.8	21	77.8	
Perineural invasion		25	62.5	7	53.8	18	66.7	0.663
Lymphovascular invasion		21	52.5	12	92.3	9	33.3	0.001*
Desmoplastic reaction	mature	15	37.5	0	0	15	55.6	< 0.001*
	intermediate	15	37.5	3	23.1	12	44.4	
	immature	10	25	10	76.9	0	0	
Depth of invasion (mm)	< 5	24	60	0	0	24	88.9	< 0.001*
	5+	16	40	13	100	3	11.1	
Lymphocytic infiltration	high	18	45	0	0	18	66.7	< 0.001*
	intermediate	13	32.5	4	30.8	9	33.3	
	low	9	22.5	9	69.2	0	0	

<sup>1</sup>χ<sup>2</sup> test;

\*Fisher's exact probability test

**Figure 3.** Tumor localization regarding the presence of occult metastases**Table 2.** Risk factors for the occurrence of occult metastases – univariate logistic regression analysis

Characteristic	Univariate logistic regression				Multivariate logistic regression				
	OR	95% CI	p	OR	95% CI	p			
Female sex	0.646	0.158	2.637	0.543	2.126	0.041	109.137	0.707	
Age	1.007	0.945	1.072	0.832	1.100	0.976	1.239	0.117	
Alcohol	2.423	0.598	9.816	0.215	4.897	0.082	290.940	0.446	
Growth type – exophytic	2.327	0.600	9.028	0.222	0.495	0.036	6.881	0.601	
Tumor grade	I	ref group		0.114				0.244	
	II	9.000	0.969	83.583	0.053	31.774	0.561	1798.965	0.093
	III	6.600	0.543	80.235	0.139	9.662	0.241	386.897	0.228
Perineural invasion	0.583	0.151	2.256	0.435	.069	0.004	1.266	0.072	
Lymphovascular invasion	24.000	2.682	214.725	0.004	32.713	1.862	574.667	0.017	
Constant					0.000			0.025	

OR – odds ratio; 95% CI – 95% confidence interval; Hosmer–Lemeshow test p = 0.135

relationship between the studied variables and the appearance of OM.

We excluded specific variables (DR, DOI, smoking, lymphocyte infiltration) from our logistic regression model due to perfect separation or multicollinearity, which was identified when these variables perfectly predicted the outcome, leading to model estimation issues such as non-convergence. This decision was made to ensure the stability and reliability of our model's parameter estimates.

The null hypothesis was tested with a significance threshold of  $p < 0.05$ . Statistical data processing was performed in the SPSS Statistics, Version 16.0 (SPSS Inc., Chicago, IL, USA) software package.

The study was approved by the Ethics Committee of the Dental Clinic in Niš (14/14-2019-4 EO) and the Ethics Committee of the Faculty of Medicine in Niš (12-16502/2-1).

## RESULTS

The study included 40 patients (25 male and 15 female). The mean age of the studied population was  $62.8 \pm 10.7$  (min 37 years, max 85 years). The majority of subjects were male (62.5%), older than 55 years (75.0%), smokers (72.5%), who regularly consumed alcohol (55.0%) and had exophytic tumor growth (52.5%).

There were 13 patients with OM in the group (32.5%). There was no statistically significant difference with respect to sex ( $p = 0.794$ ), age ( $p = 1.000$ ), alcohol consumption ( $p = 0.312$ ), tumor growth type ( $p = 0.370$ ) and tumor grade ( $p = 0.114$ ) regarding the presence of OM (Table 1). Smoking was statistically significantly more common in patients with OM ( $p = 0.007$ ).

PNI was present in 62.5% of patients and did not differ significantly in relation to the presence of metastases ( $p = 0.663$ ). LVI was statistically significantly different in relation to the presence of metastases (92.3% vs. 33.3%,  $p = 0.001$ ). DR differed statistically significantly in relation to the presence of metastases ( $p < 0.001$ ), as well as DOI ( $p < 0.001$ ). Lymphocytic infiltration was statistically significantly different in relation to the presence of metastases ( $p < 0.001$ ).

Statistical analysis does not show the existence of a significant correlation between tumor stage of OSCC (T1–T2) nor the presence of OM in the neck.

The lesions were localized on the tongue (42.5%), alveolar processes (20%), floor of the oral cavity (17.5%), hard palate (5%), retromolar triangle (7.5%), buccal mucosa (5%), and soft palate (5%) (Figure 3).

Univariate logistic regression analysis showed that LVI is a statistically significant risk

factor for OM (OR 24.0,  $p = 0.004$ ). Moreover, it remained a statistically significant risk factor in the multivariate model (OR 32.713,  $p = 0.017$ ) (Table 2).

## DISCUSSION

The distribution of OSCC in the oral cavity varies at a global level and is primarily dependent on the geographic location that determines exposure to the most frequent etiological factors. The location of OSCC in the oral cavity is an important prognostic factor, as well as an implication of the patient's surgical treatment. Literature data indicate that the most common site of OSCC in Thailand, India and Southeast Asian countries is the buccal mucosa [10]. Available data from Nigeria and Germany highlight the gingiva of the alveolar processes of the lower and upper jaw as well as the floor of the oral cavity as predilection sites for OSCC [11, 12]. OSCC is most common in the tongue (41.7%), floor of the oral cavity and lips (16.5%, each), gingiva of the alveolar processes of the upper and lower jaw (10.6%), buccal mucosa (6.7%), retromolar triangle (5.6%), and hard and soft palate structures (2.3%) [13].

Alcohol and tobacco consumption are the most important etiological factors associated with the occurrence of OSCC. These factors are present in 70–80% of patients with OSCC [14]. Chemical carcinogens from alcohol and tobacco participate synergistically in generating mutations in tumor suppressor genes and thus promote carcinogenesis.

OSCC is considerably more frequent in males than in females. Literature data suggest that men make up 90–93% of patients with OSCC, whereas women represent only 7–10% of patients [15]. A marked discrepancy in the frequency of patients of both sexes is explained by more frequent exposure to etiological factors in men, in contrast to women. The male-female ratio differs primarily at the regional level, but the percentage of men with OSCC is almost always higher.

OSCC is significantly more common in patients older than 50 years [16]. The presented data on age vary by the region and the number of patients included in the study.

Pathohistological findings in postoperative neck dissections can be negative, indicating the presence of ITCs, micrometastases (MM) or macrometastases. Negative findings imply reactive cellular changes, sinus histiocytosis and benign cell inclusions. By definition, ITCs are small cell aggregates not larger than 0.2 mm, or non-confluent aggregates not exceeding 200 cells per section. MM represent individual tumor deposits with a 0.2–2 mm diameter, unlike macrometastases, which also represent individual tumor deposits, but larger than 2 mm. Considering that it is impossible to prove the existence of ITCs and MM by standard H&E examination, pan-cytokeratin (pan-CK) (AE1/AE3) has been introduced as a useful marker for determining the presence of OM. The detected presence of ITCs and MM in the value of 33.3% on preparations that were negative by H&E processing indicates that pan-CK (AE1/AE3) is a reliable marker for the detection of ITCs and MM [17]. DOI was defined as the distance from the normal basal membrane to the deepest point of tumor invasion, is an

independent risk factor for the occurrence of OM in lymph nodes of the neck in patients with OSCC. Studying patients with early-stage OSCC, the threshold and increased value of DOI would represent an indicator for END [18]. The association between DOI over 5 mm and 36.25% of OM was presented in a study by Pakistani authors [19]. The study included 80 patients with pathohistologically proven OSCC. The authors concluded that patients with DOI +5 have a relative risk of occult neck nodes metastasis and that there is no significant relationship of occult neck node metastasis with age, gender, risk factors and tumor grade. LVI by definition refers to the presence of tumor cells in the lumen of a blood vessel or cellular adhesion to the vascular wall. The presence of LVI is interpreted as a negative prognostic factor for patients suffering from OSCC. In a study that included 442 patients with OSCC, Abigail E. Moore et al. [20] concluded that LVI is a significant pathohistological parameter for the occurrence of regional metastases. The same authors also reported the absence of correlation of LVI with tumor aggressiveness and local recurrence. Prakash Pandit et al. [21] conducted a study on 462 patients with OSCC and confirmed the link between LVI and metastases in the lymph nodes of the neck.

PNI represents the appearance of a tumor in close proximity to a nerve, involving at least 33% of its volume, or the presence of tumor cells within any of the three layers of the nerve sheath. The presence of PNI on pathohistological preparations of OSCC is associated with increased morbidity, poor prognosis and frequent local recurrences, but without a significant impact on the occurrence of regional metastases [22]. DR type is one of the key stromal characteristics of malignant tumors of the gastrointestinal tract [23]. Based on the morphology and arrangement of collagen fibers and myxoid stroma, DR is divided into mature, intermediate, and immature. The insight into available literature reveals works of numerous researchers who associate DR with the clinical characteristics of OSCC. In a study that included 308 patients with early-stage OSCC of the tongue, Almangush et al. [24] determined a relationship between the stromal reaction type and patient survival. However, the same authors did not find a relationship between the DR type and the appearance of metastases in the neck. Furthermore, Bittar et al. [25] conducted a study that included 157 patients with verified OSCC and a clinical N0 finding in the neck and determined an association between the appearance of OM in the neck and the type of DR. Noda et al. [8] suggested an association between immature tumor stroma and ENE. The aforementioned authors in a study that included 83 patients with pathohistologically verified OSCC indicate the existence of a significant correlation between immature tumor stroma and ENE. In addition, the results of our study indicate a significant correlation between the occurrence of OM and the immature tumor stroma of OSCC preparations.

TILs are a selected population of lymphocytes, predominantly of the T form, with a highly specific immune response to tumor cells. They represent reliable biomarkers for many solid tumors, including malignant tumors of the head and neck [26]. The method for the standardized assessment

of the presence of TILs using the H&E method published by the International Immuno-Oncology Biomarker Working Group is being very effectively applied in daily clinical practice [27]. Literature data indicate that high tumor infiltration by TILs represents a favorable prognostic sign for OSCC and other malignant tumors, in terms of an increased survival rate and less aggressiveness of the tumor [28]. The results of our study, which indicate a relationship between the appearance of OM in the neck, aggressiveness of the tumor and low tumor infiltration by TILs, are in correlation with the results of the aforementioned authors [8, 9, 29, 30].

## CONCLUSION

The presence of OM in the 16–36% range in postoperative neck dissections undoubtedly has a negative effect on the

five-year survival of OSCC patients, which varies 30–90%, depending on the stage of the tumor and the status of LNs.

The results of our study indicate a high degree of association of the analyzed pathohistological parameters with the occurrence of OM in the neck in patients with early-stage OSCC. The significance of predicting the risk of OM is a strong argument for the aforementioned parameters to be part of the standard pathohistological examination of OSCC.

We firmly believe that our idea of future inclusion of epigenetic examination of OSCC preparations in standard diagnostics will contribute to early detection of OM and thus an increase in the five-year survival of affected patients.

**Conflict of interest:** None declared.

## REFERENCES

1. Tan Y, Wang Z, Xu M, Li B, Huang Z, Qin S, et al. Oral squamous cell carcinomas: state of the field and emerging directions. *Int J Oral Sci.* 2023;15(1):44. [DOI: 10.1038/s41368-023-00249-w] [PMID: 37736748]
2. Alshami ML, Al-Maliky MA, Alsagban AA, Alshaeli AJ. Epidemiology and incidence of oral squamous cell carcinoma in the Iraqi population over 5 years (2014–2018). *Health Sci Rep.* 2023;6(4):e1205. [DOI: 10.1002/hsr.1205] [PMID: 37064317]
3. Karadaghy OA, Shew M, New J, Bur AM. Development and assessment of a machine learning model to help predict survival among patients with oral squamous cell carcinoma. *JAMA Otolaryngol Head Neck Surg.* 2019;145(12):1115–20. [DOI: 10.1001/jamaoto.2019.0981] [PMID: 31045212]
4. Bugshan A, Farooq I. Oral squamous cell carcinoma: metastasis, potentially associated malignant disorders, etiology and recent advancements in diagnosis. *F1000Res.* 2020;9:229. [DOI: 10.12688/f1000research.22941.1] [PMID: 32399208]
5. Oh LJ, Phan K, Kim SW, Low TH, Gupta R, Clark JR. Elective neck dissection versus observation for early-stage oral squamous cell carcinoma: systematic review and meta-analysis. *Oral Oncol.* 2020;105:104661. [DOI: 10.1016/j.oraloncology.2020.104661] [PMID: 32244173]
6. Miura K, Hirakawa H, Uemura H, Yoshimoto S, Shiotani A, Sugawara M, et al. Sentinel node biopsy for oral cancer: a prospective multicenter Phase II trial. *Auris Nasus Larynx.* 2017;44(3):319–26. [DOI: 10.1016/j.anl.2016.07.008] [PMID: 27496008]
7. Bark R, Kolev A, Elliot A, Piersiala K, Näsman A, Grybäck P, et al. Sentinel node-assisted neck dissection in advanced oral squamous cell carcinoma—a new protocol for staging and treatment. *Cancer Med.* 2023;12(11):12524–34. [DOI: 10.1002/cam4.5966] [PMID: 37084007]
8. Noda Y, Ishida M, Ueno Y, Fujisawa T, Iwai H, Tsuta K. Novel pathological predictive factors for extranodal extension in oral squamous cell carcinoma: a retrospective cohort study based on tumor budding, desmoplastic reaction, tumor-infiltrating lymphocytes, and depth of invasion. *BMC Cancer.* 2022;22(1):402. [DOI: 10.1186/s12885-022-09393-8] [PMID: 35418058]
9. Almangush A, Jouhi L, Atula T, Haglund C, Mäkitie AA, Hagström J, et al. Tumour-infiltrating lymphocytes in oropharyngeal cancer: a validation study according to the criteria of the International Immuno-Oncology Biomarker Working Group. *Br J Cancer.* 2022;126(11):1589–94. [DOI: 10.1038/s41416-022-01708-7] [PMID: 35043007]
10. Lin NC, Hsien SI, Hsu JT, Chen MYC. Impact on patients with oral squamous cell carcinoma in different anatomical subsites: a single-center study in Taiwan. *Sci Rep.* 2021;11(1):15446. [DOI: 10.1038/s41598-021-95007-5] [PMID: 34326432]
11. Effiom OA, Adeyemo WL, Omitola OG, Ajayi OF, Emmanuel MM, Gbotolorun OM. Oral squamous cell carcinoma: a clinicopathologic review of 233 cases in Lagos, Nigeria. *J Oral Maxillofac Surg.* 2008;66(8):1595–9. [DOI: 10.1016/j.joms.2007.12.025] [PMID: 18634945]
12. Sundermann BV, Uhlmann L, Hoffmann J, Freier K, Thiele OC. The localization and risk factors of squamous cell carcinoma in the oral cavity: a retrospective study of 1501 cases. *J Craniomaxillofac Surg.* 2018;46(2):177–82. [DOI: 10.1016/j.jcms.2017.10.019] [PMID: 29242026]
13. Stepan KO, Mazul AL, Larson J, Shah P, Jackson RS, Pipkorn P, et al. Changing epidemiology of oral cavity cancer in the United States. *Otolaryngol Head Neck Surg.* 2023;168(4):761–8. [DOI: 10.1177/01945998221098011] [PMID: 35503657]
14. Nokovitch L, Maquet C, Crampon F, Taihi I, Roussel LM, Obongo R, et al. Oral cavity squamous cell carcinoma risk factors: state of the art. *J Clin Med.* 2023;12(9):3264. [DOI: 10.3390/jcm12093264] [PMID: 37176704]
15. Lin NC, Hsu JT, Tsai KY. Difference between female and male patients with oral squamous cell carcinoma: a single-center retrospective study in Taiwan. *Int J Environ Res Public Health.* 2020;17(11):3978. [DOI: 10.3390/ijerph17113978] [PMID: 32512723]
16. Ferreira E Costa R, Leão MLB, Sant’Ana MSP, Mesquita RA, Gomez RS, Santos-Silva AR, et al. Oral squamous cell carcinoma frequency in young patients from referral centers around the world. *Head Neck Pathol.* 2022;16(3):755–62. [DOI: 10.1007/s12105-022-01441-w] [PMID: 35316511]
17. Dhawan I, Sandhu SV, Bhandari R, Sood N, Bhullar RK, Sethi N. Detection of cervical lymph node micrometastasis and isolated tumor cells in oral squamous cell carcinoma using immunohistochemistry and serial sectioning. *J Oral Maxillofac Pathol.* 2016;20(3):436–44. [DOI: 10.4103/0973-029X.190946] [PMID: 27721609]
18. Aaboubout Y, van der Toom QM, de Ridder MAJ, De Herdt MJ, van der Steen B, van Lanschot CGF, et al. Is the depth of invasion a marker for elective neck dissection in early oral squamous cell carcinoma? *Front Oncol.* 2021;11:628320. [DOI: 10.3389/fonc.2021.628320] [PMID: 33777774]
19. Muhammad AY, Dhanani R, Salman S, Shaikh Z, Ghaloo SK, Ikram M. Depth of invasion as a predictor of cervical nodal metastasis of oral tongue squamous cell carcinoma: findings from a tertiary care center in Pakistan. *Cureus.* 2021;13(10):e18976. [DOI: 10.7759/cureus.18976] [PMID: 34820231]
20. Moore AE, Alvi SA, Tarabichi O, Zhu VL, Buchakjian MR. Role of lymphovascular invasion in oral cavity squamous cell carcinoma regional metastasis and prognosis. *Ann Otol Rhinol Laryngol.* 2024;133(3):300–6. [DOI: 10.1177/00034894231211116] [PMID: 37927046]

21. Pandit P, Patil R, Palwe V, Gandhe S, Manek D, Patil R, et al. Depth of invasion, lymphovascular invasion, and perineural invasion as predictors of neck node metastasis in early oral cavity cancers. *Indian J Otolaryngol Head Neck Surg.* 2023;75(3):1511–6. [DOI: 10.1007/s12070-023-03637-0] [PMID: 37636778]
22. Bakst RL, Glastonbury CM, Parvathaneni U, Katabi N, Hu KS, Yom SS. Perineural invasion and perineural tumor spread in head and neck cancer. *Int J Radiat Oncol Biol Phys.* 2019;103(5):1109–24. [DOI: 10.1016/j.ijrobp.2018.12.009] [PMID: 30562546]
23. Ueno H, Kanemitsu Y, Sekine S, Ishiguro M, Ito E, Hashiguchi Y, et al. Desmoplastic pattern at the tumor front defines poor-prognosis subtypes of colorectal cancer. *Am J Surg Pathol.* 2017;41(11):1506–12. [DOI: 10.1097/PAS.0000000000000946] [PMID: 28877064]
24. Almagush A, Bello IO, Heikkinen I, Hagström J, Haglund C, Kowalski LP, et al. Stromal categorization in early oral tongue cancer. *Virchows Arch.* 2021;478(5):925–32. [DOI: 10.1007/s00428-020-02930-5] [PMID: 32955604]
25. Bittar RF, Ferraro HP, Ribas MH, Lehn CN. Predictive factors of occult neck metastasis in patients with oral squamous cell carcinoma. *Braz J Otorhinolaryngol.* 2016;82(5):543–7. [DOI: 10.1016/j.bjorl.2015.09.005] [PMID: 26749457]
26. Almagush A, Leivo I, Mäkitie AA. Overall assessment of tumor-infiltrating lymphocytes in head and neck squamous cell carcinoma: time to take notice. *Acta Otolaryngol.* 2020;140(3):246–8. [DOI: 10.1080/00016489.2020.1720284] [PMID: 32022615]
27. Salgado R, Denkert C, Demaria S, Sirtaine N, Klauschen F, Pruner G, et al. The evaluation of tumor-infiltrating lymphocytes (TILs) in breast cancer: recommendations by an international TILs Working Group 2014. *Ann Oncol.* 2015;26(2):259–71. [DOI: 10.1093/annonc/mdu450] [PMID: 25214542]
28. Swisher SK, Wu Y, Castaneda CA, Lyons GR, Yang F, Tapia C, et al. Interobserver agreement between pathologists assessing tumor-infiltrating lymphocytes (TILs) in breast cancer using methodology proposed by the international TILs Working Group. *Ann Surg Oncol.* 2016;23(7):2242–8. [DOI: 10.1245/s10434-016-5173-8] [PMID: 26965699]
29. Heikkinen I, Bello IO, Wahab A, Hagström J, Haglund C, Coletta RD, et al. Assessment of tumor-infiltrating lymphocytes predicts the behavior of early-stage oral tongue cancer. *Am J Surg Pathol.* 2019;43(10):1392–6. [DOI: 10.1097/PAS.0000000000001323] [PMID: 31290758]
30. Hori Y, Kubota A, Yokose T, Furukawa M, Matsushita T, Katsumata N, et al. Prognostic role of tumor-infiltrating lymphocytes and tumor budding in early oral tongue carcinoma. *Laryngoscope.* 2021;131(11):2512–8. [DOI: 10.1002/lary.29589] [PMID: 33955550]

## Предиктивна улога туморских инфилтрирајућих лимфоцита и патохистолошких параметара у настанку метастаза на клиничком N0 врату у раном стадијуму оралног сквамозелуларног карцинома

Милош Трајковић<sup>1</sup>, Драган Красић<sup>1,2</sup>, Татјана Јефтовић Стојменов<sup>2</sup>, Никола Живковић<sup>1,3</sup>, Предраг Радовић<sup>1,2</sup>, Милош Стојановић<sup>1</sup>, Симона Стојановић<sup>2,4</sup>

<sup>1</sup>Клиника за денталну медицину, Одељење за максилотоцијалну хирургију, Ниш, Србија;

<sup>2</sup>Универзитет у Нишу, Медицински факултет, Ниш, Србија;

<sup>3</sup>Универзитетски клинички центар у Нишу, Институт за патологију и патолошку анатомију, Ниш, Србија;

<sup>4</sup>Клиника за денталну медицину, Одељење за оралну хирургију, Ниш, Србија

### САЖЕТАК

**Увод/Циљ** Орални сквамозелуларни карцином, са 337.713 регистрованих случајева у свету 2020. године, најчесталији је малигни тумор регије главе и врата. Статус лимфних нодуса врата представља најважнији изоловани прогностички фактор за петогодишње преживљавање болесника. Циљ овог истраживања је утврдити да ли се на основу патохистолошке анализе препарата раног стадијума оралног сквамозелуларног карцинома може предвидети појава окултних метастаза на врату.

**Метод** У студију је укључено 40 болесника са клиничким N0 налазима на врату у раном стадијуму оралног сквамозелуларног карцинома. Свим болесницима је учињена радикална трансорална аблација тумора и елективна лимфаденектомија врата. На основу дефинитивног патохистолошког налаза болесници су подељени у групу са присуством и групу са одсуством окултних метастаза.

**Резултати** У испитиваној групи окултне метастазе су регистроване код 13 болесника (32,5%). Резултати студије указују на постојање значајне разлике параметара дезмопластичне реакције строме ( $p < 0,001$ ), дубине инвазије ( $p < 0,001$ ), лимфоцитне инфилтрације ( $p < 0,001$ ) и лимфоваскуларне инвазије у униваријантној ( $OR\ 24, p = 0,004$ ) и мултиваријантној ( $OR\ 32,713, p = 0,017$ ) логистичној регресионој анализи у групи болесника са окултним метастазама у односу на групу болесника без метастаза.

**Закључак** Резултати наше студије указују на директну повезаност појаве окултних метастаза на врату и појединих патохистолошких параметара. Сигнификантност у предикцији појаве окултних метастаза представља чврст аргумент да поменути параметри треба да бити стандардни део патохистолошког испитивања оралног сквамозелуларног карцинома.

**Кључне речи:** орални сквамозелуларни карцином; окултне метастазе; патохистолошка анализа; хируршко лечење; праћење