

## ORIGINAL ARTICLE / ОРИГИНАЛНИ РАД

# Maxillary sinus augmentation utilizing Xenograft, Bichat's fat pad tissue and low-level light therapy – cone beam computed tomography and resonance frequency analysis results of a prospective randomized clinical study

Vladan Keković<sup>1</sup>, Zoran Vlahović<sup>2</sup>, Kurt Schicho<sup>3</sup>, Dragan Stanimirović<sup>4</sup>, Ivan Soldatović<sup>5</sup>, Nikola Miković<sup>1</sup>, Vitomir S. Konstantinović<sup>1</sup>, Vladimir Sinobad<sup>1</sup>

<sup>1</sup>University of Belgrade, School of Dental Medicine, Maxillofacial Surgery Department, Belgrade, Serbia;

<sup>2</sup>University of Priština, Faculty of Medicine, Department of Dentistry, Kosovska Mitrovica, Serbia;

<sup>3</sup>Allgemeines Krankenhaus University Hospital, Department of Cranio-Maxillofacial Surgery, Vienna, Austria;

<sup>4</sup>University of Belgrade, School of Dental Medicine, Department of Periodontics and Oral Medicine, Belgrade, Serbia;

<sup>5</sup>University of Belgrade, Faculty of Medicine, Department of Biomedical Statistics, Belgrade, Serbia



## SUMMARY

**Introduction/Objective** Implant placement in the posterior maxilla may be often hard to achieve because of insufficient bone volume and the presence of a highly pneumatized maxillary sinus. In these situations, sinus floor augmentation frequently has been proposed as the treatment possibility, conventionally performed utilizing xenograft materials. This research aims to study whether fragmented fat tissue from the Bichat's fat pad mixed with bovine-derived bone yields better results than the use of bovine-derived bone alone in maxillary sinus augmentation. The secondary aim was to evaluate the influence of low-level light therapy on bone regeneration in patients treated with fragmented fat tissue mixed with bovine-derived bone.

**Methods** Six patients were included in the study; 12 maxillary sinus augmentation procedures were performed, and patients were randomly assigned into three groups. Six months after surgery a cone-beam computed tomography bone density analysis was performed, and resonance frequency analysis (RFA) was performed on 12 placed implants.

**Results** Bone density results yielded notable differences in Hounsfield units, with experimental groups ( $499.94 \pm 88.43$ ) resembling natural bone more when compared with the control group ( $674.57 \pm 217.12$ ). RFA data shows that the results exhibit a degree of comparability or moderately better stability in the experimental groups ( $56.88 \pm 6.03$ ) compared to the control group ( $53 \pm 20.12$ ).

**Conclusions** The given Hounsfield units and RFA analysis serve as clear indicators of the substantial potential of fragmented fat tissue and xenograft mixture in maxillary sinus augmentation, by its complete integration and provision of significant stability to the inserted implants. Xenograft mixed with Bichat's fat pad tissue may represent an important novel entity in the field of bone regeneration.

**Keywords:** novel graft; bone regeneration; fat tissue; low-level light therapy

## INTRODUCTION

Implant placement in the posterior maxilla may often be hard to achieve because of insufficient bone volume and the presence of a highly pneumatized maxillary sinus. In these situations, sinus floor augmentation frequently has been proposed as a treatment possibility. Grafting the floor of the maxillary sinus has emerged as the most common surgical modality for correcting this inadequacy. This technique, first published in 1980 by Boyne [1], and subsequently modified by other clinicians, can result in an increase in bone height that allows the placement of implants of conventional length in the grafted sites. Crestal sinus lift involves accessing the maxillary sinus through the alveolar crest, typically via the implant osteotomy site, to elevate the Schneiderian

membrane and place a bone graft material. This technique is suitable for cases with minor to moderate bone deficiency. Lateral sinus lift is a surgical procedure designed to increase bone height in the posterior maxilla when there is significant bone loss. This technique involves creating a lateral access window in the maxillary sinus wall to elevate the Schneiderian membrane and place a bone graft material. As surgical treatment was modified, with time and concomitant improved insight into technology and regenerative medicine, grafting materials were also modified. Various surgical techniques and biomaterials have been developed to make possible the successful placement of dental implants in resorbed alveolar bone, and multiple bone grafting techniques including natural and synthetic graft materials have been tested for this purpose. The process of osteogenesis has

**Received • Примљено:**  
September 12, 2024

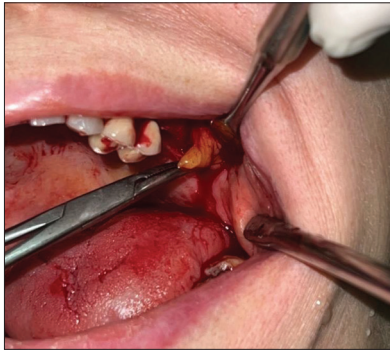
**Revised • Ревизија:**  
December 24, 2024

**Accepted • Прихваћено:**  
January 1, 2025

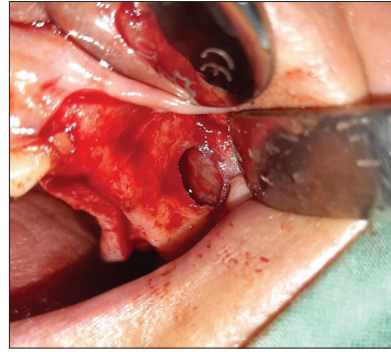
**Online first:** January 9, 2025

### Correspondence to:

Vladan KEKOVIĆ  
University of Belgrade  
School of Dental Medicine  
Department of Maxillofacial  
Surgery  
Bosutska 16  
11000 Belgrade  
Serbia  
[vladan.k@hotmail.com](mailto:vladan.k@hotmail.com)



**Figure 1.** A small fragment of Bichat's fat pad is harvested through the existing flap with no additional morbidity



**Figure 2.** Lateral maxillary sinus augmentation approach

been described as the direct transfer of vital cells to the area that will regenerate new bone. Osteoconduction embraces the principle of providing space and a substratum for the cellular and biochemical events progressing to bone formation. The space maintenance requirement for many of the intraoral bone augmentation procedures allows the correct cells to populate the zone of focus. Osteoinduction embodies the principle of converting pluripotential, mesenchymal-derived cells along an osteoblast pathway with the subsequent formation of bone. With this in mind, it is imperative to design and employ a graft with a significant and optimal regenerative potential.

Fat tissue characterization and subsequent utilization in tissue reconstruction have been found in contemporary literature. Adipose tissue contains a multipotent cell population with similar properties, although not identical, to those of marrow-derived mesenchymal stem cells [2]. Adipose-derived stem cells are shown to be pluripotent *in-vitro* as well as *in-vivo* [3], and utilization of whole fat tissue is also shown to produce bone in critical size bone defects [4].

This research aims to study whether fragmented fat tissue from the Bichat's fat pad mixed with bovine-derived bone yields better results than the use of bovine-derived bone alone in maxillary sinus augmentation. Additionally, a secondary objective was to examine the effect of low-level light therapy (LLLT) to investigate its potential enhancement of bone regeneration.

## METHODS

Before commencement, this study received approval from the Ethical Committee of the School of Dental Medicine, University of Belgrade (Approval No. 36/11). The research adhered to the principles outlined in the Declaration of Helsinki. The investigation was conducted at the Department of Maxillofacial Surgery and the Department of Periodontology and Oral Medicine, School of Dental Medicine, University of Belgrade. Patient inclusion, surgical procedures, data collection, and analysis were carried out during a two-year period (June 28, 2022 – June 28, 2024).

All patients were informed about the study/surgical protocol and provided their informed consent for participation

in the study. The study sample comprised patients who were presented at the School of Dental Medicine, University of Belgrade, for implant rehabilitation and were diagnosed with partial edentulism with atrophy of the posterior maxilla. Unilateral and bilateral atrophy cases were included. The inclusion criteria were the presence of a periodontally healthy frontal maxillary segment due to utilization of a computer-guided system, and a residual bone height of 1–4 mm in the posterior maxilla. Six patients (one female and five males) were included in

this study. A total of 12 maxillary sinus augmentations were performed and 12 implants were inserted.

Exclusion criteria were the following: acute or chronic sinusitis, active sinus or nasal infections, sinus membrane perforation during surgery, history of surgery in the sino-nasal region, history of radiation therapy in the head or neck region, systemic diseases such as uncontrolled diabetes or autoimmune diseases, pregnancy or lactation and history of significant bone metabolic disorders.

Cone beam computed tomography (CBCT) scans were performed before surgery, and patients were randomly assigned into three groups:

Group 1 (control): maxillary sinus augmentation ( $n = 4$ ) using bovine-derived bone (Bio-Oss, Geistlich Pharma AG, Wolhusen, Switzerland);

Group 2 (Xenograft + fat tissue): maxillary sinus augmentation ( $n = 4$ ) using fragmented fat tissue mixed with bovine-derived bone (Bio-Oss, Geistlich Pharma AG) in a 50:50 ratio;

Group 3 (Xenograft + fat tissue + LLLT): maxillary sinus augmentation ( $n = 4$ ) using fragmented fat tissue mixed with bovine-derived bone (Bio-Oss, Geistlich Pharma AG) in a 50:50 ratio, treated with 635 nm pulsing LLLT (Repuls 7, Repuls Lichtmedizintechnik GmbH, Wien, Austria).

In all three groups, after maxillary sinus augmentation, the lateral bone window is covered with a collagen membrane (Bio-Gide, Geistlich Pharma AG).

### Preparation of graft:

Xenograft-Bichat's fat pad mixture (Xenofat graft) was prepared utilizing fat tissue harvested from the Bichat's fat pad (Figure 1). This adipose tissue was obtained concomitantly with the flap used for the lateral sinus lift procedure (Figure 2), thereby minimizing additional morbidity. Fragments of fat tissue were meticulously excised from Bichat's fat pad and subsequently washed with a physiological solution. Following this, the fat tissue was fragmented into smaller particles (Figure 3) and mixed in a 50:50 ratio with bovine-derived bone graft material. The prepared mixture (Figure 4) was carefully placed within the maxillary sinus, positioned between the Schneiderian membrane and the floor of the sinus cavity, as part of the sinus augmentation procedure.



**Figure 3.** Fragmented tissue of the Bichat's fat pad

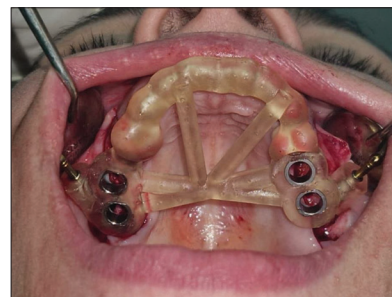
**Surgical procedure**

*First stage*

Antibiotic prophylaxis (1 g of amoxicillin with clavulanic acid or 600 mg clindamycin in cases of penicillin hypersensitivity) was prescribed to each patient, starting one hour before the surgery. Dexamethasone (0.004 g) was administered subcutaneously before surgery. The surgical procedures are performed in the conditions of local anesthesia (Septanest, Septodont, Saint-Maur-des-Fossés, France). All three groups underwent the sinus augmentation procedure using a lateral bone window approach (Figure 2). Surgical procedures in the first group include a conventional maxillary sinus augmentation procedure with the use of bovine-derived bone, while in the second and third groups, Xenograft + Bichat's fat pad tissue was utilized for sinus augmentation. The wounds were sutured with interrupted resorbable sutures. Patients from the third group are additionally treated with 635 nm LLLT (Repuls Lichtmedizintechnik GmbH) in five sessions starting from the third postoperative day.



**Figure 4.** Mixture of Bichat's fat pad tissue and xenogenic bone in a 50:50 ratio



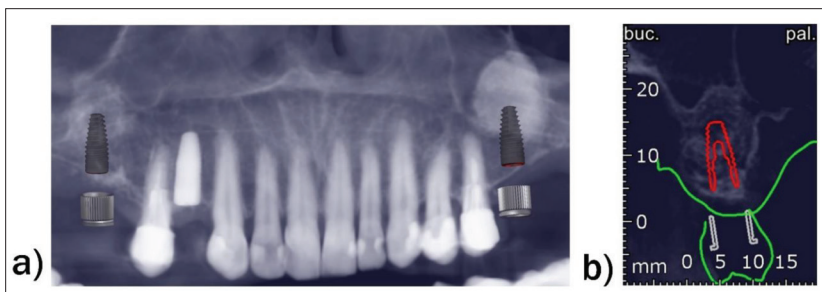**Figure 5.** Fully computer-guided implant protocol

*Second stage*


Six months after maxillary sinus augmentation, CBCT scans were obtained and patients were scheduled for implant placement (Bone Level Tapered®, Institute Straumann AG, Basel, Switzerland). The CBCT scans were utilized to meticulously assess the available bone volume and quality in the posterior maxillary segment, as well as to plan the optimal implant position related to future prosthetic work (Figure 6 and 7). A computer-guided system was employed to navigate the implants into the ideal positions. Customized surgical guides were fabricated and guided implant placement was performed in the posterior maxillary segment (Figure 5). Resonance frequency analysis (RFA) of the placed implant was performed with the use of Penguin RFA device (Integration Diagnostics Ltd., Gothenburg, Sweden).

**CBCT bone density analysis:**

Six months after maxillary sinus augmentation, CBCT scans were performed for dual objectives. Firstly, they were conducted to facilitate the precise planning of computer-guided implants (Figure 6). Secondly, the scans were utilized to analyze the bone density within the surgical site. The evaluation of bone density was conducted utilizing Planmeca Romexis analysis software (Planmeca Oy, Helsinki, Finland). Within this software, a cubical region of interest measuring 7 × 7 × 7 mm was delineated, resulting in a volume of 343 mm<sup>3</sup>. Cubical markings were



**Figure 6.** a) Panoramic radiograph image with planned implants in previously augmented maxillary sinuses; b) bucco-palatal ideal position of the implant in the previously augmented maxillary sinus



**Figure 7.** Hounsfield units analysis



**Table 1.** Differences in Hounsfield units across groups

Parameters	HU	p-value (vs. xenograft) <sup>b</sup>	RFA	p-value (vs. xenograft) <sup>b</sup>
Xenograft	674.57 ± 217.12		53.0 ± 20.12	
Xenograft + Fat	459.68 ± 86.54	0.141	60.75 ± 6.45	0.491
Xenograft + Fat + LLLT	540.19 ± 80.22	0.313	53.0 ± 1.83	1.000
p-value <sup>a</sup>	0.239		0.207	
Xenograft	674.57 ± 217.12		53.0 ± 20.12	
Xenograft + Fat/ Xenograft + Fat + LLLT	499.94 ± 88.43		56.88 ± 6.03	
p-value <sup>b</sup>	0.207		0.729	

HU – Hounsfield units; RFA – resonance frequency analysis;

LLLT – low-level light therapy;

<sup>a</sup>ANOVA;

<sup>b</sup>t test

positioned in bone regions where guided implant placement was subsequently planned. The bone density within this region of interest was automatically quantified and expressed in Hounsfield units (HU), a standardized measure of radiodensity commonly used in radiographic imaging analysis (Figure 7).

### Statistical analysis

The sample size was calculated based on the formula for determining the size of independent samples. Results are presented as mean ± standard deviation. Groups were compared using t-test (two samples) or ANOVA (three samples). Correction for unequal variances was applied where appropriate. All p-values less than 0.05 were considered significant. All data were analyzed using IBM SPSS Statistics for Windows, Version 29.0.2.0 (IBM Corp., Armonk, NY, USA).

### RESULTS

Notable differences in HU across groups are present (Table 1). Specifically, the control group exhibited significantly higher HU (674.57 ± 217.12) compared to the experimental groups (499.94 ± 88.43), which demonstrated Hounsfield unit values that were closer to those observed in natural native bone. Examination of RFA data shows that the results exhibit a degree of comparability or moderately better stability in the experimental groups (56.88 ± 6.03) compared to the control group (53 ± 20.12).

### DISCUSSION

Bone regeneration of the posterior maxilla remains a significant entity in implant-prosthetic rehabilitation due to the high prevalence of bone atrophy in this area. Placement of endosseous implants in patients with highly pneumatized maxillary sinus often requires a two-stage approach, the first stage being maxillary sinus augmentation, conventionally performed utilizing xenograft materials. Implementing effective bone regeneration strategies is crucial for ensuring the success and longevity of implant

treatment, which is why continuous and persistent efforts are invested in investigating different graft materials, driven by the imperative to achieve biomimetic bone composition. Body-derived additives to graft materials, such as various forms of growth factors, including platelet-rich plasma, platelet-rich fibrin, and plasma rich in growth factors; or mineralized tissues such as autologous bone and tooth-derived bone graft are frequently implemented in regenerative procedures [5, 6, 7].

Stem cell research is also, among other fields, focused on the need for bone regeneration in cranial, maxillofacial and oral surgery, especially because of the enormous social and psychological impact of bone defects in these regions. Stem cells are shown to be capable of differentiation under appropriate *in vitro* conditions to mesoderm-type cells, e.g. osteoblasts, adipocytes and chondrocytes [8]. This was also shown in clinical settings [9]. In clinical conditions, the accessibility of suitable cell sources is a critical consideration. An abundant tissue in most individuals and amenable to minimally invasive harvesting procedures is adipose tissue, which also emerged in the literature as a promising reservoir of stem cells [10]. Adipose tissue is readily accessible for clinical use via minimally invasive procedures, which is especially apparent in this study design since there was no additional morbidity in obtaining the Bichat's fat pad tissue, whose stem cells were shown to have similarities in cell yield, morphology, and multilineage differentiation with other adipose-derived stem cells while demonstrating faster proliferation and greater tendency of producing colonies [11]. Buccal fat-pad-derived stem cells were used successfully in the treatment of large alveolar bone defects [12], as well as in the augmentation of the atrophic posterior mandible as an additive to xenogenic bone [13]. Adipose tissue was also utilized as unprocessed with success in experimental [14], as well as clinical [4], highlighting its efficiency and clinical applications. Based on HU analysis, fragmented Bichat's fat pad tissue in this study showed contribution to achieving graft anatomy that closely aligns with natural bone anatomic structure, while at the same time providing high stability for implants.

With the advancement of technology and science, various innovative approaches have emerged to stimulate tissue regeneration. Among these approaches, the utilization of light therapy has gained prominence [15]. LLLT, also known as photobiomodulation, encompasses a spectrum of techniques that harness the therapeutic properties of light to modulate cellular activities and promote tissue repair. This non-invasive modality involves the application of specific wavelengths of light to targeted tissues, where it interacts with chromophores within cells, initiating a cascade of biological responses. Through mechanisms such as photobiomodulation, light therapy has been shown to enhance cellular metabolism, accelerate wound healing [16, 17], reduce inflammation, and promote angiogenesis

[18, 19] and collagen synthesis [20, 21]. Moreover, light therapy offers versatility in its application, with various modalities that include also possible intraoral and extraoral applications. An extraoral approach with pulsing LED 635 nm light was shown to successfully penetrate soft and hard tissues in the maxillofacial region, proving the possibility of reaching deeper tissues and achieving therapeutic goals [22]. Several studies showed the beneficial effect of LLLT on bone regeneration. Bai et al. [23] demonstrated the promotion of blood vessel, collagen fiber and bone tissue formation, while a systematic review by Kheiri et al. [24] showed evidence of stimulation of osteogenesis in critical-size bone defects as well as enhancement of fibroblast and osteoblast proliferation with the use of LLLT. The addition of LLLT to the first experimental group in this study yielded similar results, however, given that the expected influence of LLLT primarily pertains to angiogenesis, further studies and biopsy analysis will be crucial in elucidating its specific impact.

Zizelmann et al. [25] evaluated the use of autologous cancellous bone graft, which is the gold standard, in maxillary sinus augmentation and obtained bone density of 266–551 HU, which resembles natural bone density and is also comparable with experimental groups of this study. Al-Obaidi et al. [26] performed graftless maxillary sinus augmentation, utilizing only gelatine sponges in order to organize the blood clot under the elevated Schneiderian membrane, so the obtained bone was native bone whose bone density ( $595.5 \pm 159.4$  HU) is also comparable with results of this study. Maxillary sinus augmentation utilizing calcium phosphate bioceramics granules demonstrated a higher mean bone density ( $766.9\text{--}1018.7$  HU) when compared with the lower density of the native bone control group ( $482.6\text{--}891$  HU) [27]. The ideal bone graft material should emulate the structural, mechanical, and biological properties of native bone tissue. This study utilized current knowledge and advancements in biomaterial science, tissue engineering, and regenerative medicine which hold promise in obtaining a step closer to this goal. In this study, analysis of CBCT findings in the control group compared

to the experimental groups individually and collectively reveals that both experimental groups exhibit bone morphology more closely resembling natural native bone. All groups yielded high implant stability, with slightly better stability in experimental groups, however, a larger sample size is needed to get more insight. Further histological characterization and additional analyses will contribute to a deeper understanding of the achieved results and may potentially serve as guidelines for further scientific inquiry.

The given HU and RFA analysis serve as clear indicators of the substantial potential of this graft mixture, by its complete integration and provision of significant stability to the inserted implants. Xenograft mixed with Bichat's fat pad tissue may represent a novel entity in the field of bone regeneration.

## CONCLUSION

The findings of this study support that the utilization of fragmented Bichat's fat pad tissue xenograft mixture may enhance the regenerative process in terms of obtaining bone more resembling native bone compared with the utilization of xenograft alone. Additionally, the augmented graft demonstrates high implant stability, indicating its potential for successful integration and long-term support. The addition of LLLT also resulted in bone resembling native bone while maintaining high implant stability. Further analyses based on tissue biopsies are ongoing and will provide additional insights, enhancing our understanding of the observed results.

## ACKNOWLEDGMENT

This paper is a part of Dr. Vladan Keković's doctoral thesis, which is not yet published.

**Conflict of interest:** None declared.

## REFERENCES

1. Boyne PJ. Grafting of the maxillary sinus floor with autogenous marrow and bone. *J Oral Surg.* 1980;38(8):613–6. [PMID: 6993637]
2. Nahmgoong H, Jeon YG, Park ES, Choi YH, Han SM, Park J, et al. Distinct properties of adipose stem cell subpopulations determine fat depot-specific characteristics. *Cell Metab.* 2022;34(3):458–72.e6. [DOI: 10.1016/j.cmet.2021.11.014] [PMID: 35021043]
3. Bunnell BA. Adipose Tissue-Derived Mesenchymal Stem Cells. *Cells.* 2021;10(12):3433. [DOI: 10.3390/cells10123433] [PMID: 34943941]
4. Gomes SP, Deliberador TM, Gonzaga CC, Klug LG, da Costa Oliveira L, de Andrade Urban C, et al. Bone healing in critical-size defects treated with immediate transplant of fragmented autogenous white adipose tissue. *J Craniofac Surg.* 2012;23(5):1239–44. [DOI: 10.1097/SCS.0b013e31825da9d9] [PMID: 22948634]
5. Ortega-Mejia H, Estrugo-Devesa A, Saka-Herrán C, Ayuso-Montero R, López-López J, Velasco-Ortega E. Platelet-Rich Plasma in Maxillary Sinus Augmentation: Systematic Review. *Materials (Basel).* 2020;13(3):622. [DOI: 10.3390/ma13030622] [PMID: 32019255]
6. Batas L, Tsalikis L, Stavropoulos A. PRGF as adjunct to DBB in maxillary sinus floor augmentation: histological results of a pilot split-mouth study. *Int J Implant Dent.* 2019;5(1):14. [DOI: 10.1186/s40729-019-0166-6] [PMID: 30931490]
7. Simončič B, Dimitrijević M, Juloski J, Vuličević ZR. The use of adipose-derived stem cells, platelet-rich and platelet-poor plasma in the maxillary cyst treatment. *Srp Arh Celok Lek.* 2022;150(9–10):589–93. [DOI: 10.2298/SARH220505089S]
8. Shafaei H, Kalarestaghi H. Adipose-derived stem cells: An appropriate selection for osteogenic differentiation. *J Cell Physiol.* 2020;235(11):8371–86. [DOI: 10.1002/jcp.29681] [PMID: 32239731]
9. Grayson WL, Bunnell BA, Martin E, Frazier T, Hung BP, Gimble JM. Stromal cells and stem cells in clinical bone regeneration. *Nat Rev Endocrinol.* 2015;11(3):140–50. [DOI: 10.1038/nrendo.2014.234] [PMID: 25560703]
10. Rodriguez AM, Elabd C, Amri EZ, Ailhaud G, Dani C. The human adipose tissue is a source of multipotent stem cells. *Biochimie.* 2005;87(1):125–8. [DOI: 10.1016/j.biochi.2004.11.007] [PMID: 15733747]

11. Salehi-Nik N, Rezai Rad M, Kheiri L, Nazeman P, Nadjmi N, Khojasteh A. Buccal Fat Pad as a Potential Source of Stem Cells for Bone Regeneration: A Literature Review. *Stem Cells Int.* 2017;2017:8354640. [DOI: 10.1155/2017/8354640] [PMID: 28757880]
12. Khojasteh A, Hosseinpour S, Rad MR, Alikhasi M. Buccal Fat Pad-Derived Stem Cells in Three-Dimensional Rehabilitation of Large Alveolar Defects: A Report of Two Cases. *J Oral Implantol.* 2019;45(1):45–54. [DOI: 10.1563/aaid-joi-D-17-00215] [PMID: 30280966]
13. Khojasteh A, Hosseinpour S, Rezai Rad M, Alikhasi M, Zadeh HH. Buccal fat pad-derived stem cells with anorganic bovine bone mineral scaffold for augmentation of atrophic posterior mandible: An exploratory prospective clinical study. *Clin Implant Dent Relat Res.* 2019;21(2):292–300. [DOI: 10.1111/cid.12729] [PMID: 30821120]
14. Oliveira LD, Giovanini AF, Abuabara A, Klug LG, Gonzaga CC, Zielak JC, et al. Fragmented adipose tissue graft for bone healing: histological and histometric study in rabbits' calvaria. *Med Oral Patol Oral Cir Bucal.* 2013;18(3):e510–5. [DOI: 10.4317/medoral.18407] [PMID: 23524416]
15. Rakašević D, Lazić Z, Rakonjac B, Soldatović I, Janković S, Magić M, et al. Efficiency of photodynamic therapy in the treatment of peri-implantitis: A three-month randomized controlled clinical trial. *Srp Arh Celok Lek.* 2016;144(9–10):478–84. [DOI: 10.2298/SARH1610478R] [PMID: 29652462]
16. Kekovic V, Schicho K, Perisanidis C, Mikovic N, Stanimirovic D, Soldatovic I, et al. Effect of Low-level Light Therapy on Post-operative Healing of Secondary Chronic Osteomyelitis of the Jaws - A Prospective Study. *Ann Maxillofac Surg.* 2023;13(2):200–4. [DOI: 10.4103/ams.ams\_105\_23] [PMID: 38405576]
17. Waluyo Y, Hidayat MS. Low-Level Laser Therapy (LLLT) for Diabetic Foot Ulcer in Uncontrolled Diabetes: A Case Report of Improved Wound Healing. *Am J Case Rep.* 2024;25:e944106. [DOI: 10.12659/AJCR.944106] [PMID: 38956839]
18. Dungal P, Hartinger J, Chaudary S, Slezak P, Hofmann A, Hausner T, et al. Low level light therapy by LED of different wavelength induces angiogenesis and improves ischemic wound healing. *Lasers Surg Med.* 2014;46(10):773–80. [DOI: 10.1002/lsm.22299] [PMID: 25363448]
19. Zhong J, Zhang X, Ruan Y, Huang Y. Photobiomodulation therapy's impact on angiogenesis and osteogenesis in orthodontic tooth movement: in vitro and in vivo study. *BMC Oral Health.* 2024;24(1):147. [DOI: 10.1186/s12903-023-03824-z]
20. Chang CJ, Hsiao YC, Hang NLT, Yang TS. Biophotonic effects of low-level laser therapy on adipose-derived stem cells for soft tissue deficiency. *Ann Plast Surg.* 2023;90(5S):S158–S164. [DOI: 10.1097/SAP.0000000000003376] [PMID: 36752397]
21. Huang X, Tao Q, Ren C. A Comprehensive Overview of the Neural Mechanisms of Light Therapy. *Neurosci Bull.* 2024;40(3):350–62. [DOI: 10.1007/s12264-023-01089-8] [PMID: 37555919]
22. Keković V, Schicho K, Figl M, Arany P, Jezdić Z, Soldatović I, et al. Light distribution of 635 nm LED for PBM treatments in the maxillofacial region. *Oral and Maxillofacial Surgery Cases.* 2021;7(1):100208. [DOI: 10.1016/j.jomsc.2021.100208]
23. Bai J, Li L, Kou N, Bai Y, Zhang Y, Lu Y, et al. Low level laser therapy promotes bone regeneration by coupling angiogenesis and osteogenesis. *Stem Cell Res Ther.* 2021;12(1):432. [DOI: 10.1186/s13287-021-02493-5] [PMID: 34344474]
24. Kheiri A, Amid R, Kheiri L, Namdari M, Mojahedi M, Kadkhodazadeh M. Effect of Low- Level Laser Therapy on Bone Regeneration of Critical-Size Bone Defects: A Systematic Review of In Vivo Studies and Meta-Analysis. *Arch Oral Biol.* 2020;117:104782. [DOI: 10.1016/j.archoralbio.2020.104782] [PMID: 32535292]
25. Zizelmann C, Schoen R, Metzger MC, Schmelzeisen R, Schramm A, Dott B, et al. Bone formation after sinus augmentation with engineered bone. *Clin Oral Implants Res.* 2007;18(1):69–73. [DOI: 10.1111/j.1600-0501.2006.01295.x] [PMID: 17224026.]
26. Al-Obaidi M, Alhamdani F, Alalawi H, Alhamdani F. Evaluation of Bone around Dental Implants with Sinus Lift Using Gelfoam Augmentation. *South Asian Res J Oral Dent Sci.* 2021;3:108–18. [DOI: 10.36346/sarjods.2021.v03i05.002]
27. Neimane L, Skagers A, Salms G, Berzina-Cimdina L. Radiodensitometric Analysis of Maxillary Sinus-Lift Areas Enforced with Bone Substitute Materials Containing Calcium Phosphate. *Acta Chir Latv.* 2012;12(1):41–4. [DOI: 10.2478/v10163-012-0009-5]

## Аугментација максиларног синуса коришћењем ксенографта, ткива Бихатовог масног јастучета и терапије светлошћу ниског интензитета – резултати проспективне рандомизоване клиничке студије компјутеризоване томографије конусног снопа и радиофреквентне аблације

Владан Кековић<sup>1</sup>, Зоран Влаховић<sup>2</sup>, Курт Шихо<sup>3</sup>, Драган Станимировић<sup>4</sup>, Иван Солдатовић<sup>5</sup>, Никола Миковић<sup>1</sup>, Витомир С. Константиновић<sup>1</sup>, Владимир Синобад<sup>1</sup>

<sup>1</sup>Универзитет у Београду, Стоматолошки факултет, Клиника за максилофацијалну хирургију, Београд, Србија;

<sup>2</sup>Универзитету Приштини, Медицински факултет, Одсек за стоматологију, Косовска Митровица, Србија;

<sup>3</sup>Универзитетска болница „Allgemeines Krankenhaus“, Клиника за краниомаксилофацијалну хирургију, Беч, Аустрија;

<sup>4</sup>Универзитет у Београду, Стоматолошки факултет, Клиника за пародонтологију и оралну медицину, Београд, Србија;

<sup>5</sup>Универзитет у Београду, Медицински факултет, Институт за медицинску статистику и информатику, Београд, Србија

### САЖЕТАК

**Увод/Циљ** Уградња денталних имплантата у регији постериорне максиле може представљати изазов услед честе појаве недовољног волумена кости и присуства високопнеуматизованог максиларног синуса. У оваквим ситуацијама као терапијски модалитет препоручује се аугментација максиларног синуса и конвенционално се изводи помоћу ксеногених материјала.

Циљ овог истраживања је анализа резултата употребе фрагментисаног масног ткива Бихатовог масног јастучета у комбинацији са коштаним замениоцем говеђег порекла, у односу са употребом само коштанога замениоца говеђег порекла код аугментације максиларних синуса. Секундарни циљ студије је евалуација утицаја терапије светлошћу ниског интензитета на регенерацију кости код пацијената третираних фрагментисаним масним ткивом у комбинацији са коштаним замениоцем говеђег порекла.

**Метод** У студију је укључено шест пацијената, учињено је 12 аугментација максиларних синуса, а пацијенти су насумично распоређени у три групе. Шест месеци после хирургије урађена је компјутеризована томографија конусног

снопа густине кости и анализа резонантне фреквенције 12 уграђених имплантата.

**Резултати** Резултати анализе густине кости показали су значајне разлике у Хоунсфилдовим јединицама, са вредностима експерименталне групе ( $499,94 \pm 88,43$ ) које су сличније вредностима природне нативне кости у поређењу са вредностима контролне групе, које су више ( $674,57 \pm 217,12$ ). Анализа резонантне фреквенције имплантата показала је сличне вредности контролне групе ( $53 \pm 20,12$ ) и експерименталних група, са благо вишим нивоом стабилности имплантата код експерименталних група ( $56,88 \pm 6,03$ ).

**Закључак** Дате Хоунсфилдове јединице и анализе резонантне фреквенције јасни су индикатори значајног потенцијала употребе комбинације фрагментисаног масног ткива и ксеногеног коштанога замениоца код аугментације максиларних синуса, демонстрирајући комплетну интеграцију и пружање значајне стабилности уграђеним имплантатима. Фрагментисано масно ткиво у комбинацији са ксенографтом може представљати значајан нови ентитет у области коштане регенерације.

**Кључне речи:** нови графт; регенерација кости; масно ткиво; терапија светлошћу ниског интензитета