

ORIGINAL ARTICLE / ОРИГИНАЛНИ РАД

Functional results of patients with ankle syndesmosis injuries treated with the dynamic fixation (the syndesmosis TightRope® suture button) compared to the rigid fixation

Filip Maljković¹, Nemanja Slavković^{1,2}, Želimir Jovanović¹, Nemanja Jovanović¹,
Vedrana Pavlović^{2,3}, Branislav Krivokapić^{1,2}

¹Banjica Institute for Orthopedic Surgery, Belgrade, Serbia;

²University of Belgrade, Faculty of Medicine, Belgrade, Serbia;

³Institute for Medical Statistics and Informatics, Belgrade, Serbia



SUMMARY

Introduction/Objective Sprains account for 85% of all ankle injuries. Syndesmosis injuries occur in 1–18% of patients with ankle sprains and are more common in contact sports involving forced foot dorsiflexion.

Methods In our study, we compared 30 patients treated with dynamic fixation for acute syndesmotic injury with patients treated with rigid fixation. The criteria for comparison were: American Orthopedic Foot and Ankle Society (AOFAS) Ankle Hindfoot Scale, visual analogue scale (VAS), EuroQol five-dimension questionnaire (EQ-5D), range of motion, complications and reoperations.

Results The mean AOFAS score for patients treated with rigid fixation was 88.6, while the mean score for patients treated with dynamic fixation was 91.6. The mean VAS score for rigid fixation was 83.5, while it was 85.8 for dynamic fixation. Infection as a complication of rigid fixation was present in two patients (11.8%), while it was absent in the dynamic fixation group. The need for implant removal occurred in two patients treated with rigid fixation (11.8%) and in one patient treated with dynamic fixation (7.7%).

Conclusion Based on our results and the results reported by other authors, we prove that there is a lower incidence of problems related to implants and the need for the implant removal with dynamic fixation, based on the results of AOFAS score, we notice better and faster recovery with dynamic fixation as well.

Keywords: ankle syndesmosis injuries; dynamic fixation; rigid fixation; AOFAS score

INTRODUCTION

The talocrural joint is the supporting joint consisting of the articular surfaces of the distal tibia and fibula as well as the talus in its superior, medial and lateral aspects. The morphology of these surfaces forms a hinge-type synovial joint with one axis of movement (bimalleolar axis) which enables dorsiflexion and plantar flexion of the foot in the sagittal plane. The normal range of motion of plantar flexion is 23–56° and of dorsiflexion 11–33° [1]. Passive ankle stability depends on joint surface contour, joint capsule, collateral ligament and retinaculum integrity. Muscles provide dynamic stability of the ankle. Based on the functional relationship with the rest of the body, it is not surprising that ankle injuries are among the most common ones. Sprains account for 85% of all ankle injuries [2, 3]. Syndesmosis injuries occur in 1–18% of patients with ankle sprains and are more common in contact sports involving forced foot dorsiflexion [4]. Also, these injuries are associated with 23% of all ankle fractures [5].

Syndesmotic ligaments (talofibular ligaments) are composed of three separate parts. The anterior talofibular ligament is the weakest of all syndesmotic ligaments and is the first to be injured when the fibula rotates around its

longitudinal axis [6]. It consists of three parts, the upper which is the shortest, the medial which is the strongest and the lower which is the longest and thinnest. The posterior talofibular ligament is a strong, compact ligament whose lower edge literally forms the labrum for the lateral ridge of the trochlea of the talus. And the interosseous tibiofibular ligament, which consists of a network of pyramidal fibers composed of fibrous and adipose tissue [7].

The aim of this study is to present the functional outcome of patients with ankle syndesmosis injury treated with rigid or Tigh-rope fixation.

METHODS

In our study, we had 30 patients, of whom 18 were women and 12 men. The patients we included in the study were physically active and recreationally engaged in sports. The diagnosis of syndesmosis injury was made on the basis of clinical examination, X-ray and NMR. In our study, we compared patients treated with dynamic (ArthrexTighRope) fixation for acute syndesmotic injury with patients treated with rigid fixation. This study was retrospective and included patients who were treated in the

Received • Примљено:

June 24, 2024

Revised • Ревизија:

August 20, 2024

Accepted • Прихваћено:

August 22, 2024

Online first: August 30, 2024

Correspondence to:

Branislav KRIVOKAPIĆ
Banjica Institute for Orthopedic
Surgery
Mihaila Avramovića 28
11000 Belgrade
Serbia
banedoctor1984@gmail.com

Institute for Orthopedic Surgery “Banjica” in the period from 01 January 2016 to 01 January 2020. The inclusion criterion for our study was a syndesmosis injury which was proven intraoperatively. The exclusion criteria were open fracture and polytrauma. The criteria for comparison were: American Orthopedic Foot and Ankle Society (AOFAS) Ankle Hindfoot Scale, visual analogue scale (VAS), EuroQol five-dimension questionnaire (EQ-5D), range of motion, complications and reoperations.

Rigid and dynamic fixation of syndesmosis was performed in the operating room under radiographic control. The operations were performed according to AO principles. Antibiotics and thromboprophylaxis were given according to the Institute protocol. Patients were advised non-weight-bearing walking for six weeks with the present immobilization until the removal of the sutures (two weeks). Full weight-bearing was allowed after six weeks. After removing the sutures, the patients were referred to physical therapy. Regular visits occurred after the second, sixth, 12th, 24th week. We performed the assessment minimum six months after the injury.

To describe the results we obtained, we did the comparison with the healthy side and presented the results using the AOFAS score, which is a clinical score that evaluates the function of the ankle and foot before and after treatment, with a maximum score of 100 corresponding to normal ankle function. Through the EuroQol five-dimension questionnaire (EQ-5D), patients described the possibility of performing daily activities. This questionnaire contains five characteristics: mobility, self-care, usual activities, pain/discomfort, anxiety/depression. Each of these characteristics has five levels: no problems, slight problems, moderate problems, serious problems and extreme problems. 5Q-5D can be used as a quantitative measure of treatment outcome assessed by the patient himself/herself. To monitor the subjective experience of symptom severity, we used VAS, which is used to quickly classify symptom severity and control of the disease or condition. We tested the range of motion by comparing the injured and healthy foot, and the results were expressed as a percentage relative to the uninjured side.

The study has been approved by competent Ethics Committee, and conforms to the legal standards. The Decision Number of the Ethics Committee is i-97/30.

RESULTS

Thirty patients were included in our study, of whom 13 were treated with dynamic fixation and 17 with rigid fixation (RF), aged 40–60 with a mean value of 49.3 ± 5.4 (RF 49.5 ± 5.4 , dynamic fixation (DF) 49.0 ± 5.5 , $p = 0.795$) of whom 18 were women (60%). RF was used in 10 (58.8%), DF in eight (61.5%), $p = 0.880$. The minimum follow-up period from the intervention was two years. We classified the fractures according to the AO classification. We had B1 type fractures in 11 (36%) patients – RF was used in nine (52.9%), DF in two (15.4%), B2 type fractures in nine (30%) patients – RF in five (29.4%), DF in four (30.8%), B3 type

fractures in seven (23.3%) patients – RF in two (11.8%), DF in five (38.5%), C1 type fractures in two patients (6.7%), RF in 0 (0%), DF in two (15.4 %) and C3 type in one (3.3%) patient; RF in one (5.9%), DF in zero (0%) (Table 1).

In our study, the occurrence of infection as a complication was present in two (6.7%) patients. Both patients were treated with rigid fixation (11.8%), while in dynamic fixation we did not have this complication (0%). We had implant removal in three (10%) patients, of which two (11.8%) had rigid fixation and one (7.7%) had dynamic fixation (Table 2).

Table 1. Demographic characteristics of study population

Patient characteristics	Total n = 30	Rigid fixation n = 17	Dynamic fixation n = 13	p-value
Age, mean \pm sd	49.3 ± 5.4	49.5 ± 5.4	49 ± 5.5	0.795
Gender, female, n (%)	18 (60)	10 (58.8)	8 (61.5)	0.880
Type of bone fracture, n (%)	B1	11 (36.7)	9 (52.9)	2 (15.4)
	B2	9 (30.0)	5 (29.4)	4 (30.8)
	B3	7 (23.3)	2 (11.8)	5 (38.5)
	C1	2 (6.7)	0 (0.0)	2 (15.4)
	C3	1 (3.3)	1 (5.9)	0 (0.0)

Table 2. Complications

Complications	Total n = 30	Rigid fixation n = 17	Dynamic fixation n = 13	p-value
Infection, n (%)	2 (6.7)	2 (11.8)	0 (0.0)	0.492
Screw removal, n (%)	3 (10)	2 (11.8)	1 (7.7)	1.000

We demonstrated that patients in the group in which syndesmosis was treated with dynamic fixation had better AOFAS scores and modified visual analog scales based on the EQ-5D-5L questionnaire.

The mean value of AOFAS score was 89.9 ± 13.9 (RF 88.6 ± 17.1 , DF 91.6 ± 8.4 , $p = 0.572$). The mean value of VAS scale was 84.5 ± 19.6 (RF 83.5 ± 21.7 , DF 85.8 ± 17.2 , $p = 0.762$), with a value of 1 indicating the worst and 100 the best result.

Also, by analyzing the modified EQ-5D-5L questionnaire, we obtained better results in most individual parameters in the group of patients treated with dynamic fixation compared to those treated with rigid fixation. The results are shown in Figures 1 and 2, as well as in Tables 3 and 4.

DISCUSSION

Since dynamic fixation of syndesmosis is a relatively new technique, the current literature on this topic consists mainly of studies with small samples, such as ours. In our study, the minimum follow-up period was two years from the intervention. The most common fracture types according to the AO classification were B1 and B2. Surgical treatment of syndesmosis injury is an imperative in treatment, to prevent ankle instability and secondary osteoarthritis. Standard treatment involves the use of trans-syndesmotic screws. While the new technique is the use of dynamic fixation (The syndesmosis TightRope® suture button)

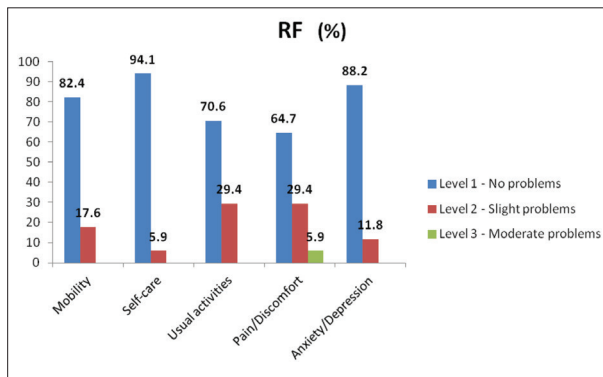


Figure 1. Rigid fixation (RF)

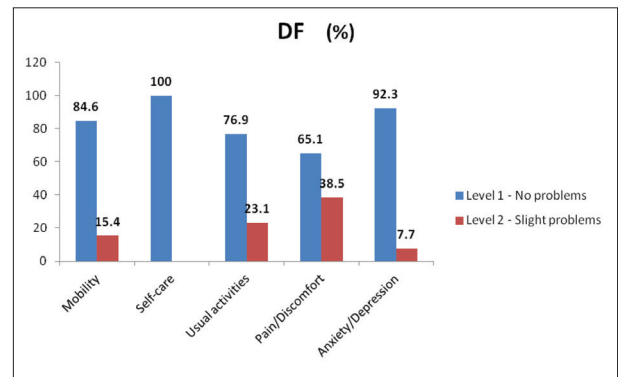


Figure 2. Dynamic fixation (DF)

Table 3. EuroQol five-dimension questionnaire (EQ-5D) results

Type of fixation	Mobility		Self-care		Usual activities		Pain/discomfort			Anxiety/depression	
	Level 1	Level 2	Level 1	Level 2	Level 1	Level 2	Level 1	Level 2	Level 3	Level 1	Level 2
RF, n (%)	14 (82.4)	3 (17.6)	16 (94.1)	1 (5.9)	12 (70.6)	5 (29.4)	11 (64.7)	5 (29.4)	1 (5.9)	15 (88.2)	2 (11.8)
DF, n (%)	11 (84.6)	2 (15.4)	13 (100)	0 (0.0)	10 (76.9)	3 (23.1)	8 (61.5)	5 (38.5)	0 (0.0)	12 (92.3)	1 (7.7)

RF – rigid fixation; DF – dynamic fixation

Table 4. Comparison of quality of life between patients treated with different procedures

Score	Total n = 30	Rigid fixation n = 17	Dynamic fixation n = 13	p-value
VAS, mean ± sd	84.5 ± 19.6	83.5 ± 21.7	85.8 ± 17.2	0.762
AOFAS, mean ± sd	89.9 ± 13.9	88.6 ± 17.1	91.6 ± 8.4	0.572

VAS – visual analogue scale; AOFAS – American Orthopedic Foot and Ankle Society score

which is a permanent stabilization system composed of a nonabsorbable suture. A drill hole is made through all four cortices in a parallel manner along the transmalleolar axis, 1–2 cm above the ankle joint. A needle containing the pull-through suture is advanced through the drilled hole from a lateral approach. The suture pulls the oblong button longitudinally across the hole until it can be flipped and attached to the medial tibial cortex. The suture is tightly tied by hand to stabilize compression. In cases of Maisonneuve fracture, two TightRope® sutures may be placed. The procedure requires anatomic fibular alignment, and thus associated fibular fractures usually undergo simultaneous reduction and internal fixation [8]. In their work, Westermann et al. [9] demonstrated that dynamic fixation allows more movement and better self-centering of syndesmosis, which proves better anatomical reduction of syndesmosis. In their study, Qamar et al. [10] presented 16 patients with tibiofibular syndesmosis injury treated with dynamic fixation, with a follow-up period of two years. The average AOFAS score was 86.88 ± 11.49. Thornes and McCartan [8] in a similar study showed a mean AOFAS score of 93 with TightRope® compared to the use of a trans-syndesmotomic screw whose mean AOFAS score was 83. Colcuc et al. [11] have proven in their study that dynamic fixation has a lower complication rate and earlier return to sports activities and their conclusion is that this method is especially recommended for highly active patients. Some authors showed that the use of rigid fixation is associated with a higher reoperation rate compared to dynamic

fixation, mainly due to screw removal [12]. Routine screw removal is also associated with a wound infection rate of 5–9% [13]. One of the advantages of dynamic fixation is that it does not require implant removal [12]. Some studies show osteolysis, an implant slippage, and tibial drill-hole enlargement with the use of dynamic fixation [14, 15]. Better AOFAS results when using dynamic fixation compared to a rigid type, indicate a higher level of satisfaction and functionality in patients treated with dynamic type of fixation, which suggests that dynamic fixation is a valid option in the treatment of these injuries. Benedikte et al. showed that five years after syndesmotomic injury which was treated with either dynamic or rigid fixation, they found better AOFAS and OMA scores and they also found lower incidence of ankle osteoarthritis, in the dynamic fixation group [16–27]. Based on our results and the results of the above authors, we prove that there is a lower incidence of problems related to implants and the need for the implant removal with dynamic fixation, based on the results of AOFAS score, we notice better and faster recovery with dynamic fixation as well. However, we believe that it is desirable to do a randomized controlled trial with more parameters in the outcome reports in order to determine the long-term effects of the dynamic fixation method.

Infection rate of patients who undergo surgical treatment of ankle fracture is 1–8%.

Predisposing factors for occurrence of infection are: patient age, high-energy injuries, smoking, diabetes, open fracture, compromised soft tissue sheath, alcoholism [28, 29, 30].

CONCLUSION

Since our results show reduced incidence of infections in patients treated with dynamic fixation, a study that would show whether the use of dynamic fixation has an effect on reducing the incidence of infection in all operated

ankles, should also be considered. The dynamic fixation system has a similar treatment result compared to rigid fixation. The rate of implant removal and infection is lower compared to the group treated with syndesmotic screw. Dynamic fixation is a modern and promising technique for surgical repair of ankle syndesmosis injury and can

eventually replace traditional fixation with a trans-syndesmotic screw. In addition, there is a need for studies on the long-term effects of the TightRope® system.

Conflicts of Interest: None declared.

REFERENCES

- Castro MD. Ankle biomechanics. *Foot Ankle Clin.* 2002;7(4):679–93. [DOI: 10.1016/s1083-7515(02)00049-9] [PMID: 12516726]
- Garrick JG. The frequency of injury, mechanism of injury, and epidemiology of ankle sprains. *Am J Sports Med.* 1977;5(6):241–2. [DOI: 10.1177/036354657700500606] [PMID: 563179]
- Ferran NA, Oliva F, Maffulli N. Ankle instability. *Sports Med Arthrosc Rev.* 2009;17(2):139–45. [DOI: 10.1097/JSA.0b013e3181a3d790] [PMID: 19440141]
- Marín Fermín T, Papakostas ET, Olory BCR, D'Hooghe P. Tibiofibular syndesmosis injury. *Orthop Sports Med.* 2024;1–20. [DOI: 10.1007/978-3-030-65430-6_133-1]
- Rammelt S, Obruba P. An update on the evaluation and treatment of syndesmotic injuries. *Eur J Trauma Emerg Surg.* 2015;41(6):601–14. [DOI: 10.1007/s00068-014-0466-8] [PMID: 26037997]
- Golanó P, Vega J, Pérez-Carro L, Götzens V. Ankle anatomy for the arthroscopist. Part II: Role of the ankle ligaments in soft tissue impingement. *Foot Ankle Clin.* 2006;11(2):275–96, v-vi. [DOI: 10.1016/j.fcl.2006.03.003] [PMID: 16798512]
- Bartonicek J. Anatomy of the tibiofibular syndesmosis and its clinical relevance. *Surg Radiol Anat.* 2003;25(5–6):379–86. [DOI: 10.1007/s00276-003-0156-4] [PMID: 14504816]
- Thornes B, McCartan D. Ankle syndesmosis injuries treated with the TightRope Suture-Button Kit. *Techniques in Foot and Ankle Surgery.* 2006;5(1):45–53. [DOI: 10.1097/00132587-200603000-00010]
- Westermann RW, Rungprai C, Goetz JE, Femino J, Amendola A, Phisitkul P. The effect of suture-button fixation on simulated syndesmotic malreduction: a cadaveric study. *J Bone Joint Surg Am.* 2014;96(20):1732–8. [DOI: 10.2106/JBJS.N.00198] [PMID: 25320200]
- Qamar F, Kadakia A, Venkateswaran B. An anatomical way of treating ankle syndesmotic injuries. *J Foot Ankle Surg.* 2011;50(6):762–5. [DOI: 10.1053/j.jfas.2011.07.001] [PMID: 21962383]
- Colcuc C, Blank M, Stein T, Raimann F, Weber-Spickschen S, Fischer S, et al. Lower complication rate and faster return to sports in patients with acute syndesmotic rupture treated with a new knotless suture button device. *Knee Surg Sports Traumatol Arthrosc.* 2018;26(10):3156–64. [DOI: 10.1007/s00167-017-4820-3] [PMID: 29224059]
- Grassi A, Samuelsson K, D'Hooghe P, Romagnoli M, Mosca M, Zaffagnini S, et al. Dynamic Stabilization of Syndesmosis Injuries Reduces Complications and Reoperations as Compared With Screw Fixation: A Meta-analysis of Randomized Controlled Trials. *Am J Sports Med.* 2020;48(4):1000–13. [DOI: 10.1177/0363546519849909] [PMID: 31188642]
- Andersen MR, Frihagen F, Madsen JE, Figved W. High complication rate after syndesmotic screw removal. *Injury.* 2015;46(11):2283–7. [DOI: 10.1016/j.injury.2015.08.021] [PMID: 26319204]
- Hohman DW, Affonso J, Marzo JM, Ritter CA. Pathologic tibia/fibula fracture through a suture button screw tract: case report. *Am J Sports Med.* 2011;39(3):645–8. [DOI: 10.1177/0363546510384807] [PMID: 21098817]
- Bawady AH, Allam AS, Karamany M, Farag HS. Tight Rope versus Screw Fixation in Ankle Syndesmotic Injuries. *BMJF.* 2023;40(surgical issue):112–28. [DOI: 10.21608/bmfj.2022.20545.1183]
- Ræder BW, Figved W, Madsen JE, Frihagen F, Jacobsen SB, Andersen MR. Better outcome for suture button compared with single syndesmotic screw for syndesmosis injury: five-year results of a randomized controlled trial. *Bone Joint J.* 2020;102-B(2):212–9. [DOI: 10.1302/0301-620X.102B2.BJJ-2019-0692.R2] [PMID: 32009435]
- Migliorini F, Maffulli N, Cocconi F, Schäfer L, Bell A, Katusic D, et al. Better outcomes using suture button compared to screw fixation in talofibular syndesmotic injuries of the ankle: a level I evidence-based meta-analysis. *Arch Orthop Trauma Surg.* 2024;144(6):2641–53. [DOI: 10.1007/s00402-024-05354-x] [PMID: 38740648]
- Xu B, Wang S, Tan J, Chen W, Tang KL. Comparison of Suture Button and Syndesmotic Screw for Ankle Syndesmotic Injuries: A Meta-analysis of Randomized Controlled Trials. *Orthop J Sports Med.* 2023;11(1):23259671221127665. [DOI: 10.1177/23259671221127665] [PMID: 36636033]
- Doll J, Waizenegger S, Bruckner T, Schmidmaier G, Wolf SI, Fischer C. Differences in gait analysis and clinical outcome after TightRope® or screw fixation in acute syndesmosis rupture: study protocol for a prospective randomized pilot study. *Trials.* 2020;21(1):606. [DOI: 10.1186/s13063-020-04550-5] [PMID: 32616003]
- Alastuey-López D, Seral B, Pérez MA. Biomechanical evaluation of syndesmotic fixation techniques via finite element analysis: Screw vs. suture button. *Comput Methods Programs Biomed.* 2021;208:106272. [DOI: 10.1016/j.cmpb.2021.106272] [PMID: 34293494]
- Gräff P, Alanazi S, Alazzawi S, Weber-Spickschen S, Krettek C, Dratzidis A, et al. Screw fixation for syndesmotic injury is stronger and provides more contact area of the joint surface than TightRope®: A biomechanical study. *Technol Health Care.* 2020;28(5):533–9. [DOI: 10.3233/THC-191638] [PMID: 32280069]
- Lehtola R, Leskelä HV, Flinkkilä T, Pakarinen H, Niinimäki J, Savola O, et al. Suture button versus syndesmosis screw fixation in pronation-external rotation ankle fractures: A minimum 6-year follow-up of a randomised controlled trial. *Injury.* 2021;52(10):3143–9. [DOI: 10.1016/j.injury.2021.06.025] [PMID: 34246483]
- Liu J, Pathak G, Joshi M, Andrews K, Lee J. A meta-analysis comparing the outcomes of syndesmotic injury treated with metal screw, dynamic fixation, and bioabsorbable screw. *J Orthop.* 2021;25:82–7. [DOI: 10.1016/j.jor.2021.04.006] [PMID: 33994703]
- Onggo JR, Nambiar M, Phan K, Hickey B, Ambikaipalan A, Hau R, et al. Suture button versus syndesmosis screw constructs for acute ankle diastasis injuries: A meta-analysis and systematic review of randomised controlled trials. *Foot Ankle Surg.* 2020;26(1):54–60. [DOI: 10.1016/j.fas.2018.11.008] [PMID: 30503612]
- Ræder BW, Figved W, Madsen JE, Frihagen F, Jacobsen SB, Andersen MR. Better outcome for suture button compared with single syndesmotic screw for syndesmosis injury: five-year results of a randomized controlled trial. *Bone Joint J.* 2020;102-B(2):212–9. [DOI: 10.1302/0301-620X.102B2.BJJ-2019-0692.R2] [PMID: 32009435]
- Ræder BW, Stake IK, Madsen JE, Frihagen F, Jacobsen SB, Andersen MR, et al. Randomized trial comparing suture button with single 3.5 mm syndesmotic screw for ankle syndesmosis injury: similar results at 2 years. *Acta Orthop.* 2020;91(6):770–5. [DOI: 10.1080/17453674.2020.1818175] [PMID: 32907456]
- Xu K, Zhang J, Zhang P, Liang Y, Hu JL, Wang X, et al. Comparison of suture-button versus syndesmotic screw in the treatment of distal tibiofibular syndesmosis injury: A meta-analysis. *J Foot Ankle Surg.* 2021;60(3):555–66. [DOI: 10.1053/j.jfas.2020.08.005] [PMID: 33518505]
- Mehta SS, Rees K, Cutler L, Mangwani J. Understanding risks and complications in the management of ankle fractures. *Indian J Orthop.* 2014;48(5):445–52. [DOI: 10.4103/0019-5413.139829] [PMID: 25298549]
- Gougoulias N, Oshba H, Dimitroulias A, Sakellariou A, Wee A. Ankle fractures in diabetic patients. *EFORT Open Rev.* 2020;5(8):457–63. [DOI: 10.1302/2058-5241.5.200025] [PMID: 32953131]
- Schmidt T, Simske NM, Audet MA, Benedick A, Kim CY, Vallier HA. Effects of Diabetes Mellitus on Functional Outcomes and Complications After Torsional Ankle Fracture. *J Am Acad Orthop Surg.* 2020;28(16):661–70. [DOI: 10.5435/JAAOS-D-19-00545] [PMID: 32769721]

Функционални резултати пацијената са повредом синдесмозе скочног зглоба лечених динамичком фиксацијом (*tight-rope*) у поређењу са ригидном фиксацијом

Филип Маљковић¹, Немања Славковић^{1,2}, Желимир Јовановић¹, Немања Јовановић¹, Ведрана Павловић^{2,3}, Бранислав Кривокапић^{1,2}

¹Институт за ортопедију „Бањица“, Београд, Србија;

²Универзитет у Београду, Медицински факултет, Београд, Србија;

³Институт за статистику и информатику, Београд, Србија

САЖЕТАК

Увод/Циљ Уганућа чине 85% свих повреда скочног зглоба. Синдесмотске повреде се јављају код 1–18% пацијената са уганућем скочног зглоба и чешће су у контактним спортовима који укључују форсирану дорзифлексију стопала.

Методe У нашој студији поредили смо 30 пацијената који су лечени динамичком фиксацијом због акутне синдесмотске повреде са пацијентима који су лечени ригидном фиксацијом. Критеријуми за поређење били су: скор Америчког удружења за стопало и скочни зглоб, визуелна аналогна скала, упитник *EuroQol* са пет димензија, опсег покрета, компликације и реоперације.

Резултати Средња вредност скорa Америчког удружења за стопало и скочни зглоб за пацијенте третиране ригидном фиксацијом била је 88,6, док је средња вредност за пацијенте третиране динамичком фиксацијом била 91,6. Средња вредност визуелне аналогне скале била је 83,5 код

ригидне фиксације, док је код динамичке фиксације била 85,8. Инфекција као компликација ригидне фиксације била је присутна код два пацијента (11,8%), док је код динамичке фиксације нисмо имали. Потребу за уклањањем имплантата имали смо код два пацијента лечена ригидном фиксацијом (11,8%) и код једног пацијента леченог динамичком фиксацијом (7,7%).

Закључак На основу наших резултата и резултата наведених аутора, показали смо да је мања инциденца проблема везаних за имплантате и потреба за њиховим уклањањем код динамичке фиксације. Резултати скорa Америчког удружења за стопало и скочни зглоб показали су бољи и бржи опоравак код динамичке фиксације.

Кључне речи: повреде синдесмозе; динамичка фиксација; ригидна фиксација; скор Америчког удружења за стопало и скочни зглоб