

CASE REPORT / ПРИКАЗ БОЛЕСНИКА

Torsion of the undescended testis in a healthy adult male

Ivan Levakov, Stevan Stojanović, Jovo Bogdanović, Dimitrije Jeremić, Saša Vojinov

Clinical Center of Vojvodina, Clinic of Urology, Novi Sad, Serbia;
University of Novi Sad, Faculty of Medicine, Novi Sad, Serbia**SUMMARY****Introduction** Torsion of undescended testis (UDT) in adults is rare, with only several published cases so far, and represents a urological emergency.**Case outlines** We present a case of UDT torsion in 31-year-old, otherwise healthy, man who had right-side inguinal pain for six hours before he was admitted to hospital. Swelling was palpable in the area of the right groin region. The diagnosis was established based on Doppler ultrasound and exploratory surgery findings. A right-sided orchiectomy was performed. According to the available data, there are no published cases on this topic in the region.**Conclusion** Although torsion of the UDT is a rare condition, it must be considered when symptoms of abdominal pain or swelling and pain in the groin region occur. Orchiectomy is suggested.**Keywords:** UDT; torsion; orchiectomy**INTRODUCTION**

Testicular torsion represents a urological emergency. Torsion of an undescended testis (UDT) is unlikely after the first year of life, with only several reports in adults. Orchiectomy is suggested, especially in adult cases. In this article, we present a case of undescended testis torsion in a 31-year-old, otherwise healthy adult.

CASE REPORT

A 31-year-old patient was presented to the Emergency Center due to a sudden onset of pain in the right groin region that had lasted six hours before the patient's arrival at the hospital. He did not suffer from any acute or chronic diseases. The family history was negative for congenital deformities and defects. The patient reported having two healthy children.

A clinical examination revealed a tender palpable mass in the right groin. The skin above mass was without signs of redness and elevated temperature (Figure 1). The right testicle was not palpable in the scrotum. Doppler ultrasonography of the scrotum, testicles, and abdomen revealed a hypoechoic ovoid mass in the right groin, measuring 2.7×1 cm, with no visible color Doppler signal. One enlarged lymph node measuring 1 cm was identified in the immediate vicinity of the hypoechoic mass.

Laboratory findings were normal, except slightly elevated white blood cells count ($12.2 \times 10^9/L$) and blood glucose 6.6 mmol/L (NV 4–5.9 mmol/L). Tumor markers serum levels were within range limits.

Based on the clinical examination and additional diagnostics mentioned above, immediate surgical exploration was indicated. The right groin was exposed through inguinal incision (Figure 2). The hypotrophic right side cryptorchid testicle was livid due to a 180° torsion of the seminal cord. A right-sided orchiectomy was performed. Cefuroxime 2 g / 24 hours i.v., nadroparin calcium 0.3 ml / 24 hours s.c., pantoprazole 40 mg / 24 h p.o., as well as symptomatic analgesic therapy, were administered during the postoperative course. The patient was discharged on postoperative day 2. The pathohistological examination confirmed hemorrhagic infarction of the testicle, suggesting testicular torsion.

All procedures performed involving human participants were in accordance with the ethical standards of the institutional and/or national research committee and with the 1964 Helsinki declaration and its later amendments or comparable ethical standards. Written consent to publish all shown material was obtained from the patient.

DISCUSSION

Testicular torsion is one of the most common urological emergencies, which is misdiagnosed in 20% of cases among adults [1, 2]. The incidence of UDT torsion is unknown [3]. UDT torsion can mimic acute abdomen, strangulated inguinal hernia, and inguinal lymphadenitis [2, 4]. Generally, 70% of UDT are palpable. Non-palpable testicles can be found in the inguinal-scrotal area in 30% and 55% of cases, respectively. Vanishing or absent

Received • Примљено:
April 3, 2024**Revised • Ревизија:**
October 25, 2024**Accepted • Прихваћено:**
November 14, 2024**Online first:** November 15, 2024**Correspondence to:**Stevan STOJANOVIĆ
Clinic of Urology
Clinical Center of Vojvodina
21000 Novi Sad
Serbiastevan.stojanovic@mf.uns.ac.rs



Figure 1. A clinical inspection – swell of the right groin region

testicle is found in 15% of patients [5, 6]. Both testicles are absent in 3–5% of cases [7]. Mechanism of UDT torsion is unclear, with two possible theories proposed. The first theory proposes that abnormal contractions or spasms of the cremasteric muscles cause spermatic cord torsion, as in patients with spastic neuromuscular diseases [4, 8, 9]. The second theory proposes that the size of the undescended testis is associated with the risk of UDT torsion, as in association with testicular tumors [4, 10, 11].

The clinical symptoms of UDT torsion are nonspecific, including abdominal and groin pain, sometimes vomiting and poor oral intake [4].

Ultrasound with color Doppler is the most common imaging modality [12]. CT, MRI, and scintigraphy are

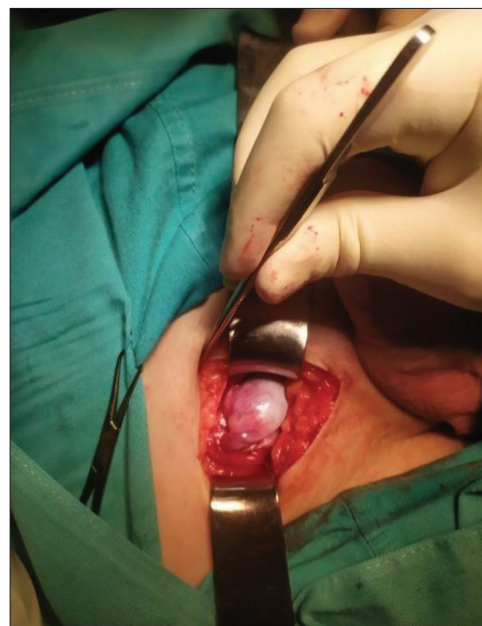


Figure 2. Surgical exploration of the right inguinal region – inguinal approach

not widely used [12, 7]. One of three cases treated with exploration-detorsion resulted in testicular ischemia [13]. Orchiectomy is suggested, especially in adult cases, since salvage rates in UDT are less than 10% [4].

In adults, even as a rare occasion, UDT torsion could be the cause of sudden abdominal pain, swelling, nausea, and vomiting. Proper history, physical examination of scrotum following ultrasound examination is to be performed in every case of UDT. Surgical exploration is obligatory. Orchiectomy is suggested, especially in adult cases having normal contralateral testicle.

Conflict of interest: None declared.

REFERENCES

- Dang VT, Pradere B, de Varennes AM, Benali NA, Vallée M, Berchiche W, et al. Torsion of the spermatic cord in adults: a multicenter experience in adults with surgical exploration for acute scrotal pain with suspected testicular torsion. *Asian J Androl.* 2022;24(6):575–8. [DOI: 10.4103/aja2021126] [PMID: 35322657]
- Shin J, Jeon GW. Comparison of diagnostic and treatment guidelines for undescended testis. *Clin Exp Pediatr.* 2020;63(11):415–21. [DOI: 10.3345/cep.2019.01438] [PMID: 32252147]
- Zhong HJ, Tang LF, Bi YL. Cryptorchid testicular torsion in children: characteristics and treatment outcomes. *Asian J Androl.* 2021;23(5):468–71. [DOI: 10.4103/aja.aja_10_21] [PMID: 33723095]
- Siraj QH. Functional Imaging of Testicular Torsion. *Semin Nucl Med.* 2023;53(6):797–808. [DOI: 10.1053/j.semnuclmed.2023.04.005] [PMID: 37210316]
- Reed B, Banerjee R, Tsampoukas G, Gray R. Testicular torsion in an undescended testicle: chasing a diagnosis. *J Surg Case Rep.* 2022;2022(6):rjac263. [DOI: 10.1093/jscr/rjac263] [PMID: 35721261]
- Karavdic K. Laparoscopic management of non-palpable testis. *SEES Journal.* 2023;2(2):146–56. [DOI: 10.55791/ymxag947]
- Sondermann M, Menzel V, Borkowetz A, Baunacke M, Huber J, Eisenmenger N, et al. Treatment trends for undescended testis and impact of guideline changes a medical health care analysis of orchidopexy and cryptorchidism in Germany between 2006 und 2020. *World J Urol.* 2024;42(1):386. [DOI: 10.1007/s00345-024-05095-x] [PMID: 38918219]
- Ali K, Ouaddane Alami R, Malki MA, Ahsaini M, Mellas S, El Ammari J, et al. A spontaneous acute abdomen revealing testicular torsion of an undescended testicle. *WJARR.* 2024;21(03):2356–9. [DOI: 10.30574/wjarr.2024.21.3.0840]
- Alshaibani LK, Alshaibani SK. Testicular Torsion in the Undescended Testis of a Four-Year-Old: A Delayed Diagnosis. *Cureus.* 2024;16(1):e51664. [DOI: 10.7759/cureus.51664] [PMID: 38313930]
- Alturaiki ZA, Alnasser AA, Alabandi AM. A Case of Testicular Tumor Presenting as Acute Scrotum. *Cureus.* 2023;15(8):e44185. [DOI: 10.7759/cureus.44185] [PMID: 37767253]
- Alsaffaf Y, Arab H, Jaafar J, Shehadeh M. A 7-year-old with extravaginal torsion of an undescended testicle in the left inguinal region: The first case report from Syria. *Clin Case Rep.* 2024;12(6):e9013. [DOI: 10.1002/ccr3.9013] [PMID: 38808196]
- Ilyas F, Aslam M, Ali S, Nazir MI. Torsion of a cryptorchidism testicle in a toddler. *UTJ.* 2024;8(1):6–8. [DOI: 10.31491/UTJ.2024.03.017]
- Kargl S, Haid B. Torsion of an undescended testis – A surgical pediatric emergency. *J Pediatr Surg.* 2020;55(4):660–4. [DOI: 10.1016/j.jpedsurg.2019.06.018] [PMID: 31272681]

Торзија неспушеног тестиса код здравог одраслог мушкарца

Иван Леваков, Стеван Стојановић, Јово Богдановић, Димитрије Јеремић, Саша Војинов

Клинички центар Војводине, Клиника за урологију, Нови Сад, Србија;
Универзитет у Новом Саду, Медицински факултет, Нови Сад, Србија

САЖЕТАК

Увод Торзија неспушеног тестиса код одраслих је ретка, са само неколико објављених случајева до сада, и представља ургентно стање у урологији.

Приказ болесника Приказујемо случај торзије неспушеног тестиса код здравог мушкарца старог 31 годину, који је примљен у болницу због десностраног ингвиналног бола који је трајао шест сати пред пријем. Била је присутна палпабилна тумефакција у пределу десне препонске регије. Дијагноза је

постављена уз помоћ доплер ултразвука и експлоративне хирургије. Начињена је деснострана орхиектомија. Према доступним подацима, до сада није било објављених случајева на ову тему у региону.

Закључак Иако је торзија неспушеног тестиса изузетно ретко стање код одраслих, мора се имати у виду када се јаве симптоми абдоминалног бола или отицање и бол препонске регије. Орхиектомија је метода избора.

Кључне речи: неспушени тестис; торзија; орхиектомија