

CASE REPORT / ПРИКАЗ БОЛЕСНИКА

En bloc kidney transplantation of an infant to an adolescent girl – one-year follow-up



Mirjana Cvetković^{1,2}, Ana Petrović¹, Vladimir Radlović^{1,2}, Ivana Gojković¹, Brankica Spasojević^{1,2}

¹University Children's Hospital, Belgrade, Serbia;

²University of Belgrade, Faculty of Medicine, Belgrade, Serbia

SUMMARY

Introduction *En bloc* kidney transplantation (EBKT) overcomes the problems of insufficient nephron mass of the solitary kidney of the youngest donors and the creation of a vascular anastomosis with small blood vessels. Although there are positive experiences with EBKT in adult patients, there is little data in pediatric recipients.

Case outline The kidney donor was a six-month-old male infant (7 kg), and the recipient was a 16-year-old adolescent girl (58.7 kg). The estimated glomerular filtration rate increased during the one-year follow-up after EBKT and reached 88.8 ml/min/1.73 m², which was accompanied by an increase in the dimensions of the medial and lateral kidneys. Normalization of proteinuria and tubular functions occurred six and 12 months after transplantation, respectively.

Conclusion EBKT in an adolescent girl was performed without vascular complications, with satisfactory kidney function and physiological values of proteinuria after a one-year follow-up. EBKT of infants could increase the number of cadaveric donors but also enable better function and survival of the graft, given that the growth and functional maturation of the infant's kidneys continue postnatally in the body of the graft recipient.

Keywords: *en bloc* kidney transplantation; small infant donor; pediatric recipient; postnatal kidney maturity

INTRODUCTION

Kidney transplantation is the gold standard for renal replacement therapy in children [1]. Although pediatric recipients have priority in the allocation of cadaveric grafts [2], the number of pediatric cadaveric transplants is low primarily due to the small number of quality cadaveric grafts. By changing the demographic characteristics of adult cadaveric donors after brain death (older age, higher body mass index, comorbidities such as hypertension and diabetes), the quality of the cadaveric graft worsened [3]. Having in mind that every pediatric patient with end-stage renal disease needs at least two to three kidney transplants for an average life span, the importance of long-term survival of the transplanted kidney is clear, from which it follows that borderline donors are not the best solution for them. *En bloc* kidney transplantation (EBKT) implies transplanting both kidneys in a pair together with part of the aorta and inferior vena cava, which overcomes the problems of insufficient nephron mass of the solitary kidney of the youngest donors and the creation of a vascular anastomosis with small blood vessels [4]. Application of this transplantation method is one way to increase the donor pool of quality grafts for pediatric patients [5–8]. There are numerous positive experiences with EBKT in adult patients [3, 9–13]. However, there are few studies related

to the outcome of EBKT in pediatric recipients, especially if the graft donor was an infant [5, 7, 8, 14, 15]. The aim of our work is to present the one-year clinical course of EBKT of a six-month-old infant to an adolescent girl.

CASE REPORT

The kidney donor was a six-month-old infant (7 kg), whose cause of death was a ventricular arrhythmia caused by a fetal rhabdomyoma of the heart. The recipient of the kidney was a 16-year-old girl (58.7 kg), with a congenital anomaly of the urinary tract. At the age of 12.5 years the girl was referred to a nephrologist for the first time, due to unrecognized advanced chronic kidney disease. She was on chronic hemodialysis from the age of 13.5 years, until transplantation. EBKT was performed by creating a venous T-L anastomosis between the external iliac vein of the recipient and inferior vena cava of the donor, and the arterial anastomosis was created between the external iliac artery of the recipient and the aorta of the donor (Figure 1). Cold ischemia lasted 6 hours and 35 minutes, and warm ischemia 52 minutes. Immunosuppressive therapy with basiliximab, corticosteroids, tacrolimus and mycophenolate mofetil was administered. Due to delayed graft function, the patient required three hemodialysis sessions. The urinary catheter, clogged

Received • Примљено:

May 30, 2024

Accepted • Прихваћено:

July 15, 2024

Online first: July 16, 2024

Correspondence to:

Mirjana CVETKOVIĆ
Tiršova 10
11000 Belgrade, Serbia
mirjanacvetkovic@yahoo.com

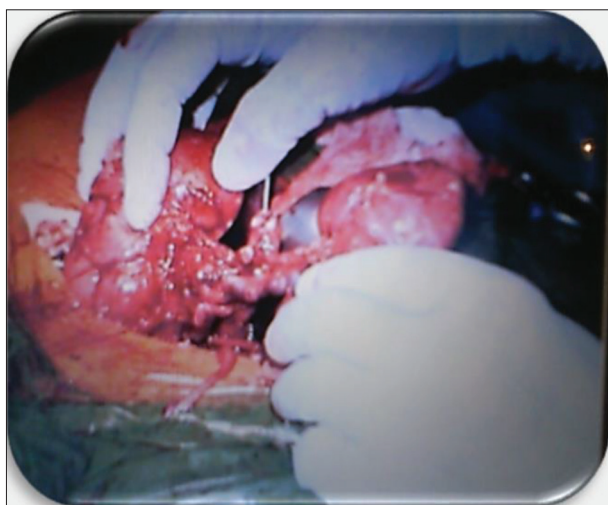

Figure 1. Kidneys transplanted using the *en bloc* surgical technique, after the creation of vascular anastomoses and established reperfusion




Figure 2. Spontaneously voided coagulums from the urinary bladder after removal of the urinary catheter on the eighth post-transplantation day

by a large coagulum, was removed on the eighth post-transplantation day, after which the patient spontaneously passed out several more coagulums (Figure 2). On the 10th post-transplantation day, a perirenal collection was verified by ultrasound, positioned in front of both transplanted kidneys and ureters, which progressively increased, and on the 17th post-transplantation day its dimensions were $97 \times 61 \times 25$ mm. Due to compression on the venous flow in the lateral kidney, two months after transplantation, drainage of this perirenal collection was performed. Cytological and biochemical findings indicated a lymphocele. Recurrent lymphocele was treated by laparoscopic fenestration at the end of the third post-transplantation month. During the second post-transplantation month, the clinical course was complicated by cytomegalovirus disease, treated with valganciclovir, human cytomegalovirus immunoglobulin, and immunosuppressive therapy reduction. In the fourth post-transplantation month, the patient was diagnosed with SARS-CoV2-infection, which was successfully treated with immunosuppression therapy reduction and supportive therapy. None of the listed complications affected the functional maturation of the grafts (Table 1). The estimated glomerular filtration rate (eGFR) during the one-year follow-up increased, which was accompanied by an increase in the dimensions of the medial

and lateral kidney, measured by ultrasound. Normalization of proteinuria occurred six months after transplantation. Tubular functions reached physiological values one year after transplantation.

The authors declare that the article was written according to ethical standards of the Serbian Archives of Medicine as well as ethical standards of medical facilities for each author involved. No personal data of the patient were presented in the manuscript. Written consent was obtained from the patient and her parent.

DISCUSSION

Survival, growth, cognitive development and quality of life of transplanted children are incomparably better and morbidity rate is lower, compared to children on dialysis [1]. Pediatric patients on dialysis have a 78% higher risk of cardiovascular death compared to age-matched transplanted patients [16]. Furthermore, early transplantation in children limits the accumulation of cardiovascular risk such as intima-media thickness, marker of atherosclerosis, which increases in children on dialysis over time, and remains stable for years after kidney transplantation [17]. Worldwide there is a growing discrepancy between the number of available cadaveric grafts and the number of potential recipients, which is the cause of longer waiting time for a cadaveric kidney [7]. Also, with changing the demographic characteristics of adult cadaveric donors, the number of borderline donors increased [3]; however, they are not a good option for pediatric patients due to the extreme importance of long-term graft survival in this population. Therefore, the importance of increasing the donor pool of organs for child transplantation is clear, and EBKT is one of the possible solutions to this problem [8, 18]. Furthermore, children who receive a kidney from a pediatric donor have a better long-term graft outcome compared to children who receive a kidney from an adult donor [19]. EBKT remains a challenge for surgeons, given that it is accompanied by a higher frequency of vascular and urological complications [18]. A good selection of donors and recipients, improvement of surgical technique, shorter cold ischemia time, better immunosuppressive therapy, as well as postoperative anticoagulation and antiplatelet therapy, contributed to a significant reduction in the rate of these complications [4, 7, 8, 12, 13]. Regarding early post-operative complications, our patient had large coagulums in the urinary bladder (Figure 2) and perirenal lymphocele, which was successfully treated by laparoscopic fenestration.

Utilization of very small pediatric donor kidneys can provoke hyperfiltration injury, but careful recipient selection and EBKT technique (doubling the nephron mass) with adequate follow-up of transplanted patients, successfully overcomes this problem, and provides similar graft survival in comparison with adult deceased donor or even

Table 1. Functional maturation and growth of infant kidneys transplanted in pair

Parameters	Months after EBKT				
	1	3	6	9	12
eGFR (ml/min/1.73 m ²)	26.1	46.2	68.6	77.2	88.8
Medial kidney size (mm)	68 × 35	86 × 38	95 × 34	95 × 42	102 × 44
Lateral kidney size (mm)	64 × 41	76 × 44	91 × 44	100 × 44	105 × 49
Tubular functions (%)	FeNa 5.5 FeK 46.7 TRP 53		FeNa 2.47 FeK 18.9 TRP 74.2		FeNa 1.96 FeK 12.01 TRP 84.3
Urine protein creatinine ratio (UPCR) (mg/mg)	1.27		0.21		0.14

EBKT – en bloc kidney transplantation; eGFR – estimated glomerular filtration rate; FeNa – fractional excretion of sodium; FeK – fractional excretion of potassium; TRP – tubular reabsorption of phosphate; UPCR – urine protein creatinine ratio

living donor kidneys [4, 7, 11]. One year after transplantation, our patient had eGFR 88.8 ml/min/1.73 m² with normal proteinuria values, which points against hyperfiltration damage of EBKT.

The newborn kidney differs from the mature kidney anatomically, histologically and functionally. The GFR of a term newborn is low and after birth it continuously increases. Functional maturation of the nephron is completed by the end of the second year of life [20]. In case the kidney donor is an infant, the functional maturation and growth of the infant kidneys continue in the body of the graft recipient [4, 8, 21]. Table 1 clearly shows the functional maturation of nephrons and the growth of infant kidneys transplanted in a pair to the adolescent girl.

Numerous studies have shown the excellent outcome of EBKT of small pediatric kidneys in adult graft recipients in terms of graft function and survival [4, 11, 12, 22]. Recently published follow-up results (mean follow-up of 65 months, range 7–220 months) of adult patients after EBKT indicated excellent results: 100% patient survival and creatinine clearance which increased during the first three years before reaching stabilization (at 10 years, the mean creatinine clearance was 112 ml/minute, 95% confidence interval 107–117) [4]. During the last year, two EBKT to adults from preterm neonate donors after circulatory death (< 30 weeks gestation and weight < 1.2 kg) with acceptable results five and nine months post-surgery have been described in the literature [23]. On the other hand, a low percentage of EBKT was performed in pediatric recipients [7]. This is why there is a small number of studies assessing the long-term survival of grafts transplanted with this surgical technique in pediatric graft recipients. However, the experience of individual centers indicates promising

results [5, 7, 8, 14, 15]. Yaffe HC et al. [14] and Winnicki et al. [7] compared pediatric recipients with grafts from small pediatric donors and pediatric recipients with grafts from standard donors, and showed that the one-year survival of grafts was slightly poorer in the group of recipients of small pediatric grafts, but five years after transplantation the outcome was practically the same. Chesnaye et al. [15] analyzed the five-year graft survival of small pediatric donors under five years of age who were transplanted into pediatric recipients. They divided the recipients according to age into four groups (0–3 years, 4–5 years, 6–11 years, and 12–19 years) and showed that the five-year graft survival was

70%, 75%, 81%, and 83%, respectively. This year, Azzam et al. [8] published the results of a follow-up (mean duration 6.86 ± 1.35 years) of pediatric patients after EBKT from donors with body weight < 15 kg and showed excellent renal function outcome on the last follow-up (eGFR 79.8 ± 30.8 ml/min/1.73 m²). The outcome of EBKT of infant kidneys in our adolescent girl one year after the transplant was excellent, despite numerous complications in the first four months after the surgical intervention. EBKT from infants could increase the number of cadaveric donors, as well as the quality grafts for pediatric recipients, and also could enable better function and survival of the graft given that the growth and functional maturation of the infant kidneys continue postnatally. We should not hesitate to use this potential pool of donors because the data in the literature is truly positive and encouraging. Certainly, in the future, multicenter studies are necessary, considering the small number of pediatric patients transplanted with this technique per center, which will show us the long-term outcome (> 10 years) of grafts transplanted with the *en bloc* surgical technique in the youngest patients.

ACKNOWLEDGEMENT

The authors would like to express their gratitude to their teachers, Prof. Dr. Amira Peco-Antić, Prof. Dr. Zoran Krstić, and Prof. Dr. Mirjana Kostić, for their significant contribution to the development and improvement of pediatric kidney transplantation at the University Children's Hospital.

Conflict of interest: None declared.

REFERENCES

- Fernandez HE, Foster BJ. Long-Term Care of the Pediatric Kidney Transplant Recipient. *Clin J Am Soc Nephrol.* 2022;17(2):296–304. [DOI: 10.2215/CJN.16891020] [PMID: 33980614]
- Engen RM, Smith JM, Bartosh SM. The kidney allocation system and pediatric transplantation at 5 years. *Pediatr Transplant.* 2022;26(7):e14369. [DOI: 10.1111/ptr.14369] [PMID: 35919967]
- Alshahrani M, Alotaibi M, Bhutto B. Assessing the Outcome of Adult Kidney Transplantation from a Deceased Expanded Criteria Donor: A Descriptive Study. *Cureus.* 2020;12(10):e11199. [DOI: 10.7759/cureus.11199] [PMID: 33269130]
- Seizilles de Mazancourt E, Badet L, Codas Duarte R, Morelon E, Crouzet S, Terrier N, et al. En Bloc Kidney Transplantation: A Retrospective Study of an 18-year Experience in a Single Institution. *Eur Urol Open Sci.* 2022;46:137–44. [DOI: 10.1016/j.euro.2022.10.012] [PMID: 36506250]
- Kizilbash SJ, Evans MD, Chinnakotla S, Chavers BM. Survival Benefit of En Bloc Transplantation of Small Pediatric Kidneys in Children. *Transplantation.* 2020;104(11):2435–43. [DOI: 10.1097/TP.0000000000003158] [PMID: 32022736]

6. Zhao WY, Zhang L, Zhu YH, Chen Y, Zhu FY, Shen Q, et al. En bloc kidneys transplanted from infant donors less than 5 kg into pediatric recipients. *Transplantation*. 2014;97(5):555–8. [DOI: 10.1097/01.tp.0000437174.55798.0b] [PMID: 24162253]
7. Winnicki E, Dharmar M, Tancredi D, Butani L. Comparable Survival of En Bloc versus Standard Donor Kidney Transplants in Children. *J Pediatr*. 2016;173:169–74. [DOI: 10.1016/j.jpeds.2016.01.054] [PMID: 26898807]
8. Azzam A, Tawfeeq M, Obeid M, Khan I, Almaghrabi M, AlQahtani M, et al. Pediatric en bloc kidney transplant from donors <15 kg: An excellent approach to expand the pediatric deceased donor pool. *Pediatr Transplant*. 2024;28(3):e14715. [DOI: 10.1111/ptr.14715] [PMID: 38553805]
9. Dave RV, Hakeem AR, Dawrant MJ, Ecuyer CL, Lewington AJ, Attia MS, et al. Renal Transplantation from Pediatric Donors in the United Kingdom. *Transplantation*. 2015;99(9):1968–75. [DOI: 10.1097/TP.0000000000000575] [PMID: 25651310]
10. Bhayana S, Kuo YF, Madan P, Mandaym S, Thomas PG, Lappin JA, et al. Pediatric en bloc kidney transplantation to adult recipients: more than suboptimal? *Transplantation*. 2010;90(3):248–54. [DOI: 10.1097/TP.0b013e3181e641f8] [PMID: 20548262]
11. Spaggiari M, Petrochenkov E, Patel H, Di Cocco P, Almario-Alvarez J, Fratti A, et al. Donor Size Doesn't Impact En Bloc Kidney Transplant Outcomes: A Single-Center Experience and Review of Literature. *Transpl Int*. 2022;35:10731. [DOI: 10.3389/ti.2022.10731] Erratum in: *Transpl Int*. 2022;35:10982. [PMID: 36311258]
12. López-González JA, Beamud-Cortés M, Bermell-Marco L, Pérez-Martínez MA, Cuenca-Ramírez MD, Moratalla-Charcos LM, et al. A 20-year experience in cadaveric pediatric en bloc kidney transplantation in adult recipients. *Actas Urol Esp (Engl Ed)*. 2022;46(2):85–91. English, Spanish. [DOI: 10.1016/j.acuroe.2021.09.003] [PMID: 35184988]
13. Yagisawa T, Kanzawa T, Hirai T, Unagami K, Shirai Y, Ishizuka K, et al. En bloc kidney transplantation from pediatric donors to teenage recipients: Two case reports. *IJU Case Rep*. 2023;7(2):136–40. [DOI: 10.1002/iju5.12686] [PMID: 38440719]
14. Yaffe HC, Friedmann P, Kayler LK. Very small pediatric donor kidney transplantation in pediatric recipients. *Pediatr Transplant*. 2017;21(5). [DOI: 10.1111/ptr.12924] [PMID: 28397368]
15. Chesnaye NC, van Stralen KJ, Bonthuis M, Groothoff JW, Harambat J, Schaefer F, et al. The association of donor and recipient age with graft survival in paediatric renal transplant recipients in a European Society for Paediatric Nephrology/European Renal Association-European Dialysis and Transplantation Association Registry study. *Nephrol Dial Transplant*. 2017;32(11):1949–56. [DOI: 10.1093/ndt/gfx261] [PMID: 28992338]
16. Parekh RS, Carroll CE, Wolfe RA, Port FK. Cardiovascular mortality in children and young adults with end-stage kidney disease. *J Pediatr*. 2002;141(2):191–7. [DOI: 10.1067/mpd.2002.125910] [PMID: 12183713]
17. Grabitz C, Sugianto RI, Doyon A, Azukaitis K, Anarat A, Bacchetta J, et al. 4C Study Consortium. Long-term Effects of Kidney Transplantation Compared With Dialysis on Intima-media Thickness in Children-Results From the 4C-T Study. *Transplantation*. 2024;108(5):1212–9. [DOI: 10.1097/TP.0000000000004881] [PMID: 38227773]
18. Damji S, Callaghan CJ, Loukopoulos I, Kessar N, Stojanovic J, Marks SD, et al. Utilisation of small paediatric donor kidneys for transplantation. *Pediatr Nephrol*. 2019;34(10):1717–26. [DOI: 10.1007/s00467-018-4073-5] [PMID: 30238149]
19. Pape L, Hoppe J, Becker T, Ehrich JH, Neipp M, Ahlenstiel T, et al. Superior long-term graft function and better growth of grafts in children receiving kidneys from paediatric compared with adult donors. *Nephrol Dial Transplant*. 2006;21(9):2596–600. [DOI: 10.1093/ndt/gfl119] [PMID: 16861725]
20. Hsu CN, Tain YL. The First Thousand Days: Kidney Health and Beyond. *Healthcare (Basel)*. 2021;9(10):1332. [DOI: 10.3390/healthcare9101332] [PMID: 34683012]
21. Hirukawa T, Suzuki H, Niimura F, Fukagawa M, Kakuta T. En Bloc Cadaver Kidney Transplantation From a 9-Month-Old Donor to an Adult Recipient: Maturation of Glomerular Size and Podocyte in the Recipient. *Transplant Direct*. 2017;3(3):e130. [DOI: 10.1097/TXD.0000000000000648] [PMID: 28361114]
22. Chen C, Su X, Wu C, Liu L, Zhang H, Deng R, et al. Successful single kidney transplantation from pediatric donors less than or equal to 10 kg to adult recipient: a retrospective cohort study. *Transl Pediatr*. 2021;10(6):1618–29. [DOI: 10.21037/tp-21-23] [PMID: 34295776]
23. Li D, Wu H, Chen R, Zhong C, Zhuang S, Zhao J, et al. The minimum weight and age of kidney donors: en bloc kidney transplantation from preterm neonatal donors weighing less than 1.2 kg to adult recipients. *Am J Transplant*. 2023;23(8):1264–7. [DOI: 10.1016/j.ajt.2022.11.023] [PMID: 36695695]

En bloc трансплантација бубрега одојчета адолесценткињи – једногодишње праћење

Мирјана Цветковић^{1,2}, Ана Петровић¹, Владимир Радловић^{1,2}, Ивана Гојковић¹, Бранкица Спасојевић^{1,2}

¹Универзитетска дечја клиника, Београд, Србија;

²Универзитет у Београду, Медицински факултет, Београд, Србија

САЖЕТАК

Увод Трансплантацијом бубрега у блоку (*en bloc*) (ЕБТБ) превазилазе се проблеми недовољне нефронске масе солитарног бубрега најмлађих донора и креирања васкуларне анастомозе са малим крвним судовима. Иако постоје позитивна искуства са ЕБТБ код одраслих болесника, мало је података код педијатријских прималаца.

Приказ болесника Донор бубрега било је шестомесечно мушко одојче (7 kg), а прималац адолесценткиња узраста 16 година (58,7 kg). Процењена јачина гломерулске филтрације током једногодишњег праћења после ЕБТБ је расла и достигла 88,8 ml/min/1,73 m², што је праћено порастом димензија медијалног и латералног бубрега. Нормализација протеи-

нурије постигнута је шест месеци после трансплантације, а тубулских функција после 12 месеци.

Закључак ЕБТБ код адолесценткиње је протекла без васкуларних компликација, са задовољавајућом функцијом бубрега и физиолошким вредностима протеинурије после једногодишњег праћења. ЕБТБ одојчади могла би да повећа број кадаверичних донора, али и да омогући бољу функцију и преживљавање графта с обзиром на то да се раст и функционално sazревање одојчачких бубрега настављају постнатално и у телу примаоца графта.

Кључне речи: *en bloc* трансплантација бубрега; одојче донор бубрега; педијатријски прималац; постнатално sazревање бубрега