



ORIGINAL ARTICLE / ОРИГИНАЛНИ РАД

Evaluation of the success of the modified Vazirani–Akinosi technique in comparison to the standard Vazirani–Akinosi technique – a randomized clinical trial

Jovana Bakalović¹, Ljiljana Stojčev², Bojan Janjić², Bojan Gačić²

¹University of Belgrade, School of Dental Medicine, Belgrade, Serbia;

²University of Belgrade, School of Dental Medicine, Clinic for Oral surgery, Belgrade, Serbia

SUMMARY

Introduction/Objective The correct choice of local anesthesia should imply choosing the simplest technique, with maximum anesthesia and minimal discomfort for the patient. The objectives of this research were to determine the efficacy of the modified Vazirani–Akinosi technique (mVAt) in comparison to the standard one (VAt) and to compare the techniques regarding clinically relevant parameters.

Methods The research was conducted at the Clinic for Oral Surgery, School of Dental Medicine, University of Belgrade. A prospective, randomized, single-blinded clinical trial included 60 patients scheduled for surgical extraction of mandibular third molars. The first group of patients was anesthetized using mVAt, while the second group received anesthesia using VAt. Pain during injection, onset time, duration of anesthesia, and width of the anesthetized area were the evaluated parameters.

Results Out of 60 performed injections, 42 were successful, which proved to be statistically significant in comparison to 18 unsuccessful injections ($p = 0.047$). The failure rate of the buccal nerve (BN) anesthesia was statistically significantly lower in the mVAt group ($p = 0.030$). There was no statistically significant difference among the groups considering pain ($p = 0.114$), onset time ($p = 0.370$), and duration of anesthesia ($p = 0.628$).

Conclusion mVAt proved to be more successful regarding BN anesthesia. Considering other examined clinical parameters, both techniques showed similar performance.

Keywords: Vazirani–Akinosi technique; mandibular anesthesia; oral surgery

INTRODUCTION

Attaining complete numbness prior to every surgical procedure is imperative, which unequivocally indicates that local anesthesia is an essential part of everyday oral surgery practice. The correct choice of local anesthesia technique should consider the simplest technique to perform, with the maximum effect of anesthesia and minimal discomfort for the patient. Many surgical procedures in the mandible require anesthesia of the inferior alveolar nerve (IAN), lingual nerve (LN) and buccal nerve (BN). Frequent use in everyday clinical practice has led to the discovery and description of various techniques and their variations for achieving anesthesia of the nerves mentioned.

Pioneers in achieving inferior alveolar and lingual nerve block were surgeons, William S. Halstead and Richard J. Hall. Their discovery was based on the injection of cocaine solution near mandibular foramen, back in 1884 [1, 2]. Ever since, Halstead's technique of performing inferior alveolar nerve block has been considered a conventional method and is well known as conventional inferior alveolar nerve block (CIANB). This technique takes into consideration intraoral parameters to determine the place of needle insertion. After administration of the anesthetic solution, it provides anesthesia of the inferior alveolar and the lingual nerve.

However, the success of the conventional technique requires not only the dentist's experience but also a high level of cooperation with the patient [1, 2]. Since patients usually face fear of both the procedure and anesthesia, the contemporary literature often states that the patient's overall impression of the doctor and the performed procedure is often and mostly determined by the success of anesthesia [3, 4].

The precision of determining the injection site vastly depends on the recognition of anatomical structures, which are prone to many variations among individuals. Edentulous patients with advanced bone resorption, patients with very strong cheek or tongue muscles, as well as large fat pads, are just some of the cases which may be encountered that can be more difficult to accurately determine the site of a needle insertion [1]. This extensively explains the data from the literature, indicating a relatively high failure rate of CIANB, from 15% to 25% [1, 5–12]. Frequent variability of the position, shape, and size of the mandibular foramen on the inner side of the mandibular ramus as well as the position and shape of the mandibular lingula may also contribute to the failure of CIANB [13]. Another factor which should be taken into consideration while applying this technique is the anteroposterior diameter of the ramus, and its divergence [14]. Collateral sensory innervation of mandibular teeth, which in some cases

Received • Примљено:
July 12, 2022

Revised • Ревизија:
March 2, 2023

Accepted • Прихваћено:
March 17, 2023

Online first: March 21, 2023

Correspondence to:

Correspondence to:
Bojan GAČIĆ
Clinic for Oral Surgery
Doktora Subotića 4
11000 Belgrade, Serbia
gacib67@gmail.com

may originate from the mylohyoid nerve, can also affect the unpredictable outcome of CIANB [8, 9, 15, 16]. In addition, this technique often shows positive aspiration, since the inferior alveolar nerve is in close proximity to the inferior alveolar artery [1, 2, 7, 15, 17, 18, 19]. The artery is usually positioned posteriorly or posterolaterally in relation to the nerve, entering mandibular foramen together [15, 20].

Intending to improve on the Halstead's technique, which had been acknowledged as conventional, alternative techniques, commonly but inaccurately called mandibular anesthesia, have been described, among them the Vazirani–Akinosi (VA) technique. Vazirani introduced this technique into dental practice in 1960, while Akinosi presented a similar technique to the academic community in 1977 [1, 10]. In order to pay homage to Vazirani, the technique is known as the Vazirani–Akinosi technique.

Presenting the technique, in his original paper Akinosi [14] pointed out the ease of administration, shorter onset time, compared to other thus far described techniques, as well as the lowest intensity of pain during the injection and anesthetic solution deposition. The VA method has been described as a closed-mouth technique, which is stated to be an advantage when performed in patients with limited mouth opening [21, 22]. As stated by Akinosi, due to the closed-mouth position, the patient is unlikely to become apprehensive during the injection. In addition, a completely different approach and area of needle insertion reduce the possibility of provoking gag reflex in sensitive patients [1]. Unlike the conventional technique, it is stated that a correctly performed VA technique anesthetizes all three nerves important for surgical interventions in the mandible with a single injection [14]. Thus, additional injection for the BN is avoided, therefore additional traumatization of the tissues and the patient himself.

The often-mentioned information about the possible failure of anesthesia of the BN with the VA technique was the incentive to design a modification of this technique [8, 19, 23, 24].

The objectives of this research were to determine the efficacy of the modified in comparison to the standard VA technique, in terms of anesthesia of all three aforementioned nerves, and to compare the techniques regarding clinically relevant parameters such as pain during the injection, onset time, and duration of anesthesia.

METHODS

The research was conducted at the Clinic for Oral Surgery, School of Dental Medicine, University of Belgrade, Serbia, after the approval of the Ethics Committee was obtained.

Sixty adult patients who had been scheduled for surgical extraction of the mandibular third molars were included. Prior to the inclusion, all the patients had been informed about the procedure and written consent of participation was signed.

All participants were classified according to the American Society of Anesthesiologists (ASA) physical status classification system as ASA I and ASA II. Pregnant and

breastfeeding women were excluded from the study, as well as patients who refused the consent to participate.

A prospective, randomized, single-blinded clinical trial was accomplished by patients randomly choosing number 1 or 2. Participants were allocated into two equal groups. The first group of patients was anesthetized using modified VA technique (mVAT), while the second, control group, was anesthetized using the standard VA technique (VAT).

All anesthetics were administered by the same doctor. The anesthetic of choice in all cases was 4% articaine (Septanest[®], Septodont, Saint-Maur-des-Fossés, France) with epinephrine (1:100,000), and the needle gauge was 27G.

Standard Vazirani–Akinosi technique

With the mouth slightly open, the doctor palpates the front edge of the ramus with his finger (forefinger or thumb), while simultaneously retracting the cheek outwards. Before the insertion of the needle, the patient closes teeth lightly. The horizontally placed syringe is directed backwards and laterally as much as the maxillary dental arch and the alveolar ridge of the upper jaw allow. The needle is placed parallel to the occlusal plane, and at the height of the marginal gingiva of the teeth in the upper jaw. The puncture site is located in the mucosal fold between the maxillary tuberosity and the medial side of the mandibular ramus. After the puncture, the needle is directed laterally and parallel to the inner side of the ramus and inserted into the pterygomandibular space to a depth of 25–30 mm, where the anesthetic is deposited.

Modified Vazirani–Akinosi technique

The anatomical guidelines used to determine the puncture site as well as the method of needle insertion into pterygomandibular space do not differ from the described VAT. The difference between the mVAT and the VAT is reflected in the manner of anesthetic solution deposition. The mVAT implies deposition of the first dose of anesthetic solution (0.6 ml) at a depth of 25–30 mm. The needle is then withdrawn to a depth of 20–25 mm, where another third of the anesthetic solution is deposited. The last 0.6 ccm of the anesthetic is applied after withdrawing the needle another 5 mm, i.e., at a depth of 15–20 mm (Figures 1–4).

The parameters for evaluation were pain during injection, onset time, duration of anesthesia, width of the anesthetized area, and success of anesthesia. The pain was assessed by the patient using a numerical rating scale (NRS), from 0 to 10, with 0 meaning “no pain” and 10 meaning “worst pain imaginable.” Additionally, four-point verbal rating scale (VRS) was used (1 – no pain; 2 – mild pain; 3 – moderate pain; 4 – severe pain). The onset time was measured in seconds from the moment of the injection until the complete feeling of numbness was acquired. The duration of anesthesia was measured in minutes, from the moment of achieving complete anesthesia until the moment of sensibility restoration. The width of the anesthetized area was assessed subjectively, by the patient, stating the feeling of numbness in the innervation zones of the

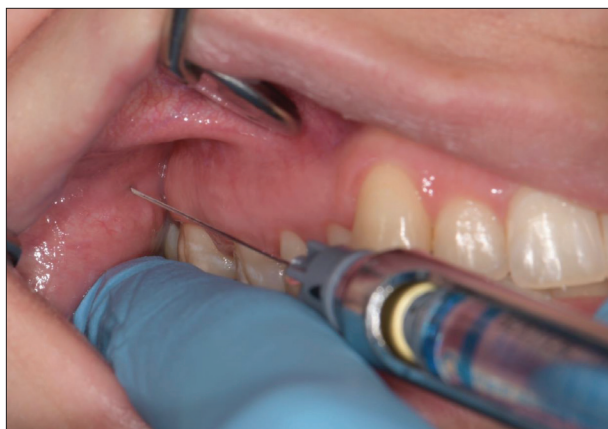

Figure 1. The puncture site and needle direction for modified Vazirani–Akinosi technique

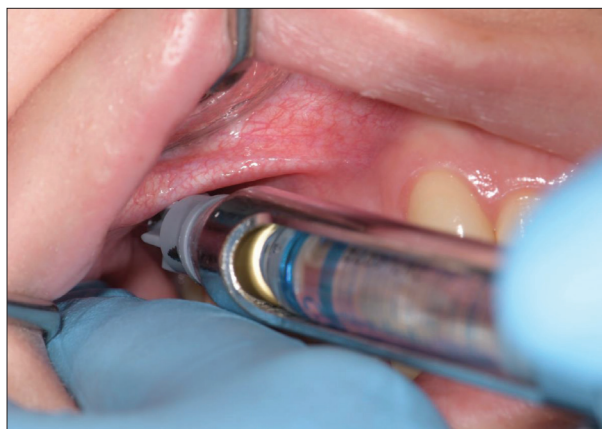

Figure 2. Deposition of the first dose of anesthetic solution (0.6 ml) at a depth of 25–30 mm within the pterygomandibular space

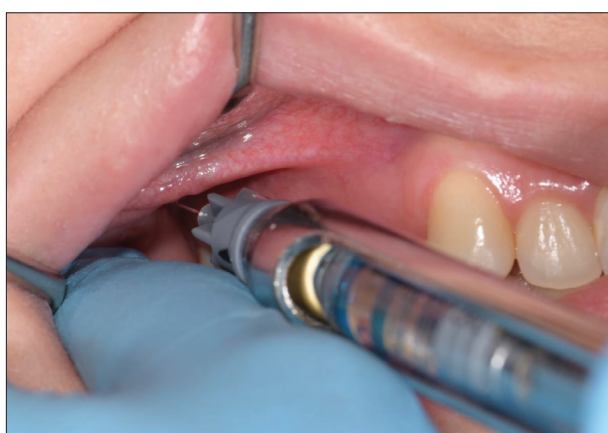

Figure 3. Deposition of the second dose of anesthetic solution (0.6 ml) at a depth of 20–25 mm within the pterygomandibular space

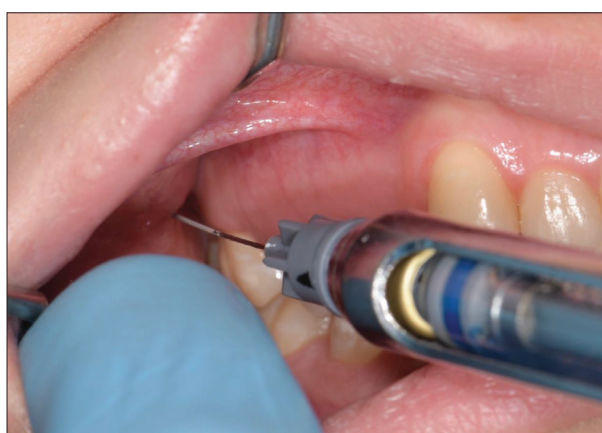

Figure 4. Deposition of the third dose of anesthetic solution (0.6 ml) at a depth of 15–20 mm within the pterygomandibular space

targeted nerves, and it was confirmed objectively, i.e., by a pin-prick test performed by the doctor. The test implied light pricks of mucosa in innervation zones of the targeted nerves with the dental probe. The width of the anesthetized area was considered adequate if the anesthesia included the innervation zones of IAN, LN, and BN. The injection was repeated before the surgery if failure to obtain adequate anesthesia occurred. If the failure implied only inadequate anesthesia in the BN innervation zone, only an additional BN block was administered. Cases that did not require any additional injection were considered successful.

Data analysis was carried out using IBM SPSS Statistics, Version 23.0 (IBM Corp., Armonk, NY, USA). The level of significance was set at 0.05. Normality of distribution was tested using Kolmogorov–Smirnov test. Depending on the variable, parametric (t-test) or nonparametric (Mann–Whitney) tests were used, as well as measures of central tendency and dispersion. For categorical variables, the frequency and percentage in each category were presented and analyzed with a χ^2 test.

RESULTS

The study included 60 patients, aged 18–27 years. The average age of participants in the first group was 20.67 ± 2.4

years, and in the second group 21.50 ± 2.6 years, without a statistically significant difference ($p = 0.224$). There was a total of 33 female and 27 male patients, with no statistically significant difference regarding sex distribution within the groups ($p = 0.604$). The first group included an equal number of men and women, while the second group consisted of 18 women and 12 men.

The highest recorded value of pain intensity in both groups (in all 60 patients) using NRS was 4, and the overall mean pain score was 1.87 ± 1.2 . Although there was no statistically significant difference between the examined groups ($p = 0.114$), patients rated mVAt as less painful (1.60 ± 1.3) compared to VAt (2.13 ± 1.2). The results of the VRS pain assessment are shown in Table 1.

Mean values representing the onset time measured in seconds are shown in Table 2. A slightly faster anesthetic effect was observed in the control group, i.e., after the application of the VA technique, without statistical significance ($p = 0.370$). Considering both groups, the shortest recorded onset time was 57 seconds, while the longest was 227 seconds. The mean onset time for all 60 cases was 138.20 ± 41.7 seconds.

Out of 60 performed anesthesia injections, 42 were successful, which proved to be statistically significant in comparison to 18 unsuccessful ones ($p = 0.047$). Details related to the success rate within the groups are shown in

Table 3. The number of unsuccessful injections, as well as the failure rate regarding individual nerves for each of the examined techniques, are shown in Table 4.

Table 1. Pain during the injection (verbal rating scale)

Group	No pain	Mild pain	Moderate pain	Severe pain	Total
Modified VA technique	7 (23.3%)	21 (70%)	2 (6.7%)	0 (0%)	30 (100%)
Standard VA technique	4 (13.3%)	22 (73.3%)	4 (13.3%)	0 (0%)	30 (100%)
Total	11 (18.3%)	43 (71.7%)	6 (10%)	0 (0%)	60 (100%)

VA – Vazirani–Akinosi

Table 2. Onset time of anesthesia measured in seconds

Group	Mean	Min	Max
Modified VA technique	140.37	57	227
Standard VA technique	136.03	65	187

VA – Vazirani–Akinosi

Table 3. The success rates within the groups

Group	Successful	Unsuccessful	Total
Modified VA technique	25 (83.3%)	5 (16.7%)	30 (100%)
Standard VA technique	17 (56.7%)	13 (43.3%)	30 (100%)
Total	42* (70%)	18* (30%)	60 (100%)

VA – Vazirani–Akinosi;

*statistically significant ($p = 0.047$)

Table 4. The failure rates within the groups

Group	Successful	IAN failure	LN	BN	Total
Modified VA technique	25 (41.7%)	1 (1.7%)	1 (1.7%)	3* (5%)	30 (50%)
Standard VA technique	17 (28.3%)	2 (3.3%)	0 (0%)	11* (18.3%)	30 (50%)
Total	42 (70%)	3 (5%)	1 (1.7%)	14 (23.3%)	60 (100%)

IAN – inferior alveolar nerve; LN – lingual nerve; BN – buccal nerve;

VA – Vazirani–Akinosi;

*statistically significant ($p = 0.030$)

A statistically significant higher success rate of BN anesthesia was observed in the mVAt group ($p = 0.030$). The success of anesthesia considering inferior alveolar and lingual nerve did not significantly differ among the groups ($p = 0.554$ and $p = 0.313$, respectively).

The duration of anesthesia in the first group averaged 172.87 ± 24.6 minutes and in the second group it was 176.93 ± 38.4 minutes. The values of this parameter did not show a statistically significant difference ($p = 0.628$).

DISCUSSION

Ensuring profound anesthesia is of great importance before every surgical procedure. Having in mind a wide variety of the described methods for achieving local anesthesia, modern dentistry should strive towards the improvement of techniques in terms of simplicity, effectiveness, and comfort. Obtaining numbness and a completely painless

procedure may often present a great challenge, due to various above-mentioned difficulties. The ability to provide a successful nerve block by a single injection is, by all means, a key factor to consider when choosing the right technique.

Besides the overall success rate in this study, the results also show the ratio of failed injections, as well as individual nerves that, in case of failure, were not anesthetized. In total, 18 unsuccessful injections were reported. In 14 cases, the BN was not anesthetized. mVAt proved to be more effective in terms of BN anesthesia success, since only three failed injections were observed in this group, unlike the control group, where failure was noticed in 11 cases. Our results are in accordance with data from the literature where the Vazirani–Akinosi technique is presented as a technique of mandibular block that includes the IAN, LN, and very often BN [8, 19, 23]. In this study, failure to achieve anesthesia in the innervation area of the BN after the application of the VAT occurred in 36.7% of the cases. Studies conducted by Sisk [23] and Donkor et al. [19] reported 20% and 29% failure rates of BN anesthesia, respectively. Such cases require additional anesthesia for this nerve. Therefore, the main advantage of the Vazirani–Akinosi technique, which implies complete anesthesia of IAN, LN, and BN with a single injection, is devaluated. Namely, the IAN and the LN separate before entering the pterygomandibular space [20], through which they extend parallel to each other at an average distance of 5.3–8.5 mm [15]. The LN lies anterior and medial to IAN [9, 15]. The BN extends through the upper and anterior part of the pterygomandibular space, descending forward, towards the deep portion of the temporal muscle [20]. Due to the single-phase application of the entire dose of anesthetic solution at a depth of 25–30 mm, as the VA method suggests, the more anteriorly placed BN may not be anesthetized. As the modification of the technique implies – the sequential application of anesthetics to three different places within the pterygomandibular space – it is justified to expect successful anesthesia of all three targeted nerves (Figure 5).

As for the remaining four failed injections in both groups, three injections did not cover IAN innervation zone, while in only one case LN was not anesthetized. Presumably, the failure of anesthesia occurred due to poor assessment of the clinician when placing the needle into the pterygomandibular space. Since this technique relies mostly on the clinician's ability to make a good assessment and does not include any bony landmarks and endpoints, it is possible to deposition anesthetic solution outside the confines of the pterygomandibular space [1, 19]. Nevertheless, no statistically significant difference was observed among groups regarding these two nerves. In addition, a high rate of successful IAN and LN blocks was observed in both groups. These findings are in accordance with previously conducted studies that aimed to evaluate the efficacy of the VA technique. Based on the obtained results, Jendi and Thomas [2], Ravi Kiran et al. [5], Prabhu Nakkeeran et al. [7], and Akinosi [14] also indicated a high success rate and clinical efficacy of the VA technique.

Due to the lack of bony endpoint, while performing both examined techniques, it is possible to anesthetize the

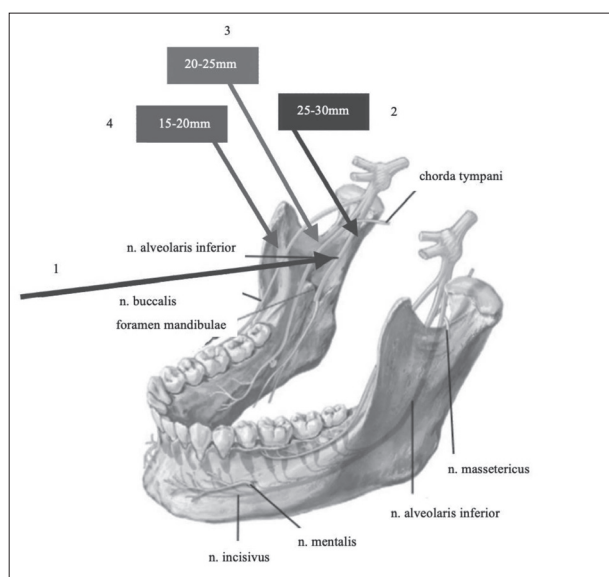


Figure 5. Scheme of needle insertion and anesthetic solution deposition depth for the modified Vazirani–Akinosi technique; 1 – direction of needle insertion; 2, 3, 4 – different depths of anesthetic solution deposition within the pterygomandibular space

auriculotemporal nerve, which happened in several cases during this research. This condition is not considered a complication but only an incidental anesthesia that will inevitably pass without any consequences.

The closed-mouth position, distinctive for the VA technique, ensures relaxation of the muscles and mucosa, which makes the needle prick, as well as the needle insertion, much less painful and unpleasant [14]. The puncture site and the anatomy of the upper parts of the pterygomandibular space also serve as a contribution to the low discomfort while performing this technique. After penetrating the oral mucosa and underlying buccinator muscle, the needle is inserted in the pterygomandibular space [14]. Having a fairly steady direction, it passes through the anterior entrance of the pterygomandibular space, i.e. between the deep tendon of temporal muscle externally, and the medial pterygoid muscle internally [20]. Following the medial surface of the ramus, the needle is inserted to a depth of approximately 25–30 mm. Extending upwards and medially, towards the lateral pterygoid process, the medial pterygoid muscle diverges from the mandibular ramus, giving greater width to superior parts of the pterygomandibular space [25]. The described manner of needle insertion together with advantageous anatomical relations result in negligible discomfort since excessive tearing of muscle fibers is avoided, thus minimizing tissue traumatization.

The specific puncture site, used in both mVAT and VAT, does not include insertion of a needle into sensitive areas that could provoke gag reflex, which makes them more comfortable for patients with severe gagging sensitivity [1, 26]. In addition, concentrating on the required closed-mouth position serves as a diversion, especially in apprehensive patients, shifting their thought focus from fear of the following injection [1]. Overall pain assessment in the present study showed low pain intensity among patients in both examined groups. Most patients evaluated the pain

during the injection as mild, and no one reported severe pain. These findings are consistent with literature reports since Bhat et al. [1], Prabhu Nakkeeran et al. [7], Akinosi [14], Kota et al. [26], and Mishra [27] also stated low pain intensity and high comfort in their studies.

As one of the advantages of the technique, in his original work, Akinosi [14] points out a very short onset time, claiming that the altered sensation occurs 40 seconds after the injection, while the full effect of anesthesia is achieved after 90 seconds. In a study conducted by Jendi and Thomas [2], the mean onset time for the Vazirani–Akinosi technique was 104.24 seconds, Bhat et al. [1] reported the mean onset time of 1.98 minutes, and the study presented by Mishra [27] reported 1.6 minutes as the mean onset for this technique. In the present study, a slightly longer onset time was recorded, with the average of 136.02 seconds (2.26 minutes). Even longer onset time was observed by Ravi Kiran et al. [5], Todorović et al. [18], and Prabhu Nakkeeran et al. [7]. The time required for the anesthetic solution to achieve the effect mainly depends on the proximity of the anesthetic solution deposition to the targeted nerve trunk [2]. Since needle insertion while performing the VA technique is not determined by any bony endpoints, it is possible to inject the solution at an inadequate distance from the nerve trunk, i.e., more distant from the nerve. Such cases may require more time for the solution to take effect or even result in inadequate perfusion of the nerve trunk [1]. Besides the lack of bony landmarks, variations of the ramus anatomy should also be taken into account [2]. The anesthetic solution injected into the upper parts of the pterygomandibular space is able to diffuse targeted nerves under the influence of gravity [19]. Moreover, the diameter of nerve fibers may also affect the onset time, as stated by Mishra [27]. Namely, the diameter of the nerve trunk is larger in the superior parts of the pterygomandibular space, where the anesthetic solution is injected using the VA technique. This may cause a longer onset time since it takes more time for the anesthetic to diffuse and reach core nerve fibers.

In the study by Todorović et al. [18], the mean duration of anesthesia for the VA technique was 180 minutes, which is very similar to our findings. Bhat et al. [1] found the duration to be slightly longer, 3.69 hours on average. This may suggest that the duration of anesthesia is not a key parameter that should be considered when choosing the technique for IAN, LN, and BN block. Additionally, the duration of anesthesia largely depends on the pharmacological properties of the solution, as well as on the speed and the ability of the individual organism to metabolize and eliminate the solution, which certainly exceeds the goals and interests of this research.

CONCLUSION

Modified VA technique proved to be more successful regarding BN anesthesia. Considering other examined clinical parameters, both techniques showed similar performance.

Conflict of interest: None declared.

REFERENCES

- Bhat P, Chanu HT, Radhakrishna S, Ashok Kumar KR, Marimallappa TR, Ravikumar R. Comparison of Clinical Efficacy of Classical Inferior Alveolar Nerve Block and Vazirani-Akinosi Technique in Bilateral Mandibular Premolar Teeth Removal: A Split-Mouth Randomized Study. *J Maxillofac Oral Surg.* 2022;21(1):191–202. [DOI: 10.1007/s12663-020-01374-3] [PMID: 35400900]
- Jendi SK, Thomas BG. Vazirani-Akinosi Nerve Block Technique: An Asset of Oral and Maxillofacial Surgeon. *J Maxillofac Oral Surg.* 2019;18(4):628–33. [DOI: 10.1007/s12663-019-01183-3] [PMID: 31624448]
- Reed KL, Malamed SF, Fonner AM. Local anesthesia part 2: technical considerations. *Anesth Prog.* 2012 Fall;59(3):127–36; quiz 137. [DOI: 10.2344/0003-3006-59.3.127] [PMID: 23050753]
- Jamalpour MR, Talimkhani I. Efficacy of the Gow-Gates and inferior alveolar nerve block techniques in providing anesthesia during surgical removal of impacted lower third molar: a controlled randomized clinical trial. *Avicenna J Dent Res.* 2013;5(1):26–9. [DOI: 10.17795/ajdr-20938]
- Ravi Kiran BS, Kashyap VM, Uppada UK, Tiwari P, Mishra A, Sachdeva A. Comparison of Efficacy of Halstead, Vazirani Akinosi and Gow Gates Techniques for Mandibular Anesthesia. *J Maxillofac Oral Surg.* 2018;17(4):570–5. [DOI: 10.1007/s12663-018-1092-5] [PMID: 30344402]
- Khalil H. A basic review on the inferior alveolar nerve block techniques. *Anesth Essays Res.* 2014;8(1):3–8. [DOI: 10.4103/0259-1162.128891] [PMID: 25886095]
- Prabhu Nakkeeran K, Ravi P, Doss GT, Raja KK. Is the Vazirani-Akinosi Nerve Block a Better Technique Than the Conventional Inferior Alveolar Nerve Block for Beginners? *J Oral Maxillofac Surg.* 2019;77(3):489–92. [DOI: 10.1016/j.joms.2018.08.034] [PMID: 30312586]
- Haas DA. Alternative mandibular nerve block techniques: a review of the Gow-Gates and Akinosi-Vazirani closed-mouth mandibular nerve block techniques. *J Am Dent Assoc.* 2011;142 Suppl 3:85–125. [DOI: 10.14219/jada.archive.2011.0341] [PMID: 21881056]
- Khoury JN, Mihailidis S, Ghabriel M, Townsend G. Applied anatomy of the pterygomandibular space: improving the success of inferior alveolar nerve blocks. *Aust Dent J.* 2011;56(2):112–21. [DOI: 10.1111/j.1834-7819.2011.01312.x] [PMID: 21623801]
- Yu F, Xiao Y, Liu H, Wu F, Lou F, Chen D, et al. Evaluation of Three Block Anesthesia Methods for Pain Management During Mandibular Third Molar Extraction: A Meta-analysis. *Sci Rep.* 2017;7:40987. [DOI: 10.1038/srep40987] [PMID: 28106160]
- Mahajan A, Patel H, Surana M, Abhani V. Comparison of Vazirani-Akinosi and Kurt-Thoma technique for mandibular anesthesia: An observational clinical study. *Natl J Maxillofac Surg.* 2022;13(1):78–83. [DOI: 10.4103/njms.NJMS_189_20] [PMID: 35911817]
- Lee CR, Yang HJ. Alternative techniques for failure of conventional inferior alveolar nerve block. *J Dent Anesth Pain Med.* 2019;19(3):125–34. [DOI: 10.17245/jdapm.2019.19.3.125] [PMID: 31338418]
- Ahn BS, Oh SH, Heo CK, Kim GT, Choi YS, Hwang EH. Cone-beam computed tomography of mandibular foramen and lingula for mandibular anesthesia. *Imaging Sci Dent.* 2020;50(2):125–32. [DOI: 10.5624/isd.2020.50.2.125] [PMID: 32601587]
- Akinosi JO. A new approach to the mandibular nerve block. *Br J Oral Surg.* 1977;15(1):83–7. [DOI: 10.1016/0007-117x(77)90011-7] [PMID: 268212]
- Tomaszewska IM, Graves MJ, Lipski M, Walocha JA. Anatomy and Variations of the Pterygomandibular Space. In: Iwanaga J, Tubbs R, editors. *Anatomical Variations in Clinical Dentistry.* Springer, Cham; 2019. p. 27–9. [DOI: 10.1007/978-3-319-97961-8_4]
- Ferneini EM, Bennett JD. 32 - Anesthetic considerations in head, neck, and orofacial infections. In: Hupp JR, Ferneini EM, editors. *Head, Neck, and Orofacial Infections.* St. Louis: Elsevier; 2016. p. 422–37. [DOI: 10.1016/B978-0-323-28945-0.00032-6]
- Yücel E, Hutchison IL. A comparative evaluation of the conventional and closed-mouth technique for inferior alveolar nerve block. *Aust Dent J.* 1995;40(1):15–6. [DOI: 10.1111/j.1834-7819.1995.tb05606.x] [PMID: 7710409]
- Todorović L, Stajčić Z, Petrović V. Mandibular versus inferior dental anaesthesia: clinical assessment of 3 different techniques. *Int J Oral Maxillofac Surg.* 1986;15(6):733–8. [DOI: 10.1016/s0300-9785(86)80115-6] [PMID: 3100676]
- Donkor P, Wong J, Punnia-Moorthy A. An evaluation of the closed mouth mandibular block technique. *Int J Oral Maxillofac Surg.* 1990;19(4):216–9. [DOI: 10.1016/S0901-5027(05)80395-9] [PMID: 2120362]
- Barker BC, Davies PL. The applied anatomy of the pterygomandibular space. *Br J Oral Surg.* 1972;10(1):43–55. [DOI: 10.1016/s0007-117x(72)80008-8] [PMID: 4506809]
- Cavallini CN, Toledano-Serrabona J, Gay-Escoda C. Evaluation of different mandibular blocks for the removal of lower third molars: a meta-analysis of randomised clinical trials. *Clin Oral Investig.* 2021;25(4):2129–39. [DOI: 10.1007/s00784-020-03525-9] [PMID: 32839834]
- de França AJB, Costa RTF, Monteiro JLGC, Rocha NS, do Egito Vasconcelos BC, de Moraes SLD. Comparison of three anesthetic techniques for the removal of posterior mandibular teeth with 2% lidocaine: a systematic review. *Clin Oral Investig.* 2020;24(12):4143–52. [DOI: 10.1007/s00784-020-03580-2] [PMID: 33089877]
- Sisk AL. Evaluation of the Akinosi mandibular block technique in oral surgery. *J Oral Maxillofac Surg.* 1986;44(2):113–5. [DOI: 10.1016/0278-2391(86)90192-8] [PMID: 3456016]
- Rocha FS, Carneiro RP, Magalhães AEH, Zanetta-Barbosa D, Furtado LM, da Silva MCP. Modified Jorgensen and Hayden Approach to Intraoral Mandibular Anesthesia [Internet]. *A Textbook of Advanced Oral and Maxillofacial Surgery.* InTech. 2015;2. [DOI: 10.5772/59163]
- Coleman RD, Smith RA. The anatomy of mandibular anesthesia: review and analysis. *Oral Surg Oral Med Oral Pathol.* 1982;54(2):148–53. [DOI: 10.1016/0030-4220(82)90209-2] [PMID: 6956833]
- Kota MZ, Zakirulla M, Haider Z, Alshehri A, Alajmi F, Alqahtani N, et al. Comparative analysis between classical inferior alveolar nerve block technique (IANB) and Vazirani Akinosis closed mouth approach for mandibular nerve block. *J Res Med Dent Sci.* 2021;9(5):366–71.
- Mishra S, Tripathy R, Sabhlok S, Panda PK, Patnaik S. Comparative analysis between direct Conventional Mandibular nerve block and Vazirani–Akinosi closed mouth mandibular nerve block technique. *Int J Adv Res Technol.* 2012;1:112–7.

Процена ефикасности модификоване технике у поређењу са стандардном техником Вазирани–Акиноси – рандомизована клиничка студија

Јована Бакаловић¹, Љиљана Стојчев², Бојан Јањић², Бојан Гачић²

¹Универзитет у Београду, Стоматолошки факултет, Београд, Србија;

²Универзитет у Београду, Стоматолошки факултет, Клиника за оралну хирургију, Београд, Србија

САЖЕТАК

Увод/Циљ Правилан избор технике локалне анестезије под-разумева одабир најједноставније технике за извођење, којом се постиже максимални ефекат анестезије уз најмању непријатност са становишта пацијента.

Циљ овог истраживања био је утврђивање ефикасности модификоване у односу на стандардну технику Вазирани–Акиноси, као и поређење наведених техника по питању клинички релевантних параметара.

Метод Истраживање је спроведено на Клиници за оралну хирургију Стоматолошког факултета Универзитета у Београду. Проспективна, рандомизована, једноструко слепа клиничка студија обухватила је 60 пацијената упућених на Клинику ради екстракције импактираних умњака у доњој вилици. Прва група пацијената анестезирана је применом модификоване, док је друга група пацијената анестезирана стандардном техником Вазирани–Акиноси. Праћени параметри били су бол током убризгавања анестетика, латент-

ни период, ширина анестезираног поља и време трајања анестезије.

Резултати Од укупно 60 апликованих анестезија, 42 су биле успешне, што се показало као статистички значајно у поређењу са 18 неуспешних инјекција ($p = 0,047$). Процент неуспеха анестезије образног нерва био је статистички значајно нижи у групи пацијената анестезираних применом модификоване технике Вазирани–Акиноси ($p = 0,030$). Није било статистички значајне разлике међу групама по питању бола ($p = 0,114$), латентног периода ($p = 0,370$) и трајања анестезије ($p = 0,628$).

Закључак Модификована техника Вазирани–Акиноси показала је већу успешност анестезирања образног нерва. Узимајући у обзир остале клиничке параметре, обе технике су показале сличан учинак.

Кључне речи: техника Вазирани–Акиноси; мандибуларна анестезија; орална хирургија