

CASE REPORT / ПРИКАЗ БОЛЕСНИКА

The use of adipose-derived stem cells, platelet-rich and platelet-poor plasma in the maxillary cyst treatment

Boris Simončič¹, Maja Dimitrijević², Jelena Juloski², Zoran R. Vulićević²¹Mirje Medical Center, Institute for regenerative medicine and e-medicine, Ljubljana, Slovenia;²University of Belgrade, School of Dental Medicine, Clinic for Pediatric and Preventive Dentistry, Serbia**SUMMARY****Introduction** The case report describes the effect of combination therapy using adipose-derived stem cells (ADSC), platelet-rich plasma (PRP) and platelet-poor plasma (PPP) in the treatment of a maxillary cyst.**Case outline** A maxillary cyst between the central incisors was identified in a healthy 54-year-old male patient during a routine dental check-up. Following thorough clinical and radiographic examinations, the treatment plan was presented and explained to the patient and written informed consent was obtained. Initially, the conservative periodontal treatment was performed. Afterwards, the adipose tissue was collected from the patient's belly fat and ADSC, PRP, and PPP were obtained, following the Institution's surgical and laboratory protocols. The maxillary cyst was then surgically removed and ADSC, PRP, PPP, and resorptive collagenous membrane were placed on the surgical site. Three-year-follow up radiographs showed significantly reduced radiolucency and bone regeneration around apexes of central incisors. Clinically, there were no signs of inflammation or pain.**Conclusion** The positive outcome of the case presented in this report could be considered as a promising way to treat large bone defects using ADSC, PRP, and PPP.**Keywords:** stem cells; platelet-rich plasma; platelet-poor plasma; maxillary cyst**INTRODUCTION**

Commonly seen cysts of the anterior region of the maxilla are radicular cysts and nasopalatine duct cysts (NPDC). Radicular cysts are inflammatory odontogenic cysts developed around the apices of the teeth with infected or necrotic pulp. Clinically, the lesion may be asymptomatic and discovered by accident on a routine dental radiograph. Their incidence is higher between the third and the sixth decade of life with male predominance [1]. NPDC or incisive canal cyst is the most common non-odontogenic developmental cysts which arises from embryogenic remnants of nasopalatine duct. Patients with this lesion may also be asymptomatic, but many will manifest with one or more symptoms [2]. According to previous studies, prevalence of NPDC is significantly higher in male patients [3]. Both mentioned cysts can grow to significant dimensions and their surgical enucleation can leave large defect in the alveolar bone.

Postnatal stem cells, such as dental pulp stem cells or adipose-derived stem cells (ADSCs), play a significant role in tissue repair and regeneration [4]. The ADSCs are multipotent stem cells, which can be easily obtained in large quantities during simple surgical procedure [5]. According to several studies, ADSCs can differentiate into many different cell types and have great potential for bone regeneration, which has been demonstrated in different in

vitro experimental studies [6, 7]. The platelet-rich plasma (PRP), as a bioactive scaffold, took a significant place in regenerative dentistry. Because of its variety of growth factors, PRP influences bone remodeling and wound healing [8].

The present case report describes the effect of combination therapy using ADSCs, PRP and platelet-poor plasma (PPP) in the treatment of a maxillary cyst.

CASE REPORT

A healthy 54-year-old male came to the Simed Zobozdravstvo Clinic, in Ljubljana, Slovenia for a routine dental check-up in September 2017. He had no subjective problems, and the medical history and family history were non-contributory. Retroalveolar radiography (Figure 1a), made in September 2017, showed a cystic lesion that extends below the nasal spin and is associated with the incisive canal. A cone-beam computed tomography (CBCT) of the intercanine segment of the maxilla was done in December 2017 (Figure 2) showed a radiolucent, clearly demarcated lesion located along the incisive canal and labially from it, extending from the nasal floor to the edge of the alveolar ridge between the upper central incisors. The dimensions of cyst measured on CBCT were 11.63 mm × 13.42 mm × 14.82 mm (Figure 2). The apexes of both upper central incisors

Received • Примљено:

May 8, 2022

Revised • Ревизија:

August 3, 2022

Accepted • Прихваћено:

August 21, 2022

Online first: August 31, 2022**Correspondence to:**Jelena JULOSKI
Dr Subotića Starijeg 11
11000 Belgrade
Serbia
jelena.juloski@stomf.bg.ac.rs

were projected into the lesion; however, they were both surrounded by bone. The buccal lamella above the cyst was intact, while palatal lamella appeared to be affected. Periodontal involvement of all intercanine teeth was severe, and the bone deficit along tooth 21 extended completely marginally. The orthopantomogram image previously made in 2013, brought by the patient, showed that cyst between the upper middle incisors was already visible but in a smaller dimension (approximately 10 × 6 mm).

In the beginning of 2018, the patient was addressed by another dentist to three different oral and maxillofacial surgeons for an examination and consultation due to a lesion that was discovered on a routine examination on an orthopantomogram image. In their reports it was stated that during extraoral examination no obvious abnormality was detected. The mouth opening was not blocked, the occlusion was stable and correct, and the lips were palpable without pathological resistance. A clinical examination revealed that both upper and lower dental arches were provided with fixed partial dentures. Also, generalized periodontal disease with periodontal pockets was present. In the region of the upper central incisors the cyst was not palpated, and when pressed from the vestibular side, no secretion from the gums was observed. When probing, the gums immediately bled, and the increased probing depth of 8 millimeters was present in both incisors distally. All three oral and maxillofacial surgeons believed it was necessary to surgically remove the cyst and to extract both upper middle incisors. The periodontal treatment was also advised.

The patient returned to the Simed Zobozdravstvo Clinic, Ljubljana, Slovenia where complex periodontal-surgical treatments were performed, upon written informed consent has been obtained from the patient. Based on the clinical and radiographical appearance, it was supposed that the lesion was a nasopalatine cyst, which was later confirmed by the histopathological analysis. First, in March 2018 the conservative periodontal treatment was performed. Then, in June 2018, following the institution's protocols, the patient was prepared for the liposuction by injecting local anesthetics and collagenase, prepared according to the prescription (Lekarna, Ljubljana), in the subcutaneous tissues around the patient's waist. Half an hour later, the adipose tissue from the patient was collected from the belly fat, following a standard liposuction protocol, using a 100 ml syringe. After obtaining the lipoaspirate, heparin was added to prevent coagulation and 40 minutes of centrifugation was performed using predetermined programs (Centrifuge, Domel Holding, Železniki, Slovenia). Then, three fractions were aspirated into three syringes: ADSCs approx. 1.5 ml, PRP approx. 2 ml and PPP approx. 2 ml. Before application of the fractions in the surgical field, calcium was added to all three syringes to start coagulation and block heparin. The mentioned autotransplantation protocol has been approved by the Agency for Medicinal Products and Medical Devices of the Republic of Slovenia, that granted the Donor Center status to Clinic Simed Zobozdravstvo (EU Register Simed SI100053). The nasopalatine cyst was then surgically removed under local anesthesia. Incision and nasolabial flap

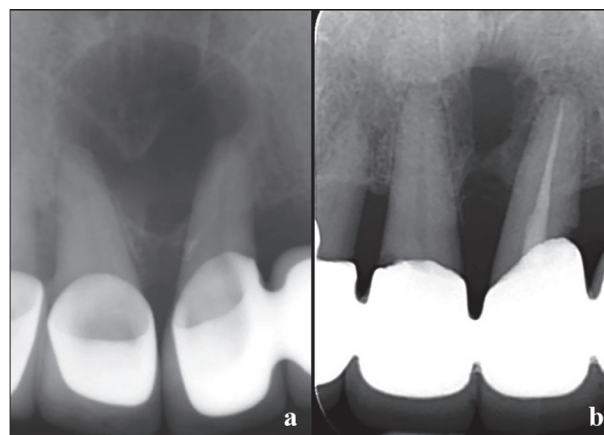

Figure 1. a – preoperative retroalveolar radiograph showing a cystic lesion between roots of the central incisors; b – the 3-year follow-up retroalveolar radiograph showing reduced radiolucency; 900 pixels wide (300 PPI)

were made. The lesion was located along the incisive canal and extended from the nasal floor to the edge of the alveolar ridge between the upper central incisors. The apices of both upper middle incisors were surrounded by bone, but also projected into the lesion. Careful enucleation of the cyst was performed without extraction of adjacent teeth, and on the surgical site ADSCs and PRP were applied and covered with collagenous resorptive membrane Evolution (OsteoBio®, Torino, Italy) and PPP.

The sutures were removed after seven days, and the surgical wound was in the healing process without complications. In September 2018 the dental check-up was conducted, tooth 21 was endodontically treated. After almost three years, in April 2021, a follow-up retroalveolar radiograph (Figure 1b) and CBCT (Figure 3) showed significantly reduced radiolucency (5.44 mm × 8.4 mm × 9.84 mm) and bone regeneration around both apices were visible. Also, clinically there were no signs of inflammation or pain, and periodontal condition of the teeth was acceptable.

DISCUSSION

Over the past decades, the regenerative dentistry represents a progressing field of dentistry, that also involves stem cell technology. The adipose tissue is most used as a stem cells source for tissue engineering, because of high concentration of adult stem cells [9]. According to an earlier study, the ADSCs may be applied in the management of alveolar bone defects, specifically in periodontal disease, and, as stated by the authors, further verification through human clinical trials would be required [10]. Experiences from other research found this application acceptable [9].

Based on a previous study, biomaterials represent significant component in tissue engineering because of their constant stem cells supply with nutrients, and also acting like a biological barrier that protects cells from immune attacks [11]. It is considered that PRP may have a considerable role in tissue regeneration as a suitable biomaterial scaffold for ADSCs, because of the high levels of growth

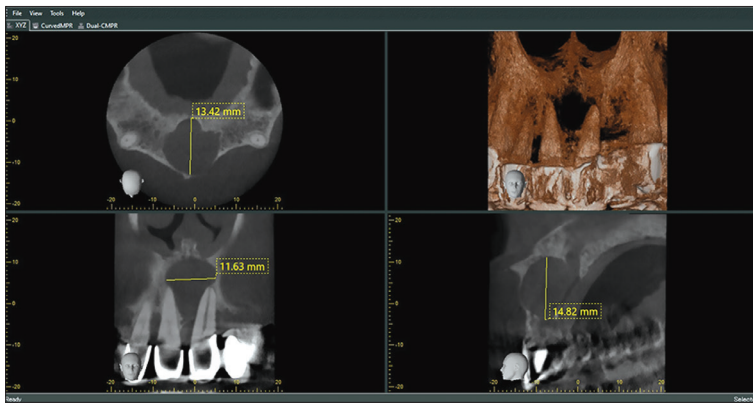


Figure 2. Cone-beam computed tomography showing a radiolucent clearly demarcated lesion located in the intercanine segment of the maxilla; 900 pixels wide (300 PPI)

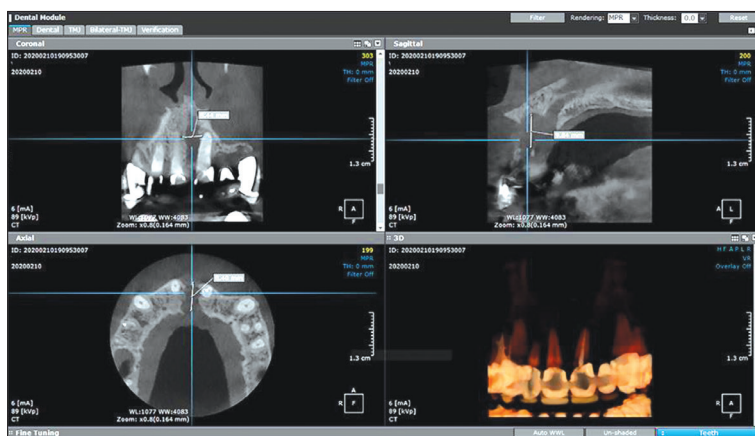


Figure 3. The 3-year follow-up cone-beam computed tomography showing reduced size of the radiolucency; 900 pixels wide (300 PPI)

factors and secretory proteins [12]. Minimal risk of infectious disease transmission, immunologic reactions and rejection are associated with PRP preparation from autologous blood [13]. According to Aly LAA et al [14], the use of PRP in bone surgery can be explained by the local release of various growth factors, from alpha granules, involved in reparative process of osteogenesis. They include platelet derived growth factor (PDGF), insulin-like growth factor-I (IGF-I), transforming growth factor- β (TGF- β), vascular endothelial growth factor (VEGF) and endothelial growth factor (EGF) [14]. PDGF contributes in many specific activities such as angiogenesis and macrophage activation, collagen synthesis and enhance the proliferation of bone cells; IGF-I stimulates protein synthesis and improves bone formation because of the osteoblasts and their proliferation and differentiation; TGF- β shows the ability to induce deposition of bone matrix, to promote the production of extracellular matrix, to enhance the proliferative activity of fibroblasts, and also may inhibit osteoclast formation and bone resorption; VEGF is important for vasculogenesis and angiogenesis and EGF leads to DNA synthesis causing an increased expression of certain genes by binding to the epidermal growth factor receptors (EGFR) [15].

Platelets activation in PRP is one of the crucial elements which will induce the release of multiple growth factors from α -granules by thrombin or calcium [16]. Previous

studies have often reported usage of platelets concentrates in oral and maxillofacial surgery due to the sudden release of platelets as a result of mixing PRP with calcium chloride and thrombin [17]. PRP growth factors, upon release from platelets, bind to receptors that mesenchymal stem cells express on surface of target cells in site of application and initiate a signaling pathway that can inhibit or stimulate cell differentiation and proliferation [12, 18]. PPP is another platelet-derived fraction which can have a significant role in bone regeneration. Study carried out by Hatakeyama et al. [19] implied that PPP gel is stronger than PRP gel because of the slightly higher concentration of fibrinogen and that PPP can stimulate bone formation due to the presence of a fibrin network that allows the space making for bone regeneration. Both PRP and PPP promote wound healing and their similar biological responses indicate that they may conduct positive effect on gingival repair [20].

Due to significant regulatory role of PRP and its ability to affect bone remodeling and healing, some authors believe that the use of PRP together with ADSCs could increase adhesion, migration, proliferation, and differentiation of stem cells, and thus enhance their effectiveness in bone formation and mineralization [21]. Other studies, which have used combination of ADSCs and PRP on experimental animal models, reported differentiation into alveolar bone, cement and periodontal-like structures at the site of the implementation [12]. In vitro investigation in rats, carried out by Huang and Wang [22], reported excellent cell compatibility and proliferation, as well as the influence of PRP growth factors on increased osteogenic cell differentiation. They indicated that growth factors from PRP are adequate approach for bone tissue engineering. Some studies suggested that ADSCs can express synergistic effect with PRP in bone defects therapy [14] and that human PRP demonstrate higher concentration of TGF- β 1, PDGFAA, -AB, and -BB than animal PRP [23]. Although there are divided opinions regarding the use of PRP in bone regeneration, some in vivo studies from other research field have shown a positive PRP effect in stimulating the healing process of bone defects [24]. Also, advanced, second generation of platelet concentrates, platelet-rich fibrin, proved to have beneficial effect in the treatment of patients with chronic periodontitis when used in combination with conservative periodontal therapy [25].

In this case report, the PRP fraction was used as a source of growth factors, which encourages stem cells to proliferate and differentiate faster. Even though PRP contains PPP, a separate fraction of PPP was used as a surgical dressing. After the application of stem cells and PRP in the operative field after cyst enucleation, PPP served as a

natural glue for the stabilization and strengthening of the collagenous membrane. Also, after suturing the wound, the PPP fraction served as a bandage that covers the wound, allowing for faster clot formation and better protection of the wound against the infection. The positive outcome

of the case presented in this report could be considered a promising way to treat large bone defects.

Conflict of Interest: None declared.

REFERENCES

- Hahn HM, Lee YJ, Park DH. Huge Radicular Cyst of the Maxilla Treated with Complete Resection and Immediate Reconstruction by Rib Bone Graft. *J Maxillofac Oral Surg.* 2019;18(3):378–81. [DOI: 10.1007/s12663-018-1125-0] [PMID: 31371877]
- Yeom HG, Kang JH, Yun SU, Yoon JH. Nasopalatine duct cyst with sebaceous differentiation: a rare case report with literature review. *BMC Oral Health.* 2021;21(1):419. [DOI: 10.1186/s12903-021-01772-0] [PMID: 34445966]
- Lang MJ, Lee YP, Hwang MJ, Chiang CP. Nasopalatine duct cyst - Case report. *J Dent Sci.* 2021;16(3):1047–9. [DOI: 10.1016/j.jds.2021.03.004] [PMID: 34141129]
- Honda M, Ohshima H. Biological characteristics of dental pulp stem cells and their potential use in regenerative medicine. *J Oral Biosci.* 2022;64(1):26–36. [DOI: 10.1016/j.job.2022.01.002] [PMID: 35031479]
- Smakaj A, De Mauro D, Rovere G, Pietramala S, Maccauro G, Parolini O, et al. Clinical Application of Adipose Derived Stem Cells for the Treatment of Aseptic Non-Unions: Current Stage and Future Perspectives-Systematic Review. *Int J Mol Sci.* 2022;23(6):3057. [DOI: 10.3390/ijms23063057] [PMID: 35328476]
- Tajima S, Tobita M, Mizuno H. Bone Regeneration with a Combination of Adipose-Derived Stem Cells and Platelet-Rich Plasma. *Methods Mol Biol.* 2018;1773:261–72. [DOI: 10.1007/978-1-4939-7799-4_20] [PMID: 29687395]
- Smakaj A, De Mauro D, Rovere G, Pietramala S, Maccauro G, Parolini O, et al. Clinical Application of Adipose Derived Stem Cells for the Treatment of Aseptic Non-Unions: Current Stage and Future Perspectives-Systematic Review. *Int J Mol Sci.* 2022;23(6):3057. [DOI: 10.3390/ijms23063057] [PMID: 35328476]
- Xu J, Gou L, Zhang P, Li H, Qiu S. Platelet-rich plasma and regenerative dentistry. *Aust Dent J.* 2020;65(2):131–42. [DOI: 10.1111/adj.12754] [PMID: 32145082]
- Lauritano D, Annalisa P, Valentina C, Francesco C. Regenerative Dentistry and Stem Cells: A Multilineage Differentiation as a Safe and Useful Alternative Way of Harvesting and Selection Adipose Derived Mesenchymal Stem Cells. *CDT.* 2018;19(16):1991–7. [DOI: 10.2174/1389450119666180816122230] [PMID: 30112989]
- Gaur S, Agnihotri R. Application of Adipose Tissue Stem Cells in Regenerative Dentistry: A Systematic Review. *J Int Soc Prev Community Dent.* 2021;11(3):266–71. [DOI: 10.4103/jispcd.JISPCD_43_21] [PMID: 34268188]
- Wang Y, Wang D, Guo Y, Liu J, Pan J. The application of bone marrow mesenchymal stem cells and biomaterials in skeletal muscle regeneration. *Regenerative Therapy.* 2020;15:285–94. [DOI: 10.1016/j.reth.2020.11.002] [PMID: 33426231]
- Tobita M, Mizuno H. Adipose-Derived Stem Cells and Periodontal Tissue Engineering. *Int J Oral Maxillofac Implants.* 2013;28(6):e487–e493. [DOI: 10.11607/jomi.te29] [PMID: 24278946]
- Egle K, Salma I, Dubnika A. From Blood to Regenerative Tissue: How Autologous Platelet-Rich Fibrin Can Be Combined with Other Materials to Ensure Controlled Drug and Growth Factor Release. *Int J Mol Sci.* 2021;22(21):11553. [DOI: 10.3390/ijms222111553] [PMID: 34768984]
- Aly LAA, Menoufy HE, Hassan A, Ragae A, Atta HM, Roshdy NK, et al. Influence of Autologous Adipose Derived Stem Cells and PRP on Regeneration of Dehiscence-Type Defects in Alveolar Bone: A Comparative Histochemical and Histomorphometric Study in Dogs. *Int J Stem Cells.* 2011;4(1):61–9. [DOI: 10.15283/ijsc.2011.4.1.61] [PMID: 24298335]
- Xie Z, Shen Z, Zhan P, Yang J, Huang Q, Huang S, et al. Functional Dental Pulp Regeneration: Basic Research and Clinical Translation. *IJMS.* 2021;22(16):8991. [DOI: 10.3390/ijms22168991] [PMID: 34445703]
- Jeong W, Kim YS, Roh TS, Kang EH, Jung BK, Yun IS. The effect of combination therapy on critical-size bone defects using non-activated platelet-rich plasma and adipose-derived stem cells. *Childs Nerv Syst.* 2020;36(1):145–51. [DOI: 10.1007/s00381-019-04109-z] [PMID: 30879128]
- Rodriguez IA, Growney Kalaf EA, Bowlin GL, Sell SA. Platelet-Rich Plasma in Bone Regeneration: Engineering the Delivery for Improved Clinical Efficacy. *BioMed Res Int.* 2014;2014:392398. [DOI: 10.1155/2014/392398] [PMID: 25050347]
- Collins T, Alexander D, Barkatali B. Platelet-rich plasma: a narrative review. *EFORT Open Rev.* 2021;6(4):225–35. [DOI: 10.1302/2058-5241.6.200017] [PMID: 34040800]
- Hatakeyama I, Marukawa E, Takahashi Y, Omura K. Effects of platelet-poor plasma, platelet-rich plasma, and platelet-rich fibrin on healing of extraction sockets with buccal dehiscence in dogs. *Tissue Eng Part A.* 2014;20(3–4):874–82. [DOI: 10.1089/ten.TEA.2013.0058] [PMID: 24098948]
- Martínez CE, Gómez R, Kalergis AM, Smith PC. Comparative effect of platelet-rich plasma, platelet-poor plasma, and fetal bovine serum on the proliferative response of periodontal ligament cell subpopulations. *Clin Oral Investig.* 2019;23(5):2455–63. [DOI: 10.1007/s00784-018-2637-1] [PMID: 30311062]
- Liebig BE, Kisiday JD, Bahney CS, Ehrhart NP, Goodrich LR. The platelet-rich plasma and mesenchymal stem cell milieu: A review of therapeutic effects on bone healing. *J Orthop Res.* 2020;38(12):2539–50. [DOI: 10.1002/jor.24786] [PMID: 32589800]
- Huang S, Wang Z. Platelet-rich plasma-derived growth factors promote osteogenic differentiation of rat muscle satellite cells: in vitro and in vivo studies. *Cell Biol Int.* 2012;36(12):1195–205. [DOI: 10.1042/CBI20110491] [PMID: 22988823]
- Plachokova AS, van den Dolder J, van den Beucken JJ, Jansen JA. Bone regenerative properties of rat, goat and human platelet-rich plasma. *Int J Oral Maxillofac Surg.* 2009;38(8):861–9. [DOI: 10.1016/j.ijom.2009.04.009] [PMID: 19443180]
- Jamal MS, Hurley ET, Asad H, Asad A, Taneja T. The role of Platelet Rich Plasma and other orthobiologics in bone healing and fracture management: A systematic review. *J Clin Orthop Trauma.* 2022;25:101759. [DOI: 10.1016/j.jcot.2021.101759] [PMID: 35036312]
- Vučković M, Nikolić N, Milašin J, Đorđević V, Milinković I, Asotić J, et al. The effect of injectable platelet-rich fibrin use in the initial treatment of chronic periodontitis. *Srp Arh Celok Lek.* 2020;148(5–6):280–5. [DOI: 10.2298/SARH190925022V]

Употреба матичних ћелија масног ткива, плазме богате тромбоцитима и плазме сиромашне тромбоцитима у лечењу максиларне цисте

Борис Симончич¹, Маја Димитријевић², Јелена Јулоски², Зоран Р. Вулићевић²

¹Медицински центар Мирје, Институт за регенеративну медицину и е-медицину, Љубљана, Словенија;

²Универзитет у Београду, Стоматолошки факултет, Клиника за дечју и превентивну стоматологију, Србија

САЖЕТАК

Увод Приказ болесника описује ефекат комбиноване терапије коришћењем матичних ћелија добијених из масног ткива, плазме богате тромбоцитима и плазме сиромашне тромбоцитима у лечењу максиларне цисте.

Приказ болесника Код здравог 54-годишњег мушкарца је током рутинског стоматолошког прегледа случајно установљена максиларна циста између средишњих секутића. После детаљних клиничких и радиографских прегледа болеснику је представљен и објашњен план лечења и добијен је писмени информисани пристанак за лечење. Прво је спроведена конзервативна пародонтолошка терапија. После тога је сакупљено масно ткиво из сала на стомаку болесника и из њега су добијене матичне ћелије масног ткива, плазма богата тромбоцитима и плазма сиромашна тромбоцитима, према хируршким и лабораторијским протоколима Инсти-

туције. Максиларна циста је затим хируршки уклоњена и на оперативно поље су апликоване матичне ћелије из масног ткива, плазма богата тромбоцитима и плазма сиромашна тромбоцитима, као и ресорптивна колагенска мембрана. На контролном рендгенском снимку после три године уочено је значајно мање расветљење и регенерација кости око врхова корена горњих средишњих секутића. Клинички нису били присутни знаци запаљења или бола.

Закључак Позитиван исход приказаног случаја може се сматрати обећавајућим начином лечења великих дефеката виличних костију употребом матичних ћелија из масног ткива, плазме богате тромбоцитима и плазме сиромашне тромбоцитима.

Кључне речи: матичне ћелије; плазма богата тромбоцитима; плазма сиромашна тромбоцитима; максиларна циста