

CASE REPORT / ПРИКАЗ БОЛЕСНИКА

Pulmonary and central nervous system aspergillosis in a patient with COVID-19 infection

Jelena Ljubičić¹, Nataša Čolović², Jelena Bodrožić³¹Studenica General Hospital, Kraljevo, Serbia;²University of Belgrade, Faculty of Medicine, Belgrade, Serbia;³University Clinical Center of Serbia, Clinic of Hematology, Belgrade, Serbia**SUMMARY**

Introduction Patients with COVID-19 infection are vulnerable to a variety of serious complications, including invasive fungal infections such as aspergillosis. Because pulmonary aspergillosis is difficult to confirm with perfect confidence, it has been classified as “proven,” “probable,” and “possible.” We present a patient with COVID-19 infection in whom a “probable” pulmonary aspergillosis was complicated by hematogenous spread into brain with formation of multiple abscesses.

Case outline A 67-year-old female was diagnosed with COVID-19 infection using polymerase chain reaction (PCR) from a nasopharyngeal swab. The patient had never been vaccinated before. Despite standard therapy and noninvasive oxygen support, the patient’s health deteriorated one month following the onset of the disease, with chest discomfort, cough, and hemoptysis. Thoracic computed tomography (CT) revealed bilateral infiltrative lesions with varying diameters of cavities, primarily in the left lung, as well as modest effusions in both pleural spaces. *Aspergillus* hyphae were isolated from tracheobronchial aspirates. Despite therapy with Amphotericin B, which was only available antifungal medication at the time, the patient fell into a coma. A CT scan of the skull revealed several infiltrative lesions inside the brain, some with cavities suggestive to metastatic abscesses, most likely of fungal etiology (*Aspergillus*) as a result of hematogenous spread of pulmonary aspergillosis. Despite therapy and all other precautions, the patient died. The autopsy was not carried out.

Conclusion In addition to other complications, COVID-19 patients may develop pulmonary aspergillosis, which can be fatal because of the possibility of hematogenous spread to the brain.

Keywords: COVID-19; invasive pulmonary aspergillosis; brain

INTRODUCTION

Fungal infections are one of the problems that people with COVID-19 infection are prone to. As a result of respiratory alveolar damage brought on by COVID-19 infection, these tissues are more vulnerable to microbial infections and fungal invasions [1]. COVID-19-associated pulmonary aspergillosis (CAPA) is an invasive fungal complication, which emerged in intensive care units even in previously immunocompetent patients which were on mechanical ventilation [2, 3]. CAPA may also appear in severely ill COVID-19-infected patients receiving noninvasive ventilation in intensive care units, especially in those who have concomitant conditions and are receiving protracted immunomodulatory medication therapy [4].

CASE REPORT

An unvaccinated against COVID-19 67-year-old female presented on September 15, 2021 with cough, chest pain, and high fever. A nasopharyngeal swab was positive for COVID-19 by polymerase chain reaction (PCR). She was treated on the outpatient basis with antibiotics (cephixime, levofloxacin), fraxiparine

– low molecular weight heparin (LMWH) and antiviral drug – favipiravir. As the patient’s condition did not improve, she was admitted to the General hospital in Kraljevo four days later. On examination dyspnea dominated. She was under oxygen mask and O₂ saturation was normal (98%). Chest radiography showed bilateral basal pneumonia. Otherwise, she was submitted to angioplasty of right coronary artery due to myocardial infarction in 2009 and she has put on permanent treatment with aspirin (100 mg/day), angiotensin-converting enzyme inhibitors and nitrates medication. Echocardiography showed reduced ejection fraction of 50%. At admission laboratory data were as follow: white blood cells (WBC) $10.36 \times 10^9/l$, neutrophils 88.4% ($9.16 \times 10^9/l$), lymphocytes 8.2% ($0.850 \times 10^9/l$), hemoglobin (Hb) 141 g/l, platelets $124 \times 10^9/l$. Except moderately elevated glycaemia, biochemical analyses were within normal ranges (Table 1). D-dimer 1.54 mg/l, (C-reactive protein) CRP 17.1 mg/l, Fe 4.2 $\mu\text{mol/l}$, ferritin 110 $\mu\text{g/ml}$, troponin 6.0 pg/ml. Fourth day after admission to hospital the patient suffered more severe chest pain and dyspnea so she had to be transferred to pulmonary unit. Control laboratory data worsened (Table 1). She was developing covid cytokine storm. The dose of corticosteroids

Received • Примљено:

July 16, 2022

Revised • Ревизија:

August 4, 2022

Accepted • Прихваћено:

August 9, 2022

Online first: August 25, 2022**Correspondence to:**

Nataša ČOLOVIĆ
University of Belgrade
Faculty of Medicine
Dr Subotića 8
11000 Belgrade
Serbia
natasacolovic73@gmail.com

Table 1. Laboratory results

Date	15.09.2021	19.09.2021	23.09.2021	1.10.2021	7.10.2021	15.10.2021	26.10.2021	29.10.2021
White blood cell count $\times 10^9/l$	8.59	10.36	14.31	7.6	11.44	7.28	6.02	12.29
Hemoglobin g/l	140	141	135	152	115	104	93	105
Neutrophil count % (absolute count $\times 10^9/l$)	75.6% (6.49)	88.4 (9.16)	94.9 (13.58)	87.1 (6.61)	91.1 (10.43)	94.7 (6.89)	95.9 (5.77)	98 (12.059)
Lymphocyte count % (absolute count $\times 10^9/l$)	17% (1.46)	8.2 (0.85)	3.5% (0.5)	9.5 (0.72)	6.5 (0.74)	3.4 (0.25)	2.8 (0.17)	1.2 (0.15)
Platelet count $\times 10^9/l$	134	127	161	202	132	107	99	73
Blood urea nitrogen (BUN mmol/l)	6.90	7.60	6.53	12.40	10.92	9.05	11.47	20.5
Creatinine mg/l	81	80	58	68	64	89	71	137
Glycaemia mmol/l		10.44	13.56	13.93	16.35	31.19	6.97	8.44
C reactive protein mg/l	2.3	17.1	187.2	14.7	2.5	10.8	172.7	263.5
Ferritin ng/l		110	474	451	786	494	1494	/
D-dimer mg/l FEU	2.77	1.54	0.57	1.85		0.78	/	/
Lactate dehydrogenase IU/l	410	510	504	4.54	505	473	688	1126
FIBRINOGEN		3.1			1.9	2.4	5.2	8.3

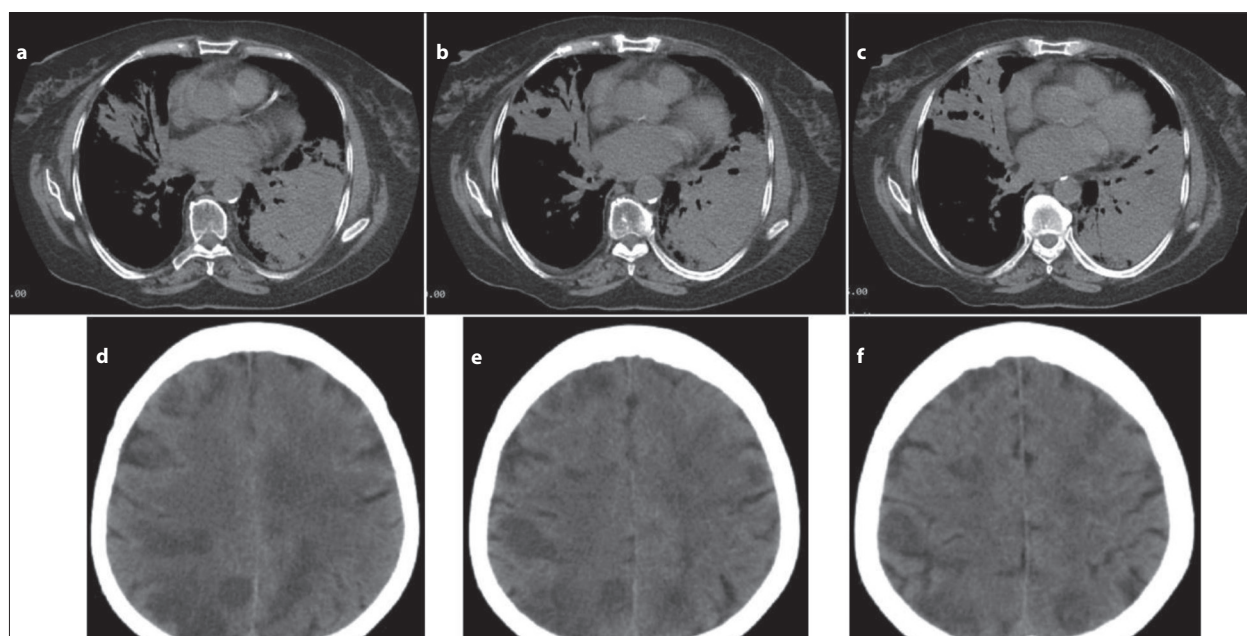


Figure 1. a, b, c – thoracic computed tomography scan showed generalized, partially necrotized inflammatory consolidation of distal part of left lower lobe with signs of numerous cavities of different size, on the right lung with partially necrotized inflammatory infiltrates with signs of cavities within; d, e, f – computed tomography scan of head showing multiple inflammatory lesions through the brain some of which forming abscesses up to 34 mm in diameter

was increased up to 240 mg of methylprednisolone. She was also treated with broad spectrum antibiotics, LMWH, fluconazole and put on permanent noninvasive oxygen therapy, and diabetes mellitus (of which she was not previously aware of) was regulated by infusion pump of insulin. Corticosteroid therapy was not interrupted during the whole hospitalization, but its dose was reduced during periods of the improvement. The patient suffered *Clostridium difficile* enterocolitis which was at first unsuccessfully treated with metronidazole orally, afterwards vancomycin was introduced in doses of 125 mg every six hours, and the patient responded well to treatment. However, soon after, general condition deteriorated developing hemoptysis in the middle of October. Laboratory data showed low number of lymphocytes $0.25/l \times 10^9/l$, CRP was 10.8 mg/l, Hb dropped to 104 gr/l.

Chest CT scan was performed on October 20, 2021 showing bilateral moderate pleural effusions, interstitial focal consolidations and restrictive segmental atelectasis, complicated by cavitory zone of consolidation in lower left pulmonary lobe with significant reduction of parenchyma. The next day condition further deteriorated. During the night between October 29 and 30, the patient became soporose, and was transferred to intensive care unit. The patient's family disagreed with starting the patient on mechanical ventilation, so she stayed on noninvasive ventilation. Laboratory data also deteriorated, especially factors of inflammation CRP 310.5 mg/l, troponin 8.35 ng/l, WBC $9.59 \times 10^9/l$, neutrophils 97.8% ($9.38 \times 10^9/l$), lymphocytes 1.4% ($0.13 \times 10^9/l$), Hb 112 g/l, platelets $76 \times 10^9/l$. Control thoracic CT scan performed on October 26, 2021 showing generalized, partially necrotizing inflammatory

consolidation of distal part of the lower left lobe with signs of numerous cavities of different size, on the right lung with partially necrotized inflammatory infiltrates with signs of cavities (Figure 1a, b, and c). From tracheo-bronchial aspirate branching hyphae of aspergillus were isolated. Amphotericin B was given as the only drug that was available, colistin, meropenem, corticosteroids and LMWH. As the patient became comatose, endocranial CT scan was performed showing multiple inflammatory lesions throughout brain. Some of the inflammatory focuses in brain were radiographically classified as abscesses up to 34 mm in diameter (Figure 1d, e, and f). The patient died on November 1, 2021. Autopsy was not performed.

This study was done in accordance with the institutional committee on ethics.

DISCUSSION

It is well known that immunodeficient patients with hematological malignancies such as acute leukemia patients, patients with hematopoietic stem cells transplantation are at highest risk for invasive fungal infections such as aspergillosis, candidiasis and mucormycosis [5, 6]. CAPA may even occur in immunocompetent patients, most frequently in those in intensive care units who are on mechanical ventilation, usually 10–14 days after establishing the diagnosis. Less frequently it may occur in patients who are not on mechanical ventilation particularly during cytokine storm, acute respiratory distress syndrome (ARDS) or in those who are on prolonged immunomodulatory drugs. The most frequent cause of fungal infection is *Aspergillus fumigatus* [7]. According to different authors the incidence of CAPA ranges between 3.8% and 33.3% of patients, depending on geographic area, while the overall incidence was 7.6% for proven, probable or possible CAPA [2, 8].

A low number of lymphocytes and severe lung damages caused by SARS-CoV-2 virus are risk factors for developing invasive fungal infection [1]. The further risk factors

for development of fungal infection are an administration of immunomodulatory agents, especially prolonged use of corticosteroids in severe COVID-19 patients [2, 8] as well as significant comorbidities such as previous pulmonary disease, renal failure, diabetes mellitus, liver failure, malignancy etc.

The European Confederation of Medical Mycology/The International Society for Human and Animal Mycology expert group established criteria for diagnosis and classification of CAPA, based on clinical factors, chest imaging and microbiological findings of *Aspergillus* presence, according which a pulmonary aspergillosis may be defined as “proven”, “probable” and “possible”, depending on the reliability of diagnostic procedure that have been performed [3]. The group advised diagnostic bronchoscopy in patients with high clinical suspicion for fungal infection in order to collect secret from bronchi for evaluation (PCR, galactomannan test and cultures). However, it turned out that in real practice a bronchoscopy was not frequently performed in the intensive care units because it generates aerosols which is considerable risk for spreading COVID-19 disease to health care workers [5]. CAPA galactomannan test in serum is usually negative, while in bronchial secret is positive. In our patient there were no technical possibilities to perform either galactomannan test in serum, or in tracheobronchial secret. It is also possible that hemoculture could be positive if taken in time of hematogenic dissemination of fungal infection to the central nervous system. CAPA is an invasive fungal complication that may develop in immunocompetent patients who are in intensive care units and receiving invasive ventilation, but it occurs less frequently in patients receiving noninvasive ventilation, particularly if they have comorbid conditions, have experienced ARDS, cytokine storm, or have received prolonged treatment with high doses of corticosteroids or other immunomodulatory medications (tocilizumab).

Conflict of interest: None declared.

REFERENCES

1. Khodavaisy S, Khajavirad N, Hashemi SJ, Izadi A, Dehghan Manshadi SA, et al. Proven Pulmonary Aspergillosis in a COVID-19 Patient: A Case Report. *Curr Med Mycol.* 2021;7(2):39–42. [DOI: 10.18502/cmm.7.2.7031] [PMID: 35028484]
2. Meijer EFJ, Dofferhoff ASM, Hoiting O, Meis JF. COVID-19-associated pulmonary aspergillosis: A prospective single-center dual case series. *Mycoses.* 2021;64(4):457–64. [DOI: 10.1111/myc.13254] [PMID: 33569857]
3. Koehler P, Bassetti M, Chakrabarti A, Chen SC, Colombo AL, Hoenigl M, et al. Defining and managing COVID-19-associated pulmonary aspergillosis: The 2020 ECM/ISHAM consensus criteria for research and clinical guidance. *Lancet Infect Dis.* 2020;21(6):e149–e162. [DOI: 10.1016/S1473-3099(20)30847-1] [PMID: 33333012]
4. Witting C, Quaggin-Smith J, Mylvaganam R, Peigh G, Angarona M, Flaherty JD. Invasive pulmonary aspergillosis after treatment with tocilizumab in a patient with COVID-19 ARDS: a case report. *Diagn Microbiol Infect Dis.* 2021;99(4):115272. [DOI: 10.1016/j.diagmicrobio.2020.115272] [PMID: 33388572]
5. Nasri E, Shoaie P, Vakili B, Mirhendi H, Sadeghi S, Hajiahmadi S, et al. Fatal invasive pulmonary aspergillosis in COVID-19 patient with acute myeloid leukemia in Iran. *Mycopathologia.* 2020;185(6):1077–84. [DOI: 10.1007/s11046-020-00493-2] [PMID: 33009966]
6. Čolović N, Arsić-Arsenijević V, Barać A, Suvajdžić N, Leković D, Tomić D. Mucormycosis of the paranasal sinuses in a patient with acute myeloid leukemia. *Srp Arh Cel Lek.* 2016;144(11–12):657–60. [DOI: 10.2298/SARH1612657C] [PMID: 29659234]
7. Machado M, Valerio M, Álvarez-Uría A, Olmedo M, Veintimilla C, Padilla B, et al. Invasive pulmonary aspergillosis in the COVID-19 era: an expected new entity. *Mycoses.* 2021;64(2):132–43. [DOI: 10.1111/myc.13213] [PMID: 33210776]
8. White PL, Springer J, Wise MP, Einsele H, Löffler C, Seif M, et al. A Clinical Case of COVID-19-Associated Pulmonary Aspergillosis (CAPA), Illustrating the Challenges in Diagnosis (Despite Overwhelming Mycological Evidence). *J Fungi (Basel).* 2022;8(1):81. [DOI: 10.3390/jof80100] [PMID: 35050021]

Аспергилоза плућа и централног нервног система код болесника са инфекцијом ковидом 19

Јелена Љубичић¹, Наташа Чоловић², Јелена Бодрожич³

¹Општа болница „Студеница“, Краљево, Србија;

²Универзитет у Београду, Медицински факултет, Београд, Србија;

³Универзитетски клинички центар Србије, Клиника за хематологију, Београд, Србија

САЖЕТАК

Увод Болесници са инфекцијом ковидом 19 подложни су разним врстама компликација, па и инвазивним гљивичним инфекцијама, као што је аспергилоза. Аспергилоза се код њих не може са сигурношћу лако доказати, тако да се њена дијагноза квалификује као „доказана“, „вероватна“ и „могућа“. Приказујемо болесницу са инфекцијом ковидом 19 код које је „вероватна“ аспергилоза плућа метастазирала у мозак доводећи до мултиплих апсцеса мозга.

Приказ болесника Код жене старе 67 година дијагностикована је инфекција ковидом 19 ланчаном реакцијом умножавања (PCR) из назофарингеалног бриса. Иначе болесница није била вакцинисана. Упркос стандардном лечењу и неинвазивној оксигенотерапији, стање болеснице се погоршало месец дана после почетка болести са појавом болова у грудима, кашљем и хемоптизијама. Компјутеризована томографија грудног коша показала је инфилтрате у оба плућ-

на крила са формирањем кавитета разне величине у њима и мање изливе у обе плеуралне дупље. Из трахеобронхијалног аспириата изоловане су хифе аспергилуса. Упркос лечењу амфотерицином Б, који је једино био доступан, болесница је развила коматозно стање, а компјутеризована томографија мозга је показала мултипле инфилтративне лезије са местимичним формирањем кавитета који су одговарали метастатским апсцесима, вероватно гљивичне етиологије (*Aspergillus*), настале хематогеном дисеминацијом из плућа. Упркос свим терапијским мерама, дошло је до леталног исхода. Сходно препорукама, аутопсија није рађена.

Закључак Међу бројним компликацијама, оболели од ковида 19 могу развити аспергилозу плућа, која због могућности хематогеног ширења на мозак може довести до леталног исхода.

Кључне речи: ковид 19; инвазивна аспергилоза плућа; мозак