

## CASE REPORT / ПРИКАЗ БОЛЕСНИКА

# Occipitocervical fusion as treatment of instability in Chiari malformation

Slaviša Zagorac<sup>1,2</sup>, Radovan Mijalčić<sup>1,3</sup>, Miloš Vasić<sup>2</sup>, Uroš Dabetić<sup>2</sup>, Uroš Novaković<sup>2</sup><sup>1</sup>University of Belgrade, Faculty of medicine, Belgrade, Serbia;<sup>2</sup>University Clinical Center of Serbia, Clinic for Orthopedic Surgery and Traumatology, Belgrade, Serbia;<sup>3</sup>University Clinical Center of Serbia, Clinic for Neurosurgery, Belgrade, Serbia**SUMMARY**

**Introduction** Occipitocervical (OC) fusion is a method for fixation of the OC junction when there is instability of that segment. Arnold Chiari malformation is a congenital disorder where cerebellar tonsils descend through the foramen magnum, which can lead to corticomedullar compression and formation of a syrinx. While treating this condition, for the purpose of decompression, the foramen magnum is expanded, which can potentially harm the stability of the OC junction.

**Case outline** We are presenting the case of a 16-year-old female who was surgically treated (suboccipital craniectomy and decompression) because of Arnold Chiari malformation type I. One-year post-op multislice computed tomography verified a slight enlargement of basion-axial and basion-dens intervals, with signs of spinal cord compression. Surgery was performed – OC fusion, canal decompression on C1 and C2 levels with a plate on occipital bone and screws placed in the third, fourth, and fifth cervical vertebra.

**Conclusion** OC fusion is a complex surgical procedure (vital neurovascular structures), but it is a reliable method for treatment of instability of the OC junction.

**Keywords:** occipitocervical instability; fusion; Arnold Chiari

**INTRODUCTION**

Occipitocervical (OC) fusion is a surgical method for fixation of the OC junction when there is instability of the OC segment caused by a variety of conditions (trauma, rheumatoid arthritis, congenital anomalies, neoplasm, iatrogenic instability due to decompression) [1].

Arnold Chiari malformation is a congenital disorder where cerebellar tonsils descend through the foramen magnum, which can lead to corticomedullar compression and creation of syrinx. It can also be associated with numerous anomalies (syringomyelia, spina bifida, hydro-myelia, kyphosis, scoliosis and tethered cord syndrome), as well as hereditary syndromes [2].

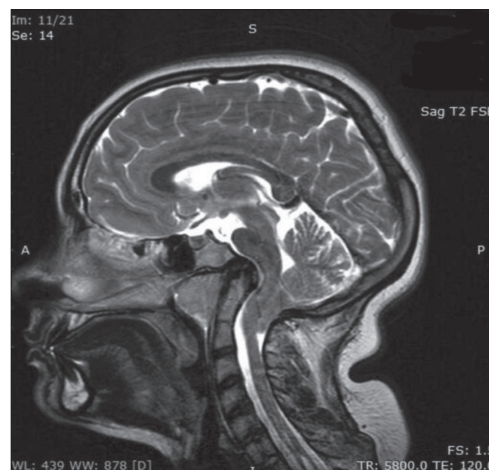
To this date the treatment protocol is debatable, with some authors preferring conservative treatment to surgery [3], but available literature is in favor of surgical treatment [4, 5, 6].

While treating this condition, for the purpose of decompression, the foramen magnum is expanded which can potentially harm the stability of the OC junction [7].

**CASE REPORT**

We are presenting the case of a 16-year-old female who was surgically treated (suboccipital craniectomy and decompression) because of Arnold Chiari malformation type I. She was initially hospitalized because of repetitive episodes of weakness in both arms and legs, that lasted

for a few minutes and disappeared spontaneously. They first appeared six months prior to hospital admission. After careful examination she was diagnosed with Chiari malformation type I that was magnetic resonance (MRI) verified – a prolapse (herniation) of the cerebellar tonsils through the foramen magnum by 20 mm, with compression of the spinal cord. The ventricular system was in an orderly position and shape, without signs of hydrocephalus. In addition to this obvious malformation, the existence of syringomyelia (starting from C5 and caudally) and malformation of the base of the skull in terms of platybasia and an abnormal angle between the medulla oblongata and mesencephalon were observed (Figure 1).



**Figure 1.** The first magnetic resonance imaging showing herniation of cerebellar tonsils through the foramen magnum (20 mm) with spinal cord compression

**Received • Примљено:**

February 3, 2022

**Revised • Ревизија:**

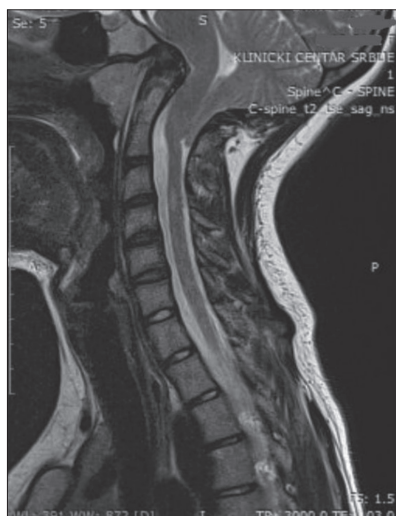April 3, 2022

**Accepted • Прихваћено:**

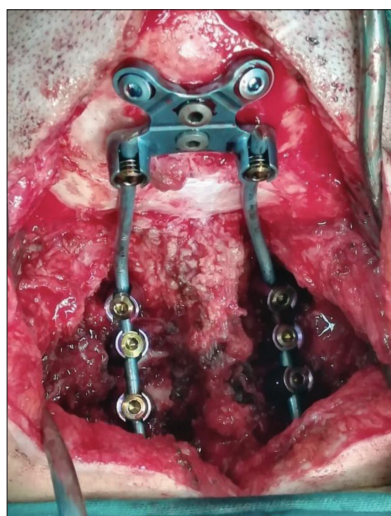
April 6, 2022

**Online first:** April 21, 2022**Correspondence to:**

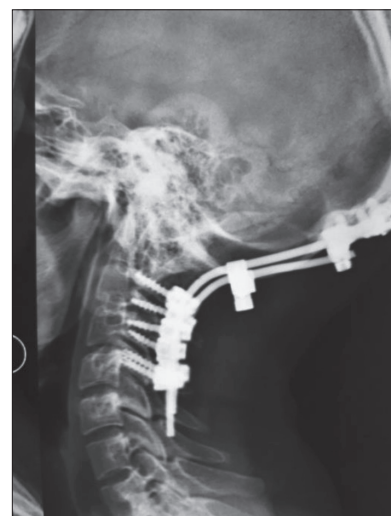Slaviša ZAGORAC  
University Clinical Center of Serbia  
Clinic for Orthopedic Surgery and  
Traumatology  
Pasterova 2  
11000 Belgrade  
Serbia  
[slavisa.zagorac@gmail.com](mailto:slavisa.zagorac@gmail.com)



**Figure 2.** The first follow up magnetic resonance imaging, before the first surgery



**Figure 3.** Intraoperative finding – occipital plate and screws



**Figure 4.** Postoperative X-ray

Follow up nuclear MRI was performed (Figure 2) following the first hospitalization and the findings were unchanged and the neurosurgical procedure (suboccipital craniectomy and decompression) was performed. Approximately one-year post-op the patient presents with following symptoms: headache, left arm paresthesia eventually followed by left side hemiparesis. New multislice computed tomography and MRI scans were obtained and showed progression of syringomyelia expanding cranially to syringobulbia, decompression in posterior cranial fossa was still intact. Two months later the symptoms persisted and new MRI scans were obtained – in comparison with former scans progression of hydrosyringomyelia was observed, as well as expanded central medullar canal with oedema. Conservative treatment was tried with antiedema therapy, but there was no clinical improvement. The patient was hospitalized again and another MRI evaluation was performed, and neurosurgeon and orthopedic spinal surgeon indicated OC stabilization.

Surgery was performed – OC fusion, canal decompression on C1 and C2 levels with a plate on occipital bone and screws placed in the third, fourth and fifth cervical vertebra. Neuromonitoring was used throughout the whole surgery (Figure 3 and 4).

Postoperatively the patient has no significant symptoms, with notable reduction of pain and paresthesia of the left arm. Movements of cervical spine are limited, in accordance with the stated surgery. The patient is feeling well and she is back to her daily activities.

The study was done in accordance with the institutional Committee on Ethics.

## DISCUSSION

OC fusion is a surgery indicated for treatment of craniocervical junction instability caused by a variety of different pathologies (congenital, traumatic, degenerative, inflammatory, infective, or neoplastic) [1, 8].

This surgery represents a huge challenge for the operator and his team, considering that C0–C1–C2 is the most mobile portion of the spine, and it is the portion of the spine that must resist force in eight axes of rotation [9].

Each patient that presents with craniocervical junction instability, whatever the cause, must be carefully and minutely assessed, appropriate diagnostic methods used. Only then – while taking into account clinical presentation (functional stability, neurological status, accompanying symptoms), as well as MRI/CT findings – after preoperative planning the decision about the right treatment should be made [10].

The advances made in the field of neuroradiology have made it possible to understand biomechanics and structure of this region, especially considering substantial number of anatomical variations of vascular and neural structures [11]. Today, these radiologic findings are crucial in preoperative planning, and intraoperative visualization.

In 1900s, OC instability was considered inoperable and a terminal condition, and in the last 90 years there was a large number of surgical techniques developed to perform OC fusion [12].

Despite of the chosen method, the main goal is the same – restore and maintain alignment, decompress neural elements and provide good conditions for the bone fusion to occur.

The spine surgeon performing OC fusion must be well aware of spinal biomechanics and anatomy, and he must be familiar with the procedures to achieve decompression, alignment immobilization and fusion. Also, the surgeon should be aware of the perioperative risks and complications rates that are significant, and the readmission rates following OC fusion – that although lower in elective OC fusion surgeries are not negligible [13, 14].

Taking into account the aforementioned, it is clear that indicating this surgery is a big decision and the surgeon must consider all of the methods available as well as evaluate each patient individually before deciding this is the best solution.

While official surgical guidelines are yet to be established advancements are being made and teams consisting of experts in diagnosing and treating this condition were put together to discuss this matter [15]. Most authors agree that a decision should be made based on the clinical condition of the patient [5–8]. In their research, Asghar Ali Turabi et al. [16] concluded that OC fusion along with decompression surgery, had better outcome than decompression surgery alone. In order to be able to make the best patient-oriented decision, larger studies focusing on treatment outcomes are necessary as the available studies have shown that outcomes vary relative to a number of

factors like chosen surgical procedure, symptoms duration and syringomyelia [17].

In our experience, OC fusion is a complex surgical procedure (involving vital neurovascular structures), demanding a multidisciplinary approach (spinal surgeon, neurosurgeon, anesthesiologist) but it is a reliable method for treatment of instability of the OC junction. Every case should be carefully considered, and if decided that OC fusion is the appropriate method of treatment, it requires detailed planning.

**Conflict of interest:** None declared.

## REFERENCES

- Kukreja S, Ambekar S, Sin A, Nanda A. Occipitocervical Fusion Surgery: Review of Operative Techniques and Results. *J Neuro Surg B Skull Base*. 2015;76(5):331–9.
- Holly L, Batzdorf U. Chiari malformation and syringomyelia. *J Neurosurg Spine*. 2019;31(5):619–28.
- Landridge B, Philips E, Choi D. Chiari Malformation Type 1: A Systematic Review of Natural History and Conservative Management. *World Neurosurg*. 2017;104:213–9.
- Vinchon M. Surgery for Chiari 1 malformation: the Lille experience. *Childs Nerv Syst*. 2019;35(10):1875–80.
- Fric R, Ringstad G, Eide P. [Chiari malformation type 1 – diagnosis and treatment]. *Tidsskr Nor Laegeforen*. 2019;139(10).
- Chatterjee S, Shivhare P, Verma S. Chiari malformation and atlantoaxial instability: problems of co-existence. *Childs Nerv Syst*. 2019;35(10):1755–61.
- Rocque B, Oakes W. Surgical Treatment of Chiari I Malformation. *Neurosurg Clin N Am*. 2015;26(4):527–31.
- Joaquim A, Osorio J, Riew K. Occipitocervical Fixation: General Considerations and Surgical Technique. *Global Spine J*. 2020;10(5):647–56.
- Ling FP, Chevillotte T, Leglise A, Thompson W, Bouthors C, Le Huec JC. Which parameters are relevant in sagittal balance analysis of the cervical spine? A literature review. *Eur Spine J*. 2018;27(Suppl 1):8–15.
- Macki M, Hamilton T, Pawloski J, Chang V. Occipital fixation techniques and complications. *J Spine Surg*. 2020;6(1):145–55.
- Izzo R, Popolizio T, Balzano RF, Simeone A, Gasparotti R, Scarabino T, et al. Imaging of craniocervical junction traumas. *Eur J Radiol*. 2020;127:108960.
- Winegar CD, Lawrence JP, Friel BC, Fernandez C, Hong J, Maltenfort M, et al. A systematic review of occipital cervical fusion: techniques and outcomes. *J Neurosurg Spine*. 2010;13(1):5–16.
- Elia C, Takayanagi A, Arvind V, Goodmanson R, von Glinski A, Pierre C, et al. Risk Factors Associated with 90-Day Readmissions Following Occipitocervical Fusion-A Nationwide Readmissions Database Study. *World Neurosurg*. 2021;147:e247–e254.
- Zileli M, Akıntürk N. Complications of occipitocervical fixation: retrospective review of 128 patients with 5-year mean follow-up. *Eur Spine J*. 2022;31(2):311–26.
- Ciaramitaro P, Massimi L, Bertuccio A, Solari A, Farinotti M, Peretta P, et al. Diagnosis and treatment of Chiari malformation and syringomyelia in adults: international consensus document. *Neurol Sci*. 2022;43(2):1327–42.
- Asghar Ali Turabi MA, Pruthi N, Bhat D, Bhagavatula ID. Complex Chiari Malformation: Proposal of a New Set of Diagnostic Criteria and Outcomes After fusion Surgery. *World Neurosurg*. 2021;154:e677–e682.
- Basaran R, Bozdogan C, Senol M, Gundogan D, Isik N. Long-term outcomes of surgical management in subtypes of Chiari malformation. *Neurol Res*. 2021;43(9):760–6.

## Окципитоцервикална фузија у лечењу нестабилности код Кјаријеве малформације

Славиша Загорац<sup>1,2</sup>, Радован Мијалчић<sup>1,3</sup>, Милош Васић<sup>2</sup>, Урош Дабетић<sup>2</sup>, Урош Новаковић<sup>2</sup>

<sup>1</sup>Универзитет у Београду, Медицински факултет, Београд, Србија;

<sup>2</sup>Универзитетски клинички центар Србије, Клиника за ортопедску хирургију и трауматологију, Београд, Србија;

<sup>3</sup>Универзитетски клинички центар Србије, Клиника за неурохирургију, Београд, Србија

### САЖЕТАК

**Увод** Окципитоцервикална (ОЦ) фузија је метода фиксације ОЦ прелаза када постоји нестабилност тог сегмента. Арнолд–Кјаријева малформација је конгенитални поремећај где долази до миграције церебеларних тонзила кроз форамен магнум, што може довести до цервикомедуларне компресије и стварања сиринокса. Приликом лечења овог поремећаја, због декомпресије се шири форамен магнум, што може довести до нестабилности ОЦ прелаза.

**Приказ болесника** Приказујемо случај болеснице старости 16 година са Арнолд–Кјаријевом малформацијом типа I која је хируршки лечена (субокципитална краниектомија и декомпресија). Годину дана после операције на мултислај-

сној компјутеризованој томографији је верификовано благо увећање интервала *базион-аксис* и *базион-денс*, са знацима компресије кичмене мождине. Учињен је хируршки захват – ОЦ фузија, декомпресија спиналног канала на нивоима C1 и C2, плоча је позиционирана на окципиталну кост, док су шrafoви пласирани у пршљенове C3, C4 и C5.

**Закључак** ОЦ фузија је сложена хируршка процедура (анатомска позиција виталних неуроваскуларних структура), али представља поуздану методу лечења нестабилности ОЦ прелаза.

**Кључне речи:** окципитоцервикална нестабилност; фузија; Арнолд–Кјари