

CASE REPORT / ПРИКАЗ БОЛЕСНИКА

Resection of Haglund's deformity using the arthroscopic method with the three-portal technique

Nemanja Jovanović¹, Filip Maljković¹, Lazar Mičeta^{1,2}, Nemanja Slavković^{1,2}, Branislav Krivokapić^{1,2}¹Banjica Institute for Orthopaedics, Belgrade, Serbia;²University of Belgrade, Faculty of Medicine, Belgrade, Serbia**SUMMARY**

Introduction Haglund's deformity represents a reactive enlargement of the posterolateral aspect of the calcaneus and often causes pain that can significantly disturb everyday activities. If the patient's condition does not improve after six months of non-surgical treatment, surgical treatment could be taken into consideration. Although Haglund's deformity is successfully treated by endoscopic calcaneoplasty with a two-portal technique, we decided to apply a slightly newer technique – arthroscopic surgery with a three-portal technique.

Case outline A patient with clinically and radiographically confirmed Haglund's deformity was operated on using arthroscopic calcaneoplasty with a three-portal technique. The postoperative recovery was uneventful and full weight-bearing was allowed after four weeks. A complete return to sports activities was allowed after four months.

Conclusion Arthroscopic calcaneoplasty with the three-portal technique proved to be a safe and cost-effective surgical method in the treatment of Haglund's deformity. There is still not enough data in the literature regarding this type of surgical treatment, but the good postoperative functional results are extremely encouraging since this surgical technique enables faster recovery and fewer postoperative complications.

Keywords: endoscopic calcaneoplasty; hindfoot; Haglund disease; retrocalcaneal bursitis

INTRODUCTION

Haglund's deformity (HD) represents a reactive enlargement of the posterolateral aspect of the calcaneus, often followed by the inflammation of the retrocalcaneal bursa and insertional tendinopathy of the Achilles tendon [1, 2].

For the precise diagnosis of HD, a clinical examination and a lateral-view radiograph are usually sufficient. HD is successfully treated non-surgically, but if the patient's condition does not improve after six months of non-surgical treatment, surgical treatment can be taken into consideration [2, 3]. Operation can be performed as open or arthroscopically assisted surgery. Both methods usually include the removal of retrocalcaneal bursa and the resection of the ossification in the posterolateral aspect of the calcaneus [2, 3, 4]. An "open" surgery bears a higher risk of postoperative complications, which include difficulties in wound healing, hyperkeloid scars, larger postoperative swelling and hematoma, skin paresthesias near the postoperative scar, neurovascular injuries, avulsions of the Achilles tendon attachment, greater possibility of the iatrogenic fracture of a heel bone and the postoperative Achilles tendon shortening, which causes decreased foot dorsiflexion [2, 4, 5, 6]. Thus, for the last three decades, arthroscopically assisted surgery of the

ankle represents the surgical method of choice in the treatment of this deformity [4].

CASE REPORT

The patient was a 27-year-old male, a recreational basketball player with pain and swelling in the posterior aspect of the right heel, with difficulties in walking. The symptoms had been lasting for three months affecting his normal life and sports activities.

Examination showed typical symptoms for HD, local swelling and redness of the posterior aspect of the heel, palpable painful bony prominence in the mentioned area, with painful sensitivity on both sides of the Achilles tendon insertion. Tendon palpation did not cause any pain. The lateral radiograph of the foot revealed the enlargement of the posterolateral aspect of the calcaneus, with the positive parallel pitch lines, which is the most important radiographic sign [7]. Due to clear clinical and radiographic presentation, MRI of the foot was not performed.

The patient was advised against wearing tight shoes and using 1 cm of padding placed under the right leg heel was suggested to him, as well as, practicing the Achilles tendon stretching on daily basis, using anti-inflam-

Received • Примљено:

July 3, 2021

Accepted • Прихваћено:

March 26, 2022

Online first: April 5, 2022**Correspondence to:**Nemanja JOVANOVIĆ
Banjica Institute for Orthopaedics
Mihaila Avramovića 28
11000 Belgrade, Serbia
nemanjahull@gmail.com

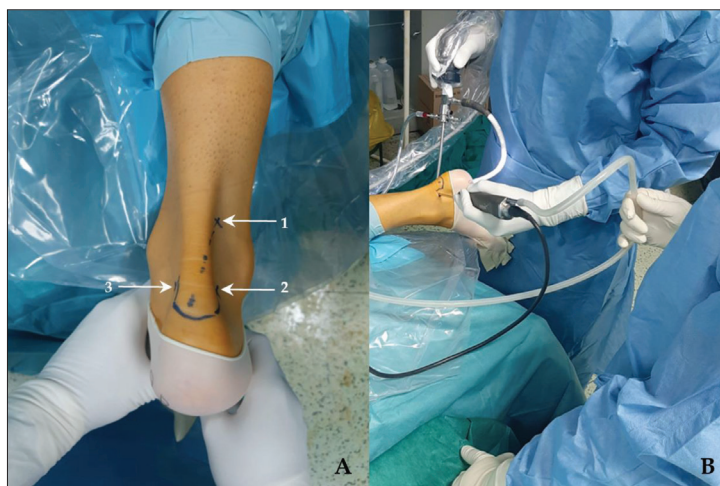


Figure 1. A) 1 – proximal posterolateral portal; 2 – distal posterolateral portal; 3 – distal posteromedial portal; B) operation procedure

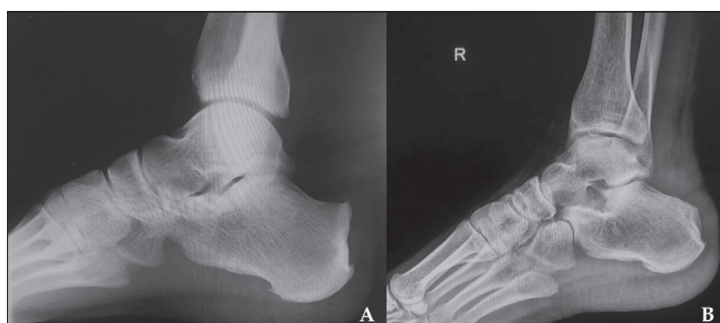

Figure 2. A) Pre-operative lateral radiograph; B) postoperative lateral radiograph

matory drugs and physical therapy. We did not decide to administer local corticosteroid therapy due to the possibility of Achilles tendon rupture, which was published in some earlier studies [6, 8, 9]. After the unsuccessful eight-month-long non-surgical treatment, we decided to perform the arthroscopic surgery with a three-portal technique, a slightly newer technic that has been in use for less than a decade [4, 9].

The endoscopic procedure was performed with the patient in a prone position under spinal anesthesia. The foot was positioned over the edge of the table, allowing a full range of motions of the ankle joint. A tourniquet was applied at the thigh. Preoperatively, bony prominences were marked, which served as landmarks for portals' placement.

The first two portals, the distal posteromedial portal (DPMP) and distal posterolateral portal (DPLP), were standard portals for hindfoot endoscopy. They were positioned at the level of the tip of the lateral malleolus, immediately adjacent to the Achilles tendon, and served as working portals. The third portal was proximal posterolateral portal (PPLP) and it served for the insertion of an optical instrument, visualization of the retrocalcaneal area and the ankle. The portal was positioned directly outward the Achilles tendon, 5 cm cranially to its attachment. Subcutaneous tissue was separated by a mosquito clamp, in order to enter caudally into the retrocalcaneal area by a blunt trocar. In this way, a passage was made for

an undisturbed, safe insertion of an endoscope into the ankle (Figure 1).

By inserting the endoscope through the PPLP, synovitis and retrocalcaneal bursitis were diagnosed. Excision of inflamed retrocalcaneal bursa and synovitis was performed using a shaver 4.5 mm in diameter (Arthrex GmbH, Munich, Germany) through the DPMP, which also enabled better ankle visualization. A contact between a bone spur at the posterosuperior aspect of the calcaneus with the Achilles tendon was discovered during the foot dorsiflexion. Using distal portals, the bone spur was removed by an abradar. The extent of bony resection was judged dynamically by performing a full range of passive motions of the ankle during the resection itself until there was no longer contact between the calcaneus and the Achilles tendon. Special attention was paid to avoiding iatrogenic Achilles tendon injury. Loose intra-articular bodies and tissue debris were removed. With the foot in full plantar flexion, a space was obtained for the insertion of the optical instrument immediately behind the Achilles tendon attachment, which made it possible to evaluate the local condition. Neither pathological substrate nor the signs of insertional tendinopathy were found.

After the tourniquet had been released and the ankle had been irrigated with saline solution, a hemostasis check was performed. The portals were closed with single sutures. Elastic bandage was applied on the operated leg for the first three postoperative days in accordance with recommendations of van Dijk et al. [4]. Standard perioperative thromboprophylaxis, antibiotic, and pain management therapy were administered.

On the first postoperative day, passive movements of plantar and dorsiflexion up to the pain threshold were started and the patient was discharged with advice for crutch-assisted walking and non-weight bearing on the operated leg. Leg elevation after activities was advised for the period of the first seven days, and avoiding conventional footwear for next eight weeks.

The first check-up was scheduled two weeks after the surgery. The patient was allowed partial, increment weight bearing on the operated leg in the following period, and functional physical therapy was suggested. Four weeks after the surgery, full weight bearing on the operated leg was allowed. After three months, the patient was allowed to gradually return to physical activities, and full return to sports was allowed after four months (Figure 2). The final check-up was carried out six months after the surgery. The patient did not report any previously presented symptoms even after performing sports activities.

This case report was approved by the institutional ethics committee, and written consent was obtained from the patient for the publication of the report and any accompanying images.

DISCUSSION

Since it was first described in detail in 1928, HD has represented a therapeutic challenge even for experienced surgeons. It is usually treated non-surgically, but when there is no improvement after six months, surgical treatment is considered. One of the main problems of the surgical treatment of HD is the amount of resection of the bony prominence. Excessive bone resection is the cause of greater post-operative problems in comparison to insufficient resection [10]. This excessive resection can cause disinsertion of the Achilles tendon and the calcaneus fracture [11]. Nesse and Finsen [10] stated that excessive resection can cause pain in the posterior aspect of the heel and ankle stiffness. Nonetheless, there are no clearly defined guidelines about the amount of bone resection during an endoscopic calcaneoplasty [1].

Open surgery usually includes either the resection of the posterosuperior aspect of the calcaneus or the wedge osteotomy of the calcaneus [10, 11]. Open surgery is a well-accepted method with good to excellent results [6, 12, 13, 14]. In cases with an accumulation of calcium salts inside the Achilles tendon or in the extremely painful insertional tendinopathies, "open" surgery has its advantages compared to the arthroscopic one [2, 15]. The most frequently used surgical approaches are the lateral and Achilles tendon-splitting approach. There are reports that open calcaneoplasty demonstrated a greater risk of the Achilles tendon attachment weakening, especially with osteoporotic bone, which can cause its avulsion during intensive rehabilitation [16]. Open surgery bears greater risks of post-operative complications, and the risks significantly decreased by the introduction of arthroscopically assisted surgery of an ankle [11, 17].

Arthroscopically assisted surgical treatment of the HD is followed by minor postoperative complications, smaller incision and scar, minor blood loss, smaller post-operative swelling and hematoma, sparing soft tissues, thus faster and easier recovery [3]. Since van Dijk performed the first arthroscopic resection of the posterosuperior aspect of the calcaneus in 1991, calling it endoscopic calcaneoplasty, this surgical procedure has been more and more accepted as a therapeutic procedure [11]. Arthroscopic surgery enables precise local decompression; thus, excessive bone resection is avoided, in addition to lesser risk of Achilles tendon avulsion [1]. Ortmann and McBryde [17] reported a case of Achilles tendon rupture three weeks after arthroscopic calcaneoplasty. Amount of the bone resection is shown to be lesser in arthroscopic calcaneoplasty [1, 6].

Initially, endoscopic procedures had been performed only through two portals, in a prone or supine position, which has been well documented [4, 11, 16, 17]. Arthroscopic calcaneoplasty through two portals have certain limitations. The small distance between DPMP and DPLP, with the need for frequent portal switching for adequate visualization and bony resection, causes technical

difficulties, increases the risk of both iatrogenic injury and instrument damage, and prolongs the time of surgery [9].

Arthroscopic calcaneoplasty with the three-portal technique has been used for the past decade due to the better visibility of retrocalcaneal bursa and bony prominence, the enlarged area for arthroscopic manipulation, and minimization of the risk of iatrogenic lesions [9]. The first two portals are standard posteromedial and posterolateral portals [18]. Our third portal was PPLP and it was used for visualization, positioned immediately lateral to the Achilles tendon, 5 cm cranially from its attachment, according to the surgical technique described by Wu et al [9]. The proximal posteromedial portal was not used due to the possibility of injury to the posterior tibial neurovascular structures [5]. Different radiographic measurements are used in the preoperative estimation of the amount of bony resection in HD [6]. The ideal preoperative planning does not exist, since every radiographic measurement has its disadvantages [1]. In our case, in addition to the preoperative positive parallel pitch line, the amount of a bony resection was determined intraoperatively by dynamic tests. Under the direct control of an arthroscope, we resected the bony prominence, until there was no longer contact with the Achilles tendon through a full range of ankle motion. The same method was used by other authors, and despite the positive postoperative parallel pitch lines in three operated heels, they had good results and satisfied patients [9].

According to published studies, in the early postoperative period, we advised the leg elevation for seven days, immediate postoperative passive and active motions up to the pain threshold, and avoidance of conventional footwear for the first eight weeks [9]. Due to the inexperience and the fact that we were getting familiar with the procedure, we kept our patient non-weight bearing on the operated leg for the first two weeks after the surgery. The avoidance of sports activities in the first three months was in accordance with the recommendations of the aforementioned studies [7, 9].

There were no iatrogenic injuries, intraoperative, or postoperative complications. We are aware that the postoperative period of monitoring is relatively short, but the good functional result and satisfied patient encourages us to continue with this surgical procedure and try to further refine and improve the surgical technique and the postoperative management.

The analysis of a larger number of patients and a longer period of monitoring would provide us with more relevant data, which would indicate if the arthroscopic calcaneoplasty with the three-portal technique is an adequate and cost-effective surgical method in the treatment of HD. Nevertheless, this paper gives insights into the possibilities of arthroscopic surgery of HD, especially with the three-portal technique.

Conflict of interest: None declared.

REFERENCES

- Lui TH, Lo CY, Siu YC. Minimally Invasive and Endoscopic Treatment of Haglund Syndrome. *Foot Ankle Clin.* 2019;24(3):515–31.
- Clanton TO, Waldrop NE. Athletic Injuries to the Soft Tissues of the Foot and Ankle. In: Coughlin MJ, Saltzman CL, Anderson RB, editors. *Mann's Surgery of the Foot and Ankle.* 9th ed. Philadelphia, PA: Elsevier; 2014. p. 1531–100.
- Opdam KTM, Zwiers R, Vroemen J, Siersevelt IN, Wiegerinck JJ, van Dijk CN. High patient satisfaction and good long-term functional outcome after endoscopic calcaneoplasty in patients with retrocalcaneal bursitis. *Knee Surg Sports Traumatol Arthrosc.* 2021;29(5):1494–501.
- Van Dijk CN, Van Dyk GE, Scholten PE, Kort NP. Endoscopic calcaneoplasty. *Am J Sports Med.* 2001;29(2):185–9.
- Retrouvey H, Silvanathan J, Bleakney RR, Anastakis DJ. A Case of Posterior Tibial Nerve Injury After Arthroscopic Calcaneoplasty. *J Foot Ankle Surg.* 2018;57(3):587–92.
- Cusumano A, Martinelli N, Bianchi A, Bertelli A, Marangon A, Sansone V. Transtendinous approach calcaneoplasty versus endoscopic calcaneoplasty for Haglund's disease. *Int Orthop (SICOT).* 2021;45(1):225–31.
- Yang YP, Li BH, Wei YX, Pan XY, Tao LY, An N, et al. Functional follow-up after endoscopic calcaneoplasty for Haglund's deformity using the biindex isokinetic muscle testing system: A case series. *Exp Ther Med.* 2020;20(3):2805–11.
- Vallone G, Vittorio T. Complete Achilles tendon rupture after local infiltration of corticosteroids in the treatment of deep retrocalcaneal bursitis. *J Ultrasound.* 2014;17(2):165–7.
- Wu Z, Hua Y, Li Y, Chen S. Endoscopic treatment of Haglund's syndrome with a three portal technique. *Int Orthop.* 2012;36(8):1623–7.
- Nesse E, Finsen V. Poor results after resection for Haglund's heel: Analysis of 35 heels in 23 patients after 3 years. *Acta Orthop Scand.* 1994;65(1):107–9.
- Scholten PE, Van Dijk CN. Endoscopic calcaneoplasty. *Foot Ankle Clin.* 2006;11(2):439–46.
- Pi Y, Hu Y, Guo Q, Jiang D, Xie X, Zhao F, et al. Open Versus Endoscopic Osteotomy of Posterolateral Calcaneal Tuberosity for Haglund Syndrome: A Retrospective Cohort Study. *Orthop J Sports Med.* 2021;9(4):23259671211001055.
- Pećina M, Bojanić I. Overuse injuries of the musculoskeletal system. 2nd ed. Boca Raton: CRC Press; 2003. pp. 270–3.
- Sammarco GJ, Taylor AL. Operative management of Haglund's deformity in the nonathlete: a retrospective study. *Foot Ankle Int.* 1998;19(11):724–9.
- Zhuang Z, Yang Y, Chhantyal K, Chen J, Yuan G, Ni Y, et al. Central Tendon-Splitting Approach and Double Row Suturing for the Treatment of Insertional Achilles Tendinopathy. *Biomed Res Int.* 2019;2019:4920647.
- Pfeffer G, Gonzalez T, Zapf M, Nelson TJ, Metzger MF. Achilles Pullout Strength After Open Calcaneoplasty for Haglund's Syndrome. *Foot Ankle Int.* 2018;39(8):966–9.
- Ortmann FW, McBryde AM. Endoscopic bony and soft-tissue decompression of the retrocalcaneal space for the treatment of Haglund deformity and retrocalcaneal bursitis. *Foot Ankle Int.* 2007;28(2):149–53.
- Murphy GA. Arthroscopy of the Foot and Ankle. In: Azar FM, Beatz JH. *Campbell's Operative Orthopaedics.* 14th ed. Philadelphia, PA: Elsevier; 2021. pp. 2552–75.

Ресекција Хаглундовога деформитета помоћу артроскопске технике са три портала

Немања Јовановић¹, Филип Маљковић¹, Лазар Мичета^{1,2}, Немања Славковић^{1,2}, Бранислав Кривокапић^{1,2}

¹Институт за ортопедију „Бањица“, Београд, Србија;

²Универзитет у Београду, Медицински факултет, Београд, Србија

САЖЕТАК

Увод Хаглундов деформитет представља реактивно увећање постеросупериорног аспекта калканеуса и често узрокује бол који може значајно реметити свакодневне активности. Ако се стање болесника не побољша после шестомесечног неоперативног лечења, у разматрање се узима хируршко лечење. Иако се Хаглундов деформитет успешно лечи ендоскопском калканеопластиком применом технике кроз два портала, одлучили смо да применимо нешто новију технику – артроскопску хирургију применом технике са три портала.

Приказ болесника Болесник са клинички и радиографски потврђеним Хаглундовим деформитетом оперисан је артроскопском калканеопластиком применом технике са три портала. Постоперативни опоравак протекао је без компли-

кација и ход са пуним ослонцем је дозвољен после четири недеље. Потпуни повратак спортским активностима био је дозвољен после четири месеца.

Закључак Артроскопска калканеопластика применом технике са три портала показала се као сигурна и исплатива хируршка метода у лечењу Хаглундовога деформитета. У литератури још увек нема довољно података о овој врсти хируршког лечења, али су добри постоперативни функционални резултати изузетно охрабрујући јер ова хируршка техника омогућава бржи опоравак и мање постоперативних компликација.

Кључне речи: ендоскопска калканеопластика; стопало; Хаглундова болест; ретрокалканеални бурзитис