

## ORIGINAL ARTICLE / ORIGINALNI RAD

# Soft tissue profile changes during treatment of patients with class II malocclusion

Jovana Milutinović<sup>1</sup>, Zorana Stamenković<sup>1</sup>, Ksenija Zelić<sup>2</sup>, Nemanja Marinković<sup>1</sup>, Nenad Nedeljković<sup>1</sup><sup>1</sup>University of Belgrade, School of Dental Medicine, Department of Orthodontics, Belgrade, Serbia;<sup>2</sup>University of Belgrade, Faculty of Medicine, Institute of Anatomy, Laboratory for Anthropology, Belgrade, Serbia**SUMMARY**

**Introduction/Objective** The class II malocclusion results in disbalanced facial harmony, primarily noticeable in the profile and the lower facial third. Aside from skeletal evaluation, orthodontic diagnosis and treatment planning should include facial soft tissue analysis. The aim of the study was to identify the soft tissue profile outcomes of orthodontic treatment of class II, division 1 malocclusion patients and to determine if these changes are related to different treatment protocols.

**Methods** The first group was the non-extraction group (25 patients) initially treated with the Herbst appliance, and the second group was four premolars extraction group (25 patients) treated with a multibracket appliance. The patients' cephalograms and pre- and post-treatment profile photographs were used.

**Results** The improvement in the non-extraction group was evident in the decrease of the nasomental angle, the angle representing the projection of the upper lip to the chin, as well as the upper lip angle. In the extraction group, the nasolabial angle showed a significant increase. Soft tissue variables showed significant differences between the groups: the total facial angle or facial convexity including the nose and the angle presenting the projection of the upper lip to the chin.

**Conclusion** The patients treated without extractions showed a significant improvement of the convex profile and favorable soft tissue changes in the lower third of the face.

**Keywords:** facial esthetics; class II malocclusion; facial convexity; profile changes; soft tissue profile

**INTRODUCTION**

The improvement of facial features is the patient's main aspiration when starting an orthodontic treatment, and thus of primary importance for clinicians. An attractive facial appearance affects social acceptance and psychological well-being, which has a profound effect on a person's self-esteem and social adjustment ability [1]. Soft tissue of the face, together with the underlying dentoskeletal tissues, determines the facial features of a person [2]. Orthodontists, maxillofacial, and plastic surgeons are expected to achieve not only functional, but also esthetic goals for their patients, both equally important [3].

Patients with class II, division 1 malocclusion have undesirable facial esthetics caused by increased overjet and convex profile. Previous studies showed that the convex profile is one of the least desirable features of the face [4]. Patients with class II, division 1 malocclusion are unsatisfied with their smile and facial look, especially in their teenage years, since they are often being perceived by peers as unattractive [5]. As self-esteem is strongly influenced by facial appearance, solving this problem is of primary importance in achieving esthetic treatment goals. Therefore, improvement of facial appearance in teenage patients could improve their quality of life through their most vulnerable years [4, 5].

Orthodontists should comprehensively understand the importance of developing an individualized treatment plan, adjusted to the patient's specific dental and skeletal problems, needs, and desires. Class II, division 1 malocclusion can be treated with functional or fixed functional appliances combined with the multibracket appliance, with or without extractions. Small skeletal discrepancies may only need multibracket appliance treatment for the correction of existing malocclusion and teeth alignment [6]. On the other hand, more severe skeletal discrepancies may require an orthognathic surgical treatment to modify the position and length of skeletal structures, to obtain better esthetic results [7]. Despite the numerous studies conducted on the consequences of extractions, it is still a question of debate among orthodontists. Some investigators reported flattening of the soft tissue profile after extraction treatment, while others claim no such effect [8–11].

Although cephalometric analysis is one of the most common parts of diagnosis and treatment planning among orthodontists, the validity of cephalometric measurements has been questioned [3]. Several authors proposed lateral photographs for the esthetic facial profile evaluation [12, 13, 14].

This study, therefore, aimed to identify the soft tissue profile outcomes of the orthodontic treatment of class II, division 1 malocclusion. A further aim was to determine if soft tissue

**Received • Примљено:**  
September 13, 2021

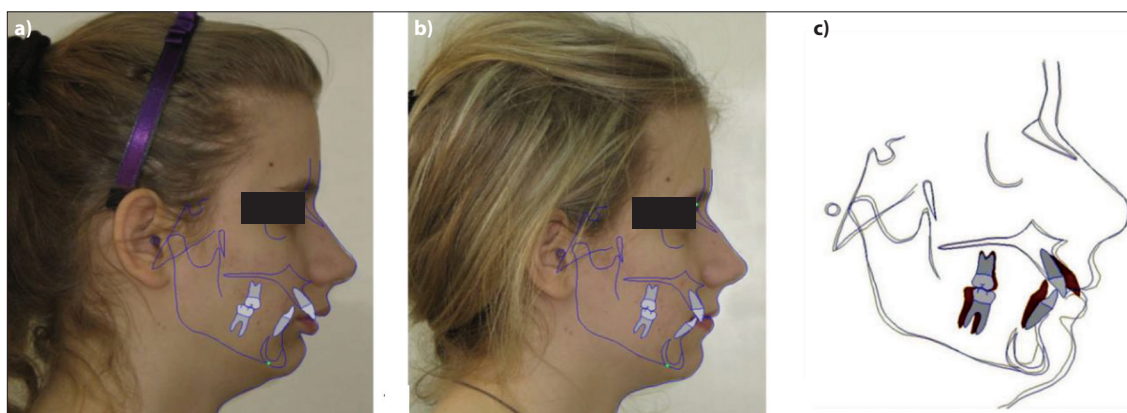
**Revised • Ревизија:**  
May 13, 2022

**Accepted • Прихваћено:**  
May 14, 2022

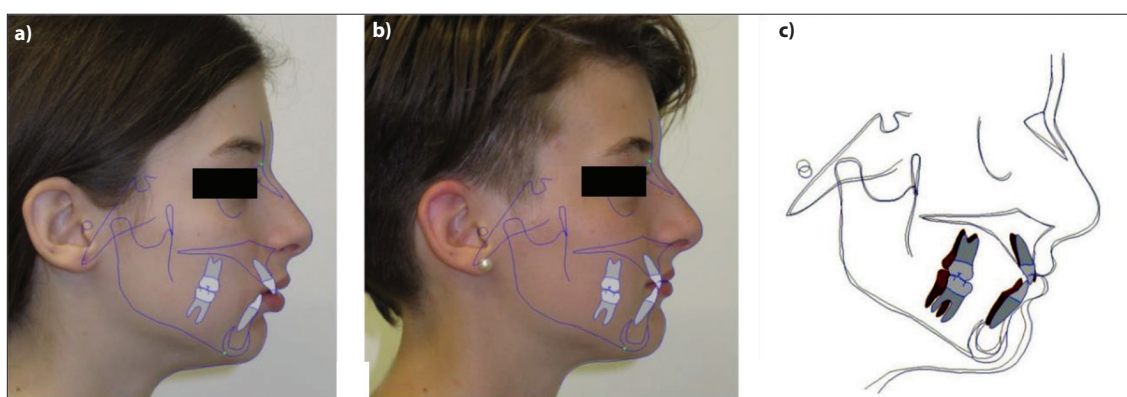
**Online first:** May 18, 2022

**Correspondence to:**

Nenad NEDELJKOVIĆ  
Gastona Gravijea 2  
11000 Belgrade, Serbia  
[nenad.nedeljkovic@stomf.bg.ac.rs](mailto:nenad.nedeljkovic@stomf.bg.ac.rs)



**Figure 1.** Non-extraction case; superimposition of the cephalometric drawing to the patient's profile: a) before treatment, b) after treatment, c) superimposition of the cephalometric drawings before (brown) and after (gray) treatment with visible changes of the soft tissue profile



**Figure 2.** Extraction case; superimposition of the cephalometric drawings to the patient's profile: a) before treatment, b) after treatment, c) superimposition of the cephalometric drawings before (brown) and after (gray) treatment with visible changes of the soft tissue profile

profile changes are connected with different treatment protocols. The hypothesis underlying this investigation is that orthodontic treatment of class II, division 1 malocclusion changes the soft tissue profile, and moreover, that those changes depend on different treatment protocols.

## METHODS

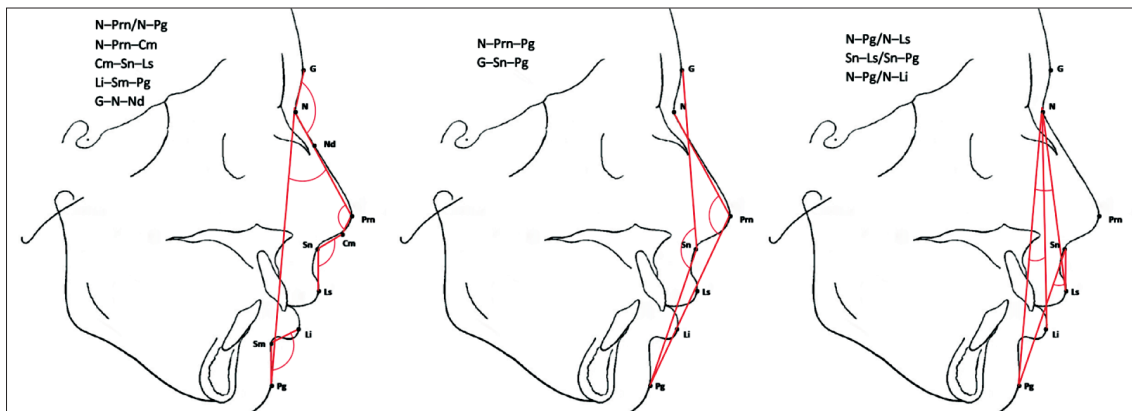
The sample for this study consisted of 50 Caucasian patients (22 males; 28 females), with a mean age of  $15.8 \pm 1.4$  years, treated at the Clinic for Orthodontics between 2014 and 2018. This retrospective study was approved by the Ethics Committee of the University (Protocol number 46/15) and informed consent was obtained from the patients' parents/guardians. All subjects were selected according to the following inclusion criteria (pretreatment): full permanent dentition (excluded third molars), class II molar occlusion, division 1 (with characteristic convex profile, deep mentolabial sulcus, retruded chin, and reverted lower lip), overjet of more than 7 mm, moderate irregularity of anterior crowding according to the Little's Irregularity Index [15], and post-pubertal stage of skeletal maturity (CS6) [16]. Exclusion criteria encompassed patients with a systemic disease, craniofacial anomalies, patients with vertical growth pattern, impacted teeth, and

poorly visible cephalograms. After successful orthodontic treatment, all the patients achieved class I occlusion, and received a vacuum-formed retainer on the same day the appliance was removed.

The subjects were divided into two study groups.

1. The first group consisted of 25 patients treated with the combined two-phase therapy. The first phase included the cast splint Herbst appliance type I for an average period of seven months. Afterwards, each patient underwent a standardized non-extractive treatment protocol. The treatment duration was on average 20 months. The skeletal and dentoalveolar changes in this group of patients are visible with superimposition in Figure 1.
2. The second group consisted of 25 patients treated with four premolars extractive treatment protocol, followed by class II intermaxillary elastic. The treatment duration was on average 19 months. The skeletal and dentoalveolar changes in this group of patients are visible with superimposition in Figure 2.

The patients' pre-treatment and post-treatment profile photographs were used [4]. The right-side profile photographs were taken in the standing position, in central occlusion. The subjects' Frankfort horizontal plane was kept as parallel to the floor as possible during the taking of the photographs. Before every recording, the operator ensured



**Figure 3.** Soft tissue profile landmarks and angular parameters

that the subject's forehead, neck, and ear were clearly visible [6]. The photographs were then printed, and the soft tissue landmarks were identified. The landmarks used in this investigation were the following: glabella (G), nasion (N), nasal dorsum (Nd), pronasale (Prn), columella (Cm), subnasale (Sn), labiale superior (Ls), labiale inferior (Li), supramentale (Sm), pogonion (Pg) [10]. Afterwards, the angular parameters were determined on each photo and used in evaluating soft tissue profile changes. The photogrammetric analysis was based on comparing changes in parameter values before and after the treatment, regardless of the average values for these parameters. These measurements are illustrated in Figure 3. Table 1 provides the definition of angular measurements used in the study. The whole sample was measured by one researcher (JM), repeated once again after two months. Also, all measurements were performed by the second researcher (NN). This was done to evaluate intra- and inter-observer reliability. Radiographic analyses rely on skeletal and dental measurement, whereas soft tissue facial measurements are less emphasized. Therefore, for providing a complete overview of changes during and after orthodontic treatment, photogrammetric analysis has been used.

**Table 1.** Definitions of angular measurements

Angular measurement	Definition
N-Prn-Pg (°)	Nasomental angle
N-Prn-Cm (°)	Nose tip angle
Cm-Sn-Ls (°)	Nasolabial angle
Li-Sm-Pg (°)	Mentolabial angle
G-N-Nd (°)	Nasofrontal angle
N-Prn-Pg (°)	Total facial angle or facial convexity including the nose
G-Sn-Pg (°)	Facial angle or angle of facial convexity excluding the nose
N-Pg-Ls (°)	Projection of the upper lip to chin
Sn-Ls-Pg (°)	Upper lip angle
N-Pg-Li (°)	Projection of the lower lip to chin

### Statistical analysis

The collected data were subjected to statistical analysis using SPSS Statistics for Windows, Version 17.0 (SPSS Inc.,

Chicago, IL, USA). The Kolmogorov-Smirnov test was applied to test whether the data distribution fits the probability density function, also known as Gaussian function or the bell curve. Subsequently, had the test not rejected the assumed normal distribution, the parametric tests would have been used. Paired-sample t-test was used for intragroup comparisons. For testing the differences in all parameter values between groups, the two-sample t-test was used. In all analyses, the significance level was set at 0.05. The Kolmogorov-Smirnov test showed normality of distribution of the obtained data in both groups. In order to evaluate intra- and inter-observer reliability, intra-class correlation coefficient (ICC) was calculated.

### RESULTS

Intra- and inter-observer agreement was found to be excellent (ICC = 0.983 for intra-observer, ICC = 0.974 inter-observer agreement). Angular measurements in the first group treated with the Herbst appliance and without extractions are demonstrated in Table 2. Several statistically significant profile changes could be observed. The nasomental angle (N-Prn-Pg) decreased significantly ( $\bar{x} = -1 \pm 1.0$ ;  $p = 0.02$ ); furthermore, the angle representing projection of the upper lip to the chin (N-Pg-Ls)

**Table 2.** Descriptive statistics of the soft tissue profile variables in Herbst/non-extraction group

Variable	Herbst/non-extraction treatment protocol			
	Before Mean ± SD	After Mean ± SD	Difference Mean ± SD	p-value change over time
N-Prn-Pg	35.93 ± 2.69	34.93 ± 2.81	-1 ± 1.01	0.02*
N-Prn-Cm	80.37 ± 5.61	78.93 ± 6.1	-1.44 ± 0.19	0.41
Cm-Sn-Ls	107 ± 6.64	108.33 ± 9.88	1.33 ± 2.81	0.01*
Li-Sm-Pg	107.06 ± 15.65	119.74 ± 20.16	12.68 ± 12.57	0.02*
G-N-Nd	141.54 ± 7.38	140.43 ± 6.84	-1.11 ± 0.19	0.08
N-Prn-Pg	121.8 ± 3.91	124.17 ± 7.3	2.37 ± 0.95	0.18
G-Sn-Pg	159.56 ± 5.55	163.41 ± 7.07	3.85 ± 4.43	0.05
N-Pg-Ls	10.46 ± 1.46	8.35 ± 2.54	-2.11 ± 2.04	0.01*
Sn-Ls-Pg	21.33 ± 5.17	16.39 ± 5.77	-4.94 ± 10.1	0.01*
N-Pg-Li	4.15 ± 2.33	6.59 ± 10.75	2.44 ± 1.3	0.29

\*Statistically significant differences at  $p < 0.05$

**Table 3.** Descriptive statistics of the soft tissue profile variables in the extraction group

Extraction treatment protocol				
Variable	Before	After	Difference	p-value change over time
	Mean ± SD	Mean ± SD	Mean ± SD	
N-Prn-Pg	35.68 ± 3.01	36.3 ± 2.94	0.62 ± 3.73	0.21
N-Prn-Cm	78.62 ± 6.5	79.92 ± 7.97	1.3 ± 3.44	0.56
Cm-Sn-Ls	103.26 ± 7.39	107.22 ± 10.16	3.96 ± 4.43	0.03*
Li-Sm-Pg	112.18 ± 24.18	119.92 ± 15.86	7.74 ± 2.89	0.33
G-N-Nd	138.04 ± 6.79	136.28 ± 9.18	-1.76 ± 2.04	0.29
N-Prn-Pg	123.96 ± 6.2	124.76 ± 7.58	0.8 ± 2.1	0.29
G-Sn-Pg	162.88 ± 6.45	163.3 ± 3.92	0.42 ± 1.61	0.52
N-Pg-Ls	9.94 ± 3.32	8.96 ± 1.88	-0.98 ± 1.01	0.07
Sn-Ls-Pg	20.24 ± 4.65	18.38 ± 3.46	-1.86 ± 1.72	0.06
N-Pg-Li	4.62 ± 1.71	5.36 ± 2.07	0.74 ± 1.47	0.08

\*Statistically significant differences at  $p < 0.05$

showed a significant decrease ( $\bar{x} = -2.11 \pm 2.04$ ;  $p = 0.01$ ). The upper lip angle showed a significantly large decrease ( $\bar{x} = -4.94 \pm 10.1$ ;  $p = 0.01$ ) over time in the non-extraction group of patients. On the other hand, the nasolabial angle (Cm-Sn-Ls) increased significantly in this group of patients ( $\bar{x} = +1.33 \pm 2.81$ ;  $p = 0.01$ ). Moreover, the mentolabial angle (Li-Sm-Pg) showed a significantly large increase ( $\bar{x} = +12.68 \pm 12.57$ ;  $p = 0.02$ ).

Changes in soft tissue profile variables in the extraction group of patients are presented in Table 3. This group showed a greater significant increase in nasolabial angle (Cm-Sn-Ls) ( $\bar{x} = +3.96 \pm 4.43$ ;  $p = 0.03$ ). However, no significant differences were detected in other soft tissue variables.

Table 4 describes intergroup comparisons of the soft tissue variables. Only two soft tissue variables showed significant differences between two groups: total facial angle or facial convexity including the nose (N-Prn-Pg) increased significantly ( $\bar{x} = -2.09 \pm 1.1$ ;  $p = 0.04$ ). As for the angle presenting projection of the upper lip to chin (N-Pg-Ls), its value showed a significant decrease ( $\bar{x} = +0.65 \pm 3.73$ ;  $p = 0.01$ ).

**Table 4.** Descriptive statistics of the soft tissue profile variables comparing both treatment groups

Herbst/non-extraction versus extraction treatment protocol				
Variable	Before	After	Difference	p-value change over time
	$\Delta$ Mean ± SD	$\Delta$ Mean ± SD	Mean ± SD	
N-Prn-Pg	-1.04 ± 3.08	1.04 ± 2.25	2.08 ± 2.92	0.33
N-Prn-Cm	-1.08 ± 5.89	1.23 ± 4.3	2.31 ± 2.81	0.71
Cm-Sn-Ls	-3.52 ± 7.04	-1.45 ± 8.26	2.07 ± 3.71	0.34
Li-Sm-Pg	-8.39 ± 17.35	-11.95 ± 21.54	-3.56 ± 7.32	0.61
G-N-Nd	0.96 ± 6.69	1.34 ± 4.45	0.38 ± 1.46	0.51
N-Prn-Pg	-0.52 ± 5.18	-2.61 ± 5.84	-2.09 ± 1.1	0.04*
G-Sn-Pg	-0.78 ± 5.69	-3.89 ± 4.61	-3.11 ± 2.29	0.05
N-Pg-Ls	1.46 ± 2.2	2.11 ± 2.25	0.65 ± 3.73	0.01*
Sn-Ls-Pg	1.78 ± 4.77	5.09 ± 5	3.31 ± 0.24	0.11
N-Pg-Li	-0.72 ± 1.14	-2.66 ± 10.39	-1.94 ± 2.04	0.15

\*Statistically significant differences at  $p < 0.05$

## DISCUSSION

The success of orthodontic treatment is closely related to facial appearance improvement. A balanced soft tissue profile is an important factor to achieve during orthodontic treatment [2]. This type of malocclusion is frequently reported as the irregularity that alters facial proportions, symmetry, and balance. Thus, correction of facial features will lead not only to facial profile correction, but also to long-term psychosocial well-being of patients [5]. Orthodontic treatment modifies the position, length, and relation between skeletal and dentoalveolar structures, and subsequently, facial expressions and esthetics are modified and enhanced (these effects are shown in Figures 1 and 2). Facial harmony can often be described as dependent on morphological relations, and proportions between three facial structures – nose, lips, and chin [17]. The facial profile consists of five facial prominences – the forehead, nose, lips, chin, and submental-cervical region.

The nasomental angle (N-Prn-Pg), or nasal prominence angle, is in the 20–30° range in class I patients [18], whereas the value is increased in class II patients. In this study, the nasomental angle showed a statistically significant decrease in the non-extraction group of patients, although it was not clinically relevant (-1°). This favorable outcome could have occurred as a result of anterior movement of the soft tissue point pogonion (Pg). This movement promoted positive changes on the soft tissue profile and was reported also by do Rego et al. [19].

Significant improvements in facial profile were recorded in the first group of patients (treated with the Herbst appliance without extractions). In particular, the nasolabial (Cm-Sn-Ls) and mentolabial (Li-Sm-Pg) angles showed significant increase after the treatment. The nasolabial angle (Cm-Sn-Ls) can be changed with both orthodontic and surgical treatment. It plays an important role in a facial profile appearance, and in some cases, it can be used as a guideline for the extraction decision. According to a study by Bergman [20], regardless of the type of treatment needed for the patients (whether it is surgical or orthodontic correction), this angle should be  $102 \pm 8^\circ$ . After orthodontic treatment, this angle increased significantly, since the upper lip moved backwards and downwards, and its prominence has been decreased, mostly due to retrusion of the upper incisors. The nasolabial angle also showed a significant increase in the second group of patients, treated with premolar extractions. The increase of this angle was also reported by Iared et al. [21], who confirmed that a backward movement of the upper lip occurred because of orthodontic treatment with extraction of premolars.

The mentolabial angle (Li-Sm-Pg) also showed great variability. A more pronounced mentolabial angle can be seen in class II and vertical maxillary deficiency cases. In both groups of patients, this angle has been increased after the treatment, as a result of achieving a balanced dentoalveolar relation, due to upper incisors retrusion [22].

Significant improvements in facial profile concerning the chin and the upper lip balance were recorded in the

first group of patients. In particular, the angle determining the projection of the upper lip to the chin (N–Pg–Ls), as well as the upper lip angle (Sn–Ls–Pg), showed a significant reduction. This result is related to a less pronounced upper lip. The value of these angles showed a statistical significance in the non-extraction group, given the fact that point Pg moved forward, while point Ls moved backward, which is an expected result of treatment with the Herbst appliance [23]. Moreover, this is also a result of decreasing of the upper lip prominence, as a consequence of upper incisors retrusion, in a ratio of 1:3. Many authors confirmed the relation between the upper lip position and the upper incisors retrusion, in the ratio of 1:3 [24, 25]. Furthermore, esthetical modification depends on the upper and lower incisors position, as well as on the change of the position and development of the lower jaw [26].

The angle N–Pg–Ls showed a statistically significant difference comparing the two groups of patients. The lower lip is the adjacent esthetic subunit to the chin, and its features play an important role in determining facial esthetics in the lower third of the face [27]. As such, the prominence of the lower lip may influence the perception of chin prominence and thus the overall management plan in terms of camouflage vs. orthognathic surgery and extraction vs. non-extraction decisions [21, 28, 29].

Therefore, a change in the lower lip position and consequent change in the lip/chin relation influences facial esthetics, as these entities determine the profile type. As mentioned, the facial profile in patients with this type of malocclusion is altered and considered unattractive before treatment. As a result of improvement of these proportions and of the profile, the esthetic perception is changed from unattractive to attractive, which is one of the main reasons why patients seek orthodontic treatment [30].

The profile angles are used to assess convexity or concavity of the facial profile. The angle of facial convexity excluding the nose or facial angle (G–Sn–Pg) is supposed to

be in the range of 165–175° [20]. This angle is decreased in class II and increased in class III. In our sample, all patients had a decreased value of this angle before treatment. After treatment, the facial angle was increased in both groups of patients – however, not significantly. The favorable outcome, not statistically significant, yet esthetically relevant, was the profile strengthening caused by reduction of facial convexity, which had been one of the main reasons of the patients' dissatisfaction.

## CONCLUSION

Photogrammetric analysis is a simple and valid method to assess orthodontic treatment effects on the soft tissue profile. This study confirms previous reports on the improvement of the convex profile, and favorable soft tissue changes at the lower third of the face, after the orthodontic treatment of class II, division 1 malocclusions. Patients treated with the Herbst appliance without extractions presented better results in facial profile parameters than the group of patients treated with premolar extractions. This result is important for orthodontists treating patients with this type of malocclusion, as facial esthetics improvement is a key factor for determining the treatment protocol and achieving patients' satisfaction.

## ACKNOWLEDGEMENTS

This work was previously posted as a preprint on Research Square.

This work was supported by the Ministry of Education, Science and Technological Development of the Republic of Serbia (Grant No. III41007).

**Conflict of interest:** None declared.

## REFERENCES

- Akter L, Hossain M. Angular photogrammetric soft tissue facial profile analysis of Bangladeshi young adults. *APOS Trends Orthod.* 2017;7(6):279–86.
- Santori F, Masedu F, Ciavarella D, Staderini E, Chimenti C, Tepedino M. Effect of Class II functional treatment on facial attractiveness, as perceived by professionals and laypeople. *Sci Rep.* 2021;11(1):13989.
- Cunningham SJ, Feinmann C. Effect of surgery-first orthognathic approach on oral health-related quality of life. *Angle Orthod.* 2020;90(5):723–33.
- Pavoni C, Gazzani F, Franchi L, Roberto S, Lione R, Cozza P. Soft tissue facial profile in Class III malocclusion: long-term post-pubertal effects produced by the Face Mask Protocol. *Eur J Orthod.* 2019;41(5):531–6.
- Tsichlaki A, Adcock R, Fleming PS. A cross-sectional evaluation of the impact of Class II Division 1 malocclusion in treated and untreated adolescents on oral health-related quality of life. *Am J Orthod Dentofacial Orthop.* 2021;160(1):58–65.
- Cacciatore G, Ugolini A, Sforza C, Gbinigie O, Plüddemann A. Long-term effects of functional appliances in treated versus untreated patients with Class II malocclusion: A systematic review and meta-analysis. *PloS one.* 2019;14(9):e0221624.
- Vale F, Queiroga J, Pereira F, Ribeiro M, Marques F, Travassos R, et al. A New Orthodontic-Surgical Approach to Mandibular Retrognathia. *Bioengineering (Basel).* 2021;8(11):180.
- Almurtadha RH, Alhammadi MS, Fayed MMS, Abou-El-Ezz A, Halboub E. Changes in Soft Tissue Profile After Orthodontic Treatment with and without Extraction: A Systematic Review and Meta-analysis. *J Evid Based Dent Pract.* 2018;18(3):193–202.
- Pradeep KD, Shwetha GS, Durkar Sachin S, Sumitra R, Sarkar Nilanjana B, Biradar Neha V. The influence of extraction treatment on soft-tissue cephalometric measurements – A retrospective study. *J Adv Med Dent Scie Res.* 2020;8(5):75–81.
- Hoi-Jeong L, Kwang-Taek Ko K, Hyeon-Shik H. Esthetic impact of premolar extraction and nonextraction treatments on Korean borderline patients. *Am J Ortod Dentofacial Orthop.* 2008;133(4):524–31.
- Solem RC, Marasco R, Guitierrez-Polido L, Nielsen I, Kim SH, Nelson G. Three-dimensional soft-tissue and hard-tissue changes in the treatment of bimaxillary protrusion. *Am J Ortod Dentofacial Orthop.* 2013;144(2):218–28.
- Evrard A, Tepedino M, Cattaneo PM, Cornelis MA. Which factors influence orthodontists in their decision to extract? A questionnaire survey. *J Clin Exp Dent.* 2019;11(5):e432–38.
- Johal A, Hasan E, Zou LF, Wong F, Shahdad S, Al-Klash R. The influence of mild versus severe hypodontia on facial soft tissues?

- A three-dimensional optical laser scanning-based cohort study. *J Orthod.* 2021;48(1):33–41.
14. Moshkelgosh V, Fathinejad S, Pakizeh Z, Shamsa M, Golhari A. Photographic facial soft tissue analysis by means of linear and angular measurements in an adolescent Persian population. *Open Dent J.* 2015; 9:346–56.
  15. Little RM. The irregularity index: a quantitative score of mandibular anterior alignment. *Am J Orthod.* 1975;68(5):554–63.
  16. Baccetti T, Franchi L, McNamara Jr JA. The cervical vertebral maturation (CVM) method for the assessment of optimal treatment timing in dentofacial orthopedics. *Sem Orthod.* 2005;11(3):119–29.
  17. Muharib SI, Alomar RK, Alolaiq RA, Alfadhel AA, Salamah FS. Indicators and Preferences of Facial Profile and Aesthetic. *J Dent Oral Sci.* 2021;3(2):18.
  18. Lines PA, Lines RR, Lines CA. Profilemetrics and facial esthetics. *Am J Ortod Dentofacial Orthop.* 1978;73(6):648–57.
  19. do Rego MV, Martinez EF, Coelho RM, Leal LM, Thiesen G. Perception of changes in soft-tissue profile after Herbst appliance treatment of Class II Division 1 malocclusion. *Am J Ortod Dentofacial Orthop.* 2017;151(3):559–64.
  20. Bergman RT. Cephalometric soft tissue facial analysis. *Am J Ortod Dentofacial Orthop.* 1999;116(4):373–89.
  21. Iared W, da Silva EM, Iared W, Macedo CR. Esthetic perception of changes in facial profile resulting from orthodontic treatment with extraction of premolars: a systematic review. *J Am Dent Assoc.* 2017;148(1):9–16.
  22. Deen E, Woods MG. Rotational effects of Class II Division 1 treatment with the Herbst appliance and fixed appliances in growing subjects with different vertical patterns. *J World Fed Orthod.* 2019;8(1):18–23.
  23. Milutinović J, Nedeljković N, Korolija N, Miličić B. Facial profile esthetics change of class II malocclusion patients treated with the Herbst appliance as perceived by orthodontists and laypersons. *Srp Arh Celok Lek.* 2017;145(9–10):446–51.
  24. Shen LH, Xie TY, Jiang RP, Jiang YR, Chen G, Xu TM, et al. Measurement of three-dimensional changes in lip vermilion in adult female patients after orthodontic extraction: a retrospective longitudinal study. *Head Face Med.* 2021;17(1):9.
  25. Lin PT, Woods MG. Lip curve changes in males with premolar extraction or nonextraction treatment. *Aust Orthod J.* 2004;20(2):71–86.
  26. Jiang X, Cao Z, Yao Y, Zhao Z, Liao W. Aesthetic evaluation of the labiolingual position of maxillary lateral incisors by orthodontists and laypersons. *BMC Oral Health.* 2021;21(1):42.
  27. Pişiren AB, Arman-Özçırpıcı A, Tunçer NI. Assessing the influence of chin prominence on profile esthetics: A survey study. *J Cranio-Maxillofac Surg.* 2018;46(4):628–34.
  28. Modarai F, Donaldson JC, Naini FB. The influence of lower lip position on the perceived attractiveness of chin prominence. *Angle Orthod.* 2013;83(5):795–800.
  29. Rocha AD, Casteluci CEV, Ferreira FPC, Conti AC, Almeida MR, Almeida-Pedrin RR. Esthetic perception of facial profile changes after extraction and nonextraction Class II treatment. *Braz Oral Res.* 2020;34:e003.
  30. Prado LH, Previato K, Delgado RZR, Nelson Filho P, Bezerra Segato RA, Nakane Matsumoto MA, et al. Adolescents' perception of malocclusion, their motivations, and expectations concerning the orthodontic treatment. Is it all about attractiveness? A qualitative study. *Am J Orthod Dentofac Orthop.* 2022;161(4):e345–52.

## Мекоткивне промене профила током терапије пацијената са II класом малоклузије

Јована Милутиновић<sup>1</sup>, Зорана Стаменковић<sup>1</sup>, Ксенија Зелић<sup>2</sup>, Немања Маринковић<sup>1</sup>, Ненад Недељковић<sup>1</sup>

<sup>1</sup>Универзитет у Београду, Стоматолошки факултет, Клиника за ортопедију вилица, Београд, Србија;

<sup>2</sup>Универзитет у Београду, Медицински факултет, Анатомски институт, Лабораторија за антропологију, Београд, Србија

### САЖЕТАК

**Увод/Циљ** Малоклузије II класе доводе до нарушавања хармоније лица и погоршаног изгледа профила и доње трећине лица. Ортодонтска дијагноза и план терапије треба да укључе и анализу мекоткивног профила.

Циљ рада је био да се одреде промене меких ткива профила пацијената са малоклузијом II класе, I. одељења, као и да се утврди да ли ове промене зависе од начина лечења.

**Метод** Прва група од 25 болесника лечена је Хербстовим апаратом без вађења зуба. Друга група од 25 болесника лечена је фиксним апаратом са вађењем четири премолара. Мерења су вршена на профилним снимцима главе и фотографијама пре и после терапије.

**Резултати** Побољшан је изглед меких ткива профила прве групе болесника у виду смањења назоменталног угла, као и углова који говоре о положају горње усне. У другој групи пацијената значајно је повећан назолабијални угао. Статистички значајна разлика поређењем обе групе болесника нађена је за угао конвекситета лица укључујући нос и угао горње усне.

**Закључак** Разлика у изгледу мекоткивног профила постојала је у групи пацијената лечених без вађења зуба у виду смањења конвекситета профила и промена у доњој трећини лица.

**Кључне речи:** естетика лица; малоклузија II класе; конвексно лице; мекоткивни профил