



ORIGINAL ARTICLE / ОРИГИНАЛНИ РАД

Differences in anthropometric measures of the orbit between Serbian and Roma population of the Central Serbia

Maja Vulović¹, Ivana Živanović-Mačuzić¹, Radmila Balaban-Đurević², Aleksandar Radunović³, Milan Aksić⁴, Vladimir Čolović⁵, Radiša Vojinović⁶

¹University of Kragujevac, Faculty of Medical Sciences, Department of Anatomy, Kragujevac, Serbia;

²University of East Sarajevo, Faculty of Medicine in Foča, Department of Preclinical Sciences (Anatomy), Republic of Srpska, Bosnia and Herzegovina;

³Military Medical Academy, Clinics for Orthopedic Surgery, Belgrade, Serbia;

⁴University of Belgrade, Faculty of Medicine, Niko Miljanić Institute of Anatomy, Belgrade, Serbia;

⁵University of Kragujevac, Faculty of Medical Sciences, Kragujevac, Serbia;

⁶University of Kragujevac, Faculty of Medical Sciences, Department of Radiology, Kragujevac, Serbia

SUMMARY

Introduction/Objectives The shape and size of the orbital cavity are important parameters in planning surgical interventions and have significance in anthropology and forensic medicine.

The aim of this study was to determine the morphometric characteristics of orbital cavity in Serbian population and to examine if there are differences in examined parameters between Serbs and the Roma Community of Serbia.

Methods Using computer tomography and subsequent multiplanar reconstruction we analyzed orbits from 76 Serbian and 18 Roma healthy volunteers. There was no significant difference in age between the ethnicities.

Results The height and width of the left orbit and the height of the right orbit were significantly higher in Roma group, whereas the width of the right orbit was not statistically different between ethnicities. Orbital indices, however, for both left and right orbit did not significantly differ between Serbian and Roma examinees. Right orbital volume did not differ between the groups, but left orbits had significantly larger volumes in Roma population. Finally, biorbital and interorbital width were both significantly higher in Roma than in Serbian examinees. We could not show differences between sexes except for the biorbital width, which had lower values in Serbian, but not Roma women than in men.

Conclusion Taken together, our results indicate larger orbits, as well as greater distances between the eyes in Roma than in Serbian examinees.

Keywords: ethnicity; sex; multiplanar reconstruction; orbit; Roma; Serbian

INTRODUCTION

The orbit is a craniofacial cavity which contains eyeball, optic nerve and accessory ophthalmic elements including muscles, ligaments, orbital fat body, blood vessels and nerves. The shape of the orbital cavity is determined by geometry of cranial and facial bones and its morphometric characteristics are variable and depend on sex, race, and ethnicity [1–4]. Its anatomical parameters are of great importance for anthropology, reconstructive surgery and forensic medicine [5].

Some studies described the sexual dimorphism of the orbit [6, 7, 8]. Also, its asymmetry was described with the right cavity larger than the left one, as the result of the dominance of the left cerebral hemisphere [7, 9]. The fractures of the orbital cavity, with soft-tissue deviations and severe complications such as double vision, enophthalmos and ocular dystopia, present a complex task in reconstructive surgery [1, 5, 10]. Knowledge of the normal morphometry of the orbital cavity is of great importance in planning the surgical approach to orbital fracture

[11], but also in the case of other pathologies such as congenital, neoplastic and Graves' ophthalmopathies [9, 12, 13, 14]. In the adult population, the orbital volume is usually between 20 and 30 cm³ [1, 10, 13, 15]. Contemporary methods for determination of the orbital measures are based on the analysis of computed tomography (CT) and magnetic resonance imaging scans, although no standardized method for orbital volume measurements exists [16].

Another parameter, often used in facial morphometry is the orbital index. It is defined as the ratio between orbit height and orbit width, multiplied by 100. According to orbital index, three categories of orbital cavities were defined: 1) large (megaseme) – with orbital index 89 and more; 2) intermediate (mesoseme) – with orbital index in the range from 83 to 89; and 3) small (microseme) – with orbital index less than 83 [15, 16, 17]. The orbital index is one of the parameters used in many anthropological studies, because it depends on the shape of the face and varies among the races, regions within the same race, and ethnic groups [18].

Received • Примљено:
March 7, 2022

Accepted • Прихваћено:
June 1, 2022

Online first: June 9, 2022

Correspondence to:

Ivana ŽIVANOVIĆ-MAČUŽIĆ
University of Kragujevac
Faculty of Medical Sciences
Department of Anatomy
Svetozara Markovica 69
34000 Kragujevac
Serbia
ivanaanatom@yahoo.com

The aim of this study was to determine the morphometric characteristics of orbital cavity in Serbian population and to examine if there are differences in examined parameters between Serbs and the Roma ethnic group of Serbia. Previous anthropometric studies in this population mostly related to the measurement of the body weight, height, body mass index, and nutrition. Studies with orbital measurements have not been conducted so far [19, 20].

METHODS

The study was designed as a retrospective descriptive non-randomized observational study, that used data from patients' skull images, archived in the hospital system for data archiving. The patients were examined at the Department of Diagnostic Radiology, Clinical Center of Kragujevac in the period from January 2010 to November 2015. The radiological imaging was performed on 64-slice multidetector CT (MDCT) scanner (Aquilion 64, Toshiba, Minato City, Japan). All scans were performed in the axial plane, with subsequent multiplanar reconstruction (MPR). The patient lied on his back, with arms extended downwards, next to the body. The head restraint was used. The study included 94 patients (61 male and 33 female) aged 24–86 years, without pathological changes, who were referred to this examination for various reasons. The ethnicity of the subjects was determined based on the questionnaire form that they filled out before the examination.

The subjects' written consent was obtained according to the Declaration of Helsinki and the study has been approved by the ethic committee and conforms to legal standards.

Orbits were inspected, as part of a broader region examination (whole head, facial mass, paranasal cavities). The radiological imaging was performed on 64-slice MDCT scanner (Aquilion 64, Toshiba, Japan). All scans were performed in the axial plane, with subsequent MPR. The patient lied on his back, with arms extended downwards, next to the body. The head restraint was used. The scan range is determined on the lateral topogram and depends on the region of interest. Scanning parameters were: 120 kVp, 500 mAs, gantry rotation of 0.75 seconds, pitch 0.5 mm, slice thickness of 0.5 mm and 0.4–0.6 mm reconstruction thickness. Analysis of all images and MDCT data is performed on a Vitrea 2 workstation ver.4.1.14.0 (Vital Images, Canon Medical, Minnetonka, MN, USA). All measurements were done by two independent radiologists, using commercially available software (Imaging Software ver.4.1.14.0, Vital Images). For evaluation of inter-observer reliability, the intra-class correlation coefficient was used and intra-class correlation coefficient > 0.8 was considered as excellent agreement. Measurement of orbital morphometric parameters and orbital volume is performed on the same workstation and with the same software on 3D reconstruction of the bone structures obtained by examinations.

Standard anatomical points were determined and used for the measurement of the orbital width, height, biorbital-interorbital diameter and the orbital index. Orbital width

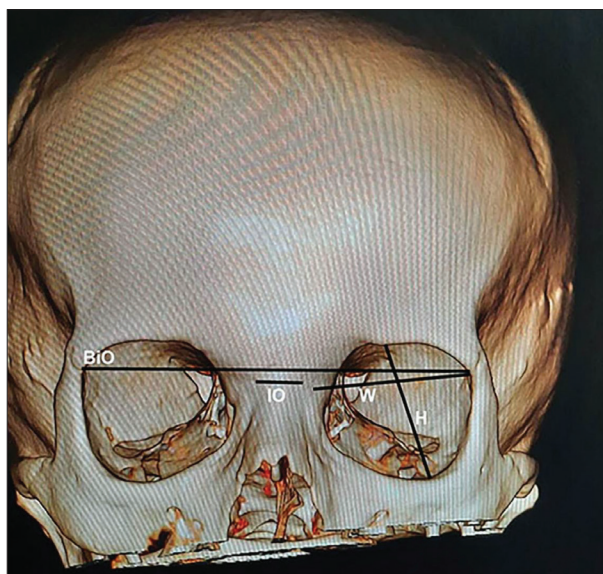


Figure 1. A representative image of reconstructed skull with orbital measurements shown; W – orbital width; H – orbital height; IO – interorbital width; BiO – biorbital width

– laterally curved distance between the dacryon (the point where frontal, lacrimal and maxillary bones intersect and the medial margin of the orbit is formed) and ectoconchion (the point of intersection of the anterior surface of the lateral limit of the orbit; the line divides the orbit along its axis into two parts) (Figure 1) [8]; orbital height – distance between the superior and inferior orbital margins; it is perpendicular to its width and similarly divides the orbit into two parts (Figure 1) [8]; orbital index – orbital height/orbital width \times 100 [21]; biorbital width – distance between left and right ectoconchion (Figure 1) [8]; interorbital width – distance between right and left dacryon (Figure 1) [8]. Measurements were performed on coronal plane using 3D images reconstructed from orbital images. The relation of age and sex with the results was analyzed.

All data are presented as the mean values \pm standard deviation. Statistical analysis was performed using a parametric statistical test, as the data had normal distribution and equal variance. Two-way analysis of variance (ANOVA) with factors “ethnicity” and “sex” was used to compare the groups, followed by Holm-Sidak post-hoc multiple comparisons analysis. Probability value for the rejection of the null hypothesis was set to 0.05.

Ethical approval

All procedures performed in studies involving human participants were in accordance with the ethical standards of the institutional and/or national research committee and with the 1964 Helsinki declaration and its later amendments or comparable ethical standards.

RESULTS

We examined the orbits of 76 Serbian (41 male and 25 female) and 18 Roma (10 male and eight female) subjects,

Table 1. Basic demographic data

Examinees	Number of examinees	Mean Age	Age SD	Age span
Serbian male	51	55.9	17.62	24–86
Serbian female	25	58.4	15.68	29–85
Serbian all	76	56.4	17.04	24–86
Roma male	10	50.8	14.06	31–72
Roma female	8	53.5	7.34	44–61
Roma all	18	52	11.35	31–72
All	94	55.6	16.1	24–86

using CT scanner and MPR. The subjects were age-matched, with the average age of 56.4 ± 17 and 52 ± 11.3 for Serbian and Roma groups, respectively ($p = 0.3$; two-way ANOVA). Detailed demographic data is given in Table 1. As sexual dimorphism has been reported for orbital measures, we analyzed our results using two-way ANOVA, with factors “ethnicity” and “sex” [12]. The height of the left orbit (38.05 ± 2.96 mm in Serbian and 39.83 ± 2.28 mm in Roma; $p = 0.012$) was significantly higher in Roma than in Serbian examinees. Similarly, the width of the left orbit (42.12 ± 2.28 mm in Serbian and 44.07 ± 1.95 mm in Roma; $p < 0.001$) was higher in Roma than in Serbs. The height of the right orbit (38.28 ± 3.35 mm in Serbian and 40.12 ± 2.34 mm in Roma; $p = 0.036$) was significantly higher in Roma group, whereas the width of the right orbit (43.69 ± 2.39 mm in Serbian and 44.31 ± 2.01 mm in Roma; $p = 0.088$) was not statistically different between the ethnicities (Figure 2A). Orbital indices, however, for both the left orbit (90.5 ± 6.8 in Serbian and 90.4 ± 3.5 in Roma; $p = 0.78$) and the right orbit (87.7 ± 7.2 in Serbian and 90.5 ± 3.4 in Roma; $p = 0.235$) did not significantly

differ between Serbian and Roma examinees (Figure 2B). Right orbital volume (22.49 ± 3.57 mm³ in Serbian and 23.67 ± 1.22 mm³ in Roma; $p = 0.053$) did not differ between the groups, although there was a tendency towards higher values in Roma, and the left orbits (21.63 ± 3.14 mm³ in Serbian and 23.44 ± 1.15 mm³ in Roma; $p = 0.002$) had significantly larger volumes in Roma population (Figure 2C). As for the distances between the eyes, biorbital width (100.50 ± 4.28 mm in Serbian and 104.65 ± 3.21 mm in Roma; $p < 0.001$) and interorbital width (18.76 ± 3.25 mm in Serbian and 20.15 ± 1.12 mm in Roma; $p = 0.035$) were both significantly higher in Roma than in Serbian examinees (Figure 2D). Of all measured parameters, only bi-orbital width was significantly different for factor “sex” ($p = 0.004$) and had significant interaction between “sex” and “ethnicity” ($p = 0.003$). Biorbital width was higher in male than in female Serbs (102.37 ± 3.37 mm in males vs. 96.88 ± 3.58 mm in females), whereas this difference was not present in the Roma population (104.60 ± 3.65 mm in males vs. 104.72 ± 2.82 mm in females). Overall, our results indicate larger orbits and larger distances between them in Roma than in Serbian population.

DISCUSSION

The morphometric characteristics of the orbital cavity are variable and depend on sex, race and ethnicity, and their estimation is relevant for anatomy, forensic medicine, anthropology and reconstructive and aesthetic surgery [2, 3, 4, 8, 13]. The results of our CT study showed that the height and the width of the left orbit and the height of the right orbit were significantly higher in Roma examinees,

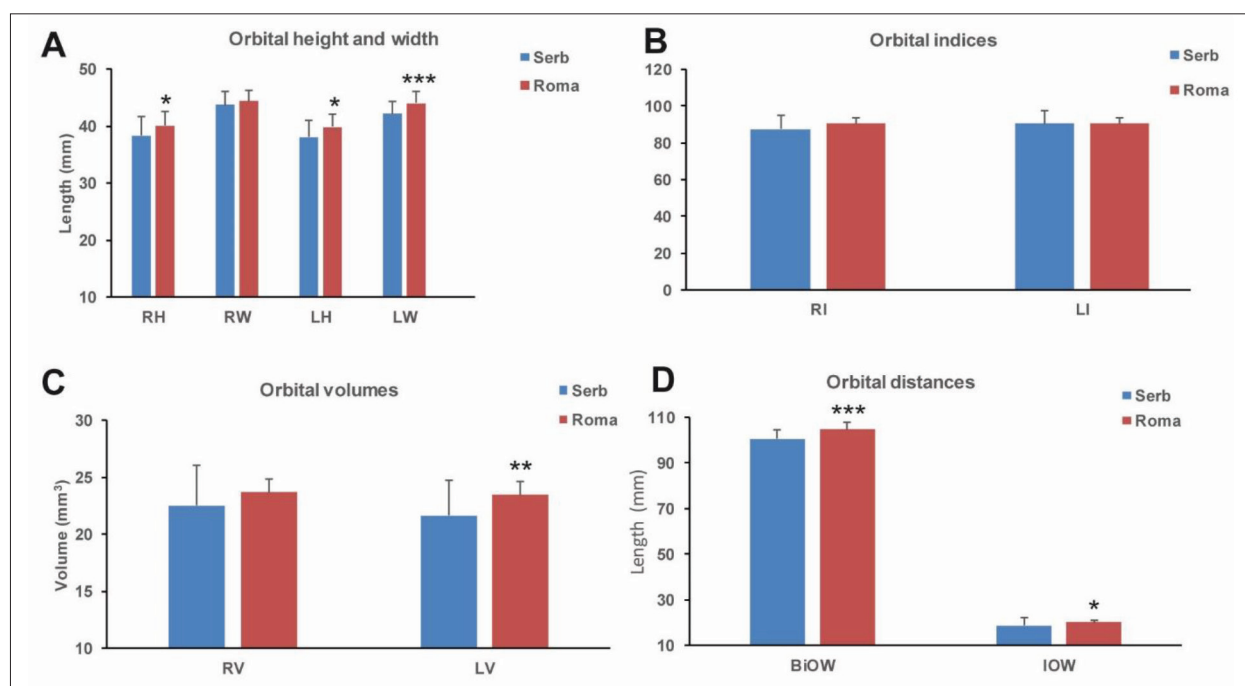


Figure 2. Orbital measurements in Serbian vs. Roma examinees; shown are mean values + SD for orbital height and width (A), orbital indices (B), volumes (C) and distances between the eyes in Serbian (blue bars) and Roma (red bars) examinees; two-way ANOVA with Holm–Sidak post-hoc, * $p < 0.05$; ** $p < 0.01$; *** $p < 0.001$. R (right), L (left) H (height), W (width), I (index), V (volume), BiO (biocular) IO (interocular)

whereas the width of the right orbit was not statistically different between the ethnicities. The obtained results for these parameters were similar to the findings of previous CT studies conducted in Turkish and Indian populations [3, 9, 22]. The sex differences in anatomy of the orbital cavity were confirmed by various studies, with male orbits being significantly larger than female [9, 11, 16, 23]. In comparison to reports that showed sex differences for most of the observed parameters [9, 16], in our study statistically significant sexual dimorphism was found for the biorbital width, which was higher in male than in female Serbs, whereas this difference was not present in Roma population. Thus, it is possible to speculate that the lack of sexual dimorphism in Roma population influenced our results. The results of our study confirmed the earlier findings in variation of orbital dimensions between the left and right side [18, 24]. The observed parameters of the orbital height and width had a tendency to be higher on the right side, leading to the higher values of the left orbital index (right: 88.2 ± 6.7 , left: 90.5 ± 6.3 ; $p = 0.019$, t-test). This is in accordance with the earlier findings and widely accepted theory that the skull and the face right/left asymmetry with higher values of the right orbital measures are the consequence of the brain asymmetry and the dominance of the left hemisphere [24, 25].

The orbital index is one of the parameters used in many anthropological studies, because it depends on the shape of the face and varies among the races, regions within the same race, and ethnic groups [19]. According to the values of orbital indices (right 86.5 ± 7.2 and left 90.2 ± 6.8), we could conclude that the right orbits in Serbs could be placed in mesoseme category, typical for the European and Caucasian race [24], whereas the left orbits are megaseme. Similar to the data from the Polish population [26], Serbian females had higher orbital indices (right: 90.02 and left: 91.09), which could be classified as megaseme, in comparison to the orbital indices of Serbian males. In both sexes, orbital index had tendency towards higher values on the left side, which was in males significant ($p = 0.012$, t-test). Orbital indices did not significantly differ between Serbian and Roma examinees. However, Roma examinees had a tendency toward higher values of orbital indices (right 90.5 ± 3.5 and left 90.4 ± 3.6), according to which, their orbits could be classified in megaseme category. Contrary

to the findings in Serbian examinees, orbital indices in Roma had a tendency towards slightly higher values on the right side than the left and among males (right: 91.19 ± 3.3 and left: 90.96 ± 3.7) than females (right: 89.75 ± 3.3 and left: 89.69 ± 3.2). These findings demonstrate that ethnicity influences orbital measures.

The volume of the right orbit was slightly higher than the left one, which was also in accordance with the earlier studies and the skull asymmetry [1, 16]. The right orbital volume did not differ between the groups, but the left orbits had significantly larger volumes in Roma population. Finally, biorbital and interorbital width were both significantly higher in Roma than in Serbian examinees. Interorbital width is earlier described as one of the sexually dimorphic morphological parameters of the skull [21], but we did not find statistically significant difference, although it was greater in males. In accordance with similar studies [17], biorbital width was found as sexually dimorphic in Serbian examinees, with higher values among males, while in Roma this sex difference was not statistically significant. A relatively small number of Roma examinees is admittedly a weakness of our study, but it should be considered that ethnic Roma rarely visit doctors' offices and have limited access to the health care system [27, 28].

CONCLUSIONS

Morphological measurements of the orbit are valuable for better practical knowledge and understanding of the difference between sexes, races, and ethnicity. Taken together, our results indicate larger orbits, as well as greater distances between orbits in Roma than in Serbian examinees. This is, to our knowledge, the first study addressing anthropometric parameters of the orbital cavity in Serbian and Roma populations.

ACKNOWLEDGEMENT

This study was supported by project grant No. JP 12/16 to MJ.

Conflict of interest: None declared.

REFERENCES

- Felding UA, Bloch SL, von Buchwald C. The Dimensions of the Orbital Cavity Based on High-Resolution Computed Tomography of Human Cadavers. *J Craniofac Surg.* 2016;27(4):1090–3. [DOI: 10.1097/SCS.0000000000002604] [PMID: 27171949]
- Patra A, Singla RK, Mathur M, Chaudhary P, Singal A, Asghar A, et al. Morphological and Morphometric Analysis of the Orbital Aperture and Their Correlation with Age and Gender: A Retrospective Digital Radiographic Study. *Cureus.* 2021;13(9):e17739. [DOI: 10.7759/cureus.17739] [PMID: 34659952]
- Coutinho DCO, Martins-Júnior PA, Campos I, Custódio ALN, Silva MRMAE. Zygomaticofacial, Zygomaticoorbital, and Zygomaticotemporal Foramina. *J Craniofac Surg.* 2018;29(6):1583–7. [DOI: 10.1097/SCS.0000000000004530] [PMID: 29570528]
- Hu S, Colley P. Surgical Orbital Anatomy. *Semin Plast Surg.* 2019;33(2):85–91. [DOI: 10.1055/s-0039-1685476] [PMID: 31037044]
- Gellrich NC, Dittmann J, Spalthoff S, Jehn P, Tavassol F, Zimmerer R. Current Strategies in Post-traumatic Orbital Reconstruction. *J Maxillofac Oral Surg.* 2019;18(4):483–9. [DOI: 10.1007/s12663-019-01235-8] [PMID: 31624425]
- Ji I, Lai C, Gu L, Fan X. Measurement of Intra-Orbital Structures in Normal Chinese Adults Based on a Three Dimensional Coordinate System. *Curr Eye Res.* 2018;43(12):1477–83. [DOI: 10.1080/02713683.2018.1510013] [PMID: 30118614]
- Jakovcevski I, Vojinovic R, Zivanovic – Macuzic I, Jakovcevski M. Age and gender differences in orbital measurements within Serbian population in Kragujevac region of the Republic of Serbia. *Serb J Exp Clin Res.* 2020. [DOI: 10.2478/sjecr-2020-0030]; in press.

8. Xing S, Gibbon V, Clarke R, Liu W. Geometric morphometric analyses of orbit shape in Asian, African and European human populations. *Anthropol Sci.* 2013;121(1):1–11. [DOI: 10.1537/ase.120803]
9. Khademi Z, Bayat P. Computed tomographic measurements of orbital entrance dimensions in relation to age and gender in a sample of healthy Iranian population. *J Curr Ophthalmol.* 2016;28(2):81–4. [DOI: 10.1016/j.joco.2016.03.002] [PMID: 27331152]
10. Andrades P, Cuevas P, Hernández R, Danilla S, Villalobos R. Characterization of the Orbital Volume in Normal Population. *J Cranio Maxill Surg.* 2018;46(4):594–9. [DOI: 10.1016/j.jcms.2018.02.003] [PMID: 29534909]
11. Dvoracek LA, Lee JY, Unadkat JV, Lee YH, Thakrar D, Losee JE, et al. Low-Cost, Three-Dimensionally-Printed, Anatomical Models for Optimization of Orbital Wall Reconstruction. *Plast Reconstr Surg.* 2021;147(1):162–6. [DOI: 10.1097/PRS.00000000000007495] [PMID: 33370061]
12. Ji Y, Qian Z, Dong Y, Zhou H, Fan X. Quantitative morphometry of the orbit in Chinese adults based on a three-dimensional reconstruction method. *J Anat.* 2010;217(5):501–6. [DOI: 10.1111/j.1469-7580.2010.01286.x] [PMID: 20807268]
13. Fetouh FA, Mandour D. Morphometric analysis of the orbit in adult Egyptian skulls and its surgical relevance. *Eur J Anat.* 2014;18(4):303–15.
14. Kang S, Kwon J, Ahn CJ, Esmali B, Kim GB, Kim N, et al. Generation of customized orbital implant templates using 3-dimensional printing for orbital wall reconstruction. *Eye (Lond).* 2018;32(12):1864–70. [DOI: 10.1038/s41433-018-0193-1] [PMID: 30154573]
15. Anibor E, Mabiaku YO, Emueze J. Orbital Index among Ika Ethnic Group of Delta State in Nigeria. *PalArch's Journal of Archaeology of Egypt / Egyptology.* 2019;18(08):3274–7.
16. Mottini M, Wolf CA, Jafari MS, Katsoulis K, Schaller B. Stereographic measurement of orbital volume, a digital reproducible evaluation method. *Brit J Ophthalmol.* 2017;101(10):1431–5. [DOI: 10.1136/bjophthalmol-2016-309998] [PMID: 28258077]
17. Hierl KV, Krause M, Kruber D, Sterker I. 3-D cephalometry of the orbit regarding endocrine orbitopathy, exophthalmos, and sex. *PLoS One.* 2022;17(3):e0265324. [DOI: 10.1371/journal.pone.0265324] [PMID: 35275980]
18. Botwe BO, Sule DS, Ismael AM. Radiologic evaluation of orbital index among Ghanaians using CT scan. *J Physiol Anthropol.* 2017;36(1):29. [DOI: 10.1186/s40101-017-0145-7] [PMID: 28697737]
19. Burnham R, Bridle C. Adult orbital wall fracture repair. In: *Idle M, Monaghan AM editors. Challenging Concepts in Oral and Maxillofacial Surgery Cases with Expert Commentary.* Oxford: Oxford university press; 2016. p. 52–60.
20. Enache G, Rusu E, Ilinca A, Rusu F, Costache A, Radulian G. Prevalence of obesity and newly diagnosed diabetes in the Roma population from a country in the south part of Romania (CĂLĂRAȘI COUNTY) – Preliminary results. *Romanian J Diabetes Nutr Metab Dis.* 2016;23(1):27–36. [DOI: 10.1515/rjdnmd-2016-0004]
21. Kanjani V, Rani A, Knajani D. Morphometric Analysis of the Orbital Aperture in North Indian Population: A Retrospective Digital Forensic Study. *Int J Appl Basic Med Res.* 2019;9(2):85–8. [DOI: 10.4103/ijabmr.IJABMR_404_18] [PMID: 31041170]
22. Saloniemi M, Lehtinen V, Snäll J. Computer-Aided Fracture Size Measurement in Orbital Fractures-An Alternative to Manual Evaluation. *Cranio Maxillofac Trauma Reconstr.* 2021;14(3):209–17. [DOI: 10.1177/1943387520962691] [PMID: 34471477]
23. Mekala D, Shubha R, Rohini Devi M. Orbital dimensions and orbital index: a measurement study on south Indian dry skulls. *Int J Anat Res.* 2015;3(3):1387–91. [DOI: 10.16965/ijar.2015.242]
24. Adel R, Ahmed HM, Hassan OA, Abdelgawad EA. Assessment of Craniometric Sexual Dimorphism Using Multidetector Computed Tomographic Imaging in a Sample of Egyptian Population. *Am J Forensic Med Pathol.* 2019;40(1):19–26. [DOI: 10.1097/PAF.0000000000000439] [PMID: 30407939]
25. Gupta V, Prabhakar A, Yadav M, Khandelwal N. Computed tomography imaging-based normative orbital measurement in Indian population. *Indian J Ophthalmol.* 2019;67(5):659–63. [DOI: 10.4103/ijo.IJO_1187_18] [PMID: 31007233]
26. Lepich T, Dabek J, Witkowska M, Jura-Szoltys E, Bajor G. Female and male orbit asymmetry: Digital analysis. *Adv Clin Exp Med.* 2017;26(1):69–76. [DOI: 10.17219/acem/58783] [PMID: 28397435]
27. Alunni L. Pathogenic camps, therapeutic city? Roma, healthcare, and the negotiation of citizenship rights in Rome. *Soc Sci Med.* 2021;289:114421. [DOI: 10.1016/j.socscimed.2021.114421] [PMID: 34571360]
28. Škarić-Jurić T, Klarić IM, Narancić NS, Drmić S, Peričić Salihović MP, Lauc LB, et al. Trapped between tradition and transition - anthropological and epidemiological cross-sectional study of Bayash Roma in Croatia. *Croat Med J.* 2007;48(5):708–19. [PMID: 17948957]

Разлике у антропометријским мерама орбите између Срба и Рома у Централној Србији

Маја Вуловић¹, Ивана Живановић-Мачужић¹, Радмила Балабан-Ђуревић², Александар Радуновић³, Милан Аксић⁴, Владимир Чоловић⁵, Радиша Војиновић⁶

¹Универзитет у Крагујевцу, Факултет медицинских наука, Катедра за анатомију, Крагујевац, Србија;

²Универзитет у Источном Сарајеву, Медицински факултет у Фочи, Катедра за претклиничке предмете, Република Српска, Босна и Херцеговина;

³Војномедицинска академија, Клиника за ортопедију, Београд, Србија;

⁴Универзитет у Београду, Медицински факултет, Институт за анатомију „Нико Миљанић“, Београд, Србија;

⁵Универзитет у Крагујевцу, Факултет медицинских наука, Крагујевац, Србија;

⁶Универзитет у Крагујевцу, Факултет медицинских наука, Катедра за радиологију, Крагујевац, Србија

САЖЕТАК

Увод/Циљ Облик и величина орбиталне шупљине су битни параметри у планирању хируршких захвата, а имају велики значај и у антропологији и судској медицини.

Циљ овог рада је био да утврди морфометричке карактеристике орбиталне шупљине у српској популацији, као и да утврди да ли постоје разлике између српске и ромске етничке групе.

Методе Користишењем компјутеризоване топографије и накнадно мултипларне реконструкције анализирали смо орбите 76 српских и 18 ромских здравих волонтера. Није било значајне разлике у годинама између етничких група.

Резултати Висина и ширина леве, као и висина десне орбите биле су значајно веће код Рома него код Срба, док се

ширина десне орбите није значајно разликовала. Орбитални индекси за оба ока су, међутим, имали сличне вредности код Срба и Рома. Запремина десне орбите није се разликовала између испитиваних етничких група, али је лева орбита имала значајно већу запремину код ромске популације. Коначно, биорбитална и интерорбитална висина и ширина су биле значајно веће код Рома него код Срба. Нисмо открили разлике међу половима, осим за биорбиталну ширину, која је имала ниже вредности код српских, али не и код ромских жена, него код мушкараца.

Закључак Наши резултати говоре у прилог већим орбитама, као и већем размаку између очију код Рома него код Срба.

Кључне речи: етничка припадност; пол; мултипланарна реконструкција; орбита; Роми; Срби