

CASE REPORT / ПРИКАЗ БОЛЕСНИКА

Customized polymethylmethacrylate cranioplasty using a low-cost 3-dimensional printed mold

Ivan Bogdanovic^{1,2}, Filip Milisavljević¹, Aleksandar Miljković¹, Nemanja Jovanović¹, Rosanda Ilić^{1,2}¹University Clinical Center of Serbia, Clinic of Neurosurgery, Belgrade, Serbia;²University of Belgrade, Faculty of Medicine, Belgrade, Serbia**SUMMARY**

Introduction Significant cranial defects result from a decompressive craniectomy following head trauma, malignant brain edema, intracranial hemorrhage, or resection of tumor affected bone. Unrepaired cranial defects are not just a tremendous esthetic problem. The underlying brain is unprotected, prone to injury, and this state can lead to the so-called “syndrome of the trephined” with mood instability, headaches, and even a neurological deficit. Currently, there is no widely accepted uniform technique of cranial vault shape restoration. Combining 3D technology with the use of polymethylmethacrylate is a challenging field that can bring good functional and aesthetic results and, in the case of smart design, become efficient, low-cost technology. We offer a possible solution to a problem that would be acceptable in neurosurgical practice.

Case outline We present a 37-year-old male patient with a massive hemicranial defect as a consequence of previous decompressive craniectomy following severe craniocerebral injury the previous year. Together with engineers from the appropriate 3D modeling studio, we have designed a two-part mold by laser printing technology using biocompatible advanced polyamide. We made a customized polymethylmethacrylate graft intraoperatively using this mold and achieved good aesthetic results.

Conclusion Reports of 3D printing assisted cranioplasties are growing, describing different techniques and cost-estimation. We hope to introduce a low-cost and simple method for repairing a skull defect.

Keywords: craniectomy; cranioplasty; skull defect; polymethylmethacrylate; 3D printing

INTRODUCTION

With first records dating over 3000 years B.C., cranioplasty is one of the oldest neurosurgical procedures aimed at restoring cranial vault integrity. The benefit to the patients is unquestionable since results concern not only esthetics and mechanical protection of intracranial structures but affect a considerable amount of subjective disturbance and even lead to regression of neurological deficit. Although as old as the first attempts of neurosurgery, there is no widely accepted uniform technique performing a cranioplasty. Materials currently used differ and can be autografts or more commonly used in modern neurosurgery – allografts.

CASE REPORT

We present a 37 years-old-male, who was admitted to our clinic for an elective cranioplasty procedure, 13 months following surgery after a traffic accident. Initial surgery included the evacuation of acute subdural hematoma and decompressive craniectomy due to malignant brain edema. Neurological status on admission revealed mild right-sided hemiparesis, and the patient-reported occasional headaches and light dizziness. Local status included clearly manifested massive bone defect, deformity of

the skull contour, without active skin infection or any skin efflorescence (Figure 1).

Routine non-enhanced computed tomography (CT) scan of the head was performed, using a bone window to build a 3D model, and data were further used for modeling by digital sculpting relying on symmetry and geometry present on the other half of the skull. Preoperative design, planning and modeling are conducted in selected studio for 3D modeling (Voxellab D.O.O.®, Belgrade, Serbia). The model was furnished using ZBrush 2021® (Pixologic®, Los Angeles, CA, USA). Based on the implant model, a 3D model of two-sided mold was created using Rhinoceros 6® software (McNeel®, Seattle, WA, USA). Finally, manufacturing of a two-part mold by selective laser sintering (3D printing) technology was conducted, using biocompatible PA2200 material (advanced polyamide 12) on Formiga P110 Velocis® (EOS®, Krailling, Germany) device with a resolution of 0.1 mm per layer, on 170°C ensuring high-level precision of construction and surface quality. The manufacturing process and material are certified for use in the medical and food industries. The material is biocompatible according to EN ISO 10993-1. The manufactured parts are isotropic and temperature-stable up to 163°C. Post-production of molds included sandblasting with glass and ceramic beads for maximum removal of unsintered

Received • Примљено:

January 11, 2021

Revised • Ревизија:

November 14, 2021

Accepted • Прихваћено:

November 15, 2021

Online first: November 17, 2021**Correspondence to:**

Ivan M. BOGDANOVIC
University Clinical Centre of Serbia
Clinic of Neurosurgery
Dojranska 16/10
11000 Belgrade
Serbia
ivanbg83@gmail.com

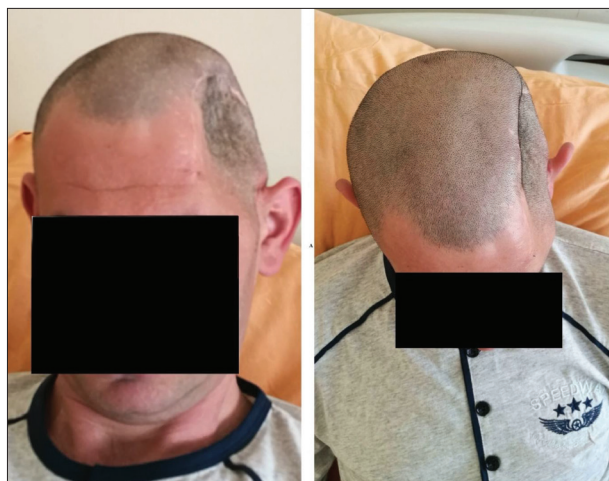

Figure 1. Patient with large hemicranial defect before surgery



Figure 2. Two-part polyamide mold made by laser printing technology and the resulting polymethylmethacrylate graft shaped by manual mold compression

powder and raising the quality of surfaces, and additional polishing of the inner surfaces of the mold for easier separation of the mold and the implant. Time consumed for 3D modeling, printing, and post-production processing was eight days, and the estimated cost per patient was €550–€600.

Since preoperative check-up revealed no absolute contraindications for operation, such as hydrocephalus, brain swelling, or infection, using 3D printed prefabricated molds, polymethylmethacrylate cranioplasty was performed. The same skin incision was used, and soft tissue dissection from the dura was carefully conducted. An evident impression of the left hemisphere and tissues above were noted. Significant adhesions of the inner dura to the arachnoid were found, and since it was the dominant hemisphere, no further dissection was performed, and no central tenting sutures could have been placed. The mold was sterilized prior to surgery in a standard autoclave at 134°C for 20 minutes and unpacked during the operation following all sterile procedures. Two packings of Poly(methyl methacrylate) (PMMA) (Gentafix, Teknimed s.a.s. Vic-en-Bigorre, France) were used for molding an implant intraoperatively. Molds were soaked with sterile saline and used for fabricating a final prosthesis. After the

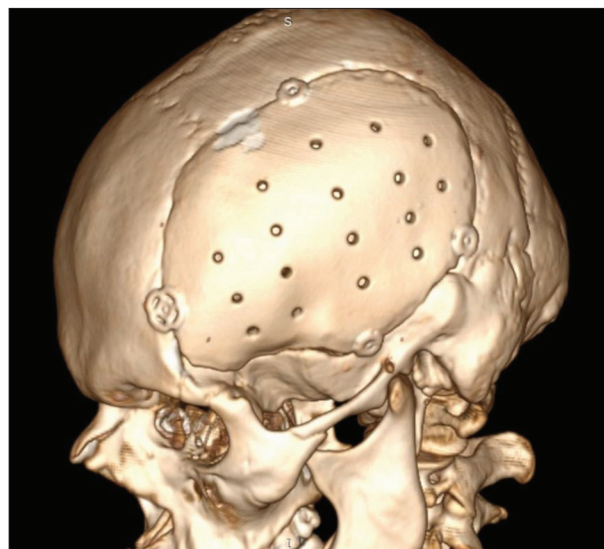


Figure 3. 3D computed tomography cranial reconstruction after the operation

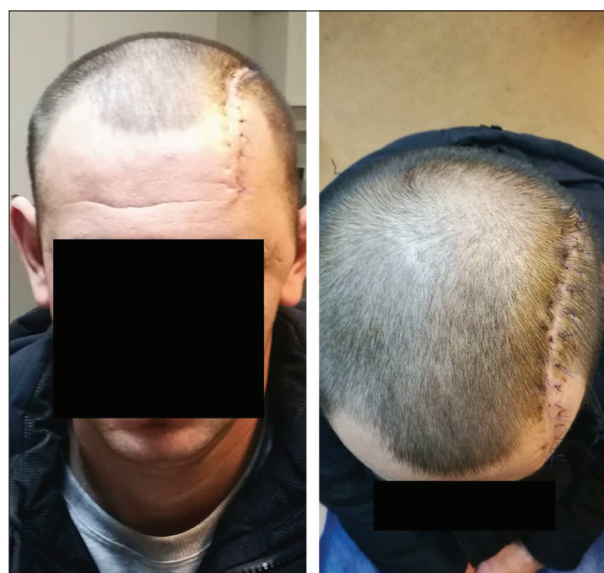

Figure 4. Restoration of head shape after the operation – pleasurable esthetic result

initial phase and achieving enough hardness not to deform, the mold was opened, allowing final stages of polymerization to occur outside of the mold and thus avoiding deformation of mold or implant. Multiple punctuations were made in the implant, allowing evacuation of potential fluid collection, as well as soft tissue ingrowth, obliterating potential epidural space (Figure 2). Fixation was achieved using CranioFix® (Aesculap®, Center Valley, PA, USA), epicranial drain was left in place, and soft tissue reconstruction was performed in anatomical layers. There were no intraoperative complications during prosthesis molding or implantation. After surgery, aesthetic results were obvious, and the patient was without new neurological deterioration (Figures 3 and 4). Initial CT scan demonstrated epidural effusion of non-blood liquid, without compressive effect (Figure 5). Local punctation was performed, and fluid, which was a mixture of blood and saline, was drained. Following punctation, an immediate control scan

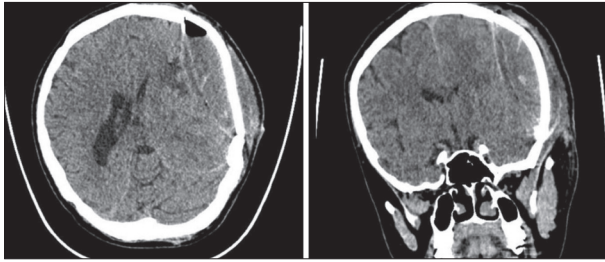


Figure 5. Epidural effusion following surgery

was performed, which showed no liquid or blood remnants in epidural space. No further complications were noted. During the 12 months follow-up, hemiparesis regression was confirmed. The patient also reported the withdrawal of subjective complaints.

Written consent was obtained from the patient to publish all the shown material. This study was conducted according to the institutional standards on ethics.

DISCUSSION

Attempts to restore the integrity of the skull are as old as neurosurgery. According to literature, defects larger than 6–10 cm² subject to reconstruction, and those larger than 50 cm², or more than 12 cm in axis should subject to custom-made cranioplasty [1–4]. Indications for reconstructive surgery concern not only aesthetic and social expectations of the patient but also the improvement of cerebral protection. Relieving cortex of soft tissue compression and restoration of normal cerebrospinal fluid circulation and venous blood return leads to neurologic improvement and diminishing of a group of symptoms counted in the syndrome of the trephined [5]. So far, many techniques and materials were tested, but still, no uniform procedure is established.

Many conditions result in cranial defects. The most common reasons are decompressive craniectomies due to intracranial hematoma, malignant edema or hemispheric ischemic lesions, comminution fractures or resection of tumor affected bone. Plenty of reports regarding this operation emphasize the use of bone graft preserved subcutaneously or in the bone bank. Still, this only provides a solution in cases of unfractured bone, excluding patients with wounds over bone flap, making them especially prone to infection and possibility of implantation under abdominal skin, since numerous cranial trauma cases also require general surgery operation. It is also an important fact that many, especially the third world and developing countries, have no bone banks. Despite all fulfilled conditions, there are still risks of bone graft resorption, especially in children, or infection and the consequent need for new operation. Younger age, bone flaps larger than 75 cm², and shunt dependency are recognized risk factors for bone resorption [6]. Even in the absence of resorption, initial damage or intraoperative drilling can cause a skull-graft mismatch, creating a significant esthetic defect. In the end, the exact discrepancy can be seen only intraoperatively.

Since World War II, the use of artificial materials is becoming more frequent. Characteristics expected to meet are biocompatibility, inertness, radiolucency, rigidity, but the material should also be light, non-magnetic, simple for handling and placement, and with low thermal conductivity [7, 8, 9]. Currently, most used alloplastic materials encompass metals, acrylic materials, plastics, and hydroxyapatite as representative of bioceramics [4]. A number of papers concerning allograft cranioplasty grows, but large studies comparing different materials with official recommendations are lacking. Data describing hydroxyapatite use, show good bio integration, demonstrating osteoconductive capabilities, making it particularly interesting for the pediatric population, but also showing a higher chance of prosthesis fracture and dislocation, as well as significantly higher price per piece [4]. Usage of titanium in cranioplasty offers good quality and persistence but is not flawless. Its fabrication is more complicated [7]. Patient's complaints of thermal conduction are well noted, with some series even reporting a higher incidence of infection in these patients compared to those operated using PMMA [4]. It is also important to emphasize that titanium offers minimal potential for an intraoperative correction [7]. Still, the main concern for health systems is a relatively high price, ranging \$3000–\$5000 [1, 4, 8, 10, 11].

Reports of 3D printing assisted cranioplasties are growing, describing different techniques and cost-estimation. Using PMMA offers many advantages over other materials. Significantly lower cost comparing to titanium makes it affordable to most health systems. Simplicity in use, low thermal conductivity, and the possibility for intraoperative modification make it especially helpful in reconstructive surgery. Still, it requires additional use of fixation hardware and develops high temperatures during polymerization, carrying a risk of thermal damage to surrounding tissues.

Methods described in literature differ significantly in every step of fabrication and implantation of the graft. Some authors propose the utilization of previously prepared and sterilized prosthetics, stating the lower price, shorter operation time, reduction of blood loss, and lower infection rate [7, 12]. One must consider that using pre-made PMMA grafts requires plasma or ethylene-dioxide sterilization, which is not widely available, increasing price, but more importantly diminishing the possibility of intraoperative correction [7, 13]. Further differences concern the method of obtaining the final prosthesis. Although printing a prosthesis model, followed by making a plaster cast and additional molding of PMMA final graft is possible, we find it unnecessary and too complicated since it can result in significant mold and prosthesis deformation [7, 9]. Using one-side mold achieves precise curvature but makes it almost impossible to achieve the exact volume of the graft, fill the trephine holes, and bears risks of uneven and bumpy inner side of the graft [1, 10]. Direct printing of two-sided mold allows immediately obtaining not only correct contour and shape, but also thickness of the bone and therefore better fixation and durability. Despite some studies stating the possibility of mold deformation during sterilization, we did not encounter such problems

[1]. Screw-assisted molds and those designed in such a manner that so that PMMA can be poured into them complicate opening of the mold and allowing final stages of polymerization of the PMMA to occur outside of the mold, avoiding sticking and deforming of both mold and prosthesis [10, 11].

Precise recommendations regarding the timing of the operation are still to be established. Current studies attribute a higher rate of hydrocephalus in early cranioplasty (< 90 days) following trauma, but also find a higher incidence of extra-axial effusion in delayed procedures [4]. We address epidural effusion seen in our case to inability to place central tack-up sutures due to dura-arachnoid scarring, arising from the late-term of the operation.

Although technically undemanding, skull reconstruction still carries risks of early and late postoperative complications [4, 5, 9, 10]. The overall rate of complication differs, usually ranging 5–25% [9, 13]. We would like to emphasize, in particular early postoperative care, including mandatory CT scan. As seen in our case, brain hemisphere atrophy presents a risk for fluid collection and extra-axial hematoma, without evident neurological deterioration, further endangering the patient. Even in good result months following the surgery and esthetically satisfying

appearance, with reduction of subjective complaints and social disturbances, late complications described in the literature suggest the need to periodical check-ups.

Beside excellent esthetic outcome, shorter operation time, reduced blood loss and infection rate, without donor site morbidity, using printed customized molds offers the possibility of intraoperative correction and remanufacturing of the graft in case of infection or prosthesis fracture [9, 14, 15].

The total price of graft manufacturing is under 600\$, making it lower than the prices stated in the literature, ranging \$600–\$5000. By using our proposed method, we hope to overcome two major concerns regarding cranioplasty – price and time consumed in planning and manufacturing of the prosthetics. Still, temporalis muscle atrophy, commonly seen following decompressive craniectomies, still remains an esthetical problem, with the best method of augmentation yet to be found. We hope that our fast, precise, efficient, and low-cost method of customized cranioplasty assisted by 3D printing technology will be accepted and funded by the Serbian National Health Insurance Fund.

Conflict of interest: None declared.

REFERENCES

- Abdel Hay J, Smayra T, Moussa R. Customized Polymethylmethacrylate Cranioplasty Implants Using 3-Dimensional Printed Poly(lactic Acid) Molds: Technical Note with 2 Illustrative Cases. *World Neurosurg.* 2017;105:971–9.e1.
- Low PH, Abdullah JY, Abdullah AM, Yahya S, Idris Z, Mohamad D. Patient-Specific Reconstruction Utilizing Computer Assisted Three-Dimensional Modelling for Partial Bone Flap Defect in Hybrid Cranioplasty. *J Craniofac Surg.* 2019;30(8):e720–e3.
- Siracusa V, Maimone G, Antonelli V. State-of-Art of Standard and Innovative Materials Used in Cranioplasty. *Polymers (Basel).* 2021;13(9):1452.
- Morselli C, Zaed I, Tropeano MP, Cataletti G, Iaccarino C, Rossini Z, et al. Comparison between the different types of heterologous materials used in cranioplasty: a systematic review of the literature. *J Neurosurg Sci.* 2019;63(6):723–36.
- Maricevich JPBR, Cezar-Junior AB, de Oliveira-Junior EX, Veras E Silva JAM, da Silva JVL, Nunes AA, et al. Functional and aesthetic evaluation after cranial reconstruction with polymethyl methacrylate prostheses using low-cost 3D printing templates in patients with cranial defects secondary to decompressive craniectomies: A prospective study. *Surg Neurol Int.* 2019;10:1.
- Maduri R, Viaroli E, Levivier M, Daniel RT, Messerer M. Use of a 3D Skull Model to Improve Accuracy in Cranioplasty for Autologous Flap Resorption in a 3-Year-Old Child. *Pediatr Neurosurg.* 2017;52(5):351–5.
- De La Peña A, De La Peña-Brambila J, Pérez-De La Torre J, Ochoa M, Gallardo GJ. Low-cost customized cranioplasty using a 3D digital printing model: a case report. *3D Print Med.* 2018;4(1):4.
- Cheng CH, Chuang HY, Lin HL, Liu CL, Yao CH. Surgical results of cranioplasty using three-dimensional printing technology. *Clin Neurol Neurosurg.* 2018;168:118–23.
- da Silva Júnior EB, de Aragão AH, de Paula Loureiro M, Lobo CS, Oliveti AF, de Oliveira RM, et al. Cranioplasty with three-dimensional customised mould for polymethylmethacrylate implant: a series of 16 consecutive patients with cost-effectiveness consideration. *3D Print Med.* 2021;7(1):4.
- Đurić KS, Barić H, Domazet I, Barl P, Njirić N, Mrak G. Polymethylmethacrylate cranioplasty using low-cost customised 3D printed moulds for cranial defects - a single Centre experience: technical note. *Br J Neurosurg.* 2019;33(4):376–8.
- Martinez-Seijas P, Díaz-Galvis LA, Hernando J, Leizaola-Cardesa IO, Aguilar-Salvatierra A, Gómez-Moreno G. Polymethyl Methacrylate Custom-Made Prosthesis: A Novel Three-Dimension Printing-Aided Fabrication Technique for Cranial and/or Orbital Reconstruction. *J Craniofac Surg.* 2018;29(5):e438–e40.
- Seen S, Young S, Lang SS, Lim TC, Amrith S, Sundar G. Orbital Implants in Orbital Fracture Reconstruction: A Ten-Year Series. *Craniofac Trauma Reconstr.* 2021;14(1):56–63.
- Broeckx CE, Maal TJJ, Vreeken RD, Bos R.R.M., Ter Laan M. Single-Step Resection of an Intraosseous Meningioma and Cranial Reconstruction: Technical Note. *World Neurosurg.* 2017;108:225–9.
- Bassi M, Antonelli V, Tomassini A, Maimone G, D'Andrea M, Campobassi A, et al. Synchronized "One-Step" Resection and Cranio-Orbital Reconstruction for Spheno-Orbital Lesions With Custom Made Implant. *J Craniofac Surg.* 2021;32(5):1870–3.
- Metwali H, Hassanin M, Ibrahim T. A Customized Technique of Cranioplasty for Patients with Large Skull Defects: A Technical Note. *World Neurosurg.* 2021;148:110–4.

Краниопластика полиметилметакрилатом коришћењем индивидуализованог калупа начињеног тродимензионалним штампачем

Иван Богдановић^{1,2}, Филип Милисављевић¹, Александар Миљковић¹, Немања Јовановић¹, Росанда Илић^{1,2}

¹Универзитетски клинички центар Србије, Клиника за неурохирургију, Београд, Србија;

²Универзитет у Београду, Медицински факултет, Београд, Србија

САЖЕТАК

Увод Дефекти лобање често настају као последица декомпресивних краниектомија након краниоцеребралне повреде, малигног едема мозга, интракранијалног крварења или ресекције кости захваћене тумором. Кранијални дефекти који нису репарирани нису само значајан естетски проблем. Мождано ткиво је у таквим случајевима незаштићено, подложно повредама и ови болесници понекад испољавају карактеристичан синдром који се одликује нестабилношћу расположења, главобољама, па чак и неуролошким дефицитом. Тренутно не постоји широко прихваћена и стандардизована техника пластике лобање. Комбиновање технологије тродимензионалне штампе са употребом полиметилметакрилата представља алтернативу, са значајним потенцијалом за добре естетске и функционалне резултате, са смањеним трошковима израде. Овде приказујемо једно од решења које би могло бити прихватљиво у неурохируршкој пракси.

Приказ болесника Представљамо 37-годишњег мушкарца са масивним хемикранијалним дефектом после декомпресивне краниектомије учињене због тешке краниоцеребралне повреде годину дана раније. Заједно са инжењерима из студија за тродимензионално моделирање, дизајнирали смо дводелни калуп технологијом ласерског штампања користећи биокompatibilни напредни полиамид. Током саме операције смо затим направили индивидуализовани полиметилметакрилатни графт према овом калупу и постигли добре естетске резултате.

Закључак Краниопластике начињене уз помоћ технологије тродимензионалног штампања су све више у употреби и већ су описане различите технике, мада још увек нису бројне. Надамо се да ћемо описаним начином увести релативно јефтин и једноставан, али ефикасан метод за репарацију дефекта лобање.

Кључне речи: краниектомија; краниопластика; дефект лобање; полиметилметакрилат; тродимензионално штампање