



CASE REPORT / ПРИКАЗ БОЛЕСНИКА

Asymptomatic “twig-like” middle cerebral artery embryological anomaly

Dragoslav Nestorović¹, Igor Nikolić^{2,3}, Vladimir Cvetić^{1,3}, Dušan Petrović¹, Goran Tasić^{2,3}

¹University Clinical Center of Serbia, Center for Radiology and Magnetic Resonance Imaging, Belgrade, Serbia;

²University Clinical Center of Serbia, Clinic for Neurosurgery, Belgrade, Serbia;

³University of Belgrade, Faculty of Medicine, Belgrade, Serbia

SUMMARY

Introduction Anomalies of the middle cerebral artery (MCA) are very rare. “Rete MCA,” “twig-like MCA” (T-MCA), “aplastic MCA,” “unfused MCA,” and others are all synonyms for unilateral embryological anomaly of the M1 segment of the MCA, where, due to an unknown cause, fusion of primordial arteries of the M1 segment did not happen. As a result, the M1 segment of the affected side consists of a mesh of small arteries from which arise normal perforators and cortical branches. Moyamoya disease, moyamoya-like syndrome, atherosclerotic steno-occlusive disease, vasculitis, and dissection of the MCA should be considered in differential diagnosis.

Case outline We present a 60-year-old female patient with twig-like left MCA, incidentally diagnosed due to persistent headaches six days prior to admission. Non-contrast computed tomography head examination was without peculiarities. Computed tomography angiography showed a network of small vessels in place of the left M1 segment, bridging internal carotid artery terminus with branches of the MCA bifurcation and giving rise to lenticulostriate arteries. Fourteen months later, on physical examination, the patient was in good general condition, without a neurological deficit, with occasional episodes of headache no stronger than 3–4/10 on the visual analogue scale.

Conclusion We report a patient with extremely rare variation of the M1 segment of the left MCA, incidentally diagnosed due to headaches.

Keywords: twig-like MCA; middle cerebral artery; CT angiography

INTRODUCTION

Anomalies of the middle cerebral artery (MCA) are very rare. They are less commonly seen than those of other major intracranial arteries [1, 2, 3]. Typically, three MCA anomalies (variations) are described: duplication (D-MCA), fenestration (F-MCA), and the presence of an accessory branch (A-MCA) [4]. “Rete MCA,” “twig-like MCA” (T-MCA), “aplastic MCA,” “unfused MCA,” and others are all synonyms for unilateral embryological anomaly of the M1 segment of the MCA, where, due to an unknown cause, fusion of the primordial arteries of the M1 segment did not happen [1, 2, 3, 5, 6, 7]. As a result, the M1 segment of the affected side consists of mesh of small arteries from which arise normal perforators and cortical branches [7].

Interestingly, the variations or possible anomalies in morphology of terminal branches of the internal carotid artery, like fenestration of the anterior cerebral artery (ACA) and hypoplastic ACA, have been also described in healthy non-human primates, as well as the left/right asymmetry in morphology of the MCA [8].

CASE REPORT

A 60-year-old female patient was admitted to the Emergency Center, University Clinical Center of Serbia, due to persistent headaches six days prior to admission. Non-contrast computed tomography head examination was without peculiarities. Computed tomography angiography showed a network of small vessels in place of the left M1 segment, bridging the internal carotid artery terminus with branches of the MCA bifurcation and giving rise to lenticulostriate arteries. Left MCA M2 branches, although somewhat “paler,” appeared to be normally filled with contrast agent. Deep middle cerebral vein had anomalous drainage into the left superior petrosal sinus (Figures 1 and 2).

Since this was an incidental finding, the patient was discharged home with only symptomatic therapy for headache (paracetamol/acetaminophen). Also, antiplatelet therapy in the form of acetylsalicylic acid (ASA) was prescribed. Fourteen months later, on physical examination, the patient was in good general condition, without a neurological deficit, with occasional episodes of headache no stronger than 3–4/10 on the visual analogue scale (VAS).

This case report was approved by the institutional ethics committee, and written consent

Received • Примљено:

July 18, 2021

Revised • Ревизија:

October 12, 2021

Accepted • Прихваћено:

October 25, 2021

Online first: November 3, 2021

Correspondence to:

Igor NIKOLIĆ
University Clinical Center of Serbia
Clinic for Neurosurgery
Koste Todorovića 4
11000 Belgrade, Serbia
i.m.nikolic@gmail.com

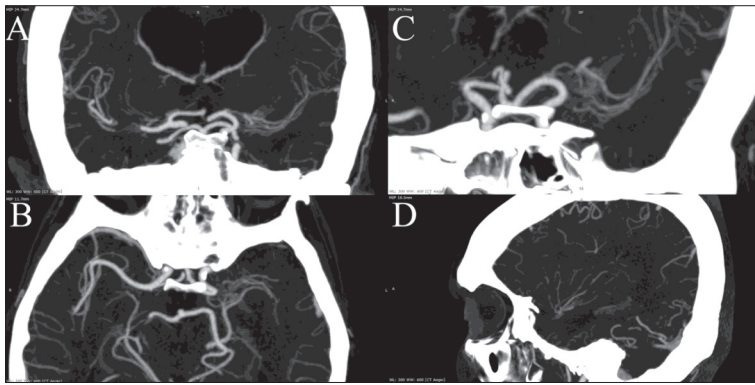


Figure 1. Computed tomography angiography maximum intensity projection reconstructions, A – coronal, B – axial, and C – oblique projections show multiple “twig-like” arteries arising from terminal part of left internal carotid artery, forming network in place where the M1 should be; D – sagittal projection demonstrates normal arborization of the left middle cerebral artery with branches that are slightly less filled with contrast agent

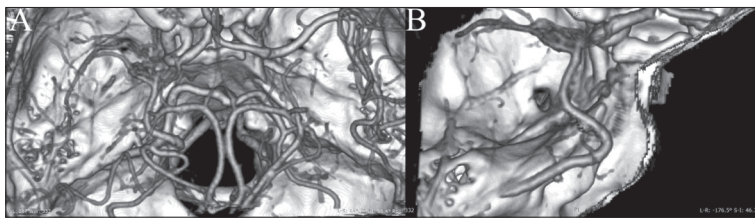


Figure 2. Computed tomography angiography volume rendering; A and B show deep middle cerebral veins anomalous drainage into superior petrosal sinus

was obtained from the patient for the publication of this case report and any accompanying images.

DISCUSSION

The MCA is the largest and most complex artery supplying the brain, vascularizing the largest territory of neocortex [9, 10]. MCA develops after ACA, when fetal plexiform network of multiple small arteries fuse and regress in order to form perforating branches of the M1 segment and the main trunk of the MCA (M1 segment). Disruption of this process, by a still unknown cause, leads to MCA developmental anomalies [7]. Fukuyama reported one case of Ap/T-MCA associated with *RNF213* mutations, which was previously believed to be associated exclusively with moyamoya [11]. In “T-MCA,” this plexiform network persists unilaterally in place of the M1 segment, while cortical and perforating branches, although filled with contrast agent with discrete delay, appear to be normal [6, 7]. Of all the MCA anomalies, T-MCA is the one least commonly seen. Reports range 0.1–4% prevalence, while Viso et al. [3] reported a prevalence of 0.088% in their cohort which included over 10,000 patients.

The possibility of hypoperfusion and, eventually, ischemic events has been described [6]. Uchiyama et al. [12] reported intracerebral hemorrhage in patient two years after transient ischemic attack and diagnosed T-MCA as the culprit. Also, there is an increased risk of aneurysm formation, due to hemodynamic stress and network vessels’ fragile histological architecture which can lead to

rupture and hemorrhage [3, 5, 6, 13]. Sakai et al. [14] reported rupture of a *de novo* formed aneurysm arising from the twig-like network of an anomalous collateral artery associated with aplastic or twig-like MCA (Ap/T-MCA) in a patient who had ruptured aneurysm on the A1 segment four years earlier.

Moyamoya disease, moyamoya-like syndrome, atherosclerotic steno-occlusive disease, vasculitis, and dissection of the MCA should be considered in differential diagnosis [1, 3, 15].

Therapy options may vary depending on patient symptoms and angiographic findings, but no universal treatment has been established to this day [5]. If T-MCA is an asymptomatic, coincidental finding, the patient should be counseled and warned about the nature of the anomaly. Vessels in the mesh are functional but also fragile, so no intervention should be performed unless necessary [1]. It is still unclear if microsurgical superficial temporal artery bypass is beneficial in cases of recurrent ischemic events. In their case report, Matsunaga et al. [6] stated that postoperative magnetic

resonance angiography showed a decrease of blood flow in aberrant network indicating that this approach may improve perfusion of affected MCA territory and lower hemodynamic stress in the aberrant network. On the other hand, Matsuo et al. [16] stated that there is no evidence that revascularization is an effective approach in preventing stroke on the affected side. Further studies on this anomaly are necessary to understand its nature and provide adequate therapy. Aneurysms in an anomalous MCA network have high risk of rupture and should be treated surgically or by endovascular embolization. Open surgery is more commonly used due to higher risk of endovascular approach through these fragile vessels [7].

Although uncommon, clinicians should recognize this vascular entity in order to avoid misdiagnosis and unnecessary treatment which can lead to catastrophic adverse events, especially in the era in which mechanical thrombectomies are becoming an everyday practice, and this entity could lead to confusion because of simulating a thromboembolic event. Less experienced neuroradiologist could easily overlook the subtle vessel network between the internal carotid artery and the distal part of the MCA.

In our opinion, the patient should be on lifelong preventive antiplatelet therapy (ASA) in order to avoid consequences of steno-occlusive and thromboembolic events. A follow-up physical examination, by a neurologist/neurosurgeon, should be performed every two years, while the neuroradiological examination is reserved only for patients with hemorrhagic or ischemic symptoms.

Conflict of interest: None declared.

REFERENCES

- Akkan K, Ucar M, Kilic K, Celticki E, Ilgit E, Onal B. Unfused or twig-like middle cerebral artery. *Eur J Radiol.* 2015;84(10):2013–8.
- Goto Y, Oka H, Hiraizumi S, Okamoto T, Nishii S, Yamamoto H, et al. Aplastic or Twig-Like Middle Cerebral Artery Presenting with Intracerebral Hemorrhage During Pregnancy: Report of Two Cases. *World Neurosurg X.* 2019;2:100018.
- Viso R, Lylyk I, Albiña P, Lundquist J, Scrivano E, Lylyk P. Hemorrhagic events associated with unfused or twig-like configuration of the Middle cerebral artery: A rare vascular anomaly with clinical relevance. *Interv Neuroradiol.* 2021;27(2):285–90.
- Seo BS, Lee YS, Lee HG, Lee JH, Ryu KY, Kang DG. Clinical and radiological features of patients with aplastic or twiglike middle cerebral arteries. *Neurosurgery.* 2012;70(6):1472–80; discussion 1480.
- Cho KC, Kim JJ, Jang CK, Hong CK, Joo JY, Kim YB. Rete middle cerebral artery anomalies: a unifying name, case series, and literature review. *J Neurosurg.* 2018;131(2):453–61.
- Matsunaga Y, Izumo T, Morofuji Y, Horie N, Hayashi K, Matsuo T. Revascularization for Aplastic or Twiglike Middle Cerebral Artery: A Case Report. *J Stroke Cerebrovasc Dis.* 2018;27(5):e78–e79.
- Ren H, Ma L, Wei M, Li J, Yu M, Yin L. Duplicated middle cerebral artery origin with an aneurysm. *Medicine (Baltimore).* 2018;97(9):e9947.
- Teofilovski-Parapid G, Filipović B, Marković D, Obrenović B, Janošević S, Stanković G, et al. Arterial circle of the African green monkey brain. *Acta veterinaria.* 2006;56(2–3):225–34.
- Cilliers K, Page BJ. Anatomy of the Middle Cerebral Artery: Cortical Branches, Branching Pattern and Anomalies. *Turk Neurosurg.* 2017;27(5):671–81.
- Tsuyama K, Myamoto N, Shindo A, Hira K, Ueno Y, Yatomi K, et al. Analysis for Stroke Etiology in Duplicated/Accessory MCA-Related Cerebral Infarction: Two Case Report and Brief Literature Review. *Diagnostics.* 2021;11(2):205.
- Fukuyama R, Yamamura K, Murata H, Miyatake S, Matsumoto N, Abe H. [Ruptured Aneurysm of an Aplastic or Twig-like Middle Cerebral Artery with Ring Finger Protein 213 Mutation: A Case Report]. *No Shinkei Geka.* 2020;48(6):533–40. [Article in Japanese]
- Uchiyama T, Okamoto H, Koguchi M, Tajima Y, Suzuyama K. A Case of Aplastic or Twig-Like Middle Cerebral Artery Presenting with an Intracranial Hemorrhage Two Years after a Transient Ischemic Attack. *No Shinkei Geka.* 2016;44(2):143–8.
- Shin HS, Lee SW, Ryu CW, Koh JS. Flow-related intracranial aneurysms associated with unfused arterial twigs relevant to different vascular anomalies: embryologic and hemodynamic considerations. *Acta Neurochir (Wien).* 2014;156(9):1637–46.
- Sakai K, Hiu T, Fukuda Y, Ozono K, Honda K, Kawahara I, et al. [A Rare Case of a Ruptured De Novo Aneurysm Arising from the Twig-like Networks of an Anomalous Collateral Artery Associated with Hypoplasia of the M1 Segment of the Middle Cerebral Artery 4 Years after the Rupture of an A1 Aneurysm at the Origin of the Collateral Artery]. *No Shinkei Geka.* 2018;46(8):713–22. [Article in Japanese]
- Hosur B, Bhatia V, Kumar A, Karthigeyan M. Rete middle cerebral artery: a rare association with anterior cerebral artery aneurysm rupture. *BMJ Case Rep.* 2021;14(2):e240219.
- Matsuo A, Hiu T, Ito T, Moritsuka T, Honda K, Kawahara I, et al. [Aplastic or Twig-like Middle Cerebral Artery with Cortical Subarachnoid Hemorrhage and Reversible Cerebral Vasoconstriction Syndrome during the Postpartum Period in a Juvenile Female: A Case Report]. *No Shinkei Geka.* 2020;48(5):435–44. [Article in Japanese]

Асимптоматска ембриолошка аномалија средње церебралне артерије „налик граници“

Драгослав Несторовић¹, Игор Николић^{2,3}, Владимир Цветић^{1,3}, Душан Петровић¹, Горан Тасић^{2,3}

¹Универзитетски клинички центар Србије, Центар за радиологију и магнетну резонанцу, Београд, Србија;

²Универзитетски клинички центар Србије, Клиника за неурохирургију, Београд, Србија;

³Универзитет у Београду, Медицински факултет, Београд, Србија

САЖЕТАК

Увод Аномалије средње мождане артерије (СМА) веома су ретке. *Rete MCA*, *twig-like MCA (T-MCA)*, „апластична СМА“, „нефузионисана СМА“ и други називи синоними су за једнострану ембрионалну аномалију сегмента М1 СМА, где, из непознатих разлога, није дошло до фузије примордијалних артерија сегмента М1. Као резултат, сегмент М1 захваћене стране састоји се из мреже малих артерија из које полазе нормални перфоратори и кортикалне гране. Диференцијално дијагностички треба разматрати болест мојамоја, синдром сличан мојамоји, атеросклеротичну стенооклузивну болест, васкулитис и дисекцију СМА.

Приказ болесника Приказујемо жену стару 60 година са СМА „налик граници“, случајно откривеној због перзистентних главобоља шест дана пре пријема. Бесконтрастна

копјутеризована томографија главе није показала неуобичајености. Копјутеризована томографска ангиографија приказала је мрежу малих крвних судова уместо левог сегмента М1, која је повезивала терминални сегмент унутрашње каротидне артерије са гранама бифуркације СМА и лентикулостријатним артеријама. Четрнаест месеци касније, на контролном физикалном прегледу, болесница је била доброг општег стања, без неуролошког дефицита, са повременим епизодама главобоље не јачим од 3–4/10 на визуелној аналогој скали.

Закључак Приказујемо болесницу са екстремно ретком варијацијом левог сегмента М1 СМА, случајно откривеном због упорних главобоља.

Кључне речи: СМА „налик граници“; средња мождана артерија; копјутеризована томографска ангиографија