



ORIGINAL ARTICLE / ОРИГИНАЛНИ РАД

Clinical analysis of internal fixation femoral neck fractures with two or three cannulated screws

Igor M. Kostić¹, Milan M. Mitković^{1,2}, Saša S. Milenković^{1,2}, Milorad B. Mitković^{2,3}¹University Clinical Center Niš, Clinic for Orthopedics and Traumatology, Niš, Serbia;²University of Niš, Medical Faculty, Niš, Serbia;³Serbian Academy of Sciences and Arts, Belgrade, Serbia**SUMMARY**

Introduction/Objective Angular stability and dynamic fixation are key factors to successful healing of femoral neck fractures.

The objective was to evaluate the efficacy of internal fixation of femoral neck fractures with two parallel self-tapping antirotation screws (SAF) compared to standard, three cannulated cancellous screws (CCS) fixation.

Methods In total 100 fractures were retrospectively analyzed, divided in two groups in which two SAF screws were used in parallel (n = 50) or three standard screws in an inverted triangle configuration (n = 50). The groups were compared with operation time, time of consolidation, femoral neck shortening, Harris hip score and reoperation rates.

Results SAF parallel fixation group of patients achieved consolidation rate of 86% compared to 74% in CCS fixation group, without statistically significant difference between the examined groups (p > 0,05). Dynamization of implants was significantly positively correlated with the fracture healing time in both examined groups (SAF: r = 0.324, p = 0.025; CCS: r = 0.572, p = 0.001), with significantly shorter healing time in SAF patients – on average 15 weeks (15.02 ± 1.44) in relation to the CCS group of patients – 19 weeks (19.81 ± 2.94) ($\chi^2/z = 7.048$, p < 0.001). There was no statistically significant difference in the Harris hip score and reoperation rate among the study groups ($\chi^2 = 2.44$, p = 0.487; $\chi^2 = 0.500$, p = 0.696).

Conclusion Our results suggested that dual parallel fixation is simpler, less invasive and it demands less performance time. It is not inferior to fixation with three screws, from the point of biomechanics, possible complications, healing and functional recovery.

Keywords: femoral neck fractures; bone union; internal fixation

INTRODUCTION

Femoral neck fractures include injuries involving the area between the head of the femur and the intertrochanteric line and account for nearly half of all hip fractures, increasing exponentially with age [1]. The specific intracapsular environment with vulnerable vascular supply, and burden some biomechanics of the hip, contribute to the high complication rates seen after osteosynthesis of these fractures [2].

Internal fixation is frequently used for undisplaced fractures and for displaced intracapsular fractures in which preservation of the femoral head is preferred or the patient with poor pre-morbid conditions for arthroplasty [3, 4]. Traditionally intracapsular femoral neck fractures are operatively treated with three cannulated cancellous screw, but controversy remains over what the ideal number and correct position of screws should be for treating these fractures [5, 6].

However, the outcomes after conventionally inverted cancellous three screw fixation of femoral neck fractures have not been uniformly positive and the rates of revision surgery ranging 8–27% [7]. One of the main reasons for such poor outcomes is reflected in a more

technically demanding procedure in terms of fracture reduction and correct placement of screws. A simpler technique of placing only two parallel screws, one higher and the other lower in the femoral neck, may be a suitable alternative to improve complication rates of surgical treatment of femoral neck fracture in properly selected patients.

Objective

The primary objective of our trial was to evaluate the clinical outcome of internal fixation of femoral neck fractures by double screws versus three cancellous screws fixation in skeletally mature patients.

METHODS

After Institutional Review Board approval (ref. no. 12-2466-12, approval date March 9, 2015) we retrospectively reviewed data from January 2014 to January 2017 from the University Clinic of Orthopedics and Traumatology, at the Clinical Center in Niš. The study included a series of 100 patients with femoral neck fractures treated by the same group of surgeons.

Received • Примљено:
July 27, 2020

Revised • Ревизија:
February 28, 2021

Accepted • Прихваћено:
March 14, 2021

Online first: March 19, 2021

Correspondence to:

Igor M. KOSTIĆ
Clinical Center Niš
Clinic of Orthopedy and
Traumatology
Belgrade, Serbia
igaort@gmail.com

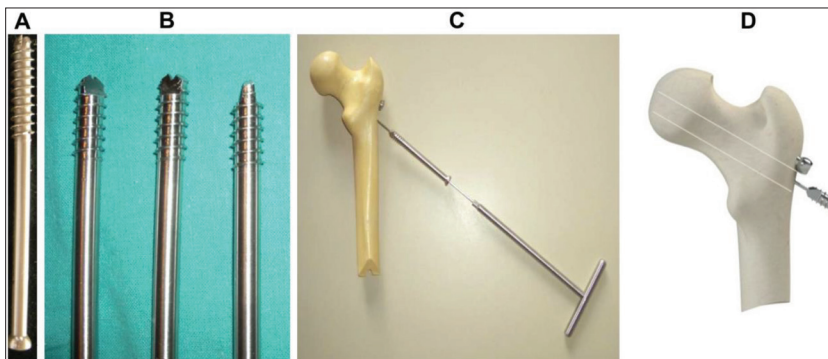


Figure 1. Standard AO 6,5 mm cannulated cancellous screw (A); self-tapping cannulated screws and position of the implant in femoral neck (B, C, D)

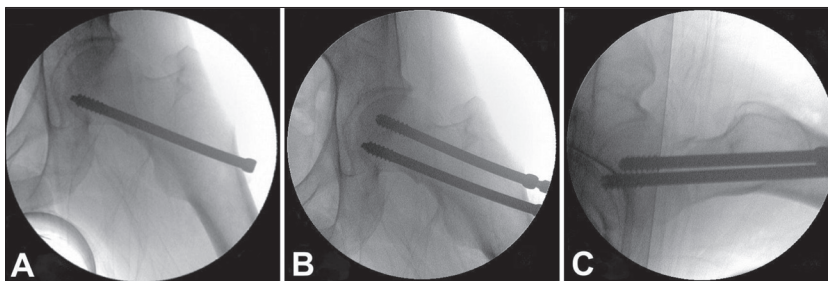


Figure 2. Plain radiographs to verify correct placement of self-tapping cannulated screws femoral neck fixation (A – distal screw placement; B – proximal screw placement; C – profile parallel placement)

A group of 50 patients with femoral neck fractures were treated surgically with two parallel inserted self-tapping anti-rotational screw fixation (SAF) group, while the other group of 50 patients were surgically treated using the multiple cancellous screw fixation method with three cannulated cancellous screws (CCS) group. Data were collected and compared retrospectively in both groups. Patients were selected using random allocation software [8]. The patients were not blinded to their treatments. All patients were followed up until fracture union or a revision surgery was performed. No patient was lost by the end of the first-year follow-up.

The inclusion criteria were for all patients who had either an undisplaced fracture, or a displaced femoral neck fracture with American Society of Anesthesiologists score range 1–3, who walked independently prior to the fracture, in the absence of hip osteoarthritis. We excluded from the study patients with pathological femoral neck fractures, open femoral neck fractures, femoral neck fractures in skeletal immaturity patients, polytrauma patients (ISS > 16) with ipsilateral fractures of femoral neck and shaft fractures and patients older than 65 years who had a severe concomitant medical condition (Grade 4, 5 American Society of Anesthesiologist Score).

Fracture management

In all selected cases the surgery was performed either in spinal or general anesthesia, with patients positioned supine on a traction table using the technique of closed reduction under C-arm control with manual traction and internal rotation of the injured extremity (Whitman's maneuver). If closed reduction was not satisfied after two

attempts, open reduction through Watson-Jones approach was carried out. In our clinical practice, for the last 15 years, we predominantly used for osteosynthesis of femoral neck fractures, double SAF from a domestic supplier (D.O.O. Traffix, Niš, Serbia). Anti-rotational self-tapping cannulated screw is made by medical steel 316LVM, body diameter screw of 7.2 mm, with threads thickness of 9 mm with a thread's length of 16 mm and self-tapping tip (Figure 1B, Figure 1).

The first group of 50 patients, in our study, underwent surgery with dual SAF cannulated implant from a domestic supplier (D.O.O. Traffix). Anti-rotational self-tapping cannulated screw is made by medical steel 316LVM, body diameter screw of 7.2 mm, with threads thickness of 9 mm with a threads length of 16 mm and self-tapping tip. The second group (CCS) of patients consists of other 50 patients with femoral neck fractures surgically treated by using

standard 6.5 or 7.3 mm three CCS (Figure 1). The SAF screws are designed to adjust to the load to which they are exposed and, on the other hand, to minimally injure bone tissue. Derotation compression of the fragment is achieved by parallel position of the SAF screws. These characteristics make the concept distinctive by itself. The tip of each screws was driven into head of femur to within 5 mm, approximately, from the subchondral bone plate (Figure 2).

On the other hand, three cancellous screws, in most cases, were placed in the configuration of an inverted triangle, respecting the principles of three-point fixation (Three-Point Principle) [9].

Assessment methods

Radiographic parameters

Before internal fixation, based on radiographs, the fracture classification according to Pauwel and Garden classification was performed. Pauwel's type II and III fractures ($\geq 50^\circ$) were considered unstable and Garden III or IV fractures were considered displaced. Acceptable reduction parameters have been defined as a neck shaft angle $130\text{--}150^\circ$, less than 15 degrees of valgus with no varus angulation, and $0\text{--}15^\circ$ of lateral angulation [10]. Intraoperative reduction assessments were graded as anatomical, acceptable or poor in both groups of patients. Preoperative and postoperative data were recorded, including age, type of fracture, degree of posterior comminution, surgical timing, duration of surgery, and final outcomes.

Functional outcome assessments and complications

Postoperatively, all patients received antibiotic prophylaxis for 48 hours and deep vein thrombosis prophylaxis for three weeks. Postoperatively, sitting was encouraged at the first day, non-weight-bearing ambulation with the aid of a walker frame was allowed after one or two weeks as long as the pain was tolerated. Patients were encouraged to partial weight bearing six weeks after the operation. After hip X ray confirmation that fracture healed, full weight bearing was allowed. Postoperative radiographs were assessed until the end-point was reached, defined as fracture consolidation, collapse of the femoral neck, loss of reduction that necessitated reintervention, necrosis of the head or pseudarthrosis of the neck, with a minimum period of six months elapsed from the time of the fracture. As a predictor of poor outcome, the influence of posterolateral comminution on healing time and stability of fixation was tested. The sliding length of the lag screws after fracture consolidation was measured by comparing the immediate postoperative and final anteroposterior radiographs.

The complete functional recovery of the patient after the minimum of one-year follow-up was verified in our study. The values obtained by filling in the questionnaires of Harris hip score scaled 1–100. After the 12-month follow-up, all patients in both groups were studied for the functional outcome, as well as the effect of femoral neck shortening on gait pattern and muscle strength and reoperation rate was recorded.

Data analysis

Statistical analysis was performed with SPSS® Version 16.0 for Windows® (SPSS Inc, Chicago, IL, USA). Baseline and outcome variables were compared between the investigated groups. Proportions and means among groups were compared using either the χ^2 or Fisher's exact test and Student's t test, respectively. Statistical significance was set at $p < 0.05$.

The study was approved by the local Medical Research Ethics Committee (ref. no. 12-2466-12, approval date March 9, 2015) and carried out according to the declaration of Helsinki

RESULTS

A total of 100 patients with undisplaced and displaced femoral neck fractures were included in this retrospective study. Their baseline socio-demographics data and significance in prevalence, in relation to the treatment groups (SAF vs. CCS), are shown in the Table 1.

The mean operative time for the fixation with two cannulated screws was significantly shorter by approximately 14 minutes (52.89 vs. 39.17 minutes, $p < 0.0001$, unpaired t-test) (Figure 3). Intraoperative blood loss and average fluoroscopy time were similar in both groups, with no significant difference ($p = 0.75$; $p = 0.62$).

Statistical analysis of the data founded that the majority of patients in the overall population achieved anatomical

type of fracture reduction or acceptable one, without statistical significance ($p = 0.490$), as shown in Table 2.

Table 1. Patient data among the study groups

Parameters	SAF (n = 50)	CCS (n = 50)	P	
Age (years) mean \pm SD (min–max)	58.06 \pm 10.35 (27–79)	51.86 \pm 16.52 (16–80)	0.027	
Sex (%F, %M)	40%F, 60%M	46%F, 54%M	> 0.05	
Garden class	I	14	10	> 0.05
	II	22	27	> 0.05
	III	11	10	> 0.05
	IV	3	3	> 0.05
Pauwels class	I	31	29	> 0.05
	II	17	18	> 0.05
	III	2	3	> 0.05
CRIF n (%)	45 (90%)	37 (74%)	0.038	

SAF – self-tapping antirotational fixation; CCS – cannulated cancellous screws; CRIF – closed reduction and internal fixation

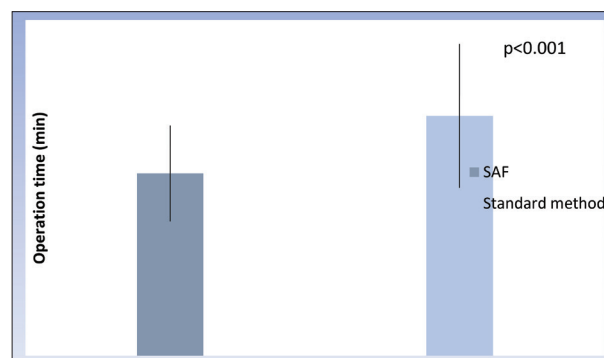


Figure 3. Operating time among studies groups; SAF – self-tapping cannulated screws

Table 2. Reduction quality assessment among the study groups

Assessment of reduction	Total n (%)	SAF n (%)	CCS n (%)	χ^2	P
acceptable	39 (39%)	20 (40%)	19 (38%)	1.428	0.490
anatomical	54 (54%)	28 (56%)	26 (52%)		
poor	7 (7%)	2 (4%)	5 (10%)		

SAF – self-tapping antirotational fixation; CCS – cannulated cancellous screws

The SAF group of patients had union rate of 86%, consolidation was observed in 43 of the 50 fractures. In the group which was made standard methods of treatment, consolidation was observed in 37 out of 50 fractures (74%). There was no statistically significant difference among the examined groups ($p > 0.05$).

In relation to posterolateral comminution, implant dynamics, meaning a migration of the lag screw(s) in the femoral neck or lateralization of the lag screw(s) due to fracture collapse, were observed more frequent in patients treated by surgical technique with multiple cancellous screws thickness of 6.3/7.5 mm and was greater than or equal to 10 mm which was statistically significantly ($\chi^2 = 6.474$, $p < 0.001$). Also, the union time was significantly shorter in SAF group (15.02 \pm 1.44) compared to patients in CCS group (19.81 \pm 2.94) with posterolateral fracture comminution ($\chi^2 = 7.048$, $p < 0.001$) (Table 3).

Table 3. Posterolateral comminution, union time and dynamization of implant

Characteristics	SAF	CCS	χ^2/z^*	p
Posterolateral comminution n (%)	43 (86%)	43 (86%)		1.000
Union time (weeks) mean \pm SD (min-max)	15.02 \pm 1.44 (10-22)	19.81 \pm 2.94 (12-26)	7.048*	< 0.001
Implant dynamization (mm) mean \pm SD (min-max)	3.33 \pm 1.96 (0-10)	13.18 \pm 6.21 (2-24)	6.474*	< 0.001

SAF – self-tapping antirotational fixation; CCS – cannulated cancellous screws

Comparing the fracture healing rate time with the degree of dynamization of implants in both groups of patients with posterolateral comminution, we came to the result that dynamization of implants significantly positively correlated with the fracture healing time in both examined groups, respectively (SAF: $r = 0.324$, $p = 0.025$; CCS: $r = 0.572$, $p = 0.001$) (Figure 4 and 5).

After one-year follow-up, Harris hip score values (SAF: 89.7 ± 8.4 ; CCS: 82.2 ± 14.3) were similar, with no statistically significant difference ($\chi^2 = 2.44$, $p = 0.487$) (Figure 6).

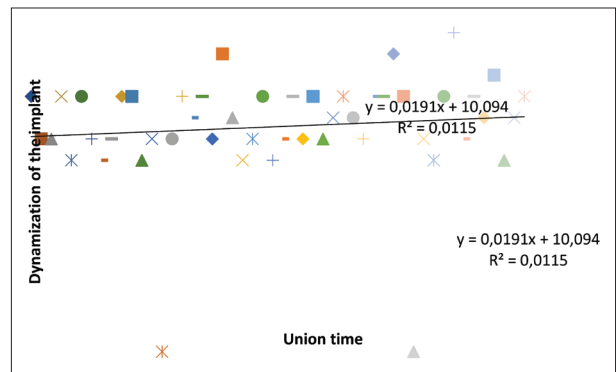
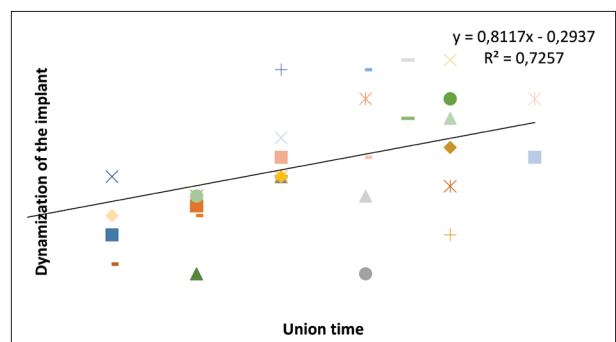
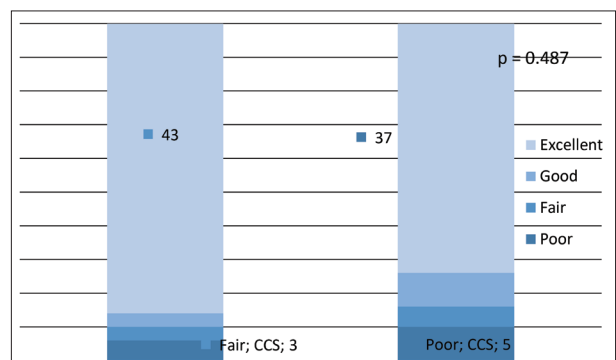
Reoperation was performed in five patients (10%) of SAF group and eight patients (16%) in CCS group of patients. It was found that there was no statistically significant difference in the incidence of reoperation rate between the tested method ($\chi^2 = 0.500$, $p = 0.696$).

Of the total number of patients operated by dual SAF implants, in five patients were performed reoperation procedures (two nonunions, one varus collapse and two healed fractures with advanced stage of femoral head necrosis - III and IV grade by Ficat and Arlet classification). Because of the developing of the osteoarthritis of injured hip, total hip replacement was carried out in all cases.

DISCUSSION

So far, there have not been many studies investigating double screw femoral neck fixations [11]. Mostly, the authors compared the rates of treatment complications between fixed angular plate and three screw fixation methods, emphasizing significantly higher prevalence in blood loss and duration of operation in the group of patients treated with fixed angular plates [12, 13]. Our data suggest that the use of the CCS was associated with approximately 14 minutes longer surgery which was significantly shorter in the SAF group of patients (52.89 vs. 39.17 minutes, $p < 0.0001$, $p = 0.62$, unpaired t-test).

Screw loosening, fracture displacement and some other complications may often occur with regards to the internal fixation of femoral neck fractures, which in turn increases the rates of nonunion and femoral head necrosis [14]. Furthermore, it is generally known that the compressive forces have a positive impact on fracture healing, but it is unclear what the degree of dynamic compression is needed to promote healing the fracture, in order to prevent the

**Figure 4.** Relationship between implant dynamics and fracture healing time in patients undergoing cannulated cancellous screws fixation**Figure 5.** Relationship between implant dynamics and fracture healing time in patients undergoing self-tapping cannulated screws fixation**Figure 6.** Assessments of complete functional recovery obtained by Harris hip score; SAF – self-tapping antirotational fixation; CCS – cannulated cancellous screws

prevalence of the shear forces which are the main cause of mechanical failure of fixation [15, 16]. During healing of femoral neck fracture, both bone resorption and shear forces of the fracture site can result in secondary sliding and displacement, even though the fracture was reduced in anatomic reduction quality, which tend to cause femoral neck shortening resulted in poorer functional outcome scores compared to patients who healed in an anatomic position [17]. Our study shows that dynamization of implants significantly positively correlated with the fracture healing time in both examined groups, respectively (SAF: $r = 0.324$, $p = 0.025$; CCS: $r = 0.572$, $p = 0.001$) indicating that fracture union rate was significantly shorter in group of patients treated with SAF method of fixation, average time 15 weeks (15.02 \pm 1.44) on related to CCS group of patients which was average 19

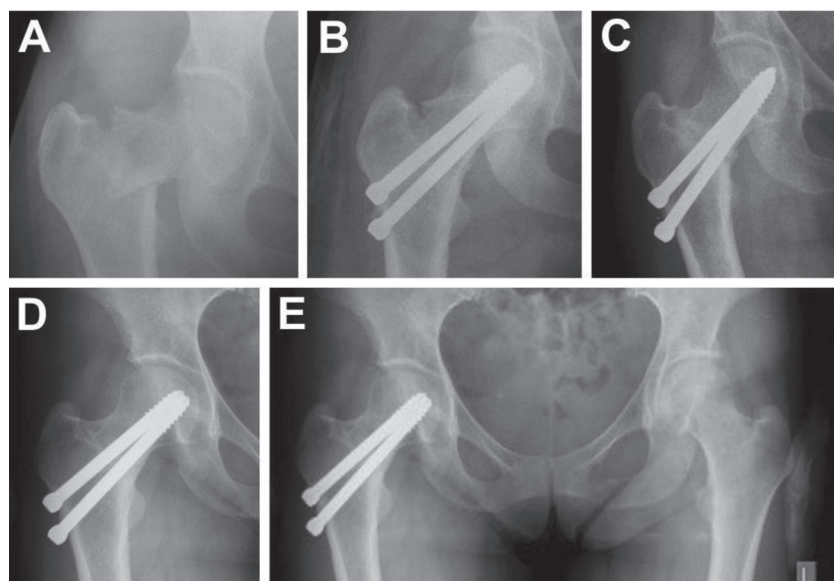


Figure 7. A 43-year-old female patient with unstable vertical (Pauwel III) intra-capsular femoral neck fractures, when Adam's arch is missing and lateral cortex suffers the greatest load, in our series of patients treated with two self-tapping antirotational fixations screws – serial follow up X-ray (A – initial; B – 12 weeks postoperative; C – six months; D – 12 months; E – 24 months postoperative)

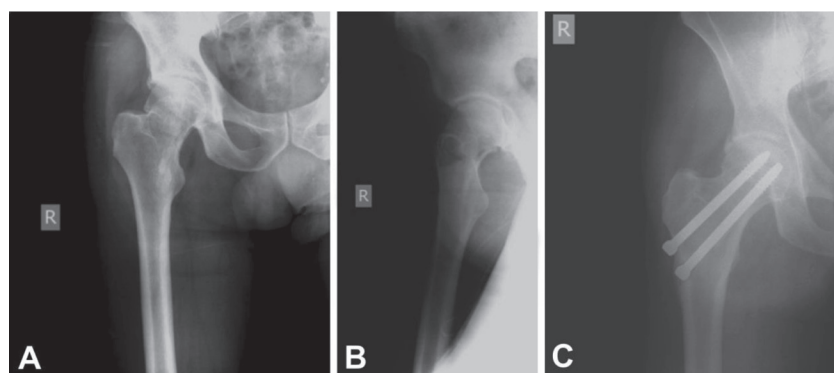


Figure 8. A – effect of "biological plate": anteroposterior view of femoral neck fractures with posterior wall comminution in a 63-year-old male patient; B – profile view indicated disrupted posterior wall of femoral neck fractures; C – six months postoperative X-ray show significant thickening of the lateral cortex around the distal screw with fracture healing

weeks (19.81 ± 2.94) ($\chi^2/z = 7.048$, $p < 0.001$). It follows that SAF fixation improves rotational control of fracture fixation represents a technically less demanding procedure.

Secondary sliding of implants (dynamization), which leads to resorption of fragments and shortening of the femoral neck, lasts until the end of the third month postoperatively, as part of normal bone consolidation. In cases of poor-quality fracture reduction and severe osteoporosis this event can cause uncontrolled excessive shortening of the femoral neck, which further leads to higher possibilities of nonunion and fixation failure after femoral neck fractures [18]. Literature data suggest that there is a high incidence of the unacceptable collapse of the femoral neck (≥ 10 mm), approximately 30%, after fixation displaced and undisplaced femoral neck fracture with posterolateral comminution with three cancellous screws, the thickness of 6.5 or 7.3 mm [19]. In our study, the average dynamization of the implant in SAF group was 5 mm, while in a CCS group it was 17 mm, which was a statistically

significant difference ($p < 0.001$). Despite the overall better value of Harris hip score for patients who had undergone SAF surgery (SAF: 89.7 ± 8.4 ; CCS: 82.2 ± 14.3), we found no statistically significant difference in functional recovery after one follow-up among the tested groups ($\chi^2 = 2.44$, $p = 0.487$). Considering the study's average revision rate among the studied groups (SAF = 6% vs. CCS = 8%) no significant difference between the two groups could be observed.

According to previous findings, it has been well known that the disruption of posterior wall of the femoral neck fractures is a major cause of excessive shortening of the femoral neck during the healing phase, and that adversely affects fracture healing, functional outcome and the occurrence of reoperation rate [20]. To ensure stable fixation and healing of the femoral neck fractures, it is necessary to secure three point of support which need to be adjusted to the biomechanical characteristics of the implant: the subchondral bone head of the femur for rotational stability (the first point of fixation), Adam's arch and femoral calcar of the neck of the femur (the second point of fixation) and support of lateral femoral cortex (the third point of fixation) [21, 22].

If Adam's arch of the caudal fragments remains intact (as it happens in the majority of femoral neck fractures) use of thick, rigid plate,

such as dynamic compression plate, is not required, and placement of free cannulated screws are enough for secure fracture fixation. Placed in parallel position, free cancellous screws give enough support to the femoral calcar and Adam's arch [23, 24]. This approach also causes less trauma to the soft tissues and requires shorter surgery duration. In our series intraoperative blood loss and average fluoroscopy time were similar in both groups, with no significant difference ($p = 0.75$; $p = 0.62$) which supports this claim.

But, in the cases when Adam's arch as the support of the second point of fixation is missing and cannot support the implant (Pauwels type III of femoral neck fractures, basiocervical femoral neck fractures, comminuted femoral neck fractures), double lever becomes a single, and large load suffers lateral cortex of the femur as a third point of support of internal fixation [25]. In these situations, additional reinforcement with an appropriate implant is required, in order to achieve resistance to the shear force inherent in these vertical fractures. Recently, the use of a medial

buttress plate on the medial side of the femoral neck has been proposed by some authors, with satisfactory initial results. However, it requires a more extensive surgical dissection and care must be taken not to damage the femoral head blood supply [26, 27]. SAF in most cases in our study was performed after closed reduction (90%) as a less surgically demanding procedure, where even after open fracture reduction (10%) adequate dynamic compression of the fracture site was provided without additional damaging the blood supply to the femoral head (LFCA and MFCA) (Figure 7). In order to achieve better angular stability and dynamic compression of the unstable Pauwels III fracture, recently, AO foundation authors introduced a new implant called Femoral Neck System (DePuy Synthes, Zuchwil, Switzerland), to improve the biomechanical performance of fracture fixation. They have biomechanically proven that implant is superior versus fixations with three parallel cannulated screws and comparable to both dynamic hip screw with antirotation screw and dynamic hip screw with blade in terms of sustainability of the restored neck length for unstable Pauwels III fractures [28].

One of the proofs overloading the third point of internal fixation of the femoral neck fractures is a thickening of the lateral cortex at the site around the distal screw, which was clearly visible on X-rays several weeks after dual SAF screw fixation. The pain was present until the “biological plate” did not finish its formation and provide solid support to the screw (Figure 8).

This phenomenon can be explained by the presence of micro-movements of the screw due to the load, causing osteogenesis followed by formation at first irritative callus, and then supportive periosteal callus around the distal screw on the lateral femoral cortex. This example shows that the lateral cortex could not always respond to the high demands that are placed in front of the third fixation point and that even in the cases of perfect fracture reduction and stabilization, micro-movements occurred. To avoid reduction loss or excessive femoral neck shortening after

internal fixation with free cannulated screws, it is necessary to strengthen the lateral cortex, especially in the case of osteoporotic patients [29].

The present retrospective study has certain limitations, that must be acknowledged. Firstly, it is a preliminary report with a small number of cases. Secondly, we found a small number of avascular necrosis cases in SAF group, which may be due to the short follow-up period. But it has certain character, which is reflected in the fact that the data analyzed here cover particular type of injury, where a large number of patients suffered unstable femoral neck fractures, almost equally distributed (SAF = 28% vs. CCS = 26% according to Garden type, SAF = 38% vs. CCS = 42% according to Pauwels type) in both studied groups.

CONCLUSION

Our data shows that the double screw SAF prevents the excessive collapse of the femoral neck fracture, respecting the principles of three-point fixation, acting as a load sharing device. Likewise, with significantly shorter duration of surgery, SAF provides optimal conditions for the healing of the comminuted fracture without further shortening the length of the femoral neck and functional damage to the hip abductor lever in properly selected patients. There is also a trend supporting the preferential use of the SAF over the CCS in terms of complication rates but lacks statistical significance. Nevertheless, more clinical prospective randomized trials should be done to evaluate the effectiveness of this implant.

Conflict of interest: The author Milorad B. Mitković at the moment of writing of this paper has an agreement on temporary assignment to patent use. Other authors declare no conflict of interest.

REFERENCES

1. Frisch N, Wessell N, Charters M, Greenstein A, Shaw J, Peterson E, et al. Hip fracture mortality: differences between intertrochanteric and femoral neck fractures. *J Surg Orthop Adv.* 2018;27(1):64–712.
2. Dolatowski FC, Frihagen F, Bartels S, Opland V, Šaltytė Benth J, Talsnes O, et al. Screw fixation versus Hemiarthroplasty for Nondisplaced femoral neck fractures in elderly patients: a multicenter randomized controlled trial. *J Bone Joint Surg Am.* 2019;101(2):136–44.
3. Okike K, Hasegawa IG. Current Trends in the Evaluation and Management of Nondisplaced Femoral Neck Fractures in the Elderly. *J Am Acad Orthop Surg.* 2021;29(4):e154–e164.
4. Li Z, Zhang X, Li Z, Peng A, Zhang L, Deng Y, et al. Comparative study of Pauwels type III femoral neck fractures managed by short dynamic hip screw with fibula bone graft or cannulated screws in young adults. *Ann Transl Med.* 2020;8(11):681.
5. Guo J, Dong W, Qin S, Zhang Y. Definition of ideal configuration for femoral neck screw fixation in older people. *Sci Rep.* 2019;9(1):12895.
6. Zhu Q, Shi B, Xu B, Yuan J. Obtuse triangle screw configuration for optimal internal fixation of femoral neck fracture: an anatomical analysis. *Hip Int.* 2019;29(1):72–6.
7. Kim SJ, Park HS, Lee DW. Complications after internal screw fixation of nondisplaced femoral neck fractures in elderly patients: A systematic review. *Acta Orthop Traumatol Turc.* 2020;54(3):337–43.
8. Saghaei M. Random allocation software for parallel group randomized trials. *BMC Med Res Methodol.* 2004;4:26.
9. Kazley J, Bagchi K. Femoral neck fractures. In: StatPearls. Edn. Treasure Island (FL): StatPearls Publishing; 2021.
10. Wang Y, Ma JX, Yin T, Han Z, Cui SS, Liu ZP, et al. Correlation Between Reduction Quality of Femoral Neck Fracture and Femoral Head Necrosis Based on Biomechanics. *Orthop Surg.* 2019;11(2):318–24.
11. Widhalm HK, Arnhold R, Beiglböck H, Munteanu A, Lang NW, Hajdu S. A Comparison of Dynamic Hip Screw and Two Cannulated Screws in the Treatment of Undisplaced Intracapsular Neck Fractures-Two-Year Follow-Up of 453 Patients. *J Clin Med.* 2019;8(10):1670.
12. Li J, Wang M, Zhou J, Zhang H, Li L. Finite element analysis of different screw constructs in the treatment of unstable femoral neck fractures. *Injury.* 2020;51(4):995–1003.
13. Zeng W, Liu Y, Hou X. Biomechanical evaluation of internal fixation implants for femoral neck fractures: A comparative finite element analysis. *Comput Methods Programs Biomed.* 2020;196:105714.
14. Shehata MSA, Aboelnas MM, Abdulkarim AN, Abdallah AR, Ahmed H, Holton J, et al. Sliding hip screws versus cancellous screws for

- femoral neck fractures: a systematic review and meta-analysis. *Eur J Orthop Surg Traumatol.* 2019;29(7):1383–93.
15. Samsami S, Augat P, Rouhi G. Stability of femoral neck fracture fixation: A finite element analysis. *Proc Inst Mech Eng H.* 2019;233(9):892–900.
 16. Schottel PC, Blankstein M, Sprague S, Swiontkowski M, Bzovsky S, Bhandari M, et al. Optimal Technical Factors During Operative Management of Low-Energy Femoral Neck Fractures. *J Orthop Trauma.* 2021;35(2):92–9.
 17. Stacey SC, Renninger CH, Hak D, Mauffrey C. Tips and tricks for ORIF of displaced femoral neck fractures in the young adult patient. *Eur J Orthop Surg Traumatol.* 2016;26(4):355–63.
 18. Nanty L, Canovas F, Rodriguez T, Faure P, Dagneaux L. Femoral neck shortening after internal fixation of Garden I fractures increases the risk of femoral head collapse. *Orthop Traumatol Surg Res.* 2019;105(5):999–1004.
 19. Felton J, Slobogean GP, Jackson SS, Della Rocca GJ, Liew S, Haverlag R, et al. Femoral neck shortening after hip fracture fixation is associated with inferior hip function: results from the FAITH trial. *J Orthop Trauma.* 2019;33(10):487–96.
 20. Biz C, Tagliapietra J, Zonta F, Belluzzi E, Bragazzi NL, Ruggieri P. Predictors of early failure of the cannulated screw system in patients, 65 years and older, with non-displaced femoral neck fractures. *Aging Clin Exp Res.* 2020;32(3):505–13.
 21. Koldaas MIB, Pedersen JN, Hojsager FD, Palm H, Viberg B. Implant positioning (IMPO) in undisplaced femoral neck fractures: association to reoperation and development of an IMPO scoring system. *Injury.* 2020;51(2):372–9.
 22. Wu Y, Leu TH, Chuang TY, Ho WP, Chen YP, Lin CY. Screw trajectory affects screw cut-out risk after fixation for nondisplaced femoral neck fracture in elderly patients. *J Orthop Surg (Hong Kong).* 2019;27(2):1–7.
 23. Xiong WF, Chang ShM, Zhang YQ, Hu SJ, Du SC. Inferior calcar buttress reduction pattern for displaced femoral neck fractures in young adults: a preliminary report and an effective alternative. *J Orthop Surg Res.* 2019;14(1):70.
 24. Johnson J, Deren M, Chambers A, Cassidy D, Korupolu S, Born C. Biomechanical analysis of fixation devices for basicervical femoral neck fractures. *J Am Acad Orthop Surg.* 2019;27(1):41–8.
 25. Dong Q, Han Z, Zhang YG, Sun X, Ma XL. Comparison of transverse cancellous lag screw and ordinary cannulated screw fixations in treatment of vertical femoral neck fractures. *Orthop Surg.* 2019;11(4):595–603.
 26. Nwankwo CD, Schimoler P, Greco V, Kharlamov A, Westrick ER, Miller MC. Medial Plating of Pauwels Type III Femoral Neck Fractures Decreases Shear and Angular Displacement Compared to Derotational Screw. *J Orthop Trauma.* 2020;34(12):639–43.
 27. Ye Y, Chen K, Tian K, Li W, Mauffrey C, Hak DJ, et al. Medial buttress plate augmentation of cannulated screw fixation in vertically unstable femoral neck fractures: surgical technique and preliminary results. *Injury.* 2017;48(10):2189–93.
 28. Stoffel K, Zderic I, Gras F, Sommer C, Eberli U, Mueller D, et al. Biomechanical Evaluation of the Femoral Neck System in Unstable Pauwels III Femoral Neck Fractures: A Comparison with the Dynamic Hip Screw and Cannulated Screws. *J Orthop Trauma.* 2017;31(3):131–7.
 29. Schopper C, Zderic I, Menze J, Müller D, Rocci M, Knobe M, et al. Higher stability and more predictive fixation with the Femoral Neck System versus Hansson Pins in femoral neck fractures Pauwels II. *J Orthop Transl.* 2020;24:88–95.

Клиничка анализа унутрашње фиксације прелома врата бутне кости применом два или три канулирана завртња

Игор М. Костић¹, Милан М. Митковић^{1,2}, Саша С. Миленковић^{1,2}, Милорад Б. Митковић^{2,3}

¹Универзитетски клинички центар Ниш, Клиника за ортопедију и трауматологију, Ниш, Србија;

²Универзитет у Нишу, Медицински факултет, Ниш, Србија;

³Српска академија наука и уметности, Београд, Србија

САЖЕТАК

Увод/Циљ Ангуларна стабилност и динамичка фиксација су кључни фактори за успешно зарастање прелома врата бутне кости.

Циљ ове студије је процена ефикасности унутрашње фиксације прелома врата бутне кости са два паралелна самонарезајућа антиротациона завртња (САЗ) у односу на три канулирана спољашња завртња.

Метод Ретроспективно је анализирано 100 прелома врата бутне кости, који су хируршки збрињавани са два САЗ завртња ($n = 50$) или три стандардна АО завртња у конфигурацији обрнутог троугла ($n = 50$). Упоредивани су дужина операције, време зарастања прелома, степен скраћивања врата бутне кости током консолидације прелома, крајњи функционални резултат мерен Харисовим скором и стопа реоперације.

Резултати У групи у којој се користила дуална (САЗ) паралелна фиксација, консолидација прелома је остварена у

86% случајева у односу на 74% у групи са три канулирана завртња, без статистички значајне разлике међу испитаним групама ($p > 0,05$). Динамизација имплантата значајно позитивно је корелирала са временом зарастања прелома у обе испитиване групе (САЗ: $p = 0,324$, $p = 0,025$; АО: $r = 0,572$, $p = 0,001$), са значајно краћим временом зарастања у групи САЗ пацијената – просечно 15 недеља ($15,02 \pm 1,44$) у односу на АО групу пацијената – 19 недеља ($19,81 \pm 2,94$) ($\chi^2 / z = 7,048$, $p < 0,001$). Према Харисовом скору кука и стопи реоперација, није примећена значајна разлика између група ($\chi^2 = 2,44$, $p = 0,487$; $\chi^2 = 0,500$, $p = 0,696$).

Закључак Резултати указују да је дуална паралелна фиксација (САЗ) једноставнија, мање инвазивна и захтева мање времена за извођење. Није инфериорна у односу на фиксирање са три завртња, са становишта биомеханике, могућих компликација, зарастања и функционалног опоравка.

Кључне речи: унутрашња фиксација; прелом врата бутне кости; зарастање