

CASE REPORT / ПРИКАЗ БОЛЕСНИКА

Non-invasive approach in the treatment of temporomandibular joint osteoarthritis

Anđela Milojević-Šamanović, Dejan Zdravković, Stefan Veličković, Milica Jovanović, Marko Milosavljević

University of Kragujevac, Faculty of Medical Sciences, Department of Dentistry, Kragujevac, Serbia



SUMMARY

Introduction Temporomandibular dysfunction (TMD) is a set of disorders that involve the masticatory muscles, the temporomandibular joint (TMJ), and its associated structures. Osteoarthritis (OA), as one of the forms of TMD, leads to permanent changes in the bone structures of TMJ. These changes can be the cause of serious functional disorders of the TMJ.

Case outline This article describes a case of a 24-year-old female patient who sought help due to pain and swelling in the area of the right and left TMJ, accompanied by muscular tension, severe headaches, which did not respond to medication. After establishing the diagnosis, we applied a therapy in the treatment of the bilateral OA of the TMJ, where we used non-invasive methods. Six months later, the patient reported the absence of pain, swelling, headache, and muscle tension in the orofacial region.

Conclusion There is no "gold standard" for the management of OA of TMJ. In our study, non-invasive therapy was successful in eliminating pain, increasing the range of motion of the lower jaw, stopping the progression of the disease, and advancing the quality of life.

Keywords: temporomandibular joint dysfunction; temporomandibular joint osteoarthritis; stabilization splint; cone beam computed tomography

INTRODUCTION

Temporomandibular dysfunction (TMD) is a set of disorders that involve the masticatory muscles, the temporomandibular joint (TMJ), and its associated structures [1].

Osteoarthritis (OA) as a form of TMD leads to a permanent change in bone structures. OA of the TMJ is a degenerative disease of the TMJ structures, followed by inflammatory changes causing pain, crepitus, and limited mouth opening [2].

The etiology is multifactorial. It most commonly occurs unilaterally as the possession of trauma, unbalanced dental occlusion, parafunction, systemic diseases, and functional overloading of the TMJ [3]. Some studies have not found an association between age, sex, and prevalence of OA of the TMJ, but others have shown that the mean age in women, with more frequent occurrence (84.5%), is 48.09 years, and 48.18 years in men [4, 5].

The most reliable diagnostic method that can confirm a clinical diagnosis of OA of the TMJ is radiological. Cone-beam computed tomography (CBCT) is a reliable three-dimensional (3D) method that can detect the radiological characteristics of this disease by the presence of one or more bone changes such as surface erosion, osteophyte, subcortical pseudocyst, articular surface flattening, and subcortical sclerosis [6].

Therapy involves a multidisciplinary approach, it can be non-invasive, minimally-invasive, and invasive. Non-invasive therapy

includes patient education, physical, pharmacological, and splint therapy. Minimally-invasive therapy includes injections, arthrocentesis, arthroscopy, while invasive modalities include surgical interventions [3, 7].

The aim of this study is to prove by appropriate diagnostic methods that OA of the TMJ lies behind TMD, and to show the possibility of successful application of non-invasive therapy of this disease in the progressive case of the younger population.

CASE REPORT

This report was approved by the Ethics Committee of the Faculty of Medical Sciences, University of Kragujevac, Serbia.

A 24-year-old female patient contacted the Faculty of Medical Sciences, University of Kragujevac, due to severe pain and swelling in the area of the right and left TMJ. The intensity of pain increased during the night, chewing, sneezing, mouth opening, and lateral movements of the lower jaw. Pain existed in the lower two-thirds of the face with severe muscular tension and headaches, which often did not respond to medication. The period of onset of pain in the right and left TMJ and the right leg coincided with the period of a stressful life situation.

Analysis of the anamnestic data revealed that she was born with a deformity of the right foot, which was rehabilitated with the use of

Received • Примљено:

June 11, 2020

Revised • Ревизија:

July 18, 2020

Accepted • Прихваћено:

September 17, 2020

Online first: September 30, 2020

Correspondence to:

Anđela MILOJEVIĆ ŠAMANOVIĆ
University of Kragujevac
Faculty of Medical Sciences
Department of Dentistry
Svetozara Markovića 69
34000 Kragujevac, Serbia
andjela-kg@hotmail.com

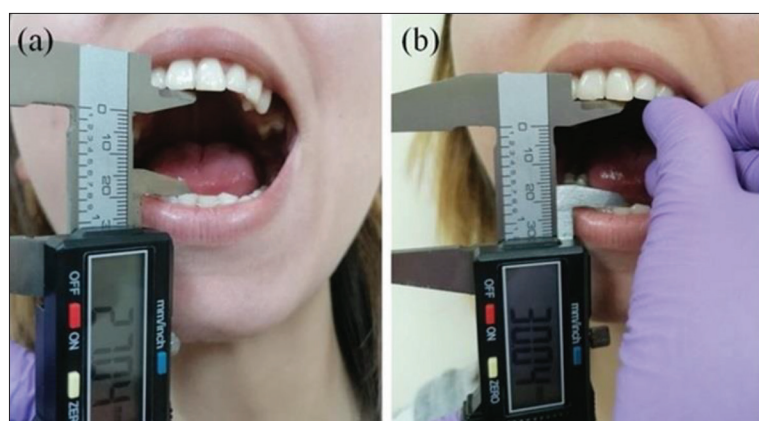


Figure 1. Assisted and non-assisted mouth opening at the beginning of therapy; non-assisted (a); assisted (b)

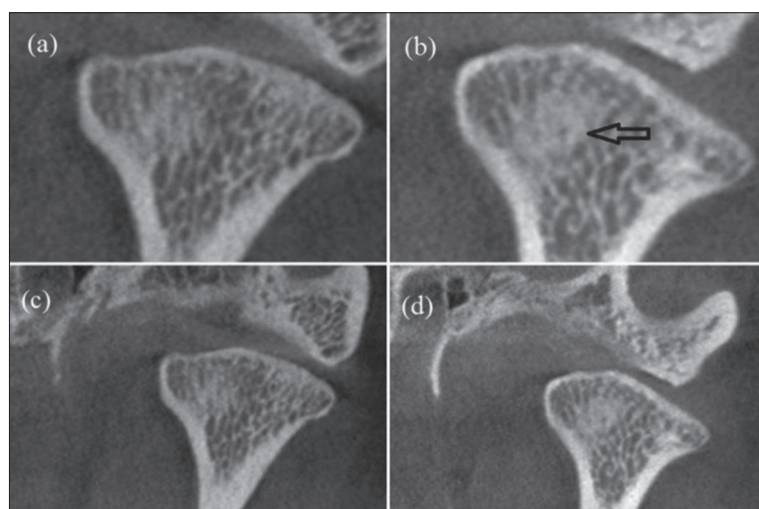


Figure 2. Osteoarthritis changes of the left and right temporomandibular joint (TMJ) on CBCT; the right TMJ without subcortical pseudocyst (a); subcortical pseudocyst of the left TMJ (b); ero-sion of the right (c) and the left (d) TMJ

surgical and physical therapy (*Dg. Pes equinovarus lat.dex, Th. Operatio: Plastica sec. Mc Kay*). Physical therapy lasted up to 18 years, the symptoms were in remission until the end of the 24th year, after which the onset of problems in the right leg occurred again. She was born with a visual impairment (nearsightedness, diopter -11), wherewith an adequate physical therapy the disorder was reduced by the time she was 18 years old (diopter -5.5). The patient denied the existence of the same or similar illness in the immediate and extended family.

By extraoral examination, non-assisted mouth opening without the onset of painful sensations was 27.04 mm, while the assisted mouth opening, regardless of the onset of pain, was 30.04 mm (Figure 1). In the TMJ, the pain occurred with a protrusive movement of 6 mm. During the right (5 mm) and left (7 mm) lateral movement of the lower jaw, the pain occurred in the area of both TMJs. Opening the mouth, the deviation of the mandible to the left was detected. The middle line of the face did not coincide with the middle of the dental arch. On a visual analogue scale (VAS = 0–10), the patient registered a painful sensation VAS = 9. Palpation of the masticatory and neck muscles showed no painful sensitivity, whereas palpation

of the lateral pole of both condyles showed severe pain with the presence of crepitus.

Intraoral examination and analysis of the orthopantomogram (OPG) showed the presence of a bilateral interrupted dental row of the upper jaw (missing teeth 16, 25, 26) and the presence of all teeth of the lower jaw. The teeth that were present were conservatively repaired, with no prosthetic replacement. The presence of skeletal class II was observed, the vertical overbite of the tooth amounted to 2 mm and horizontal overjet was 9 mm. The occlusion of the posterior teeth was normal. The periodontal condition of the teeth was preserved.

The radiological diagnostics of the patient's right and left TMJ was made with an Orthophos XG 3D apparatus (Sirona Dental Systems GmbH, Bensheim, Germany). The work area covered by the imaging was 8 × 8 cm. Analysis and 3D reconstruction was performed with the help of GALAXIS v1.9.4 software (Sirona Dental Systems GmbH). Analysis of 3D radiograms showed the articular surface of the temporal bone in the right joint was of the usual morphological structure, with slight erosion in the middle part of the articular surface of the temporal bone. The right articular extension of the lower jaw was of normal ovoid shape, with slight erosion near the medial pole of the condyle. The articular surface of the temporal bone in the left joint was of the usual morphological structure, with slight erosion in the middle and posterior part of the articular surface of the temporal bone.

The left articular extension of the lower jaw was of a normal ovoid shape, with the presence of a single subcortical pseudocyst oval in shape (0.64 mm × 0.81 mm) (Figure 2). The mediolateral dimensions of the head of the left condyle were significantly larger than those of the condyle on the opposite side, as were other measurements as well (Figure 3, 4).

The first therapeutic procedure in the treatment of the bilateral OA of the TMJ was to refer the patient to appropriate physical and psychological therapy. After satisfactory results were obtained, the patient underwent reversible occlusal therapy in the form of applying a stabilization splint (SS) in the position of the centric relation with the aim of raising the vertical dimension of the occlusion by 2 mm. The clinical and laboratory phases during the fabrication of the SS are shown in Figure 5. Wearing the splint overnight and for two hours a day, four to six weeks, was recommended. The patient also received anti-inflammatory medication (NSAID ibuprofen pills 0.4 g, 2 × 1, four weeks) and muscle relaxants [tolperison pills 0.15 g, 3 × 1 (first five days), 2 × 1 (next five days), and 1 × 1 (by the end of the month)]. Six months after wearing the SS, at the check-up, the patient reported the absence of pain, swelling in both TMJs, cessation of the headache and muscle tension in the

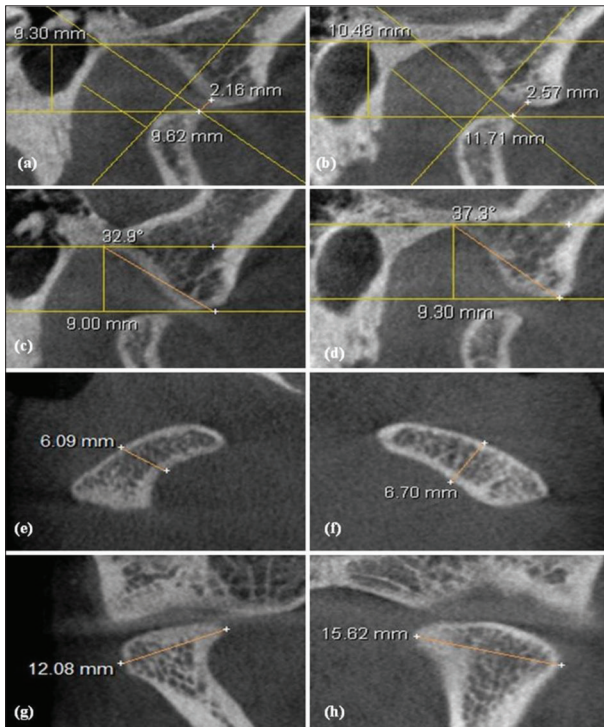


Figure 3. Dimensions of anatomical structures, right and left temporomandibular joint (TMJ) on CBCT; height of joint space of the right (front, posterior and upper joint space) (a), and the left (b) TMJ; sagittal condylar angle and depth of mandibular fossa of the right (c), and the left (d) TMJ; anterior–posterior dimension of a condyle head of the right (e), and the left (f) TMJ; medi-olateral dimension of a condyle head of the right (g), and the left (h) TMJ

orofacial region. She stated that low-intensity pain in the right and left TMJs, that did not interfere with normal life activities (VAS = 3) occurred during chewing of hard food. Maximal mouth opening improved with an intermaxillary separation of 39.09 mm (unassisted) and 46.22 mm (assisted) (Figure 6). When opening the mouth, there was still a mild deviation of the mandible to the left, and crepitus in both TMJs were still felt. The palpation of the lateral pole of both condyles did not result in painful sensitivity. Lower

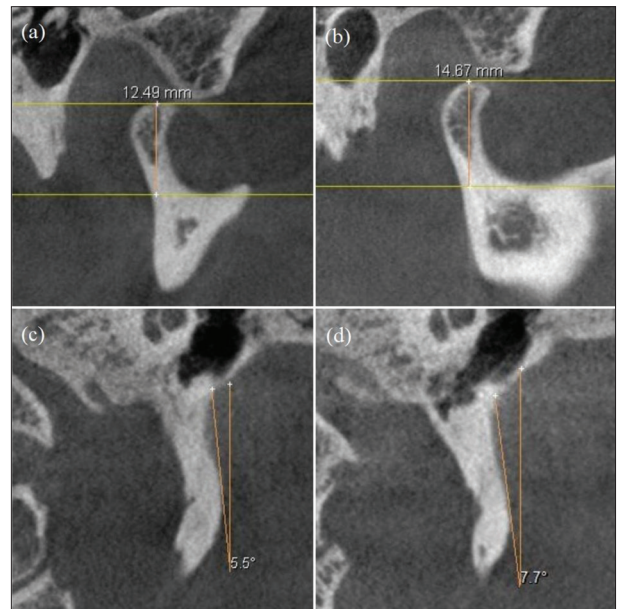


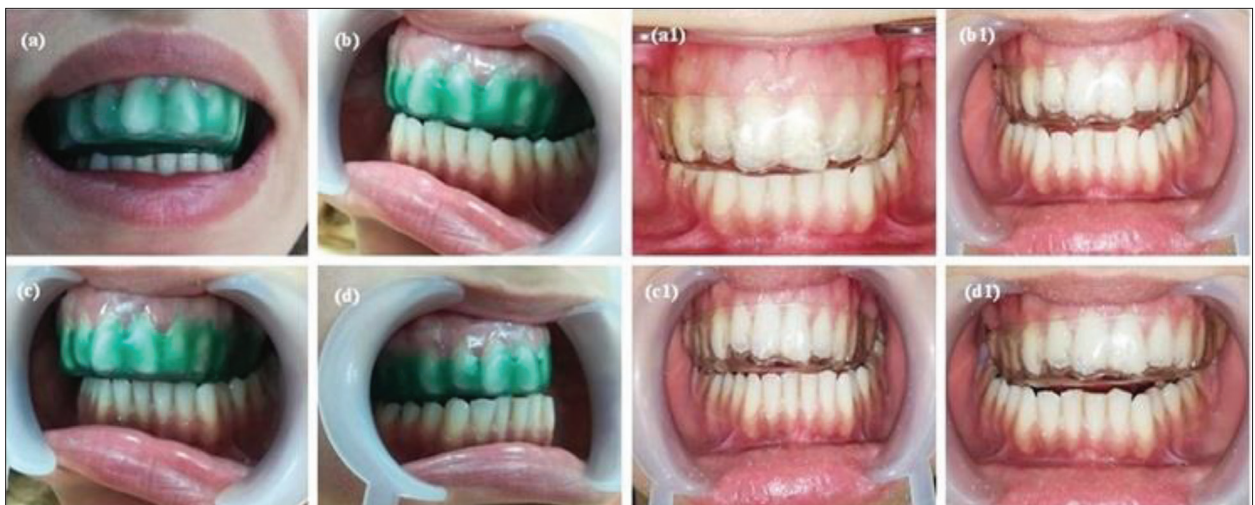Figure 4. Dimensions of anatomical structures, right and left temporomandibular joint (TMJ) on CBCT; condyle height of the right (a), and the left (b) TMJ; Bennett angle of the right (c), and the left (d) TMJ

jaw movements during the opening, protrusion, and left and right lateral movement did not cause pain.

Based on the achieved positive therapeutic effect, in order to maintain the remission of the disease, it was proposed to apply irreversible therapy in the form of fixed prosthetic dental replacement in the upper jaw, which would permanently correct the existing spatial relationship of the upper and the lower jaw and normalize relations within the masticatory system.

DISCUSSION

TMD are heterogeneous musculoskeletal disorders that result in the presence of chronic pain that significantly



Figur 5. Wax model and the definitive form of the stabilization splint (SS); wax model of the SS in centric relation (a), protrusive position (b); undisturbed guidance of the wax model of the SS in the left (c), and the right (d) lateral position; SS in centric relation (a1), protrusive position (b1); undisturbed guidance of the SS in the left (c1), and the right (d1) lateral position

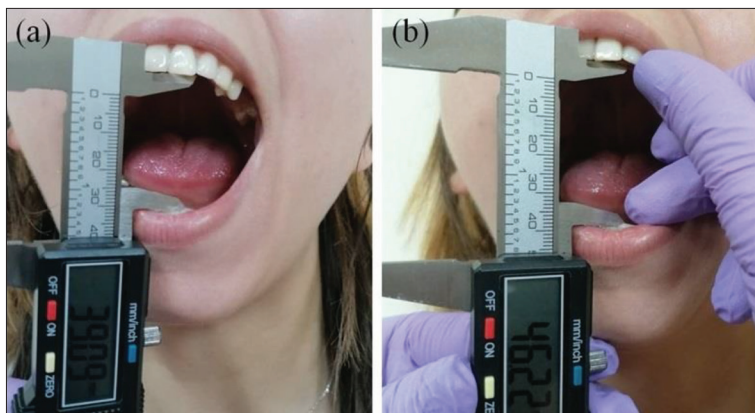

Figure 6. Assisted and non-assisted mouth opening after six months of therapy; non-assisted (a); assisted (b)

affects the quality of life, socio-psychological status, and inability to perform daily activities [6]. OA of the TMJ, as one of the subtypes of TMD, is a degenerative disease characterized by destructive changes of the TMJ structures and a condition that is still being researched [3].

In order to make an accurate diagnosis, it is necessary to detect the signs and symptoms of the disease through medical history, clinical examination, laboratory, and radiographic procedures [7]. The most common symptoms of TMD by extraoral examination are sound in the TMJ, painful sensitivity of the muscles on palpation, and lateral turning of the mandible during the mouth opening [8]. These symptoms were also present in our patient, except for the representation of painful sensitivity of the masticatory and neck muscles on palpation, whereas palpation of the lateral pole of both condyles showed severe pain with the presence of crepitus.

Computed tomography (CT) and CBCT are 3D TMJ imaging methods reliable in visualizing the bony contours of the mandibular condyle and mandibular fossa. In our study, the patient was diagnosed with the presence of OA of the TMJ by detecting symptoms and signs of the disease with the help of medical history, clinical examination, and radiographic methods (OPG, CBCT). Ahmad et al. [6] stated that the CBCT method in clinical practice has emerged as more acceptable and can be said to be a reliable tool in the diagnosis of OA by being able to perfectly detect the bone changes of the mandible condyle and mandibular fossa, including the presence of one or more changes such as osteophyte, surface erosion, subcortical pseudocyst, flattening, and subcortical sclerosis.

Therapy is multidisciplinary, aimed at reducing pain and inflammation in the TMJ, which improves the function of the orofacial system, prevents further development of the disorder, and partly eliminates the etiological factors that lead to the onset of the disorder [2, 7].

In our study, the patient was treated with non-invasive methods that included patient education, physical, medical, psychological, and SS therapy, which was a successful procedure, in the form of complete painlessness and range of motion of the lower jaw within the physiological limits, while avoiding invasive methods. There are different modalities of pharmacotherapy in the treatment of OA of the TMJ, but one of the most widely used, which we also used in our study, are NSAIDs, which play a role in reducing pain, inflammation and thus slow down the degenerative process, and muscle relaxants which have a role in regulation the reflex masticatory muscle spasm [7, 3]. SS therapy has a significant effect on

reducing the intensity of pain, improving the quality of life, and the comfortable mouth opening of patients, which is consistent with the results of our study [9, 10]. Kuzmanovic Pfcicer et al. [11] have indicated that SS can play a significant role in the treatment of TMDs in the short term (≤ 3 months), while in our study, the full positive effects of SS showed after six months, where in the third month of using SS, a significant improvement of the disease state appeared in our patient, but not the maximum positive effect of therapy. Ok et al. [12] have shown that SS treatment could be a successful therapy option for the reduction of bone resorption in the mandibular fossa of OA of the TMJ patients. The researchers indicate that the most appropriate method is the one that will achieve the best results with a less invasive approach with the aim of eliminating symptoms, stopping the progression of the disease, and improving the quality of life of the patient [3]. Kalladka et al. [7] agree that invasive techniques, if necessary, must be preceded by attempts to reduce OA of the TMJ symptoms by non-invasive methods, with surgical methods being considered only if non-invasive methods are in no way capable of eliminating the symptoms. Future research on this subject using an appropriate sample size would be of great value.

Based on the described case of a young patient's OA of the TMJ, the task of medical workers is primarily to recognize the symptomatology of the disease. As medical history and clinical diagnosis are not always characteristic, it is important to supplement the findings with adequate radiographic imaging techniques. Based on a proper diagnosis, the most acceptable therapeutic method will be the one that will achieve the best results with a less invasive approach. In our study, non-invasive therapy had a positive effect as a form of therapeutic modality.

Conflict of interest: None declared.

REFERENCES

1. Kandasamy S, Greene CS. The evolution of temporomandibular disorders: A shift from experience to evidence. *J Oral Pathol Med.* 2020;49(6):461–9.
2. Machon V, Hirjak D, Lukas J. Therapy of the osteoarthritis of the temporomandibular joint. *J Craniomaxillofac Surg.* 2011;39(2):127–30.
3. Tanaka E, Detamore MS, Mercuri LG. Degenerative disorders of the temporomandibular joint: etiology, diagnosis, and treatment. *J Dent Res.* 2008;87(4):296–307.
4. Walewski LA, Tolentino ES, Yamashita FC, Iwaki LCV, da Silva MC. Cone beam computed tomography study of osteoarthritic alterations in the osseous components of temporomandibular joints in asymptomatic patients according to skeletal pattern, gender, and age. *Oral Surg Oral Med Oral Pathol Oral Radiol.* 2019;128(1):70–7.
5. Alexiou K, Stamatakis H, Tsiklakis K. Evaluation of the severity of temporomandibular joint osteoarthritic changes related to age using cone beam computed tomography. *Dentomaxillofac Radiol.* 2009;38(3):141–7.
6. Ahmad M, Schiffman EL. Temporomandibular joint disorders and orofacial pain. *Dent Clin North Am.* 2016;60(1):105–24.
7. Kalladka M, Quek S, Heir G, Eliav E, Mupparapu M, Viswanath A. Temporomandibular joint osteoarthritis: diagnosis and long-term conservative management: a topic review. *J Indian Prosthodont Soc.* 2014;14(1):6–15.
8. Todić J, Lazić D, Radosavljević R. Correlation analysis of craniomandibular index and gothic arch tracing in patients with craniomandibular disorders. *Vojnosanit Pregl.* 2011;68(7):594–601.
9. Đorđević I, Todorović A, Lazić V, Obradović-Đuričić K, Milekić B, Stamenković D. Occlusal appliances – an alternative in pain treatment of temporomandibular disorders. *Srp Arh Celok Lek.* 2019;147(9–10):541–6.
10. Alajbeg IZ, Boric Brakus R, Brakus I. Comparison of amitriptyline with stabilization splint and placebo in chronic TMD patients: a pilot study. *Acta Stomatol Croat.* 2018;52(2):114–22.
11. Kuzmanovic P, Pficer J, Dodic S, Lazić V, Trajkovic G, Milic N, Milicic B. Occlusal stabilization splint for patients with temporomandibular disorders: meta-analysis of short and long term effects. *PLoS One.* 2017;12(2):e0171296.
12. Ok SM, Jeong SH, Ahn YW, Kim YI. Effect of stabilization splint therapy on glenoid fossa remodeling in temporomandibular joint osteoarthritis. *J Prosthodont Res.* 2016;60(4):301–7.

Неинвазивни приступ у терапији остеоартритиса темпоромандибуларног зглоба

Анђела Милојевић-Шамановић, Дејан Здравковић, Стефан Величковић, Милица Јовановић, Марко Милосављевић
 Универзитет у Крагујевцу, Факултет медицинских наука, Катедра за стоматологију, Крагујевац, Србија

САЖЕТАК

Увод Темпоромандибуларне дисфункције представљају скуп поремећаја који укључују масикаторне мишиће, темпоромандибуларни зглоб (ТМЗ) и његове придружене структуре. Остеоартритис, као једна од форми темпоромандибуларне дисфункције, доводи до трајних промена на коштаном строју ТМЗ. Ове промене могу бити узрок озбиљних функцијских поремећаја ТМЗ.

Приказ болесника Описује се случај 24-годишње болеснице која је затражила помоћ због болова и отока у пределу десног и левог ТМЗ, праћених мишићном напетосту, јаким главобољама, које нису реаговале на фармакотерапију. После успостављања дијагнозе, у лечењу остеоартритиса била-

тералног ТМЗ примењивали смо неинвазивну терапију. Шест месеци касније болесница није имала бол, отицање у оба ТМЗ, главобољу и напетост мишића у орофацијалној регији. **Закључак** Не постоји „златни стандард“ у терапији остеоартритиса ТМЗ. У овом приказу неинвазивна терапија је имала позитиван ефекат; постигнут је успех у уклањању бола, повећању опсега кретњи доње вилице, заустављању прогресије болести и побољшању квалитета живота.

Кључне речи: дисфункција темпоромандибуларног зглоба; остеоартритис темпоромандибуларног зглоба; стабилизациони сплент; компјутеризована томографија конусног зрака