



CASE REPORT / ПРИКАЗ БОЛЕСНИКА

Recurrent aphthous stomatitis as the only clinical sign of celiac disease in an obese adolescent – case report and literature review

Jelena Mandić¹, Nedeljko Radlović², Zoran Leković^{3,4}, Vladimir Radlović^{3,4}, Siniša Dučić^{3,4}, Dejan Nikolić^{3,4}, Olivera Jovičić¹

¹University of Belgrade, School of Dental Medicine, Clinic for Pediatric and Preventive Dentistry, Belgrade, Serbia;

²Serbian Medical Society, Academy of Medical Sciences, Belgrade, Serbia;

³University of Belgrade, Faculty of Medicine, Belgrade, Serbia;

⁴University Children's Hospital, Belgrade, Serbia

SUMMARY

Introduction Recurrent aphthous stomatitis (RAS) is a relatively common oral mucosal lesion of unclear etiology. It occurs in otherwise healthy people, but also in various infectious and non-infectious diseases, including celiac disease (CD). We present an obese adolescent with RAS as the only clinical sign of CD.

Case outline An adolescent aged 15 2/12 years come with very pronounced RAS in previous five months. He had no other difficulties. The patient was obese from the age of 12. Other data were without peculiarities. On admission he was 165 cm tall (P25), obese (BMI 27 kg/m²), in the final stage of puberty, with stretch marks in the distal areas of the abdomen, thighs and gluteus and very pronounced pain-sensitive aphthae in the buccal and labial mucosa accompanied by swelling of the lips and perioral region. Except for lower serum iron levels (8 μmol/l), routine laboratory blood tests were within the reference range. The serological test for CD was positive (antibodies to tissue transglutaminase IgA 78.5 U/ml, anti-endomysial antibodies IgA positive). Endoscopy revealed reflux esophagitis, without any other pathological findings. Stereomicroscopic and pathohistological analysis of the duodenal mucosa samples showed mild destructive enteropathy (Marsh IIIa). Pathohistological examination of the gastric mucosa revealed grade I-II lymphocytic gastritis. The urease test for *Helicobacter pylori* was negative. A gluten-free diet resulted in the withdrawal of aphthous stomatitis and no recurrence later.

Conclusion Within the differential diagnostic analysis of the RAS causes, CD should also be considered. Additionally, obesity does not exclude the presence of CD.

Keywords: recurrent aphthous stomatitis; celiac disease; obesity

INTRODUCTION

Recurrent aphthous stomatitis (RAS) is a relatively common oral mucosal lesion [1–5]. It occurs in children as well as in adults and the elderly [1, 2]. The most common age of onset is the second and third decade of life, becoming less common with advancing age [1]. It is slightly more common in females than in males [3]. In the United States, it is found in 0.89–1.64% of the general population, and in some countries even more often [1]. The cause of RAS is not clear [1, 3]. It is seen in otherwise healthy people, but also in various infectious and non-infectious diseases, including celiac disease (CD) [1, 6–15]. In addition, RAS is associated with genetic predisposition, iron and vitamin B12 deficiency, local mechanical injuries, stress, and hormonal imbalance [16, 17, 18]. We present an obese adolescent with RAS as the only clinical manifestation that indicated CD.

RAS in previous five months (Figures 1 and 2). He had no other difficulties. Oral aphthous eruptions were not associated with infection, local trauma, stress, or any other factor. Personal and family history in terms of allergic diathesis was negative. Standard local therapeutic measures did not give the desired effect. From the age of 12, he began to gain weight. Also, he complained of occasional episodes of post-prandial heartburn. Other data from personal and family history without peculiarities. On admission, the patient was 165 cm tall (P25), obese (BMI 27 kg/m²), in the final stage of puberty, with stretch marks in the distal areas of the abdomen, thighs, and gluteus, and very pronounced pain-sensitive aphthae in the buccal and labial mucosa accompanied by swelling of the lips and perioral region. Erythrocyte sedimentation rate, C-reactive protein, blood count, bilirubin, serum glutamic pyruvic transaminase, serum glutamic oxaloacetic transaminase, creatinine, lipid profile, creatinine, and other laboratory analyses, except lower serum iron levels (8 μmol/l), were within their reference ranges. IgA antibodies to tissue transglutaminase (AtTG) were elevated (78.5 U/ml) and anti-endomysial antibodies IgA positive.

CASE REPORT

A boy aged 15 2/12 years referred for examination and treatment due to very pronounced

Received • Примљено:
June 26, 2020

Revised • Ревизија:
August 20, 2020

Accepted • Прихваћено:
August 25, 2020

Online first: September 8, 2020

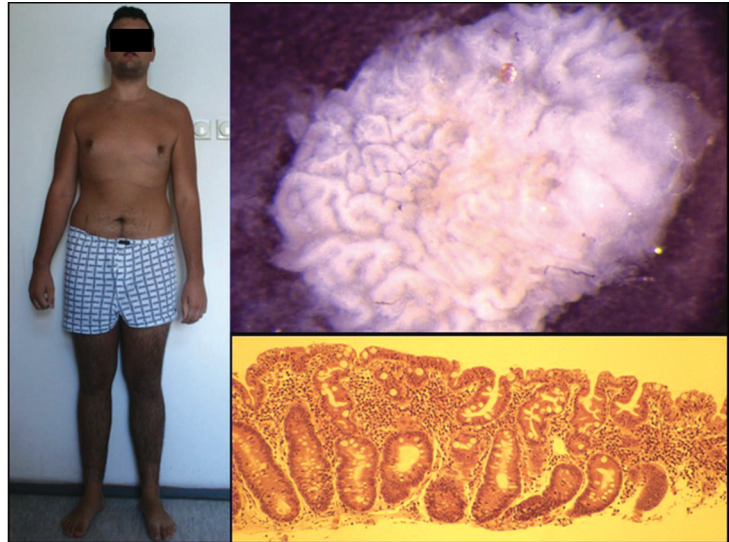
Correspondence to:

Nedeljko RADLOVIĆ
Academy of Medical Sciences of
the Serbian Medical Society
Džordža Vašingtona 19
11000 Belgrade, Serbia
n.radlovic@beotel.net

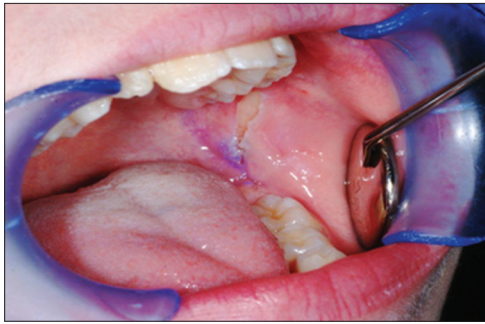

Figure 1. Deep aphthous change treated with gentian violet

Figure 2. Our patient with stereomicroscopic (top) and pathohistological (bottom) appearance of the small intestinal mucosa ▶



Esophagogastroduodenoscopy revealed reflux esophagitis, without any other pathological findings. Stereomicroscopic and pathohistological analysis of the duodenal mucosal samples showed mild destructive enteropathy (Marsh IIIa) (Figure 2). Pathohistological examination of the gastric mucosa revealed grade I-II lymphocytic gastritis. The urease test for *Helicobacter pylori* was negative. A gluten-free diet resulted in the withdrawal of aphthous stomatitis and no recurrence later. In addition, he received instructions related to the correction of diet and the inclusion of appropriate physical activity in order to normalize body weight. At the control examination after three months, normal values of serum iron and ferritin were registered, which was also the case with AtTG after six months. The degree of obesity, however, remained unchanged.

DISCUSSION

CD is a systemic autoimmune disease induced by gluten and related prolamins of wheat, rye, and barley [19]. It occurs as a result of a polygenic predisposition in a set of *HLA DQ2* and *HLA DQ8* genes that play the central role [19]. Although present in all population groups, it is most common in the white population (~1%) [20]. The basis of the disease and the key finding in its diagnostics is symptomatic or asymptomatic gluten-sensitive enteropathy, a nonspecific inflammation of the small intestinal mucosa that disappears on a gluten-free diet [19]. In addition to enteropathy, the disease is also characterized by a full spectrum of extraintestinal manifestations, including RAS [19, 21–25]. What makes our patient unusual is the fact that

RAS was the only sign to indicate CD. In addition, he was obese, which is also atypical for CDs [19]. According to the data obtained from the father and the boy himself, the eruptions to the standard local therapy-resistant five-month RAS were not related to intercurrent infections, local mechanical injuries, and stressful situations [10, 13, 14, 16]. Also, he did not show a tendency to allergic manifestations [13]. Having in mind this fact, regardless of the boy's obesity, serological screening on CD was performed. Since AtTG IgA were elevated (78.5 U/ml) and anti-endomysial antibodies IgA positive, in accordance with the criteria of the European Society for Pediatric Gastroenterology, Hepatology, and Nutrition for the diagnosis of CD, enterobioscopy was performed [19]. The morphological appearance of the small intestinal mucosa, both stereomicroscopically and pathohistologically, was consistent with the diagnosis of CD. A gluten-free diet resulted in the complete withdrawal of RAS, as found by other authors [26, 27]. In the further course with a strict gluten-free diet, the patient did not have recurrences of aphthous stomatitis. At the control examination after three months, normal values of serum iron and ferritin were registered, which was also the case with AtTG after six months.

In conclusion, the combination of RAS and obesity in clinical presentation with CD is extremely rare. Hence, in our experience, CD should be kept in mind, even in obese patients, as a cause of RAS.

Ethical standards: Written consent for the publication of this article was obtained from the patient's parents.

Conflict of interest: None declared.

REFERENCES

- Rivera C. Essentials of recurrent aphthous stomatitis. *Biomed Rep.* 2019;11(2):47–50.
- Gürkan A, Özlü SG, Altraylık-Özer P, Kurtul BE, Karacan CD, Şenel S. Recurrent aphthous stomatitis in childhood and adolescence: A single-center experience. *Pediatr Dermatol.* 2015;32(4):476–80.
- Akintoye SO, Greenberg MS. Recurrent aphthous stomatitis. *Dent Clin North Am.* 2014;58(2):281–97.
- Fitzpatrick SG, Cohen DM, Clark AN. Ulcerated lesions of the oral mucosa: Clinical and histologic review. *Head Neck Pathol.* 2019;13(1):91–102.

5. Edgar NR, Saleh D, Miller RA. Recurrent aphthous stomatitis: A review. *J Clin Aesthet Dermatol*. 2017;10(3):26–36.
6. Radlović N. Celiac disease in children – modern diagnostic approach. *Srp Arh Celok Lek*. 2008;136 Suppl 2:152–7.
7. Caio G, Volta U, Sapone A, Leffler DA, De Giorgio R, Catassi C, et al. Celiac disease: a comprehensive current review. *BMC Med*. 2019;17(1):142.
8. Al Homaidhi MA. The effect of celiac disease on the oral cavity: a review. *J Dent Health Oral Disord Ther*. 2018;9(1):43–7.
9. Macho VMP, Coelho AS, Veloso E Silva DM, de Andrade DJC. Oral manifestations in pediatric patients with coeliac disease – A review article. *Open Dent J*. 2017;11:539–45.
10. Gomes CC, Gomez RS, Zina LG, Amaral FR. Recurrent aphthous stomatitis and *Helicobacter pylori*. *Med Oral Patol Oral Cir Bucal*. 2016;21(2):e187–91.
11. Bıçak DA, Urgancı N, Akyüz S, Usta M, Uslu Kızılkın N, Alev B, et al. Clinical evaluation of dental enamel defects and oral findings in coeliac children. *Eur Oral Res*. 2018;52(3):150–6.
12. Rodrigo L, Beteta-Gorriti V, Alvarez N, de Castro CG, de Dios A, Laura Palacios, et al. Cutaneous and mucosal manifestations associated with celiac disease. *Nutrients*. 2018;10(7):800.
13. Giannetti L, Murri Dello Diago A, Lo Muzio L. Recurrent aphthous stomatitis. *Minerva Stomatol*. 2018;67(3):125–8.
14. Li L, Gu H, Zhang G. Association between recurrent aphthous stomatitis and *Helicobacter pylori* infection: a meta-analysis. *Clin Oral Investig*. 2014;18(6):1553–60.
15. Macho V, Manso MC, Silva D, Andrade D. Does the introduction of gluten-free diet influence the prevalence of oral soft tissue lesions in celiac disease?. *J Int Oral Health*. 2019;11(6):347–52.
16. Yılmaz S, Tuna Kırsaçlıoğlu C, Şaylı TR. Celiac disease and hematological abnormalities in children with recurrent aphthous stomatitis. *Pediatr Int*. 2020;62(6):705–10.
17. Ślebioda Z, Krawiec E, Szponar E, Dorocka-Bobkowska B. Haematinic deficiencies and patient clinical profiles in Polish patients with recurrent aphthous stomatitis (RAS). *J Oral Pathol Med*. 2018;47(5):531–7.
18. Chiang CP, Yu-Fong Chang J, Wang YP, Wu YH, Wu YC, Sun A. Recurrent aphthous stomatitis - Etiology, serum autoantibodies, anemia, hematinic deficiencies, and management. *J Formos Med Assoc*. 2019;118(9):1279–89.
19. Husby S, Koletzko S, Korponay-Szabó IR, Mearin ML, Phillips A, Shamir R, et al; ESPGHAN Working Group on Coeliac Disease Diagnosis; ESPGHAN Gastroenterology Committee; European Society for Pediatric Gastroenterology, Hepatology, and Nutrition. European Society for Pediatric Gastroenterology, Hepatology, and Nutrition guidelines for the diagnosis of coeliac disease. *J Pediatr Gastroenterol Nutr*. 2012;54(1):136–60.
20. Choung RS, Larson SA, Khaleghi S, Rubio-Tapia A, Ovsyannikova IG, King KS, et al. Prevalence and morbidity of undiagnosed celiac disease from a community-based study. *Gastroenterology*. 2017;152(4):830–9.e5.
21. Aydemir S, Tekin NS, Aktunç E, Numanoğlu U, Gündoğdu Y. Celiac disease in patients having recurrent aphthous stomatitis. *Turk J Gastroenterol*. 2004;15(3):192–5.
22. Shakeri R, Zamani F, Sotoudehmanesh R, Amiri A, Mohamadnejad M, Davatchi F, et al. Gluten sensitivity enteropathy in patients with recurrent aphthous stomatitis. *BMC Gastroenterol*. 2009;9:44.
23. Yaşar S, Yaşar B, Abut E, Aşiran Serdar Z. Clinical importance of celiac disease in patients with recurrent aphthous stomatitis. *Turk J Gastroenterol*. 2012;23(1):14–8.
24. Marty M, Bailleul-Forestier I, Vaysse F. Recurrent aphthous stomatitis as a marker of celiac disease in children. *Pediatr Dermatol*. 2016;33(2):241.
25. Gürkan A, Özlü SG, Özer PA, Kurtul BE, Karacan CD, Şenel S. Response to “recurrent aphthous stomatitis as a marker of celiac disease in children”. *Pediatr Dermatol*. 2016;33(2):242.
26. Pastore L, Carroccio A, Compilato D, Panzarella V, Serpico R, Lo Muzio L. Oral manifestations of celiac disease. *J Clin Gastroenterol*. 2008;42(3):224–32.
27. Campisi G, Di Liberto C, Carroccio A, Compilato D, Iacono G, Procaccini M, et al. Celiac disease: oral ulcer prevalence, assessment of risk and association with gluten-free diet in children. *Dig Liver Dis*. 2008;40(2):104–7.

Рекурентни афтозни стоматитис као једини клинички знак целијачне болести код обезног адолесцента – приказ болесника и преглед литературе

Јелена Мандић¹, Недељко Радловић², Зоран Лековић^{3,4}, Владимир Радловић^{3,4}, Сениша Дучић^{3,4}, Дејан Николић^{3,4}, Оливера Јовичић¹

¹Универзитет у Београду, Стоматолошки факултет, Клиника за дечју и превентивну стоматологију, Београд, Србија;

²Српско лекарско друштво, Академија медицинских наука, Београд, Србија;

³Универзитет у Београду, Медицински факултет, Београд, Србија;

⁴Универзитетска дечја клиника, Београд, Србија

САЖЕТАК

Увод Рекурентни афтозни стоматитис (РАС) представља релативно честу оралну мукозну лезију нејасне етиологије. Јавља се код иначе здравих особа, али и у склопу различитих инфективних и неинфективних обољења, укључујући и целијачну болест (ЦБ). Приказујемо обезног адолесцента са РАС као јединим клиничким знаком ЦБ.

Приказ болесника Адолесцент узраста 15 2/12 година долази са веома израженим РАС последњих пет месеци. Друге сметње није имао. Гојазан је од 12. године. Остали подаци били су без особености. На пријему је висок 165 cm (П25), гојазан (БМИ 27 kg/m²), у завршној фази пубертета, са стријама у подручју дисталних подручја абдомена, бутина и глутеуса и веома израженим болно осетљивим афтама у подручју букалне и лабијалне слузокоже праћеним отоком усана и периоралног региона. Сем нижег нивоа серумског гвожђа (8 μmol/l), рутинске лабораторијске анализе крви су биле

у референтном оквиру. Серолошки тест на ЦБ је био позитиван (антитела на ткивну трансглутаминазу IgA 78,5 U/ml, антиендомизијумска антитела IgA класе позитивна). Ендоскопијом је констатован рефлукс езофагитис, без другог патолошког налаза. Стереомикроскопска и патохистолошка анализа узорака слузокоже дуоденума су показале лакшу деструктивну ентеропатију (*Marsh IIIa*). Патохистолошким прегледом слузокоже желуца установљен је лимфоцитни гастритис I-II степена. Уреазни тест на *Helicobacter pylori* је био негативан. Дијета без глутена резултирала је повлачењу афтозног стоматитиса и није било рецидива у каснијем току. **Закључак** У оквиру дифенцијално-дијагностичког разматрања узрока РАС треба узети у обзир и ЦБ. Додатно, гојазност не искључује присуство ЦБ.

Кључне речи: рекурентни афтозни стоматитис; целијачна болест; обезитет