

ORIGINAL ARTICLE / ОРИГИНАЛНИ РАД

The diabetic dental pulp repair – involvement of vascular endothelial growth factor and bone morphogenetic protein 2

Jugoslav Ilić¹, Katarina Radović², Božidar Brković³, Jugoslav Vasić⁴, Jelena Roganović⁵¹University of Belgrade, School of Dental Medicine, Department of Restorative Odontology and Endodontics, Belgrade, Serbia;²University of Belgrade, School of Dental Medicine, Department of Prosthetic Dentistry, Belgrade, Serbia;³University of Belgrade, School of Dental Medicine, Department of Oral Surgery, Belgrade, Serbia;⁴University of Belgrade, School of Veterinary Medicine, Department of Surgery, Orthopedics and Ophthalmology, Belgrade, Serbia;⁵University of Belgrade, School of Dental Medicine, Department of Pharmacology in Dentistry, Belgrade, Serbia**SUMMARY****Introduction/Objective** We aimed to investigate the effects of diabetes mellitus (DM) on rat dental pulp repair by measuring time-dependent changes in expressions of vascular endothelial growth factor (VEGF) and bone morphogenetic protein 2 (BMP 2) following direct pulp capping.**Methods** Two groups, each of 20 Wistar rats, received either streptozotocin (for DM induction) or the same volume of sterile saline. A week later, the pulp of maxillary and mandibular right incisors in diabetic and non-diabetic groups were exposed and capped with calcium hydroxide in order to provoke reparative response. The levels of VEGF and BMP 2 were determined in the pulp tissue lysates one and seven days after the pulp capping, using enzyme-linked immunosorbent assays.**Results** Diabetic state *per se* increased VEGF level, with a peak at first day after the pulp capping (19.3 ± 0.9 pg/mg, $p < 0.001$), but did not affect BMP 2 levels. Significant increase of BMP 2 expression was noticed on the seventh day in capped pulp, but only in diabetic rats (16.7 ± 1 pg/mg, $p = 0.001$). Positive correlation between VEGF and BMP 2 was found on the seventh day following capping, only in diabetic pulp ($r = 0.905$, $p = 0.003$).**Conclusion** Diabetes-induced increase in VEGF expression reflects changes in the inflammatory phase of pulp repair in DM. Increase in BMP 2 expression suggest that stimulating effect of calcium hydroxide appears seven days after diabetic pulp capping.**Keywords:** dental pulp capping; diabetes; vascular endothelial growth factor; bone morphogenetic protein 2; calcium hydroxide**INTRODUCTION**

Under pathological conditions, such as injury or infection, the dentine–pulp complex shows significant reparative response initiated by an inflammatory reaction, prerequisite for pulp healing and mediated principally by macrophages [1]. Besides clearing the injury site, macrophages are the main source of the growth factors (GF), including vascular endothelial growth factor (VEGF) and bone morphogenetic protein 2 (BMP 2), required for tissue repair [2, 3].

Dental pulp repair rely on dental pulp stem cells that migrate to the site of injury, differentiate and proliferate into endothelial cells, involved in angiogenesis, or into odontoblasts – for dentin generation, processes regulated by GF, among others VEGF and BMP 2 [1, 4]. Recent study by Aksel et al. [4] showed that *in vitro* delivery of VEGF and BMP 2 significantly enhanced the angiogenic and odontogenic potential of human dental pulp stem cells. Noteworthy, the alteration in expression of VEGF

and BMP 2 has been identified within human dental pulp cells in inflammation as well as in human diabetic pulp tissue [5, 6, 7].

Diabetes mellitus (DM) impedes the healing of dental pulp resulting in inadequate reparative response, yet underlying molecular mechanisms are still not clarified [8]. A recent study investigating diabetic wound healing point at alterations in the inflammatory phase due to macrophages dysfunction as a critical event in impaired tissue healing in DM [9]. Having in mind that the dental pulp, due to its limited collateral circulation, is especially sensitive to diabetes-induced circulatory disorder and associated failure to deliver components of the immune system and GF, we aimed to investigate effects of diabetes on initial events of dental pulp repair by means of measuring time-dependent changes in VEGF and BMP 2 expression in rat dental pulp following direct capping [10].

Received • Примљено:

February 28, 2020

Accepted • Прихваћено:

August 5, 2020

Online first: September 3, 2020**Correspondence to:**Jelena Roganović
Dr Subotića 8
11000 Belgrade, Serbia
jelena.roganovic@stomf.bg.ac.rs

METHODS

Reagents

Streptozotocin (STZ) was purchased from Sigma-Aldrich (Sigma-Aldrich, St. Louis, MO, USA). The enzyme-linked immunosorbent assay (ELISA) kits for VEGF (Rat VEGF ELISA Kit) were purchased from RayBiotech Inc. (RayBiotech Inc., Norcross, GA, USA) and the ELISA kits for BMP 2 (Quantikine BMP-2 Immunoassay) were purchased from R&D Systems Inc. (R&D Systems Inc., Minneapolis, MN, USA). Other reagents, medicaments, and dental materials were procured from standard local commercial suppliers.

Experimental animals

The study was conducted on 40 Wistar rats with a body weight between 250 g and 300 g obtained from the Military Medical Academy in Belgrade, Serbia. The study was reviewed and approved by the Ethics committee of the School of Dental Medicine, University of Belgrade (approval number: 36/8) and was carried out in accordance with the EU Directive 2010/63/EU for animal experiments. The animals were randomly allocated in either experimental (diabetic) or control (non-diabetic) group (20 animals per group). Both the experimental and the control group were additionally divided into two groups of 10 animals according to the duration of induced pulp reparative response (day one and day seven). All rats were housed in wire-bottomed cages (five animals per cage), with *ad libitum* food and water, on a 12-hour light-dark schedule.

Diabetes induction

All the animals underwent overnight fasting prior to induction of hyperglycemia by intraperitoneal injection of 60 mg/kg of STZ, *ex tempore* dissolved in sterile saline [11]. Animals in control group were injected with the same volume of sterile saline. Blood glucose levels were estimated on blood from tail vein using GlucoSure glucometer and Touch-In test strips (Apex Biotechnology Corp, Taiwan), five minutes before, 24 hours, and seven days after STZ or saline administration. Only the animals showing 200 mg/dl blood glucose level were considered as diabetic.

Operative procedures

One week after the STZ or sterile saline injection, all animals underwent cavity preparation procedures on distal surfaces of right mandibular and maxillary incisors in order to provoke pulp reparative response. Left incisors remained intact and served as controls. The rats were anaesthetized with an intramuscular injection of 20 mg/kg tiletamine-zolazepam combination (Zoletil 100, Virbac, Carros, France). Before cavity preparation, the oral cavity was disinfected with 0.2% chlorhexidine digluconate (Curasept 220, Curaden International AG, Kriens, Switzerland) and teeth additionally scrubbed with cotton pellet soaked with 70% ethanol. Aided with magnifying glasses (magnification 4.5×; Zeiss, Aalen, Germany), cavities were

prepared with a micro motor handpiece and a carbide round burs (ISO 006; NTI, Kahla, Germany) until the pulp was visible. The cavities were prepared under constant water cooling. Pulp exposure was subsequently treated with a sterile sharp probe (Ref. 27-3; HLW, Wernberg-Köblitz, Germany). The cavities were rinsed with saline solution, and hemostasis obtained with sterile, saline soaked paper points. After the careful air-drying of the cavities, pulp tissue was directly capped with calcium hydroxide (Ca(OH)₂) paste (Life; Kerr Corp., Orange, CA, USA) in order to induce reparative response, and cavities were restored using a self-etch, flowable composite restoration material (Vertise Flow; Kerr Corp., Orange, CA, USA).

Sample collection and preparation

Sacrifices of randomly chosen 10 animals in both diabetic and non-diabetic group were done one day after the capping procedure, using an overdose of thiopental-Na (Trapanal, Nycomed, Konstanz, Germany). The sacrifices of remaining 10 animals in diabetic and non-diabetic groups were done in the same way seven days after the induction of pulp reparation. The incisor teeth were extracted and split using excavators and pliers, and pulp tissue evacuated with sterile probes and tweezers. The samples of pulp in reparation were formed as pools of pulp tissue from right mandibular and maxillary incisors of a single animal. Similarly, pools of intact pulp tissue were obtained from contralateral intact incisors. Specimens were transferred directly to previously weighed Eppendorf tubes. Tubes with pulp tissue were then measured for total weight and stored at -70°C until further use. All weight measurements were conducted using high precision (readability: 10⁻⁴ g) Adventurer™ digital balance (OHAUS, Corp., Pine Brook, NJ, USA). The samples weights were calculated by subtracting total and empty tubes weights.

After homogenization, the pulp tissue lysates were centrifuged at 5000 g for 10 minutes in micro-centrifuge (Heraeus* Biofuge Primo R, Thermo Fisher Scientific, Waltham, MA, USA), the supernatants were collected, divided into two aliquots (for VEGF and BMP 2 concentration measurement) and stored at -70°C until further analysis.

Vascular endothelial growth factor and bone morphogenetic protein 2 quantification

Concentrations of VEGF and BMP 2 were measured in supernatants of rat pulp tissue lysates using ELISA kits according to the manufacturer's instructions. The absorbencies of microplate wells at 450 nm were recorded using Multiskan EX microplate reader (Thermo Fisher Scientific, Waltham, MA, USA). Each standard and sample was run in duplicate for both GF and the value used for statistical analysis was the average of two readings. The final GF concentrations of each pulp sample were normalized to its total weight. Results were expressed as pg/mg of pulp tissue.

Statistical analysis

Mean values and standard error of mean (SEM) were used for descriptive statistics of the sample. Parametric statistical analysis was used since the obtained concentrations of GF, blood glucose levels and body weight were normally distributed (Shapiro-Wilk test, $p > 0.05$) and variance of observed groups were homogenous ($p > 0.05$). Data were analyzed using one-way analysis of variance (ANOVA) with *post hoc* Holm-Sidak method for pairwise comparisons, and Pearson correlation coefficient. Analyses were computed with the statistical software SPSS Statistics for Windows, version 18.0 (SPSS Inc., Chicago, IL, USA). A p value less than 0.05 was considered to be statistically significant.

RESULTS

Variables of diabetic state

Diabetic animals expressed hyperglycemia and significant loss of body weight (Table 1).

Table 1. Glycaemia (mg/dL) and body weight (g) values in experimental animals

Group	Initial glycaemia	Final glycaemia	Initial weight	Final weight
Diabetic	90.8 ± 2	204.7 ± 2.3 ^a	277 ± 5.78 ^c	246 ± 6.18 ^d
Non-diabetic	95.1 ± 2.3	100.9 ± 2.2 ^b	287 ± 4.96	299 ± 3.7

^avs. glycaemia in all other groups;
^bvs. initial glycaemia in diabetic group;
^cvs. final body weight in diabetic group;
^dvs. body weight in nondiabetic groups;
 Values are presented as mean ± standard error of mean. Superscript letters represent significant differences ($p < 0.05$, One-way ANOVA & Holm-Sidak post hoc test).
 Diabetic group – experimental animals received streptozotocin; Non-diabetic group – experimental animals received saline; initial glycaemia and body weight values were estimated five minutes before Streptozotocin/saline injection; final glycaemia and body weight values were estimated at the time of sacrifice;

Vascular endothelial growth factor protein expression in dental pulp

Diabetic rats showed significant increase of the VEGF pulp levels ($p < 0.001$) compared to non-diabetic in both intact and capped pulp, regardless of examined capping time duration (Figure 1). Diabetes *per se* increased VEGF levels at both time points: 19.3 ± 0.9 pg/mg in diabetic vs. 11.7 ± 1.8 pg/mg in non-diabetic intact pulp on the first day, and 18.5 ± 0.6 pg/mg in diabetic vs 10.7 ± 1.2 pg/mg in non-diabetic intact pulp on the seventh day. Also, capping with Ca(OH)₂ *per se* increased VEGF levels on the first day both in diabetic pulp (28.2 ± 1.7 pg/mg in capped vs. 19.3 ± 0.9 pg/mg in intact pulp) and in non-diabetic (18.9 ± 1.0 pg/mg in capped vs. 11.7 ± 1.8 pg/mg in intact pulp).

Bone morphogenetic protein 2 protein expression in dental pulp

BMP 2 pulp levels were not significantly altered in diabetic compared to non-diabetic animals, in either intact or capped pulp. However, on the seventh day, diabetic capped pulp showed significantly higher BMP 2 levels compared to

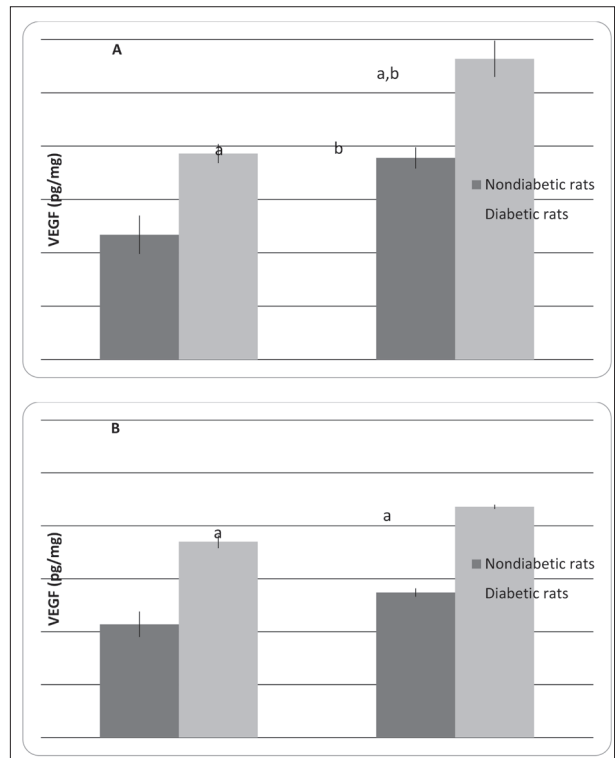


Figure 1. Vascular endothelial growth factor levels (pg/mg of tissue) in intact and capped dental pulp in diabetic and nondiabetic rat. Bars represent mean ± standard error of mean of pulp vascular endothelial growth factor levels on the first (A) and the seventh day (B) after pulp capping in diabetic and nondiabetic rat
^a $p < 0.001$ diabetic compared to nondiabetic rats;
^b $p < 0.001$ capped compared to intact pulp

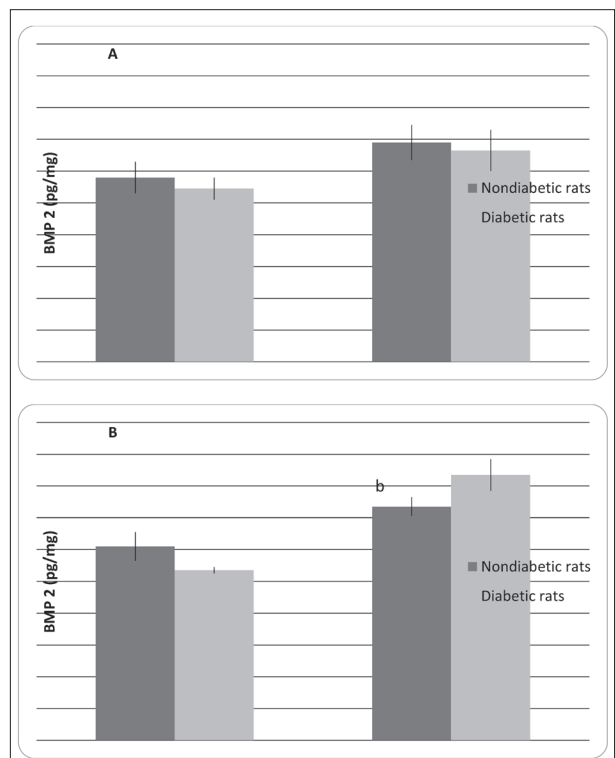


Figure 2. Bone morphogenetic protein 2 pulp concentrations (pg/mg of tissue) in intact and capped dental pulp in diabetic and nondiabetic rat. Bars represent mean ± standard error of mean of the pulp bone morphogenetic protein 2 levels on first (A) and seventh day (B) after pulp capping in diabetic and nondiabetic rat
 $b - p = 0.001$ capped compared to intact pulp

Table 2. Vascular endothelial growth factor and bone morphogenetic protein 2 correlations

Experimental groups		I	II	III	IV	V	VI	VII	VIII
	GF	VEGF	VEGF	VEGF	VEGF	VEGF	VEGF	VEGF	VEGF
I	BMP 2	r = -0.353 p = 0.560							
II	BMP 2		r = -0.248 p = 0.688						
III	BMP 2			r = 0.905* p = 0.0348					
IV	BMP 2				r = -0.410 p = 0.493				
V	BMP 2					r = -0.881* p = 0.0482			
VI	BMP 2						r = 0.592 p = 0.293		
VII	BMP 2							r = -0.363 p = 0.548	
VIII	BMP 2								r = -0.662 p = 0.224

GF – growth factor; r – Pearson correlation coefficient;

*significant correlation ($p < 0.05$); experimental groups: I – diabetic rats, capped pulp, first day; II – diabetic rats, intact pulp, first day; III – diabetic rats, capped pulp, seventh day; IV – diabetic rats, intact pulp, seventh day; V – non-diabetic rats, capped pulp, first day; VI – non-diabetic rats, intact pulp, first day; VII – non-diabetic rats, capped pulp, seventh day; VIII – non-diabetic rats, intact pulp, seventh day;

diabetic intact pulp (16.7 ± 1.0 pg/mg vs. 10.7 ± 0.2 pg/mg, $p = 0.001$) (Figure 2).

Vascular endothelial growth factor - bone morphogenetic protein 2 correlations

In non-diabetic animals, there was a significant negative correlation between pulp VEGF and BMP 2 levels on the first day after capping. In diabetic pulp samples, VEGF and BMP 2 were positively correlated on the seventh day after capping (Table 2).

DISCUSSION

Pulp healing in rats shows histological similarity to pulp healing in humans after direct pulp capping with different dentinogenetic-stimulating agents [12]. Although rat molar teeth are more frequently used as model for human teeth for histological analysis of dentin repair [13], in the present study, due to voluminous pulp, incisor teeth were used in order to provide the required amount of pulp tissue necessary for VEGF and BMP 2 quantification. Rodent incisor teeth, although differing from human for their constant growth, were proposed as a useful model for evaluating potential human dental pulp reactions to pulp capping agents and were used previously to evaluate several aspects of pulp repair and inflammation [14, 15]. The repair of dental pulp after direct capping by $\text{Ca}(\text{OH})_2$ implies following sequential steps: a moderate inflammation, migration of dental pulp stem cells, their proliferation and differentiation resulting in reparatory dentin formation [1]. Inflammation is prerequisite for pulp repair as a first step, resolved during the first week and is characterized by infiltration of macrophages starting from the first day after trauma or capping [1, 16]. Spiller

et al. [17] showed that M1 macrophages, predominant in initial inflammatory phase, express VEGF gene in order to support angiogenesis but also, VEGF is necessary for M1 to shift to M2 macrophage phenotype and to resolve inflammation [18].

Present results show that capping procedure induce VEGF expression being the prominent on the first day after the procedure while returning to control levels on the seventh day after the capping, suggesting significance of VEGF for the inflammatory phase of pulp repair after capping. Namely, previous studies showed an increase in capillary proliferation and inflammation being intensive one to three days after direct pulp capping of rat teeth with calcium hydroxide, suggesting time line for inflammatory phase following capping [12].

The effects of $\text{Ca}(\text{OH})_2$ as capping material rely on its dissociation into calcium and hydroxyl ions. Hydroxyl ions exhibit antibacterial properties due to alkaline reaction and stimulates reparative dentin formation [19]. Oxidation of hydroxyl ions results in formation of hydroxyl radicals, which is able, as reactive oxygen species (ROS), to induce VEGF expression [20]. Beside ROS, another potent stimulus for VEGF induction is hypoxia. In line with this, our results show that experimentally induced diabetes caused a significant increase of VEGF levels in intact and capped dental pulp. This is probably induced by both hyperglycemia and hypoxia, strong stimuli for VEGF induction, effects potentiated by the fact that dental pulp has limited or no collateral circulation, therefore is more prone to hypoxia-induced VEGF induction [21]. Furthermore, intensive ROS generation and resulting oxidative stress are hallmark of diabetes and induced VEGF [22] and, accordingly, our previous studies showed oxidative stress in dental pulp tissue of patients with type 2 DM [23]. In line with the proposed mechanism of redox-mediated VEGF induction by $\text{Ca}(\text{OH})_2$ and DM is the fact that present

results show the greatest VEGF induction in both capped and diabetic dental pulp. Having in mind that diabetic state is characterized by an imbalance in the ratio of M2-“anti-inflammatory” and M1-“pro-inflammatory” macrophages in the favor of the latter [24], present results of enhanced VEGF expression in DM could be reflecting proinflammatory state induced by M1 macrophages prevalence, but also VEGF overexpression could contribute to resolving inflammation by activation of M2 “anti-inflammatory macrophages”.

Regarding BMP-2 levels, present results show significant increase in BMP 2 expression only in diabetic rats, seven days after pulp capping, suggesting that BMP-2 induction depends on both Ca(OH)₂ and diabetic state. It is well known that BMP 2 promotes the differentiation of pulp stem cells into odontoblasts and production of reparative dentin, phases following inflammation resolution [25] which is in line with presently observed negative correlation between VEGF and BMP-2 observed on the first day after capping in non-diabetic pulps. Regarding mechanisms underlying stimulatory effects of calcium hydroxide on BMP 2 expression under diabetic state, it is noteworthy that in addition to ROS-stimulated BMP 2 expression [26], increased availability of Ca⁺² ions is also associated with an increase in cellular BMP 2 expression [27]. These effects are potentiated in the diabetic state- state of oxidative stress and acidic environment which enhance BMP 2 expression and stability [28] but also, BMP 2 -VEGF mutual association, suggested by observed positive correlation between BMP-2 and VEGF in DM. Having in mind that dental pulp stem cells isolated from diabetic patients show diminished

capacity for proliferation and differentiation and that BMP 2 supplementation enhanced differentiation of pulp stem cells into odontoblasts *in vitro* [29], present results point at the beneficial effects of calcium hydroxide as the direct capping agent in the DM for pulp repair.

CONCLUSION

Studies of dental pulp repair processes *in vivo* in humans are ethically and practically limited and, therefore, present results obtained in diabetic rat represent biologic background for consideration of therapies directed toward maintaining pulp vitality in diabetic dental pulp. Namely, we showed DM and calcium hydroxide induced increase in VEGF expression, which reflects changes in the inflammatory phase of pulp healing. On the other side, our results point to the beneficial effects of Ca(OH)₂ in direct capping in DM due to an increase in BMP 2 – the critical mediator for reparative dentin formation.

ACKNOWLEDGMENTS

The authors thank Prof. Dragica Stojić for her ideas, guidance and commitment, and Spomenka Lučić for her excellent laboratory support.

This work was supported by the Ministry of Education and Science, Republic of Serbia under Grant No. 175021.

Conflict of interests: None declared.

REFERENCES

- Goldberg M, Njeh A, Uzunoglu E. Is Pulp Inflammation a Prerequisite for Pulp Healing and Regeneration? *Mediators Inflamm.* 2015;2015:347649.
- Dube PR, Birnbaumer L, Vazquez G. Evidence for constitutive bone morphogenetic protein-2 secretion by M1 macrophages: Constitutive auto/paracrine osteogenic signaling by BMP-2 in M1 macrophages. *Biochem Biophys Res Commun.* 2017;491(1):154–8.
- Wang Y, Chang T, Wu T, Xu W, Dou G, Wang Y, et al. M2 macrophages promote vasculogenesis during retinal neovascularization by regulating bone marrow-derived cells via SDF-1/VEGF. *Cell Tissue Res.* 2020;380(3):469–86.
- Aksel H, Huang GTJ. Combined Effects of Vascular Endothelial Growth Factor and Bone Morphogenetic Protein 2 on Odontogenic Differentiation of Human Dental Pulp Stem Cells. *J Endod.* 2017;43(6):930–5.
- Dou L, Yan Q, Liang P, Zhou P, Zhang Y, Ji P. iTRAQ-Based Proteomic Analysis Exploring the Influence of Hypoxia on the Proteome of Dental Pulp Stem Cells under 3D Culture. *Proteomics.* 2018;18(3–4):1700215.
- Chen Y, Li X, Wu J, Lu W, Xu W, Wu B. Dental pulp stem cells from human teeth with deep caries displayed an enhanced angiogenesis potential *in vitro*. *J Dent Sci.* 2020 *In press.* [DOI: 10.1016/j.jds.2020.03.007]
- Ilić J, Radović K, Roganović J, Brković B, Stojić D. The Levels of Vascular Endothelial Growth Factor and Bone Morphogenetic Protein 2 in Dental Pulp Tissue of Healthy and Diabetic Patients. *J Endod* 2012;38(6):764–8.
- Garber SE, Shabahang S, Escher AP, Torabinejad M. The Effect of Hyperglycemia on Pulpal Healing in Rats. *J Endod.* 2009;35(1):60–2.
- Boniakowski AE, Kimball AS, Jacobs BN, Kunzel SL, Gallagher KA. Macrophage-Mediated Inflammation in Normal and Diabetic Wound Healing. *J Immunol* 2017;199(1):17–24.
- Catanzaro O, Dziubecki D, Lauria L, Ceron C, Rodriguez R. Diabetes and its effect on dental pulp. *J Oral Sci.* 2006;48(4):195–9.
- Cotter M, Jack A, Cameron N. Effects of the protein kinase Cβ inhibitor LY333531 on neural and vascular function in rats with streptozotocin-induced diabetes. *Clin Sci.* 2002;103(3):311–21.
- Dammaschke T, Stratmann U, Wolff P, Sagheri D, Schafer E. Direct Pulp Capping with Mineral Trioxide Aggregate: An Immunohistologic Comparison with Calcium Hydroxide in Rodents. *J Endod* 2010;36(5):814–9.
- Dammaschke T. Rat molar teeth as a study model for direct pulp capping research in dentistry. *Lab Anim.* 2010;44(1):1–6.
- Orhan EO, Maden M, Senguven B. Odontoblast-like cell numbers and reparative dentine thickness after direct pulp capping with plate let-rich plasma and enamel matrix derivative: a histomorphometric evaluation. *Int Endod J.* 2012;45(4):317–25.
- Davidović L, Čuk M, Sandić MŽ, Grga D, Živković S. The influence of liners on pulp inflammation. *Srp Arh Celok Lek.* 2015;143(5–6):261–6.
- Oishi Y, Manabe I. Macrophages in inflammation, repair and regeneration. *Int Immunol* 2018;30(11):511–28.
- Spiller KL, Anfang RR, Spiller KJ, Ng J, Nakazawa KR, Daulton JW, et al. The role of macrophage phenotype in vascularization of tissue engineering scaffolds. *Biomaterials.* 2014;35(15):4477–88.
- Wheeler KC, Jena MK, Pradhan BS, Nayak N, Das S, Hsu C-D, et al. VEGF may contribute to macrophage recruitment and M2 polarization in the decidua. *PLoS One.* 2018;13(1):e0191040.
- Widjastuti I, Dewi MK, Prasetyo EA, Pribadi N, Moedjiono M. The cytotoxicity test of calcium hydroxide, propolis, and calcium hydroxide-propolis combination in human pulp fibroblast. *J Adv Pharm Technol Res.* 2020;11(1):20–4.

20. Xian D, Song J, Yang L, Xiong X, Lai R, Zhong J. Emerging Roles of Redox-Mediated Angiogenesis and Oxidative Stress in Dermatoses. *Oxid Med Cell Longev*. 2019;2019:e2304018.
21. Huang GTJ. Pulp and dentin tissue engineering and regeneration: current progress. *Regen Med*. 2009;4(5):697–707.
22. Simão S, Bitoque DB, Calado SM, Silva GA. Oxidative stress modulates the expression of VEGF isoforms in the diabetic retina. *New Front Ophthalmol*. 2016;2(1):77–83.
23. Milosavljević A, Djukić L, Toljić B, Milašin J, Dželetović B, Brković B, et al. Melatonin levels in human diabetic dental pulp tissue and its effects on dental pulp cells under hyperglycaemic conditions. *Int Endod J*. 2018;51(10):1149–58.
24. Kraakman MJ, Murphy AJ, Jandeleit-Dahm K, Kammoun HL. Macrophage polarization in obesity and type 2 diabetes: weighing down our understanding of macrophage function? *Front Immunol*. 2014;5:e470.
25. Li S, Hu J, Zhang G, Qi W, Zhang P, Li P, et al. Extracellular Ca²⁺ Promotes Odontoblastic Differentiation of Dental Pulp Stem Cells via BMP2-Mediated Smad1/5/8 and Erk1/2 Pathways. *J Cell Physiol*. 2015;230(9):2164–73.
26. Sánchez-de-Diego C, Valer JA, Pimenta-Lopes C, Rosa JL, Ventura F. Interplay between BMPs and Reactive Oxygen Species in Cell Signaling and Pathology. *Biomolecules*. 2019;9(10):e534.
27. Honda Y, Anada T, Kamakura S, Nakamura M, Sugawara S, Suzuki O. Elevated extracellular calcium stimulates secretion of bone morphogenetic protein 2 by macrophage cell line. *Biochem Biophys Res Commun*. 2006;345(3):1155–60.
28. El Bialy I, Jiskoot W, Nejadnik MR. Formulation, delivery and stability of bone morphogenetic proteins for effective bone regeneration. *Pharm Res*. 2017;34(6):1152–70.
29. Shamel M, Al Ankily M, Bakr M. Proliferative Capacity and Differentiation Potential of Isolated Postnatal Human Dental Pulp Stem Cells in Diabetic Patients. *Stem Cells Regen Med*. 2017;1(3):1–6.

Репарација дијабетичне зубне пулпе – улога васкуларног ендотелног фактора раста и костног морфогенетског протеина 2

Југослав Илић¹, Катарина Радовић², Божидар Брковић³, Југослав Васић⁴, Јелена Рогановић⁵

¹Универзитет у Београду, Стоматолошки факултет, Клиника за болести зуба, Београд, Србија;

²Универзитет у Београду, Стоматолошки факултет, Клиника за стоматолошку протетику, Београд, Србија;

³Универзитет у Београду, Стоматолошки факултет, Клиника за оралну хирургију, Београд, Србија;

⁴Универзитет у Београду, Ветеринарски факултет, Клиника за хирургију, ортопедију и офталмологију, Београд, Србија;

⁵Универзитет у Београду, Стоматолошки факултет, Стоматолошка фармакологија, Београд, Србија

САЖЕТАК

Увод/Циљ Циљ ове студије био је да се испита ефекат дијабетеса мелитуса на репарацију зубне пулпе пацова утврђивањем временски зависних промена у експресији васкуларног ендотелног фактора раста (*VEGF*) и костног морфогенетског протеина 2 (*BMP 2*) после директног прекривања пулпе. **Методе** Истраживање је спроведено на пацовима соја вистар, подељеним у две групе од по 20 животиња, при чему је једна група добила стрептозотоцин (за индукцију дијабетеса мелитуса), а друга стерилни физиолошки раствор у истој запремини. После недељу дана пулпе максиларних и мандибуларних доњих инцизива код дијабетичних и недијабетичних животиња су експонирани и одмах затим прекривене калцијум-хидроксидом да би се изазвао репараторни одговор. Нивои *VEGF* и *BMP 2* су утврђивани у лизатима пулног ткива, првог и седмог дана после директног прекривања имуноензимским тестом *ELISA*.

Резултати Дијабетично стање је довело до раста нивоа *VEGF*, са максимумом утврђеним првог дана после прекривања пулпе ($19,3 \pm 0,9 \text{ pg/mg}$, $p < 0,001$), али није утицало на ниво *BMP 2*. Значајан пораст *BMP 2* је утврђен седмог дана после прекривања пулпе, али само код дијабетичних пацова ($16,7 \pm 1 \text{ pg/mg}$, $p = 0,001$). Код ових животиња у истом периоду после прекривања нађена је позитивна корелација између нивоа *VEGF* и *BMP 2* ($r = 0,905$, $p = 0,003$).

Закључак Дијабетесом индукован пораст експресије *VEGF* указује на промене у инфламаторној фази пулпне репарације. Пораст експресије *BMP 2* указује да се стимулативан репараторни ефекат калцијум-хидроксида јавља седмог дана после прекривања дијабетичне пулпе.

Кључне речи: прекривање пулпе; дијабетес; васкуларни ендотелни фактор раста; костни морфогенетски протеин 2; калцијум-хидроксид