



CASE REPORT / ПРИКАЗ БОЛЕСНИКА

Massive traumatic myositis ossificans

Dobrivoje Martinov^{1,2}, Tatjana Stojković-Jovanović¹, Ksenija Bošković³

¹Dorđe Joanović General hospital, Zrenjanin, Serbia;

²University of Novi Sad, Mihajlo Pupin Technical Faculty, Zrenjanin, Serbia;

³University of Novi Sad, Faculty of Medicine, Clinic for Medical Rehabilitation, Novi Sad, Serbia

SUMMARY

Introduction Traumatic myositis ossificans (TMO) is a rare condition, which can jeopardize athletic careers, especially in cases when a large ossification is formed.

The aim of this paper is to present the results of treating a large TMO mass by application of physical procedures.

Case outline A TMO mass of large dimensions was detected in a 13-year-old competitive athlete two months after the patient sustained a direct blow to the quadriceps. Physical treatment lasted three months. The patient was able to carry out normal daily activities and recreational sports activities without limitation eight months after the initial injury. The imaging over a five-year follow-up detected a decrease in height and width of the ossification, but also a discrete increase in its length.

Conclusion Physical therapy resulted in full functional recovery, regardless of the massive ossification. The height and width of the ossification was reduced, but its length increased.

Keywords: muscle injuries; large ossification; physical therapy

INTRODUCTION

Traumatic myositis ossificans (TMO) is defined as a non-neoplastic, extra-osseous proliferation of cartilage and bone in an area of muscle that has been exposed to trauma [1, 2]. It is a rare entity that has great clinical relevance, primarily because of malignant differential diagnosis [3]. Despite its benign nature, TMO can lead to a serious function impairment of extremities. For athletes, it represents a special problem because of prolonged absence from the sports field and the risk of compromising sporting career [4, 5]. “There are no objective criteria in the literature for a return to physical activity following myositis ossificans” (MO) [6].

In most cases, treatment is usually conservative, with analgesics and physical therapy [5, 7–10]. If surgical intervention is planned, there is general agreement that early surgery is contraindicated for this condition and that surgery should only be undertaken on mature lesions [4, 11, 12].

In the presented case, a massive ossification was identified, which had caused severe functional impairment of the extremities in a 13-year-old active handball player. After a three-month physical therapy, an excellent functional result was achieved. Applied physical therapy is described in detail in regard to the modalities and duration of the administration of agents, and could be used for the formation of a future common treatment protocol in similar cases. The imaging five-year follow-up found that the length of the ossification increased, which, to our knowledge, has not been published to date.

CASE REPORT

A 13-year-old athlete was referred to an orthopedist due to pain and swelling in the femur five days after sustaining a direct blow to the quadriceps during a handball match. The examination showed discrete swelling and moderate palpable pain in the middle third of the front femoral region. The patient had a normal gait cycle and full knee range of motion with mild to moderate pain after flexion of the knee of over 90°. A standard inactivity regime and non-steroidal anti-inflammatory drugs were prescribed.

Two months after the initial injury, the patient visited the doctor walking with crutches and a prominent limp, pronounced functional deterioration, restricted mobility in the knee joint, and pain in the region of the thigh and knee. The patient reported that he had incurred repeated injuries in the same region during his stay in a sports camp, where he had trained but in a lighter training regime.

Clinical findings showed a limp, with the leg in an antalgic position, and reduction in the knee movement to a greater degree. The range of motion in the knee was 10° of flexion contracture, and 20° of maximal flexion of the knee joint (range of motion 0–10–20; the first number denotes hyperextension, the second represents any degree of flexion contracture, and the third indicates the degree of flexion of the joint). Pain during knee movement, according to a visual analogue scale, was 7. There was also hypotrophy of the thigh musculature and diffusely local pain sensitivity on palpation in the middle third of the thigh. A physical

Received • Примљено:

April 27, 2016

Revised • Ревизија:

February 2, 2018

Accepted • Прихваћено:

February 5, 2018

Online first: February 13, 2018

Correspondence to:

Dobrivoje MARTINOV
Koste Nikolića 1
23000 Zrenjanin, Serbia
martinovd@yahoo.com

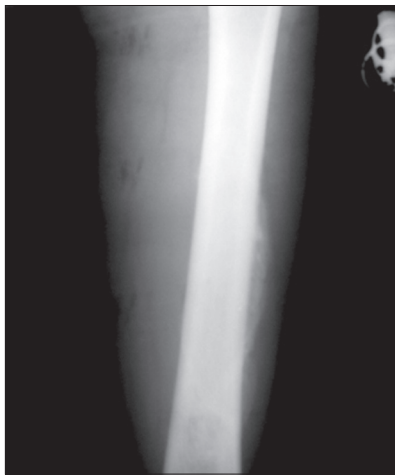

Figure 1. Anteroposterior radiograph of the femur obtained two months after the initial injury

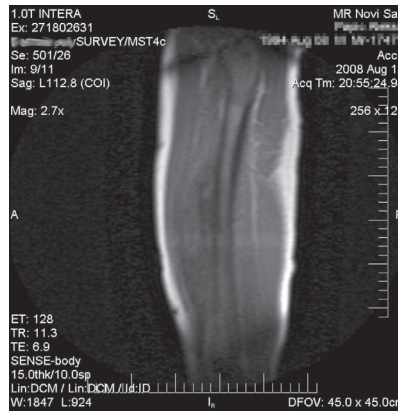

Figure 2. Sagittal magnetic resonance image obtained two months after the initial injury

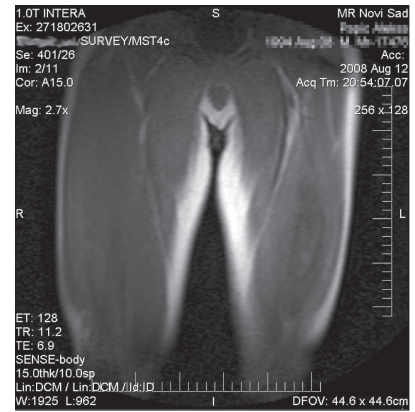

Figure 3. Frontal magnetic resonance image obtained two months after the initial injury

examination revealed a firm, massive, immobile mass in the anterior area of the thigh muscle. An anteroposterior radiograph of the femur aroused suspicion of a malignant process (Figure 1). After obtaining a second opinion at a higher-ranking institution, thus confirming the suspicion, magnetic resonance imaging (MRI) was performed (Figures 2 and 3). Based on the MRI findings, malign process was ruled out, and the diagnosis was established – TMO as a result of a repeated partial myofascial rupture. In addition to the MRI, an ultrasound was also done. Imaging revealed the greatest diameter of the mass to be 18.5 × 6 × 3 cm (length × width × thickness). The patient was then referred to physical therapy.

The physical treatment lasted three months (Table 1). The goal of the physical therapy was to increase the passive and active movement of the knee joint, to improve function, reduce pain, and improve the trophic of all involved structures and tissues around the osteoma and the knee joint. The rehabilitation program was designed in eight successive treatments based on the continuous assessment of the patient to avoid pain and reflexive spasm in the thigh muscle mass, as well as to preserve the integrity of the capsular structures at the knee while overcoming capsular restriction with the aim of returning the patient, as soon as possible, to sports and usual daily activities. The imaging follow-up included X-ray, MRI, and ultrasound.

Table 1. Treatments and modalities used in physical therapy during the three month rehabilitation

Therapy Series	Duration (days)	Physical therapy	ROM at the end of the series	VAS at the end of the series
I	15	<ul style="list-style-type: none"> • Kinesitherapy 45 minutes/day • Interferential current stimulation (1–100 Hz) 20 minutes/day • Hydro/kinesitherapy 30 minutes/day 	0/5/45	5/10
II	10	<ul style="list-style-type: none"> • Electrophoresis with potassium iodide 20 minutes/day • Diadynamic therapy 6 minutes/day • Kinesitherapy 45 minutes/day • Hydro/kinesitherapy 30–40 minutes/day 	0/5/60	4–5/10
III	10	<ul style="list-style-type: none"> • Transcutaneous electrical nerve stimulation 20 minutes/day • Kinesitherapy 45 minutes/day • Hydro/kinesitherapy 30–40 minutes/day 	0/5/70	4/10
IV	10	<ul style="list-style-type: none"> • Diadynamic therapy 6 minutes/day • Kinesitherapy 45 minutes/day • Hydro/kinesitherapy 30–40 minutes/day 	0/5/85	4/10
V	10	<ul style="list-style-type: none"> • Kinesitherapy 45 minutes/day • Hydro/kinesitherapy 30–40 minutes/day • Electrophoresis in Novocain 20 minutes/day • Massage 20 minutes/day 	0/0/90	3/10
VI	10	<ul style="list-style-type: none"> • Interferential current stimulation (1–100 Hz) 20 minutes/day • Kinesitherapy 45 minutes/day • Hydro/kinesitherapy 30–40 minutes/day 	0/0/100	3/10
VII	10	<ul style="list-style-type: none"> • Kinesitherapy 45 minutes/day • Transcutaneous electrical nerve stimulation 20 minutes/day • Diadynamic therapy 6 minutes/day • Massage 20 minutes/day 	0/0/105	2–3/10
VIII	10	<ul style="list-style-type: none"> • Kinesitherapy 45 minutes/day • Hydro/kinesitherapy 30–40 minutes/day • Heat (superficial) 15 minutes/day 	0/0/105	1–2/10

ROM – range of motion; VAS – visual analogue scale

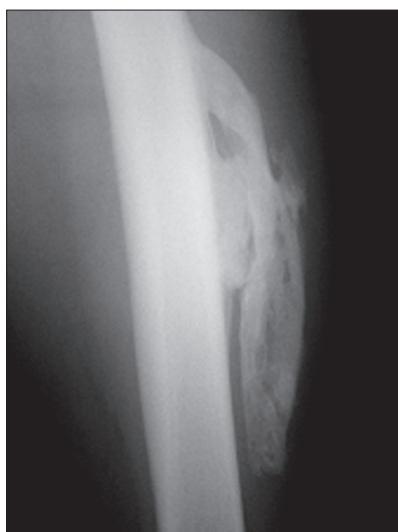

Figure 4. Lateral radiograph four months after the initial injury

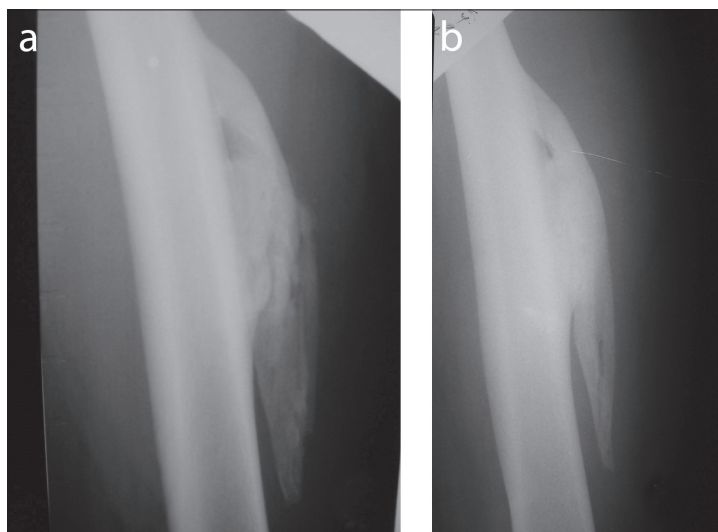


Figure 5. Lateral radiograph a) eight and b) fifteen months after the initial injury

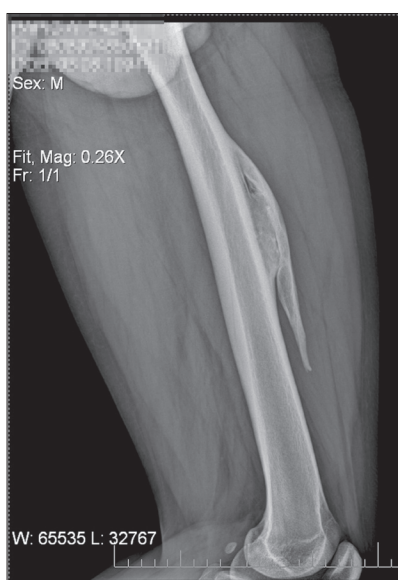


Figure 6. Follow-up radiograph five years after the initial injury

After completion of the rehabilitation treatment, the patient was able to carry out normal daily activities and recreational sports activities without limitation eight months after the initial injury. After a one-year follow-up, the patient definitely decided not to accept the operative treatment. He did not resume an active sports career.

After a five-year follow-up, he had no complaints of pain or problems in his usual daily activities. He was participating in recreational (volleyball, basketball, swimming, exercises in the gym) activities without difficulties, despite experiencing pain approximately once every two months, which was associated with daily and recreational overload and weather changes, but did not impair his overall lifestyle. He had a normal gait cycle, and full knee (130° of knee flexion) and hip range of motion (active and passive). Thigh circumference in the distal, middle, and proximal third was reduced by one centimeter compared to the uninjured side.

Imaging follow-up of MO detected changes in the shape, dimensions, and smoothness of the surface of the ossification (Figures 4 and 5). Maturation was finished after eight months and initial regression of the ossification was obvious after 15 months (Figure 5). Final radiographs revealed the greatest diameter of the mass to be 19.48 cm in length, 2.82 cm in width, and 2.39 cm in thickness (Figure 6). These results represent a decrease in the height and width, but also a discrete increase in the length of the existing mass.

DISCUSSION

Myositis ossificans is usually posttraumatic and potentially complicates hematoma formation of the muscles [2, 12]. It is common in active males, predominantly in healthy, vigorous young men. Any part of the body may be involved, but the anterior thigh is the most common site [4]. The incidence of this process ranges 9–20% in athletes who have sustained a direct blow from the body part of an opponent, most often the knee [4].

The initial damage is followed by soft tissue swelling, which grows within one to two months into a solid, painful mass. The form is benign, and develops over a period of 12–24 months, with spontaneous maturation and partial regression [2, 4, 5, 12].

The presented case had typical clinical features and disease course. One important characteristic sets it apart. According to its size, it is one of the largest ossifications described in the literature [5, 7–13] (Table 2).

Data about therapy are unproven with relevant research. It may be difficult to gain a consensus on optimal management of MO. “Treatment is not required in the vast majority of cases of heterotopic ossification” [14]. Various non-operative treatments have been reported [5, 8–11]. Apart from a large palpable mass, physical therapy and indomethacin have shown good results [5]. The administration of physiotherapy alone had been unsuccessful

Table 2. Comparison of myositis ossificans to the dimension and location – the greatest diameter of the mass

Authors	Location of ossification	Dimension of myositis ossificans (the largest mass) length × width × thickness (cm)
Orava et al. [12]	<i>vastus lateralis</i> m.	15 × 3 × 2
Srikanth et al. [8]	<i>rectus femoris</i> m.	15 × 6
Bagnulo et al. [9]	<i>vastus lateralis</i> m.	13.6 × 3.7 × 1.2
Yochum et al. [10]	<i>vastus intermedius</i> m.	18.33 × 4.04
Torrance et al. [11]	<i>vastus lateralis</i> m.	12 × 8
Drobnič et al. [13]	<i>vastus lateralis</i> m.	12 × 5
Sodl et al. [5]	bilateral – <i>vastus lateralis</i> m.	13.3 × 2.3 × 3.5 left; 12.2 × 2.2 right
Carmichael et al. [14]	hamstring m.	19 × 3
Presented case	<i>rectus femoris</i> m. <i>vastus intermedius</i> m.	19.48 × 2.82 × 2.39

m. – muscle

and only when the treatment with shockwaves was added did the management of MO become efficient [2]. On the other hand, extremely effective potential for the therapeutic program of acetic acid iontophoresis and ultrasound in eliminating MO has reflected in rapid recovery (after three weeks of treatment and six weeks after injuries) and a 98.9% decrease in the size of the ossified mass [15]. Similarly, all patients showed signs of functional improvement immediately after shockwave therapy. Two months after therapy, a normal range of motion and no signs of

weakness were observed. Three months after treatment, 87.5% of patients resumed regular sports activities [2]. This versatility makes it clear that the gold standard has not been established.

The data from the literature are often not comparable. However, surgery is indicated in those athletes who develop a large mass of mature lamellar bone, which is painful and is associated with muscle weakness and a significant loss of joint motion [4, 11, 12]. In the presented case, the patient decided not to accept surgical intervention. Readiness for recreational sports activities was achieved eight months after the initial injury. An extremely large ossification and devastating clinical picture at the start of therapy are the main reasons for the length of the recovery in the presented case.

In most cases, there is a slight change in the dimensions of the lesion, as well as partial resorption and stabilization of the ossification after conservative management, but again, like in our case report, a full functional recovery was achieved, regardless of the ossification size [2]. The dimensions of the ossification in our report were measured with different types of equipment (MRI, X-ray, ultrasound) and therefore the change in the size of the ossification mass during the five-year monitoring period should be taken with caution. Nevertheless, it can be concluded that the height and width of the ossification mass was reduced. Increasing the length of the ossification, if not the result of measurement errors, can be the result of repeated micro-injuries, which require new precise research.

REFERENCES

- Ackerman LV. Extra-Osseous Localized Non-Neoplastic Bone and Cartilage Formation (So-Called Myositis Ossificans): Clinical and Pathological Confusion with Malignant Neoplasms. *J Bone Joint Surg Am.* 1958; 40(2):279–98.
- Buselli P, Coco V, Notarnicola A, Messina S, Saggini R, Tafuri S, et al. Shock waves in the treatment of post-traumatic myositis ossificans. *Ultrasound Med Biol.* 2010; 36(3):397–409.
- Goldman AB. Myositis ossificans circumscripta: a benign lesion with a malignant differential diagnosis. *AJR.* 1976; 126(1):32–40.
- King JB. Post-traumatic ectopic calcification in the muscles of athletes: a review. *Br J Sports Med.* 1998; 32(4):287–90.
- Sodl JF, Bassora R, Huffman GR, Keenan MA. Traumatic myositis ossificans as a result of college fraternity hazing. *Clin Orthop Relat Res.* 2008; 466(1):225–30.
- Simon T, Guillodo Y, Madouas G, Saraux A. Myositis ossificans traumatica (circumscripta) and return to sport: A retrospective series of 19 cases. *Joint Bone Spine.* 2016; 83(4):416–20.
- Goyal K, Pettis CR, Bancroft AE, Wasyliw CW, Scherer KF. Myositis Ossificans in the Thigh of a Lacrosse Player. *Orthopedics.* 2015; 38(8):468, 51–5–8.
- Srikanth IM, Vishal A, Kiran KR. Myositis Ossificans of Rectus Femoris: A Rare Case Report. *J Orthop Case Rep.* 2015; 5(3):92–4.
- Bagnulo A, Gringmuth R. Treatment of Myositis Ossificans with acetic acid phonophoresis: a case series. *J Can Chiropr Assoc.* 2014; 58(4):353–60.
- Yochum AM, Reckelhoff K, Kaeser M, Kettner NW. Ultrasonography and Radiography to Identify Early Post Traumatic Myositis Ossificans in an 18-Year-Old Male: A Case Report. *J Chiropr Med.* 2014; 13(2):134–8.
- Torrance DA, deGraauw C. Treatment of post-traumatic myositis ossificans of the anterior thigh with extracorporeal shock wave therapy. *J Can Chiropr Assoc.* 2011; 55(4):240–6.
- Orava S, Sinikumpu JJ, Sarimo J, Lempainen L, Mann G, Hetsroni I. Surgical excision of symptomatic mature posttraumatic myositis ossificans: characteristics and outcomes in 32 athletes. *Knee Surg Sports Traumatol Arthrosc.* 2017; 25(12):3961–8.
- Drobnič M, Stražar K, Zupanc O. Endoscopic evacuation of an organized quadriceps haematoma. A case report with a technical note. *Zdrav Vestn.* 2010; 79:512–6.
- Carmichael SW, Burkart SL, Johnson RD. Myositis Ossificans: Report of an Unusual Case. *The J Orthop Sports Phys Therapy.* 1981; 2(4):184–6.
- Wieder DL. Treatment of traumatic myositis ossificans with acetic acid iontophoresis. *Phys Ther.* 1992; 72(2):133–7.

Масивни трауматски осификантни миозитис

Добривоје Мартинов^{1,2}, Татјана Стојковић-Јовановић¹, Ксенија Бошковић³

¹Општа болница „Ђорђе Јоановић“, Зрењанин, Србија;

²Универзитет у Новом Саду, Технички факултет „Михајло Пупин“, Зрењанин, Србија;

³Универзитет у Новом Саду, Медицински факултет, Клиника за медицинску рехабилитацију, Нови Сад, Србија

САЖЕТАК

Увод Трауматски осификантни миозитис (ТОМ) редак је али може угрозити спортску каријеру, посебно ако је великих димензија.

Циљ ове студије је да се представи резултат лечења ТОМ великих димензија применом физикалне терапије.

Приказ болесника ТОМ великих димензија је дијагностикован код 13-годишњег спортисте, два месеца после директног ударца у натколени мишић предње регије. Физикално лечење је трајало три месеца. Болесник се вратио уобичајеним дневним активностима и рекреативном спорту без

ограничења после осам месеци од повређивања. Снимања током петогодишњег праћења показала су да су се висина и ширина осификата смањиле, а да се дужина осификата дискретно повећала.

Закључак Примена физикалне терапије омогућила је пун функционални опоравак, упркос масивности осификата. Висина и ширина осификата су смањене, али је дужина повећана.

Кључне речи: повреда мишића; осификатни миозитис; физикална терапија