

CASE REPORT / ПРИКАЗ БОЛЕСНИКА

Ankyloblepharon filiforme adnatum with a bilateral cleft lip and palate

Gordana Stanković-Babić^{1,2}, Milena Vujanović¹, Sonja Cekić^{1,2}

¹University of Niš, Faculty of Medicine, Niš, Serbia;

²Niš Clinical Centre, Clinic for Eye Diseases, Niš, Serbia

SUMMARY

Introduction Ankyloblepharon filiforme adnatum (AFA) is a rare congenital abnormality of the eyelids that has been reported as an isolated anomaly, but may also be associated with other anomalies or as a part of well-defined syndromes.

The aim of this work was to present a case of familial AFA associated with bilateral cleft lip and palate.

Case outline A full-term female newborn (40 weeks' GA, BM 3,700 g) had bilateral partially fused eyelids at birth, associated with a cleft lip and palate. The surgical treatment was performed five days after AFA was diagnosed. The baby's mother also had AFA, without a cleft lip or palate. The baby girl has been followed-up by a plastic surgeon, a specialist in orthodontics, as well as an ophthalmologist and a pediatrician.

Conclusion This case indicates familial clustering of AFA, whereby it assumes a more severe form in the following generation. A cleft lip and palate in our patient has required surgical treatment, oral and dental rehabilitation, as well as the need for more intensive care and regular follow-ups by multidisciplinary teams.

Keywords: newborn; eyelids; congenital abnormality; cleft lip and palate



INTRODUCTION

Ankyloblepharon filiforme adnatum (AFA) is a rare congenital anomaly that is represented by a single or multiple strands of fine connective tissue joined to the upper and lower eyelids anywhere along the lid but never at the lateral or medial canthus. It was first described by Josef von Hasner in 1881 [1]. AFA occurs sporadically and has an incidence of 4.4 cases per 100,000 births [2, 3, 4]. Although this anomaly has been reported as an isolated anomaly, it may also be found in association with other anomalies or as a part of well-defined syndromes such as Edward's syndrome, Hay-Wells syndrome, etc. [1–26].

The ophthalmic conditions associated with AFA may be iridocorneal angle dysgenesis associated with infantile glaucoma, the absence of the lacrimal puncta, chronic conjunctivitis and blepharitis, limbus abnormalities, etc. [12, 25].

Considering the fact that AFA is potentially amblyogenic congenital abnormality of the eyelids, the treatment of AFA is conducted for neonatal comfort and in order to exclude the risk of impairment of the developing visual system [5].

We present a case of familial AFA associated with a bilateral cleft lip and palate.

CASE REPORT

A full term female newborn (40 weeks' GA, BM 3,700 g) was delivered vaginally as a result of the second normal pregnancy. The mother was 36

years old. The first child, a five-year-old male at the time, had been healthy. The mother denied taking any drugs during pregnancy except vitamin supplements. No history of any X-ray exposure was reported. The newborn had bilateral partial adhesion of the fibrous band at the ciliary edges of the upper and lower eyelids to each other at birth, associated with a bilateral cleft lip and palate. The mother claimed that she had "the same problem with the eyelids" without a cleft lip or palate. In her case, the surgery of eyelids was performed when she was ten days old.

The initial ophthalmological examination of the newborn showed the presence of bilateral thin tissue bands connecting upper and lower eyelids (Figures 1, 2, and 3). A single band of elastic tissue was vertically attached to the upper and lower eyelids. Covering the pupil, it prevented full opening of the eyelids. The dimension of this elastic tissue measured 1.5 mm in width in both eyes, while its length was 7.5 mm in the right eye and 6.5 mm in the left eye. The ultrasound scan revealed a normal B scan of the eyes and orbits. The axial length was 17 mm in both eyes. The results of the cytomorphological study of amniotic fluid showed a normal 46, XX, karyotype. Pediatric assessment detected no other congenital abnormalities such as syndactyly, a deep split in the hands or feet with missing fingers/toes, nor fusion of the remaining digits (ectrodactyly). The child's hearing was normal. Echocardiography and cerebral echography was performed to exclude congenital heart disease and cerebral malformations. Both results were normal.

Received • Примљено:
March 2, 2017

Revised • Ревизија:
November 13, 2017

Accepted • Прихваћено:
November 14, 2017

Online first: November 17, 2017

Correspondence to:
Gordana STANKOVIĆ-BABIĆ
Clinic for Eye Diseases
Niš Clinical Center
48 Dr. Zorana Đinđića Blvd.
Niš 18000, Serbia
gordanasb@mts.rs

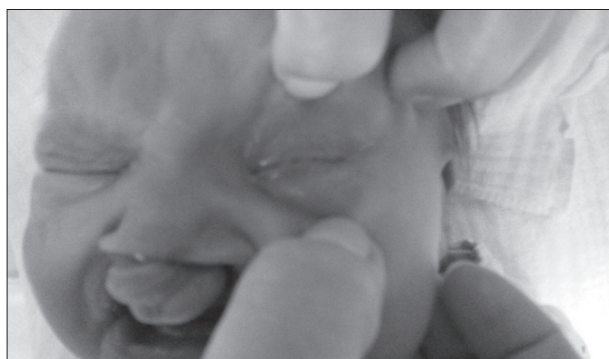


Figure 1. The newborn with ankyloblepharon filiforme adnatum (AFA) and cleft lip and palate

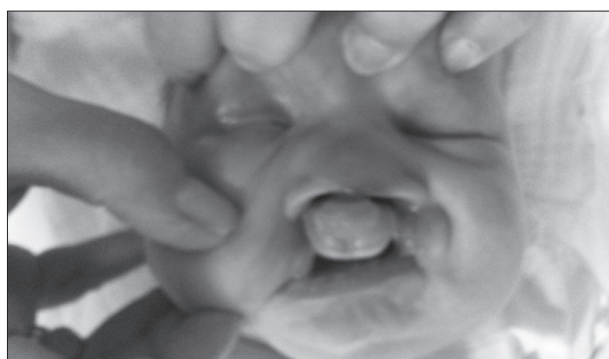

Figure 2. The newborn with AFA and cleft lip and palate

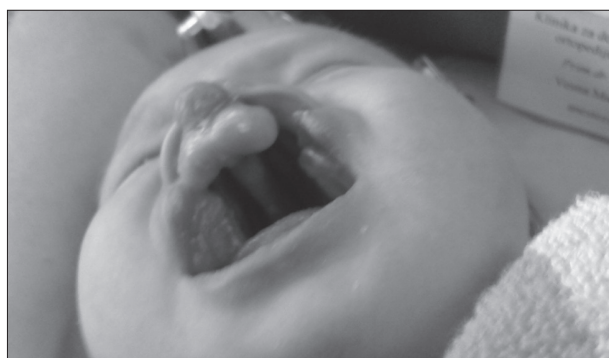

Figure 3. The newborn with AFA and cleft lip and palate

After the consultative examination by a specialist in orthodontics, an appropriate orthognathic prosthesis was made to enable smooth feeding of the newborn. Surgical treatment of the bilateral cleft lip and palate was performed later.

The operative treatment of AFA was done at the age of five days. It was performed under intravenous sedation at the Children's Surgical Clinic of the Niš Clinical Centre. The treatment of AFA included a simple surgical resection of the thin tissue bands between the eyelids bilaterally. This procedure was performed with minimal bleeding during the resection (Figure 4). The eyelids were easily parted, enabling the visualization of the anterior segment of the eyes. The results of the ophthalmic examination revealed that the anterior and the posterior segment were in the normal condition.

The ophthalmic follow-ups were carried out at the age of six, nine, and 16 months. Visual acuity assessment

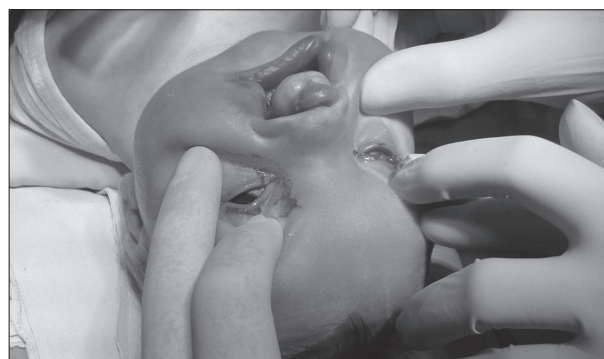

Figure 4. Separated eyelids after the surgical procedure

showed that the child could follow toy movements without any problems; the motility of the eyes and the cover test were normal. Epicanthus and hypertelorism were present. Refractometry at the age of nine months revealed low hypermetropia (SE +1.50 D). The anterior segment of the eyes was normal without a corneal limbus abnormality, without any anomalies of the lacrimal apparatus; eyelid margins were complete, without conjunctivitis; the cornea was transparent, with an adequate tear film covering the eyes; the anterior chamber, iris, and lens were normal, while both the intraocular pressure and the posterior segment findings were within normal limits. The girl had silky, light hair like her mother and had no nail anomalies (Figure 5). As for the baby's teething, according to the patient's mother, the first tooth that erupted was the left mandibular central incisor at the age of seven months; by the age of 1.5 years, the baby had both mandibular central and lateral incisors; the signals of the right maxillary lateral incisor eruption were also present.

The patient was treated surgically by cheiloplasty and the bilateral reconstruction of the nose using the Takai technique at seven months of age (the surgery was originally planned at five months of age but was postponed because of the illness of the child – infections of the upper respiratory tract). The next procedure that the patient was expected to undergo was palatoplasty. However, as the first of these procedures, cheiloplasty, was followed by complications such as wound dehiscence, the second corrective surgical procedure (the reconstruction of the left-sided cleft of the primary palate using the Tennison technique) had to be performed at the age of 14 months and palatoplasty had to be postponed. Palatoplasty (the bilateral reconstruction of the secondary palate using the Wardill–Kilner technique), which was initially planned to be carried out at the age of 12–18 months, was preformed later, at 20 months of age.

The patient has been followed up by a plastic surgeon, a specialist in orthodontics, an ophthalmologist and a pediatrician ever since.

DISCUSSION

During embryonic development, the lids are visible early in the second month of gestation. The primitive lid folds fuse in 9–10 weeks of gestation. The developing eyelid

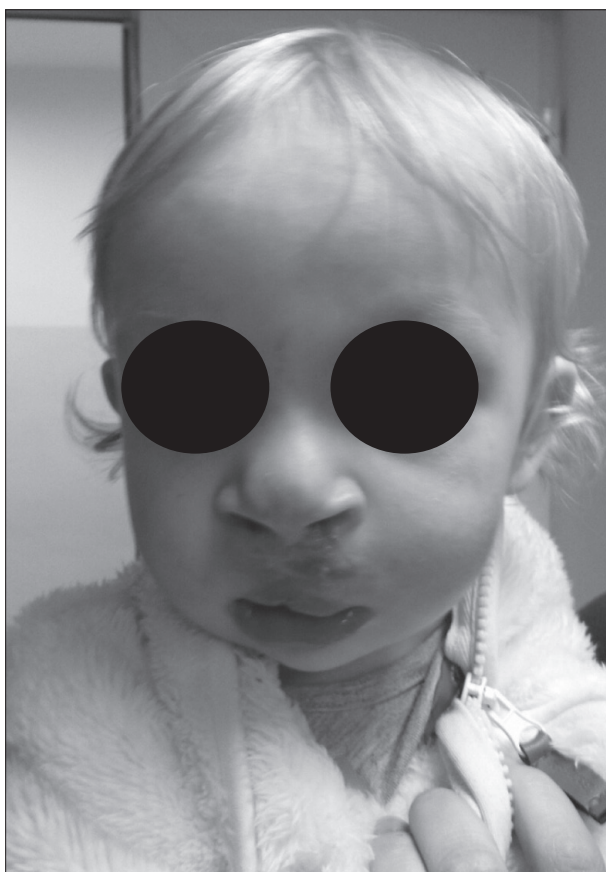

Figure 5. The patient at the age of 16 months

margins remain fused until the fifth gestational month and may not be completely separated until the seventh month, but they should be separated before birth [13]. The etiology of AFA is unknown. One of the factors that have been suggested is the failure of apoptosis at a critical stage in eyelid development [15]. AFA is a condition which arises due to the interplay of temporary epithelial arrest and rapid mesenchymal proliferation, allowing for the union of the lids at certain points [17].

We presented a case of familial AFA associated with a bilateral cleft lip and palate. The family history of ankyloblepharon filiforme adnatum in our patient suggests an autosomal dominant pattern of inheritance. The surgical correction of AFA should be performed under intravenous sedation, topical anesthesia, but sometimes anesthesia is not required [5, 21, 22]. During the surgery procedure, thin tissue bands were severed using a squint hook and scissors. For better removal of the elastic tissue from the eyelid margins, trimming at the insertion in front of the gray line is necessary [23]. A timely separation of the eyelids is crucial for avoiding the development of deprivation amblyopia.

This case report highlights that the presence of ankyloblepharon filiforme adnatum should alert the clinicians to the possibility of underlying congenital disorders. Eyelid malformations can be a sign of multisystemic diseases [16]. AFA may be associated with a popliteal pterygium syndrome (PPS, characterized by intercrural webbing of the lower limbs) [7], CHANDS (curly hair – ankyloblepha-

ron – nail dysplasia syndrome) [8], hydrocephalus, meningomyelocele, imperforate anus [11], cardiac problems such as ductus arteriosus and ventricular septal defects [7], a cleft lip and/or palate [9, 19], or with skin hypopigmentation in the absence of cleft lip/palate [10]. AFA can be seen in trisomy 18 (Edwards syndrome) [1, 2, 5, 14, 17], as a part of Hay–Wells syndrome [4, 6, 18, 24, 25, 26], or in both syndromes together [17].

Ankyloblepharon – ectodermal defects – cleft lip/palate (AEC) syndrome is a form of ectodermal dysplasia, associated with cleft lip and/or palate and congenital filiform fusion of the eyelids. It was first described by Hay and Wells in 1976. It is the result of an autosomal dominant inheritance caused by heterozygous missense mutations in the SAM domain of the *p63* gene [18, 24, 25].

The ectodermal dysplasias comprise a large, heterogeneous group of inherited disorders defined by primary defects in the development of two or more tissues derived from the embryonic ectoderm. The tissues primarily involved are the skin, hair, nails, eccrine glands, and teeth. More than 192 conditions under the umbrella term of “ectodermal dysplasias” have been described, including the following: **the skin** – erosions usually affect the scalp and can be limited or widespread covering the whole body, hypohidrosis, pigmentation changes, palmar and plantar changes, congenital erythroderma, areas of depigmentation and scarring; **the hair** – coarse, brittle, light colored, more evident with age, sparse or absent scalp hair, eyebrows and eyelashes; **the nails** – the patients have several degrees of nail anomalies, e.g. partial or total absence of nail plates, thickening of nail plates, loss of cuticles, pseudopterygium formation, and subungual hyperkeratosis; **cleft lip and/or cleft palate** are present in all cases; **other features** include craniofacial findings – an oval face, broad nasal bridge, maxillary hypoplasia, small mandible, hypoplastic alar nasi, distinctive facial features such as small jaws that cannot open fully and a narrow space between the upper lip and nose (philtrum); **dental findings** – conical, widely spaced teeth, varying degrees of hypodontia [25]. Other disorders include conductive hearing losses, syndactyly, ectrodactyly, and hypospadias in males [1, 17, 24, 25, 26]. **Ocular symptoms and signs** that can be identified are associated with numerous ectodermal dysplasias, but at present, they do not belong to the inclusion criteria of the disease group. The sparseness of eyebrows and lashes was detected in 94% of patients; the alteration of the Meibomian glands (proved to be a reliable sign in ectodermal dysplasia syndromes) and dry eye symptoms were seen in 94% of patients; finally, corneal changes, with a loss of visual acuity, occurred later in life, occasionally leading to amaurosis [25].

A cleft palate and/or lip are among the most common congenital anomalies, which account for 65% of all head and neck anomalies. The etiology of these anomalies is multifactorial (genetic and environmental reasons like medications, intake of anticonvulsants, radiation, smoking, and alcohol consumption) [19]. More than 300 syndromes are associated with a cleft lip and palate. AFA with a cleft palate and/or cleft lip has been observed in families

as well. A 'familial' tendency was invoked by Howe and Harcourt (1974), who described this condition in identical twins, and by Khanna (1957), who reported the condition in sisters, one of whom had a cleft lip and palate. Gorlin et al. (1971) stated that "the association of cleft lip or cleft palate or both and congenital filiforme fusion of the eyelids appears to be inherited as an autosomal dominant trait" [5].

Rosenman et al. [20] divided AFA into four subgroups: AFA without associated abnormalities (I), AFA with cardiac and central nervous system abnormalities (II), AFA and ectodermal syndrome (III), and AFA with a cleft lip and/or palate (IV). The same authors indicated that subgroups I and II were sporadic, while groups III and IV were autosomal dominant with variable expressivity. In 1993, Bacal et al. suggested the introduction of group V, where AFA is associated with chromosomal abnormalities [20], while in 2007, Williams et al. [5] proposed the introduction of

group VI, which included cases with a family history of AFA without systemic anomalies.

Accurate examination of the eyelids represents a fundamental part of the neonatal physical evaluation of the newborn, particularly if other congenital abnormalities have been detected, and the aim of such an examination is to avoid future functional problems. This case report is trying to emphasize the importance of early detection of AFA, as well as proper and timely treatment of this condition. Without an adequate treatment, this anomaly could result in various degrees of visual impairment. In addition, this case indicates familial clustering of AFA, whereby it assumes a more severe form in the following generation, encompassing the cleft palate and the upper lip. A cleft lip and palate in our patient has required surgical treatment, oral and dental rehabilitation, as well as the need for more intensive care and regular follow-ups by multidisciplinary teams.

REFERENCES

- Clark DI, Patterson A. Ankyloblepharon filiforme adnatum in trisomy 18 (Edwards's syndrome). *Br J Ophthalmol.* 1985; 69(6):471–3.
- Jain S, Atkinson AJ, Hopkisson B. Ankyloblepharon filiforme adnatum. *Br J Ophthalmol.* 1997; 81:708.
- Cizmeci MN, Kanburoroglu MK, Akelma AZ, Talti MM. A stitched eye in the newborn: ankyloblepharon filiforme adnatum. *J Pediatr.* 2013; 162(1):211–2.
- Gruener AM, Mehat MS. A newborn with ankyloblepharon filiforme adnatum: a case report. *Cases J.* 2009; 2:8146.
- Williams MA, White ST, McGinnity G. Ankyloblepharon filiforme adnatum. *Arch Dis Child.* 2007; 92(1):73–4.
- Vanderhooft SL, Stephan MJ, Sybert VP. Severe skin erosions and scalp infections in AEC syndrome. *Pediatr Dermatol.* 1993; 10(4):334–40.
- Akkermans CH, Stern LM. Ankyloblepharon filiforme adnatum. *Br J Ophthalmol.* 1979; 63:129–31.
- Toriello HV, Lindstrom JA, Waterman DF, Baughman FA. Re-evaluation of CHANDS. *J Med Genet.* 1979; 16:316–7.
- Long JC, Blandford SE. Ankyloblepharon filiforme adnatum with cleft lip and palate. *Am J Ophthalmol.* 1962; 53:126–9.
- Kuruville SE, Simha AR. A rare variant of ankyloblepharon filiforme adnatum associated with skin hypopigmentation: A case report from South India. *Indian J Ophthalmol.* 2016; 64(3):241–3.
- Kazarian EL, Goldstein P. Ankyloblepharon filiforme adnatum with hydrocephalus, meningomyelocele, and imperforate anus. *Am J Ophthalmol.* 1977; 84(3):355–7.
- Scott MH, Richard JM, Farris BK. Ankyloblepharon filiforme adnatum associated with infantile glaucoma and iridogoniodysgenesis. *J Paediatr Ophthalmol Strabismus.* 1994; 31(2):93–5.
- Forrester JV, Dick AD, McMenamin PG, Roberts F. *The eye. Basic science in practice.* 3rd ed. Philadelphia: Elsevier-Saunders Ltd; 2008. p. 139.
- Alami B, Maadane A, Sekhsoukh R. Ankyloblepharon filiforme adnatum: a case report. *Pan Afr Med J.* 2013; 15:15.
- Mohamed YH, Gong H, Ameniya T. Role of apoptosis in eyelid development. *Exp Eye Res.* 2003; 76(1):115–23.
- Bordin G, Valerio E, Cutrone M. Ankyloblepharon filiforme adnatum in a newborn. *AJP Rep.* 2015; 05(01):e12–3.
- Tüyzüs B, Ilikkan B, Vural M, Perk Y. Ankyloblepharon filiforme adnatum (AFA) associated with trisomy 18. *Turk J Pediatr.* 2002; 44(4):360–2.
- Ferone G, Rosaria Mollo M, Thomason HA, Antonini D, Zhou H, Ambrosio R, et al. p63 control of desmosome gene expression and adhesion is compromised in AEC syndrome. *Hum Mol Genet.* 2013; 22(3):531–43.
- Shah NS, Khalid M, Sartaj Khan M. A review of classifications systems for cleft lip and palate patients – I. Morphological classifications. *JKCD.* 2011; 2(1):95–9.
- Rosenman Y, Ronen S, Eidelman AI, Schimmel MS. Ankyloblepharon filiforme adnatum: congenital eyelid-band syndromes. *Am J Dis Child.* 1980; 134(8):751–3.
- Özyazgan İ, Eskitaşcioğlu T, Dündar M, Karac S. Hereditary isolated ankyloblepharon filiforme adnatum. *Plast Reconstr Surg.* 2005; 115(1):363–4.
- Ioannides A, Georgarakos ND. Management of ankyloblepharon filiforme adnatum. *Eye.* 2011; 25(6):823.
- Rubinov A, Seider N, Mezer E, Berkovitz L, Blumenthal EZ, Makhoul IR. Ankyloblepharon filiforme adnatum. *IMAJ.* 2015; 17:66.
- Jenwitheesuk K, Surakunprapha P, Chowchuen B, Jetsrisuparb C. Ankyloblepharon–ectodermal defects–cleft lip/palate (AEC) syndrome in monozygotic twins: two cases report and reviews. *J Med AssocThai.* 2010; 93(Suppl.4):S78–82.
- Salinas CF, Jorgenson RJ, Wright JT, DiGiovanna JJ, Fete MD. 2008 International Conference on Ectodermal Dysplasias Classification Conference Report. *Am J Med Genet A.* 2009; 149A(9):1958–69.
- Deshpande SN, Kumar V. Ectodermal dysplasia – maxillary and mandibular alveolar reconstruction with dental rehabilitation: a case report and review of the literature. *Indian J Plast Surg.* 2010; 43(1):92–6.

Ankyloblepharon filiforme adnatum са обостраним расцепом усне и непца

Гордана Станковић-Бабић^{1,2}, Милена Вујановић¹, Соња Цекић^{1,2}

¹Универзитет у Нишу, Медицински факултет, Ниш, Србија;

²Клинички центар Ниш, Клиника за очне болести, Ниш, Србија

САЖЕТАК

Увод *Ankyloblepharon filiforme adnatum* (AFA) ретка је конгенитална абнормалност капака, саопштavana као изолован налаз, удружена са другим аномалијама или као део добро дефинисаних синдрома.

Циљ овог рада је био да прикаже болесника са фамилијарним AFA, удруженог са обостраним расцепом усне и непца.

Приказ болесника Терминско новорођенче (40 недеља ГС, ТМ 3700 g) женског пола рођено је са обостраном делимичном фузијом капака и обостраним расцепом усне и непца. Оперативно лечење је изведено пет дана после рођења.

Мајка бебе је такође имала AFA, без расцепа усне и непца. Девојчица се прати од стране специјалисте пластичне хирургије, ортодонције, офталмолога и педијатра.

Закључак Овај случај указује на фамилијално груписање AFA, са озбиљнијом формом у следећој генерацији. Расцеп усне и непца код нашег болесника захтевао је хируршко лечење, оралну и зубну рехабилитацију, потребу за интензивном негом и редовним праћењем мултидисциплинарних тимова.

Кључне речи: новорођенче; капци; конгениталне аномалије; расцеп усце и непца