

CASE REPORT / ПРИКАЗ БОЛЕСНИКА

Two-stage surgical repair of type II acute aortic dissection and aortic coarctation in a 12-year-old child

Vladimir Milovanović¹, Irena Vulićević¹, Tatjana Zečević¹, Milan Đukić², Slobodan Ilić², Branko Mimić³

¹University Children's Hospital, Department of Pediatric Cardiac Surgery, Belgrade, Serbia;

²University of Belgrade, School of Medicine, Belgrade, Serbia;

³University Hospitals of Leicester NHS Trust, Department of Pediatric Cardiac Surgery, Leicester, UK

SUMMARY

Introduction Combination of acute aortic dissection associated with aortic coarctation in pediatric population is extremely rare. We are presenting a 12-year-old patient with these two conditions who was successfully treated with two-stage surgery.

Case Outline A boy with no trauma history was admitted for chest pain. The diagnosis of acute aortic dissection associated with aortic coarctation was established with echocardiography and computed tomography angiography. Emergent surgery was performed – excision of the ascending aorta aneurysm with supracoronary graft replacement and preservation of native aortic valve. Subsequently, through posterolateral left thoracotomy, the patient underwent end-to-end aortoplasty for coarctation repair.

Conclusion Two-stage surgery provides favorable outcome in this rare, life threatening condition in the pediatric age group. Native aortic valve was preserved and extra-anatomic bypass of aortic coarctation was avoided. Further monitoring of aortic valve is mandatory.

Keywords: ascending aorta aneurysm; pediatric; coarctation

INTRODUCTION

Rupture of dissecting aneurysm is an exceptionally rare, life-threatening condition in children and young adolescents [1]. Furthermore, the combination of acute aortic dissection associated with aortic coarctation in this age group is sparsely reported. Infrequent pediatric reports are mostly related to patients with Turner syndrome and other connective tissue disorders [1]. Co-existing aortic dissection and coarctation have been addressed in various ways. There are several previous reports of two-stage repair, as well as one-stage repair mainly using extra-anatomic ascending-to-descending aortic bypass. Hereby we present, to our knowledge, the youngest patient with this condition treated with staged procedures.

thoracic echocardiography demonstrated hypertrophied left ventricle, trivial incompetence (+0.5/4) of bivelar aortic valve with annulus of 2.2 cm, and significant pericardial effusion. Mitral valve was dysplastic but competent. A posterior intimal flap was detected above the aortic valve with an aneurysmal dilatation of the ascending aorta (6 cm). Furthermore, the coarctation of the aortic isthmus was demonstrated with a gradient of 50 mmHg. A computed tomography scan showed identical findings with the intimal flap extending below the origin of the innominate artery (Figure 1).

With a diagnosis of type II aortic dissection and associated aortic coarctation, emergent surgery was performed through a median sternotomy. During routine anesthetic preparation, arterial pressure lines were placed in the right radial and left femoral artery. Upon pericardium

CASE REPORT

A 12-year-old boy with no previous medical history was admitted for distressing parasternal chest pain, accompanied with shortness of breath and dizziness. There was no trauma history. On clinical examination, radial pulses were present, whereas femoral pulses were barely palpable. A systolic murmur 2–3/6 was noted in the precordium. Electrocardiography indicated sinus rhythm with transitory ST elevation during the episodes of chest pain. Trans-

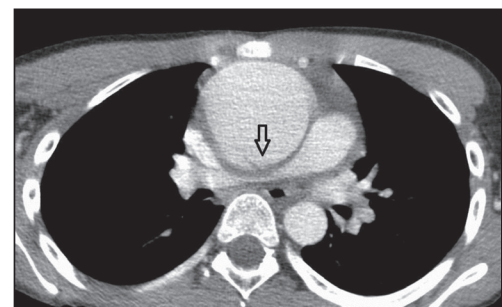


Figure 1. Computed tomography angiography: posterior intimal flap in aneurysmatic ascending aorta



Примљено • Received:
March 9, 2016

Ревизија • Revised:
January 10, 2017

Прихваћено • Accepted:
January 13, 2017

Online first: March 3, 2017

Correspondence to:

Vladimir MILOVANOVIĆ
Department of Pediatric Cardiac
Surgery
University Children's Hospital
Tiršova 10
11000 Belgrade, Serbia
vmilovanovic1972@yahoo.com

opening and draining of 600 ml of blood, grossly dilated, dissected aorta appeared. The aortic annulus was not dilated. The aneurysmatic change was above the sinotubular junction and stretched to 1.5 cm below the origin of innominate artery. Single arterial cannulation was performed high in the aortic arch, just below the innominate artery, the right atrium was cannulated with a two-stage venous cannula. Cardiopulmonary bypass was established with systemic cooling to 28°C. Pressure in the femoral artery was sufficient throughout the procedure (over 50 mmHg). The ascending aorta was highly cross-clamped, opened, and cardioplegia was infused in the coronary ostia.

The entry point of dissection was identified at the posterior aortic wall 2 cm above the right coronary ostium (Figure 2). The aortic valve was bicuspid, though it appeared as competent and anatomically normal. After excising the aneurysm, aortic valve was preserved and resuspended with a double layer of Teflon felt inside and outside the free margin of the proximal aorta. A 24 mm Dacron graft was anastomosed here, whereupon saline injection into the neo-aortic root demonstrated good aortic valve competence. The distal ascending aortic anastomosis was performed in the same manner with normal aortic wall just below the cross clamp. At the end of the procedure, after rewarming to 37°C, the patient was easily weaned off cardiopulmonary bypass.

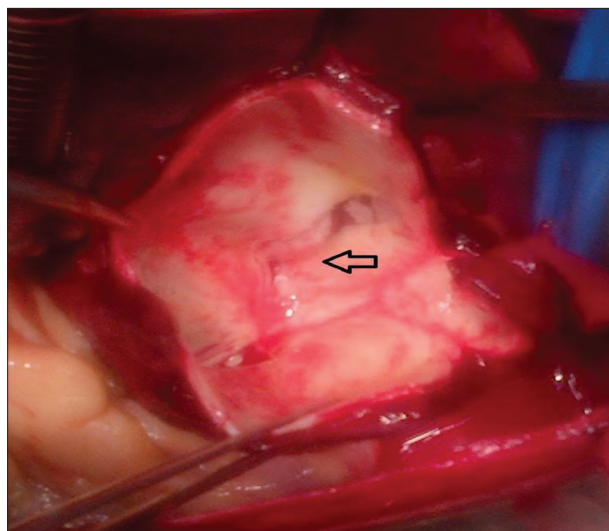


Figure 2. The entry point of dissection at the posterior aortic wall, 2 cm above the right coronary ostium

Postoperatively, he was extubated the following morning. Postoperative echocardiography demonstrated hypertrophied left ventricle with aortic valve insufficiency of +2.5/4, and mitral valve insufficiency of +1.5/4.

After achieving full recovery during the same hospitalization, the patient was operated on for aortic coarctation. Aortoplasty with coarctation resection and standard “end-to-end” anastomosis was performed through left posterolateral thoracotomy at the fourth intercostal space. Multiple collateral vessels of the descending aorta were observed.

Postoperatively, the patient was extubated five hours after the surgery. Intensive care unit stay was two days. The

main postoperative complication was hypertension. He was discharged on enalapril and metoprolol, ten days after the second operation. Echocardiography demonstrated reduction of both mitral (+1/4) and aortic valve regurgitation (+2/4), good left ventricle function, and no residual gradient at the place of aortoplasty.

At 24-month-follow-up, the patient is asymptomatic, normotensive, still on metoprolol. Repeated echocardiography showed no further progression of aortic and mitral regurgitation, and no signs of left ventricle function deterioration.

DISCUSSION

The association between coarctation and aortic dissection has been described in early studies of the natural history of the aortic coarctation [2]. However, reports of this condition in pediatric population are extremely rare [3]. The usual onset of dissection is the adolescent period rather than childhood, and, to our knowledge, this is the youngest patient presented with this life-threatening condition. The most common predisposing factors in children are connective tissue disorders as Marfan's, Turner's, and type IV Ehlers–Danlos syndrome. These disorders usually have clear physical stigmata. None of those stigmata were present in the described case, our patient had been practicing water polo actively. Nevertheless, Hatzaras et al. [4] reported that grueling physical activity with severe emotional stress are clear precipitating factors of acute dissection. Furthermore, swimming has been reported to precipitate acute aortic dissection in the absence of any predisposing factors [5]. We can speculate that the mentioned factors, alongside with idiopathic dilatation and hypertension due to coarctation, were the main etiological factors for dissection.

The repair of aortic dissection in the presence of coarctation comprises a few difficulties: decision on the optimal timing and sequence of the surgical repair, optimal surgical exposure, and perfusion techniques. Several surgical options have been reported. Sampath et al. [6] first described staged approach with initial aortoplasty followed by dissection repair. On the other hand, there is an opinion that dissection repair as a lifesaving procedure takes precedence over coarctation repair. The first single-stage repair was described by Svensson [7] in 1994.

In the reported case we performed a two-stage strategy with initial repair of dissection. Clearly, primary coarctation repair was not an option because the patient required immediate repair of the acute dissection and relief of the cardiac tamponade. Furthermore, giving the extreme rarity of this condition, relatively low gradient over the coarctation, and unknown dissection duration time, we decided to proceed with the two-stage strategy as a safer alternative. We were able to maintain adequate blood flow on cardiopulmonary bypass through a single arterial cannula thanks to well-developed collateral vessels and relatively low gradient across coarctation. In the presence of non-dilated aortic annulus, normal aortic sinuses, and functional bicuspid valve, we decided not to replace the valve.

Initial level of aortic and mitral regurgitation before coarctation repair raised numerous doubts about that decision. Fortunately, insufficiency of both mitral and aortic valve were reduced after the aortoplasty, and in the follow-up there has been no deterioration in the left ventricle function. We are aware that valve replacement will most likely prove necessary. In the meantime, the patient will hopefully complete growth and will be spared from problems related to anticoagulation therapy. One can speculate that valve-sparing aortic root implantation with a vascular graft would be a better solution, but this particular operation on bicuspid valve remains challenging [8]. The mechanical valve inserted into a composite graft is known for long-term durability, but young patients are exposed to a long-term risk of thromboembolism and oral anticoagulation. One clear advantage of two-stage repair is “end-to-end” aortoplasty, which is a far better solution for coarctation

than extra-anatomical bypass grafting from the ascending to descending aorta as a standard technique in a single-stage procedures. One other option would be stenting of coarctation – nevertheless, regarding the patient’s age, we chose to give priority to surgery.

In summary, we successfully performed a two-stage repair with the preservation of the aortic valve, replacement of the ascending aorta with Dacron graft and “end-to-end” aortoplasty for acute type II aortic dissection with coarctation. Further monitoring is mandatory for assessing the fate of the native aortic valve.

ACKNOWLEDGEMENT

The authors wish to thank Prof. Mile Vraneš, MD, for his major role in the surgical treatment of the presented case.

REFERENCES

1. Fikar CR, Fikar R. Aortic dissection in childhood and adolescence: an analysis of occurrence over a 10-year interval in New York State. *Clin Cardiol.* 2009; 32(6):E23–E26.
2. Abbott ME. Coarctation of the aorta of the adult type (II. A statistical study and historical retrospect of 200 recorded cases with autopsy, of stenosis or obliteration of the descending arch in subjects above the age of two years). *Am Heart J.* 1928; 3:574–618.
3. Paparella D, Schena S, Schinosa LLT, Vitale N. One step surgical repair of type 2 acute aortic dissection and aortic coarctation. *Eur J Cardiothorac Surg.* 1999; 16:584–6.
4. Hatzaras IS, Bible JE, Koullias GJ, Tranquilli M, Singh M, Elefteriades JA. Role of exertion or emotion as inciting events for acute aortic dissection. *Am J Cardiol.* 2007; 100(9):1470–2.
5. Edwin F, Aniteye EA, Sereboe L, Frimpong-Boateng K. Acute aortic dissection in the young: distinguishing precipitating from predisposing factors. *Interact Cardiovasc Thorac Surg.* 2009; 9:368.
6. Sampath R, O'Connor WN, Noonan JA, Todd EP. Management of ascending aortic aneurysm complicating coarctation of the aorta. *Ann Thorac Surg.* 1982; 34(2):125–31.
7. Svensson LG. Management of acute aortic dissection associated with coarctation by a single operation. *Ann Thorac Surg.* 1994; 58(1):241–3.
8. Kallenbach K, Karck M, Pak D, Salcher R, Khaladj N, Leyh R, et al. Decade of aortic valve sparing reimplantation: are we pushing limits too far? *Circulation.* 2005; 112:1253–9.

Хируршко збрињавање у два акта 12-годишњег детета са дисекцијом анеуризме асцендентне аорте удружене са коарктацијом аорте

Владимир Миловановић¹, Ирена Вулићевић¹, Татјана Зечевић¹, Милан Ђукић², Слободан Илић², Бранко Мимић³

¹Универзитетска дечја клиника, Одељење педијатријске кардиохирургије, Београд Србија;

²Универзитет у Београду, Медицински Факултет, Београд, Србија;

³Универзитетска болница Лестера, Одељење педијатријске кардиохирургије, Лестер, Уједињено Краљевство

САЖЕТАК

Увод Комбинација акутне аортне дисекције удружене са коарктацијом аорте је веома ретка у педијатријској популацији.

Приказ болесника Дечак стар 12 година, без анамнестичких података о трауми, примљен је због болова у грудном кошу. Дијагноза акутне дисекције анеуризме асцендентне аорте и аортне коарктације је постављена ехокардиографски и потврђена компјутеризованом томографијом. Учињен је хитан хируршки захват у виду ресекције анеуризме и супракоронарне уградње невалвулираног кондуита уз пре-

зервацију нативне аортне валвуле. Након тога учињена је аортопластика из постеролатералне торакотомије ради збрињавања аортне коарктације.

Закључак Етапно двостепено лечење овог ретког животно угрожавајућег стања обезбеђује добар исход. Сачувана је нативна аортна валвула и избегнуто екстраанатомско премешћавање аортне коарктације. Неопходно је даље праћење функције аортне валвуле.

Кључне речи: анеуризма асцендентне аорте; деца; коарктација аорте