

ORIGINAL ARTICLE / ОРИГИНАЛНИ РАД

Prevalence, characteristics and severity of hypomineralization of the first permanent molars and incisors in children from the northern part of Kosovo and Metohija

Brankica Martinović¹, Mirjana Ivanović², Andrijana Cvetković¹, Jelena Todić¹, Zoraida Milojković¹, Jasna Pavlović¹, Saša Z. Tabaković¹, Ivana Stošović-Kalezić¹

¹University of Priština, Faculty of Medicine, Department of Dentistry, Kosovska Mitrovica, Serbia;

²University of Belgrade, Faculty of Dental Medicine, Department of Preventive Dentistry and Pedodontics, Belgrade, Serbia



SUMMARY

Introduction/Objective Molar-incisor hypomineralization (MIH) is relatively common developmental anomaly characterized by hypomineralized enamel defects in the first permanent molars and incisors. The aim of this study was to determine the prevalence of hypomineralization of the first permanent molars and incisors in children aged eight and 10 years who live in the northern part of Kosovo and Metohija.

Methods The study included 712 respondents, 289 of whom aged eight (40.6%) and 423 of whom aged 10 years (59.4%). Criteria according to Weerheijm were used for diagnosis of hypomineralization and the severity of changes was determined.

Results The frequency of hypomineralized changes in the first permanent molars and incisors of the examined children in this area was 12.2%. It was lower in children aged eight years (10.7%) compared to those aged 10 (13.2%). Demarcated enamel opacity was more common in younger children, whereas both atypical restoration and tooth extraction due to hypomineralization were more common in older children. Mild form is more common in children aged eight years, whereas both severe form and severe form with extracted teeth are more common in children aged 10 years. The results indicate that the first permanent molars were most commonly affected by MIH changes.

Conclusion The percentage of the respondents with MIH changes in the northern part of Kosovo and Metohija, which is 12.2%, is not negligible and points to the necessity of early diagnosis in order to prevent and reduce the complications of the condition by timely prevention and treatment.

Keywords: hypomineralization; molars; incisors; children; prevalence

INTRODUCTION

In addition to dental caries and periodontal disease, developmental tooth disorders have been a problem in dentistry for more than two centuries. In economically developed countries, the problem of dental caries has been solved using targeted prevention programs, and significant results are being achieved in prevention of periodontal disease as well. Thus it has been proved that dental diseases can be prevented and controlled [1].

However, in the last ten years, especially in these countries, with a decrease in incidence of dental caries in children and adolescents, irregularities in the structure of hard dental tissues, which occur as a consequence of disorders at the time of their formation, apposition, mineralization, and maturation, have become more and more common. Special attention has been paid to isolated hypomineralized enamel defects of the first permanent molars and incisors.

During the 1970s, Swedish dentists were the first to point to the changes in the form of hypomineralization of the first permanent molars [2]. In 2001 a Dutch dentist Karin Weerheijm

[3] suggested the term of molar-incisor hypomineralization (MIH), hypomineralization of molars and incisors, to describe the clinical findings of hypomineralization of systemic origin of one or more of the first four permanent molars, which may be associated with changes in the maxillary, and less frequently in the permanent mandibular incisors.

Although the definition suggests that the influence of systemic factors is important, no specific systemic cause has been determined. It is the multifactorial etiology that is important, and inadequately explored genetic background in the etiology of MIH as well [4, 5].

Factors mentioned in the literature as possible etiological factors that might cause hypomineralization of molars and incisors are premature birth, low birth weight, twins, ear, nose, and throat infections, respiratory problems, epileptic seizures, hypoxia, disorder of calcium and phosphate metabolism, urinary tract infections, infant exposure to dioxins and biphenyls, childhood illnesses, and chronic diseases. Recent studies have shown that frequent antibiotic use and vitamin D deficiency may affect tooth hypomineralization [6–9].

Received • Примљено:

June 14, 2016

Revised • Ревизија:

December 6, 2016

Accepted • Прихваћено:

December 7, 2016

Online first: March 3, 2017

Correspondence to:

Brankica MARTINOVIĆ
Živka Davidovića 114/16
11000 Beograd
Serbia

brankicamartinovic@gmail.com

Hypomineralization of the first permanent molars and incisors, defined as reduced enamel mineralization, is a clinical condition in which enamel defects range from demarcated opacities to cracked, severely hypomineralized enamel. Defective opaque (porous) enamel is of normal thickness, with a smooth surface and can be whitish, white-yellow or yellow-brown and the defect typically has a clear line between affected and healthy enamel [10]. Teeth affected by MIH are susceptible to thermal, mechanical and chemical stimuli. Therefore, oral hygiene is difficult, and these teeth are more prone to cavities, which disturbs the oral health of children, and represents a significant problem in pediatric dentistry [11].

The frequency of this phenomenon varies significantly. Studies in different countries show different results, ranging 2.5–40.2% [12–16].

There are no precise data on the frequency of hypomineralization of the first permanent molars and incisors in the territory of Kosovo and Metohija.

Therefore, the aim of this study was to determine the distribution of hypomineralization of the first permanent molars and incisors in children who live in the northern part of Kosovo and Metohija as well as to assess the characteristics and determine the severity of hypomineralization.

METHODS

The study was approved by the Ethics Committee of the Faculty of Medicine in Kosovska Mitrovica (No. 09-2440 / November 26, 2015), and it was conducted by the researcher who had been previously trained and calibrated for assessing hypomineralization of the first permanent molars and incisors and other developmental enamel defects. Examiner reliability for the accurate diagnosis of MIH was tested on 10% of respondents of the total sample. A high inter-rater diagnostic accuracy of MIH ($\kappa = 0.97$) was received.

Children examinations were carried out at the Department of Pediatric and Preventive Dentistry of the Faculty of Medicine in Kosovska Mitrovica and in school dental offices. Dental mirrors, probes, and common lighting were used to examine children. The probes were used only when necessary, for removing dental plaque.

We examined only children who had written parental consent to participate in the study, and who had previously been fully informed, orally and in writing, about the aims of the study.

A total of 712 schoolchildren, 289 (40.6%) of whom aged eight and 423 (59.4%) aged 10, were examined in the following elementary schools: “Sveti Sava” and “Branko

Radičević” in Kosovska Mitrovica (393 schoolchildren examined), “Vuk Karadžić” in Zvečan (134 schoolchildren examined), and “Leposavić” (185 schoolchildren examined).

Criteria used in this study and commonly used in the literature are those proposed by Weerheijm et al. [17]. These are the following: demarcated opacity (DO); post-eruptive enamel breakdown (PEB); atypical restoration (AR); extracted molar due to MIH (E-MIH); un-erupted teeth (UT).

For patients with DO, PEB, and AR, we determined the severity of changes. There are three degrees of severity: mild, moderate, and severe form. Mild form of the tooth mineralization disorder is characterized by stained changes in the tooth enamel. Moderate form is characterized by changes in color (white/opaque, yellow or brown) and minimal loss of tooth substance with no need for restoration, or minimally invasive treatment is sufficient to repair defects. Loss of damaged enamel and dentin which require restoration represent severe form.

In cases when there were more defects on one tooth, the most severe change was recorded as valid. Teeth with more than one half of the crown erupted were included in the study while lesions less than 1 mm were not.

Of statistical tests, Student's t-test and χ^2 test were used, and the significance test was performed at the level of probability $p < 0.01$ and $p < 0.001$.

RESULTS

Based on the set aims and with appropriate methodology used in the study, the following results were collected.

Table 1 shows a comparative analysis of respondents by sex and age in relation to the occurrence of hypomineralized changes. The frequency of MIH in the examined children in this area was 12.2%. It was found that the percentage of female respondents with MIH was higher than that of males, but with no statistically significant difference ($\chi^2 = 0.69$, $p = 0.4058$). Analysis of MIH prevalence in relation to age has lower values in children aged eight years (10.7%) compared to that in respondents aged 10 (13.2%). The analysis of data shows there is no statistically significant difference ($\chi^2 = 1.01$, $p = 0.314$).

When analyzing individual criteria for MIH, neither the difference in the frequency of hypomineralized changes in the form of demarcated enamel opacities ($\chi^2 = 1.72$, $p = 0.190$) nor in the form of post-eruptive enamel breakdown ($\chi^2 = 1.16$, $p = 0.686$) due to MIH, is statistically significant in relation to age groups of children. An atypical restoration is statistically more common in children aged 10 years

Table 1. Distribution of children by sex and age in relation to the occurrence of molar and incisor hypomineralization (MIH)

MIH	Boys		Girls		8 years		10 years		Total sample	
	n	%	n	%	n	%	n	%	n	%
Presence of MIH	38	11.5	49	12.7	31	10.7	56	13.2	87	12.2
No MIH	291	88.5	334	87.3	258	89.3	367	86.8	625	87.8
Total	329	100	383	100	289	100	423	100	712	100

Table 2. Prevalence of molar and incisor hypomineralization (MIH) per individual criterion

MIH criteria	Children %			Molars %			Incisors %			Teeth with MIH %		
	Years			Years			Years			Years		
	8	10	8 + 10	8	10	8 + 10	8	10	8 + 10	8	10	8 + 10
Demarcated opacity	10.7	12.5	11.8	58.1**	18.9	32.9	100	91.2	94.6	65.4**	29.9	42.7
Post-eruptive enamel breakdown	4.5	6.1	5.5	27.6	30	29.2	0	8.8	5.4	22.8	26.7	25.3
Atypical restoration	1.7	6.4*	4.5	11.4	34.7**	26.4	0	0	0	9.4	29.5**	22.2
Extracted molar due to MIH	0.7	4.5*	2.9	2.9	16.3**	11.5	0	0	0	2.4	13.8**	9.6
Unerrupted teeth	0	0	0	0	0	0	0	0	0	0	0	0

*p < 0.01

**p < 0.001)

Table 3. Frequency of severity degrees of molar and incisor hypomineralization (MIH) changes

MIH expression level	Children %			Molars %			Incisors %			Teeth with MIH %		
	Years			Years			Years			Years		
	8	10	8 + 10	8	10	8 + 10	8	10	8 + 10	8	10	8 + 10
Mild form	10.7	12.5	11.8	50.9*	20.1	32.1	100	91.2	94.6	59.7*	32.6	43.2
Moderate form	3.8	4.5	4.2	33.4	34.7	34.1	0	8.8	5.4	27.4	30	29
Severe form	2.4	8*	5.8	15.7	45.2*	33.8	0	0	0	12.9	37.3*	27.8
Severe form (present + extracted teeth)	3.1	12.5*	8.7	18.1	54.2*	41.2	0	0	0	15	46*	34.8

*p < 0.001

($\chi^2 = 8.83$, $p = 0.003$) as well as tooth extraction due to MIH ($\chi^2 = 8.23$, $p = 0.004$).

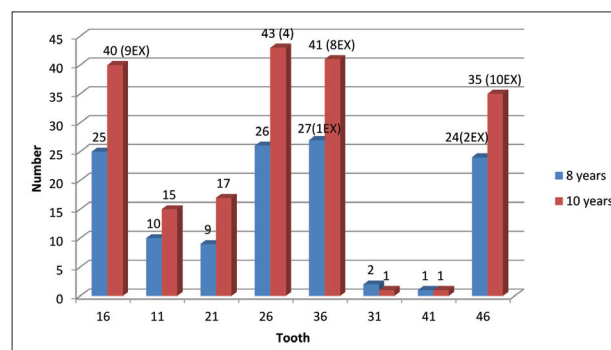
A demarcated opacity in molars is statistically more common in children aged eight years ($\chi^2 = 46.96$, $p < 0.001$), whereas both an atypical restoration ($\chi^2 = 18.89$, $p < 0.001$) and tooth extraction due to MIH ($\chi^2 = 12.01$, $p < 0.001$) are statistically more common in molars in children aged 10 years. There is no statistically significant difference in either frequency of demarcated opacities in incisors ($\chi^2 = 2.05$, $p = 0.152$) or in post-eruptive enamel breakdown ($\chi^2 = 2.05$, $p = 0.152$) in relation to age groups of children.

Demarcated opacity in teeth with MIH changes is statistically more common in children aged eight years ($\chi^2 = 41.61$, $p < 0.001$), whereas both an atypical restoration ($\chi^2 = 18.79$, $p < 0.001$) and tooth extraction due to MIH ($\chi^2 = 12.20$, $p < 0.001$) are statistically more common in children aged 10 years. Post-eruptive enamel breakdown in all teeth with MIH changes is with no statistically significant difference in relation to age groups ($\chi^2 = 0.67$, $p = 0.414$) (Table 2).

Frequency of some severity degrees by number of the respondents and affected teeth present in the respondents' mouths is shown in Table 3.

There is no statistically significant difference in either frequency of the mild ($\chi^2 = 0.54$, $p = 0.46$) or moderate form ($\chi^2 = 0.20$, $p = 0.65$) in relation to age groups of children. The severe form is statistically more common in children aged 10 years ($\chi^2 = 11.64$, $p < 0.001$) as well as the severe form with extracted teeth ($\chi^2 = 19.15$, $p < 0.001$).

Mild form in molars is statistically more common in children aged 8 years ($\chi^2 = 35.47$, $p < 0.001$) whereas both severe form ($\chi^2 = 16.58$, $p < 0.001$) and severe form with extracted teeth ($\chi^2 = 36.37$, $p < 0.001$) are statistically more common in molars in children aged 10 years. There is no statistically significant difference in frequency of moder-

**Figure 1.** Frequency of hypomineralized changes in molars and incisors per tooth and extracted teeth due to MIH

ate form in relation to age groups of children ($\chi^2 = 0.20$, $p = 0.65$). There is no statistically significant difference in either frequency of mild ($\chi^2 = 2.05$, $p = 0.152$) or moderate form ($\chi^2 = 2.05$, $p = 0.152$) in incisors in relation to age groups of children.

The mild form in all teeth with MIH changes is statistically more common in children aged eight years ($\chi^2 = 30.94$, $p < 0.001$), whereas both the severe form ($\chi^2 = 16.48$, $p < 0.001$) and severe form with extracted teeth ($\chi^2 = 34.39$, $p < 0.001$) are statistically more common in children aged 10 years. There is no statistically significant difference in the moderate form in all teeth with MIH changes in relation to age groups ($\chi^2 = 0.03$, $p = 0.86$).

The analysis of data has revealed that the upper right (16) and lower left first permanent molar (36) are most often (21.5%) affected by hypomineralized changes in children aged 10 years. In children aged eight years, lower left first permanent molar (36) is the most common tooth with hypomineralized changes. Of all the incisors in both jaws, upper right and upper left central incisors are most often affected by MIH in both age groups of children. Central lower incisors are slightly affected by the mentioned

changes. Lateral incisors in the upper and lower jaw, in the examined children, are not affected by the changes. All the teeth extracted due to hypomineralization are molars. The results have shown that the lower right first permanent molar (46) is the most common extracted tooth, which is 2.9% of teeth affected by MIH. The upper right (2.6%) and lower left first permanent molar (2.2%) are also commonly extracted teeth due to MIH, in children aged 10 years, which represents a statistically significant difference (Figure 1).

DISCUSSION

Analyzing and determining the frequency, prevalence and severity of MIH is not easy. Particularly difficult is the inevitable subjectivity in assessing the severity of the changes, and also non-standardized criteria used in various studies to diagnose the disease. However, the current findings of the prevalence of MIH in the northern part of Kosovo and Metohija are comparable to those from international studies conducted in the same age groups, which indicates that MIH is a significant problem [14, 18, 19, 20].

Prevalence of hypomineralized defects was first tested in this area and found in 12.2% of the total children examined. The same percentage of prevalence of MIH, as in our study, was found in Bosnia and Herzegovina (12.3%) in children aged 12 years [21], while in children aged eight years, in the municipality of Foča in 2008, MIH was recorded in 12.8% of the examined children [19]. Approximate percentage of MIH was found in the study conducted in Italy (Lissone) in 2005 with eight-year-old children, and was 13.7% [22]. The relatively high prevalence of MIH (17.85%) was found in children aged six and 14 in Spain [20]. In 2012 in Turkey, in a study conducted with children aged between eight and 11 years, the distribution of MIH was lower (7.7%) [23]. The study done in Libya in 2006 with children aged seven to nine years, showed significantly lower percentage of MIH (2.9%) [24]. Also, the study of prevalence of MIH in the permanent dentition in Chinese children aged 12 years in Hong Kong showed a low prevalence percentage of 2.8% [12]. Analysis of previous epidemiological studies confirms that the percentage of MIH prevalence is not negligible. Large differences in the results on the prevalence of HIM in different countries can be explained by different age groups of the respondents, local environmental factors, and different criteria used in the studies [13, 18, 20, 25].

The selected children were aged eight years, because in that age group all four first permanent molars and incisors were present, prevalence of dental caries was still low, so there was less chance that carious lesions mask hypomineralization. This study also included children aged 10 years to examine the progression of changes in molars, which largely depend on the post-eruptive tooth age or patient age. By analyzing the results of the hypomineralized changes in this study, it was found that there was no statistically significant difference in the occurrence of these changes in respondents aged eight and 10 years. Contrary

to this study, Sönmez et al. [23] found that MIH was more common in children aged eight compared to children aged 11 years (8.5% versus 6.5%).

Some studies speculated about the possible significance of sex in the development of MIH. Some studies point to a slightly higher prevalence of MIH in male respondents [6]. Neither this nor the studies in Libya nor in Bosnia and Herzegovina, nor other studies that addressed these issues, confirmed sex predisposition [19, 21, 23–26].

Review of literature shows that there is little data about individual criteria for MIH. The prevalence of certain criteria is difficult to compare. Despite the criteria being clearly determined, the details of the criteria are not clearly defined. One of the first concerns is the size of the lesion. In our research, we included only defects (opacities) larger than 1 mm in diameter. The same criterion, considering the size of the lesion, was used by Jälevik et al. [27] to determine the prevalence of MIH. Some studies included only defects larger than 2 mm [21, 22, 28].

By analyzing individual criteria for MIH in this study, it was found that demarcated opacity is the most common criterion, which is in agreement with other studies [19, 23, 25]. Post-eruptive enamel breakdown was found in 25.3% of the teeth and it was more common in molars compared to incisors. This finding is in agreement with other studies because the changes in incisors are not as extensive as in the first permanent molars and rarely, except for the color change, result in post-eruptive enamel breakdown, primarily because of no pressure during mastication [18, 25]. An atypical restoration, in our study, was found in 22.2% of the examined teeth and only in molars. The same percentage of teeth with an atypical restoration was found in the respondents in Bosnia and Herzegovina [21]. In the study in Lithuania, atypical restoration was found in 16.9% of the respondents with MIH [26].

In the present study, all teeth extracted due to hypomineralized changes or their complications were molars. In the study in the municipality of Foča conducted in 2008, tooth extraction due to MIH was found in 5.6% of children, i.e. 19% of the total number of teeth with MIH, and they were all molars [19]. In a study from Lithuania there were no teeth extracted due to MIH [26].

Un-erupted teeth due to hypomineralized changes were not found in this study. These data are in agreement with the majority of studies that dealt with MIH [19, 22, 23, 29].

By analyzing individual criteria for MIH, in relation to age, it was found that both atypical restoration and tooth extraction due to MIH are statistically more common in children aged 10 years. This finding points to the necessity of early diagnosis of MIH, which will enable timely prevention and treatment of this condition.

The mild form of hypomineralized changes in this study is the most common in all teeth with MIH. Compared to all MIH studies, we confirmed that the mild form prevailed [19, 23]. The severe form of hypomineralization was found in 5.8% of children, i.e. 27.8% of teeth, of which all were molars. The severe form was not found in incisors. In a study in conducted in Sweden in 2001 a similar percentage was recorded: severe form was found

in 6.3% of the respondents [27], while significantly lower percentage was found in a group of children who lived in the Italian city Lissone (0.4%) [22]. By analyzing the presence of some degree of severity in relation to age, it was found that the severe form was more common in children aged 10 years, while the mild form was more common in younger children. There were no significant differences in the mean values of moderate forms. These results are in agreement with findings of other authors [18, 23, 25, 30]. Frequent prevalence of the severe form in older children can be explained by the fact that hypomineralized molars, depending on the degree of hypomineralization, are brittle, fragile, and as such prone to post-eruptive enamel breakdown under the influence of chewing forces. Also, due to hypersensitivity to temperature stimuli, children with these changes can have painful sensations when brushing teeth. This is the reason why they avoid regular oral hygiene. This leads to accumulation of dental plaque, together with rapid progression of caries lesions that result in crown destruction and tooth loss.

This study confirms the findings of other studies, where the first permanent molars are most often affected by MIH changes, while the lateral incisors are least affected [12, 18, 21, 29]. When analyzing the presence of MIH in each tooth, it can be concluded that the upper right (16) and lower

left first permanent molar (36) are most often affected by hypomineralized changes. Data from the literature suggest that the changes are more common in maxillary incisors, which is also confirmed in our study [19, 23, 27, 29].

CONCLUSION

Hypomineralization of the first permanent molars and incisors is very common in children in many European countries, as well as in our country, which was confirmed by our study. In this study, no significant difference in frequency of MIH changes was found in respondents in relation to age and sex. In relation to the degree of severity of MIH changes, it was found that the severe form was more common in children aged 10 years, while the mild form was more common in younger children. This finding indicates that MIH is inadequately treated and not recognized on time due to the rapid post-eruptive enamel loss, hypersensitivity of the affected teeth, rapid and early caries progression (especially in the first permanent molars), and dental wear. Therefore, monitoring teeth eruption and making an accurate and timely diagnosis of MIH would significantly contribute to better prevention and treatment of these developmental defects.

REFERENCES

- Marthaler TM. Changes in dental caries 1953-2003. *Caries Res.* 2004; 38(3):173-81.
- Koch G, Hallonsten AL, Ludvigsson N, Hansson BO, Holst A, Ullbro C. Epidemiologic study of idiopathic enamel hypomineralization in permanent teeth of Swedish children. *Community Dent Oral Epidemiol.* 1987; 15(5):279-85.
- Weerheijm KL. Molar incisor hypomineralization (MIH). *Eur J Paediatr Dent.* 2003; 4(3):114-20.
- Crombie FA, Manton DJ, Weerheijm KL, Kilpatrick NM. Molar incisor hypomineralization: a survey of members of the Australian and New Zealand Society of Paediatric Dentistry. *Aust Dent J.* 2008; 53(2):160-6.
- Vieira AR, Kup E. On the Etiology of Molar-Incisor Hypomineralization. *Caries Res.* 2016; 50(2):166-9.
- Jälevik B, Norén JG, Klingberg G, Barregård L. Etiologic factors influencing the prevalence of demarcated opacities in permanent first molars in a group of Swedish children. *Eur J Oral Sci.* 2001; 109(4):230-4.
- Ess A, Laisi S, Sahlborg C, Lukinmaa PL, Alaluusua S. Early use of amoxicillin may cause molar incisor hypomineralization (MIH). *Eur Arch Paediatr Dent.* 2008; 9:225-8.
- Whatling P, Fearn J. Molar Incisor Hypomineralisation: a study of aetiological factors in a group of UK children. *Int J of Paediatr Dent.* 2008; 18(3):155-62.
- Silvia MJ, Scurrah KJ, Craig JM, Manton DJ, Kilpatrick N. Etiology of Molar Incisor Hypomineralization - A Systematic Review. *Community Dent Oral Epidemiol.* 2016; 44(4):342-53.
- Weerheijm KL. Molar incisor hypomineralization (MIH): clinical presentation, aetiology and management. *Dent Update.* 2004; 31(1):9-12.
- Ivanović M, Živojinović V, Šindolčić M, Marković D. Molar incisor hypomineralisation in the first permanent teeth. *Srp Arh Celok Lek.* 2007; 135(7-8):472-7.
- Cho SY, Ki Y, Chu V. Molar incisor hypomineralization in Hong Kong Chinese children. *Int J Paediatr Dent.* 2008; 18(5):348-52.
- Jälevik B. Prevalence and Diagnosis of Molar Incisor Hypomineralisation (MIH): A systematic review. *Eur Arch Paediatr Dent.* 2010; 11(2):59-64.
- Balmer R, Toumba J, Godson J, Duggal M. The prevalence of molar incisor hypomineralisation in Northern England and its relationship to socioeconomic status and water fluoridation. *Int J Paediatr Dent.* 2012; 22(4):250-7.
- Ghanim A, Morgan M, Mariño R, Bailey D, Manton D. Molar incisor hypomineralisation: prevalence and defect characteristics in Iraqi children. *Int J Paediatr Dent.* 2011; 21(6):413-21.
- Soviero V, Haubek D, Trindade C, Da Matta T, Poulsen S. Prevalence and distribution of demarcated opacities and their sequelae in permanent 1st molars and incisors in 7 to 13-year-old Brazilian children. *Acta Odontol Scand.* 2009; 67(3):170-5.
- Weerheijm KL, Duggal M, Mejäre I, Papagiannoulis L, Koch G, Martens LC, et al. Judgement criteria for molar incisor hypomineralisation (MIH) in epidemiologic studies: a summary of the European meeting on MIH held in Athens, 2003. *Eur J Paediatr Dent.* 2003; 4(3):110-3.
- Lygidakis NA, Dimoun G, Briseniou E. Molar-Incisor hypomineralization (MIH). A retrospective clinical study in Greek children: prevalence and defects characteristic. *Eur Arch Paediatr Dent.* 2008; 9:207-17.
- Janković S, Ivanović M, Davidović B, Lecić J. Distribution and characteristics of molar-incisor hypomineralization. *Vojnosanit Pregl.* 2014; 71(8):730-34.
- Martínez Gómez TP, Guinot Jimeno F, Bellet Dalmau LJ, Giner Tarrida L. Prevalence of molar-incisor hypomineralisation observed using transillumination in a group of children from Barcelona (Spain). *Int J Paediatr Dent.* 2012; 22(2):100-9.
- Muratbegovic A, Markovic N, Ganibegovic Selimovic M. Molar incisor hypomineralisation in Bosnia and Herzegovina: Prevalence, aetiology and clinical consequences in medium caries activity population. *Eur Arch Paediatr Dent.* 2007; 8(4):189-94.
- Caladera PC, Gerthoux PM, Mocarelli P, Lukinmaa PL, Tramacere PL, Alaluusua S. The prevalence of molar incisor hypomineralisation (MIH) in a group of Italian school children. *Eur J Paediatr Dent.* 2005; 6(2):79-83.
- Hayriye S, Gözde Y, Tuğba B. The prevalence and severity of molar incisor hypomineralization in a group of children living in Ankara Turkey. *Clinical dentistry and research.* 2013; 37(1):33-40.
- Fteita D, Ali A, Alaluusua S. Molar-Incisor Hypomineralisation (MIH) in group of school-aged children in Benghazi, Libya. *Eur Arch Paediatr Dent.* 2006; 7(2):92-5.

25. Costa-Silva CMD, Jeremias F, De Souza JF, Cordeiro Rde C, Santos-Pinto L, Zuanon AC. Molar incisor hypomineralization: prevalence, severity and clinical consequences in Brazilian children. *Int J Paediatr Dent.* 2010; 20(6):426–34.
26. Jasulaityte L, Veerkamp KL, Weerheijm KL. Molar incisor hypomineralisation: review and prevalence data from a study of primary school children in Kaunas (Lithuania). *Eur Arch Paediatr Dent.* 2007; 8(2):87–94.
27. Jälevik B, Klingberg G, Barregard L, Noren JG. The prevalence of demarcated opacities in permanent first molars in a group of Swedish children. *Acta Odontol Scand.* 2001; 59(5):255–60.
28. Leppäniemi A, Lukinmaa PL, Alaluusua S. Nonfluoride hypomineralizations in the permanent first molars and their impact on the treatment need. *Caries Res.* 2001; 35(1):36–40.
29. Wogelius P, Haubek D, Poulsen S. Prevalence and distribution of demarcated opacities in permanent 1st molars and incisors in 6 to 8-year-old Danish children. *Acta Odontol Scand.* 2008; 66(1):58–64.
30. Preusser SE, Ferring V, Wleklinski C, Wetzel WE. Prevalence and severity of molar incisor hypomineralization in a region of Germany—a brief communication. *J Public Health Dent.* 2007; 67(3):148–50.

Учесталост, карактеристике и степен изражености хипоминаерализације на првим сталним кутњацима и секутићима код деце која живе на подручју северног дела Косова и Метохије

Бранкица Мартиновић¹, Мирјана Ивановић², Андријана Цветковић¹, Јелена Тодић¹, Зораида Милојковић¹, Јасна Павловић¹, Саша З. Табаковић¹, Ивана Стошовић-Калезић¹

¹Медицински факултет Приштина, Стоматолошки одсек, Косовска Митровица, Србија;

²Стоматолошки факултет, Клиника за превентивну и дечју стоматологију, Београд, Србија

САЖЕТАК

Увод/Циљ Хипоминаерализација кутњака и секутића (ХКС) релативно је честа развојна аномалија која се карактерише појавом хипоминаерализованих дефеката глеђи на првим сталним кутњацима и секутићима.

Циљ овог рада био је да се испита учесталост хипоминаерализације на првим сталним кутњацима и секутићима код деце узраста осам и десет година на подручју северног дела Косова и Метохије.

Методe У истраживању је било укључено 712 испитаника – 289 узраста осам година (40,6%) и 423 (59,4%) узраста десет година. За дијагнозу обољења примењени су критеријуми по *Weerheijm*-у и одређен је степен изражености промена.

Резултати Учесталост хипоминаерализованих промена на првим сталним кутњацима и секутићима код испитиване деце на овом подручју износио је 12,2%. Код деце од осам година учесталост ових промена је мања (10,7%) у односу на

испитанике од десет година (13,2%). Ограничена замућеност глеђи била је учесталија код деце млађег узраста, док је код деце старијег узраста учесталија атипична рестаурација и екстракција зуба као последица хипоминаерализације. Блага форма је учесталија код деце од осам година, док је код деце од десет година учесталија тешка форма, као и тешка форма која укључује и екстрахиране зубе. Резултати показују да су први стални кутњаци најчешће захваћени хипоминаерализованим променама.

Закључак Процент од 12,2% испитаника са променама ХКС на подручју северног дела Косова и Метохије није занемарљив. Овакво стање указује на неопходност ране дијагностике да би се благовременом превенцијом и терапијом спречиле и ублажиле компликације овог обољења.

Кључне речи: хипоминаерализација; кутњаци, секутићи; деца; учесталост