



СРПСКИ АРХИВ
ЗА ЦЕЛОКУПНО ЛЕКАРСТВО
SERBIAN ARCHIVES
OF MEDICINE

Address: 1 Kraljice Natalije Street, Belgrade 11000, Serbia

+381 11 4092 776, Fax: +381 11 3348 653

E-mail: office@srpskiarhiv.rs, Web address: www.srpskiarhiv.rs

Paper Accepted*

ISSN Online 2406-0895

Case report / Приказ болесника

Mladen Bila[†], Igor Kovačević, Goran Damjanović, Jelena Potić, Jelena Karadžić

**A rare mechanism of subconjunctival dislocation of anterior chamber
intraocular lens after blunt ocular trauma**

Редак механизам субкоњунктивалне дислокације предње коморног сочива
након контузионе повреде ока

Clinic for eye diseases, Clinical Center of Serbia, Belgrade, Serbia

Received: February 5, 2020

Revised: April 18, 2020

Accepted: April 19, 2020

Online First: April 27, 2020

DOI: <https://doi.org/10.2298/SARH200205023B>

***Accepted papers** are articles in press that have gone through due peer review process and have been accepted for publication by the Editorial Board of the *Serbian Archives of Medicine*. They have not yet been copy-edited and/or formatted in the publication house style, and the text may be changed before the final publication.

Although accepted papers do not yet have all the accompanying bibliographic details available, they can already be cited using the year of online publication and the DOI, as follows: the author's last name and initial of the first name, article title, journal title, online first publication month and year, and the DOI; e.g.: Petrović P, Jovanović J. The title of the article. Srp Arh Celok Lek. Online First, February 2017.

When the final article is assigned to volumes/issues of the journal, the Article in Press version will be removed and the final version will appear in the associated published volumes/issues of the journal. The date the article was made available online first will be carried over.

[†]**Correspondence to:**

Mladen BILA,

Clinic for eye diseases, Clinical Center of Serbia, Pasterova 2, 11000 Belgrade, Serbia

Email: mladen.bila@gmail.com

A rare mechanism of subconjunctival dislocation of anterior chamber intraocular lens after blunt ocular trauma

Редак механизам субкоњунктивалне дислокације предње коморног сочива након контузионе повреде ока

SUMMARY

Introduction Dislocation of intraocular lens after ocular trauma is an emergency situation requiring the prompt surgery. Dislocation of intraocular lens into the subconjunctival space or pseudophacocoele is a rare event after blunt ocular trauma.

Case outline We report a case of a pseudophakic patient with dislocation of anterior chamber intraocular lens into subconjunctival space following blunt trauma to the right eye after the loss of consciousness and a fall. A 76-year-old man presented with anterior chamber intraocular lens dislocation into subconjunctival space, adapted old scleral wound and preserved corneal integrity. Fifteen years ago, he suffered right eye globe rupture after blunt trauma which was surgically closed and anterior chamber intraocular lens was inserted.

Conclusion This case highlights a rare mechanism of anterior chamber intraocular lens dislocation into subconjunctival space following blunt ocular trauma with preserved corneal integrity and adapted old scleral wound. In the cases of post-traumatic aphakia intraocular lens dislocation into the subconjunctival space should be suspected.

Keywords: ocular trauma; intraocular lens; subconjunctival lens dislocation; eye globe rupture; epiretinal membrane

САЖЕТАК

Увод Дислокација интраокуларног сочива као последица трауме ока је ургентно стање које захтева хитну хируршку интервенцију. Дислокација артифицијалног сочива у субкоњунктивални простор или псеудофакоцела је ретка и неуобичајена последица након тупе повреде ока.

Приказ случаја Код болесника старог 76 година је утврђена дислокација артифицијалног предње коморног сочива у доње-темпорални субкоњунктивални простор након контузионе повреде десног ока настале након губитка свести и пада. Утврђен је очуван интегритет булбуса са добро адаптираном старом раном на склери у коју је инкарцериран део увеалног ткива. Болесник је пре 15 година имао трауматску руптуру булбуса на десном оку која је била хируршки збринута и тада му је уграђено артифицијално предње коморно сочиво

Закључак У раду је приказан редак механизам дислокације артифицијалног предње коморног сочива у субкоњунктивални простор након контузионе повреде ока са очуваним интегритетом роњаче и добро адаптираном старом склералном раном. У случајевима посттрауматске афакије треба имати у виду и могућност дислокације интраокуларног сочива у субкоњунктивални простор.

Кључне речи: траума ока; интраокуларно сочиво; субкоњунктивална дислокација сочива; руптура булбуса; епиретинална мембрана

INTRODUCTION

Ocular trauma may cause significant ocular morbidity and is usually associated with the displacement of the natural lens in a phakic eye and of the intraocular lens (IOL) in a pseudophakic eye [1]. Biedner et al. [2] first defined the term “pseudophacocoele” for the subconjunctival extrusion of an IOL associated with eyeball rupture following blunt ocular trauma. Pseudophacocoele represents a rare clinical condition and therefore scarce data on patients’ visual outcomes are reported. Blunt eye trauma may lead to IOL subluxation, dislocation into the vitreous cavity, anterior chamber or suprachoroidal space, or IOL may be extruded from the eye in the subconjunctival space, most commonly through the surgical wound [3].

We present a rare case of blunt ocular trauma in which an anterior chamber IOL was dislocated into the subconjunctival space with preserved integrity of bulbar wall despite the ocular trauma.

CASE REPORT

A 76-year-old man was admitted at our Clinic for eye disease and presented with subconjunctival anterior chamber intraocular lens (ACIOL) dislocation following blunt trauma. He reported that he had suddenly lost the consciousness, fallen down and struck his right eye against bedside table a month earlier. Medical history included transient ischemic attacks with sudden loss of consciousness. His ocular history included right eye globe rupture due to the similar blunt ocular trauma that he experienced fifteen years ago. At that time, globe rupture was surgically treated and the scleral wound was closed at another eye clinic. Later that year the ACIOL was inserted in his right eye at the same eye clinic. He had undergone a cataract operation with implantation of a posterior chamber intraocular lens (PCIOL) in his left eye several years ago.

The patient's best corrected visual acuity was 6/60 on the right eye and 6/6 on the left eye. Intraocular pressure on the right eye was 13mmHg and on the left eye 16mmHg. Slitlamp examination of the anterior segment in his right eye showed mild hyperemia of the bulbar conjunctiva and displaced ACIOL in the infero-temporal subconjunctival space (Fig. 1). Examination of the sclera revealed at 12 to 3.0' clock intact and adapted old scleral wound with the incarcerated uveal tissue at 2.0' clock (Fig. 2). Corneal leucoma in limbal zone from 10 to 2.0' clock was present. Observation of the anterior chamber demonstrated the presence of vitreous body and hyphema presented as a reddish tinge. Also, the presence of traumatic aniridia was revealed in his right eye (Fig. 3). Eye fundus examination demonstrated mild partial haemophthalmus and epiretinal membrane in the macula. Photo fundus revealed the presence of epiretinal membrane in macula in his right eye (Fig. 4). Examination of the left eye showed the presence of PCIOL and hypertone fundus with no other abnormalities. Dislocated ACIOL in his right eye was operatively extracted from subconjunctival space under local anesthesia.

DISCUSSION

Pseudophacocoele or dislocation of IOL into the subconjunctival space after blunt ocular trauma is rare entity and can lead to serious ocular complications [4]. In this case report we describe a rare mechanism of an ACIOL being dislocated into the subconjunctival space after blunt ocular trauma with no evidence of the dehiscence of an old scleral wound which occurred in our patient after the rupture of the eye globe following trauma fifteen years ago. Scleral wound was adapted and intact with incarcerated uveal tissue and covered by conjunctiva. The integrity of cornea was preserved.

Most commonly IOL may be extruded from the eye into the subconjunctival space through the surgical wound. The presence of large surgical wound increases the risk of IOL extrusion after blunt trauma as presented by Azis et al. [5], in which report the authors hypothesized that IOL was dislocated into the subconjunctival space through the large corneal wound following the antero-posterior compression and equatorial expansion of the globe. Kumawat et al. [6] reported a case of post-traumatic pseudophacocoele where no scleral wound dehiscence could be noted. In reported case previous scleral wound from cataract surgery may have opened up and led to dislocation of IOL, but may have sealed spontaneously. We hypothesize that antero-posterior compression and equatorial expansion of the globe may be a possible mechanism of ACIOL dislocation in our patient. Of note, our patient's visual outcome was surprisingly good considering the fact that he had experienced two serious blunt ocular traumas which were associated with complications including traumatic aniridia, aphakia and epiretinal membrane.

We present a case of ACIOL dislocation in the infero-temporal part of subconjunctival space following blunt ocular trauma with rare mechanism of ACIOL dislocation since the bulbar wall integrity was preserved. We believe that in our patient previous corneal wound from cataract surgery may have opened up, caused the dislocation of ACIOL and then the wound has sealed spontaneously as he was presented to our clinic a month after the blunt eye trauma. The presence of epiretinal membrane in macula, aphakia and traumatic aniridia may be treated by vitrectomy with membrane peeling accompanied with transconjunctival intrascleral fixation of intraocular lens or by intrascleral insertion of 3-piece lens and silicon iris prosthesis [7-9].

We present the case of rare mechanism of ACIOL dislocation into the subconjunctival space after blunt ocular trauma which should be suspected while examining cases of post-traumatic aphakia.

ACKNOWLEDGMENT

All procedures performed were in accordance with the ethical standards of the institutional and national research committee and with the 1964 Helsinki declaration and its later amendment. Written consent to publish all shown material was obtained from the patient.

Conflicts of interest: Authors declare no conflicts of interest.

REFERENCES

1. Narang P, Agarwal A. Clinical outcomes in traumatic pseudophacole: A rare clinical entity. *Indian J Ophthalmol.* 2017; 65(12):1465-1469. doi: 10.4103/ijo.IJO_1068_17.
2. Biender B, Rothkoff L, Blumenthal M. Subconjunctival dislocation of intraocular lens implant. *Am J Ophthalmol.* 1977; 84(2):265-266.
3. Mohan A, Kaur N, Sharma V. Inferior subconjunctival dislocation of posterior chamber intraocular lens after blunt trauma. *Indian J Ophthalmol.* 2017; 65(6):521-523 doi: 10.4103/ijo.IJO_359_16.
4. Bawankar PM, Lahane T, Parekh R. Pseudophacole. *Indian J Ophthalmol.* 2018; 66(8): 1191. doi: 10.4103/ijo.IJO_323_18
5. Aziz S, Asokumaran T, Intan G. Pseudophacocoele following blunt ocular trauma. *Med J Malaysia.* 2011; 66(1):64-65.
6. Kumawat D, Sachan A, Sahay P, Kumar V. Delayed presentation of post-traumatic pseudophacocoele. *BMJ Case Rep.* 2018:1-2 doi:10.1136/bcr-2018-226957
7. Yamane S, Sato S, Maruyama-Inoue M, Kadonosono K. Flanged Intrascleral Intraocular Lens Fixation with Double Needle Technique. *Ophthalmology.* 2017; 124(8):1136-1142. doi: 10.1016/j.ophtha.2017.03.036.
8. Yavuzer K, Evcimen Y. Sutureless transconjunctival intrascleral intraocular lens fixation: the modified Yamane technique. *Arq Bras Oftalmol.* 2019; 82(5):389-393. doi: 10.5935/0004-2749.20190072.
9. Gooi P, Teichman JC, Ahmed II. Sutureless intrascleral fixation of a custom-tailored iris prosthesis with an intraocular lens. *J Cataract Refract Surg.* 2014; 40(11):1759-63. doi: 10.1016/j.jcrs.2014.09.015.

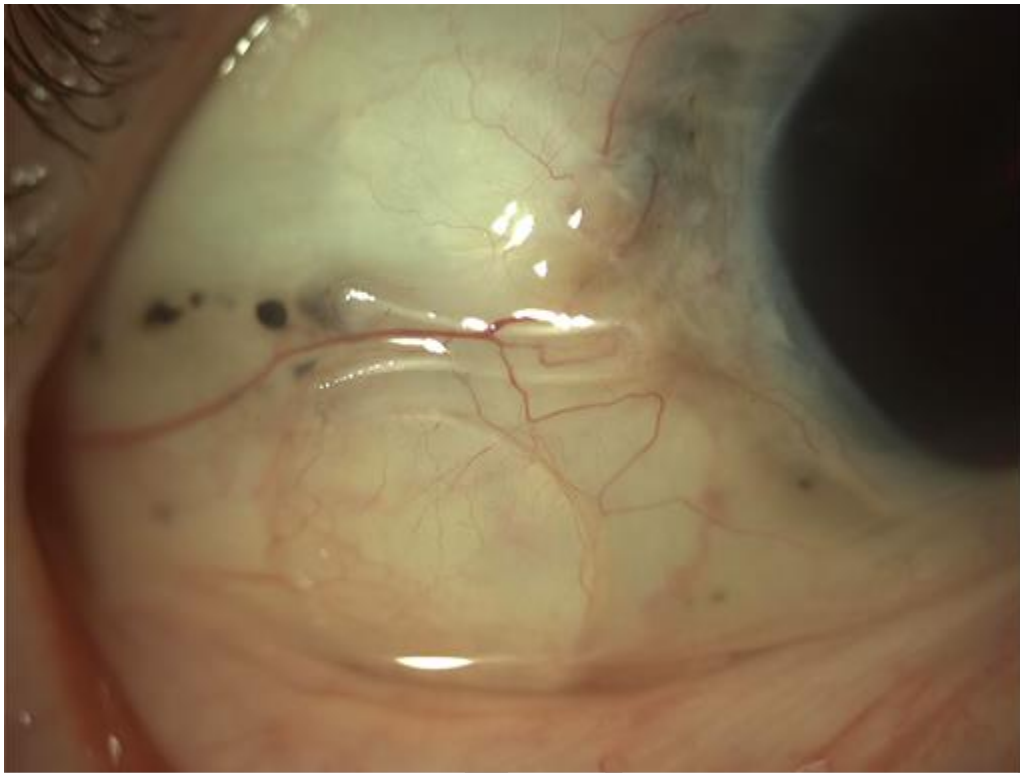


Figure 1. Dislocated anterior chamber intraocular lens in infero-temporal subconjunctival space

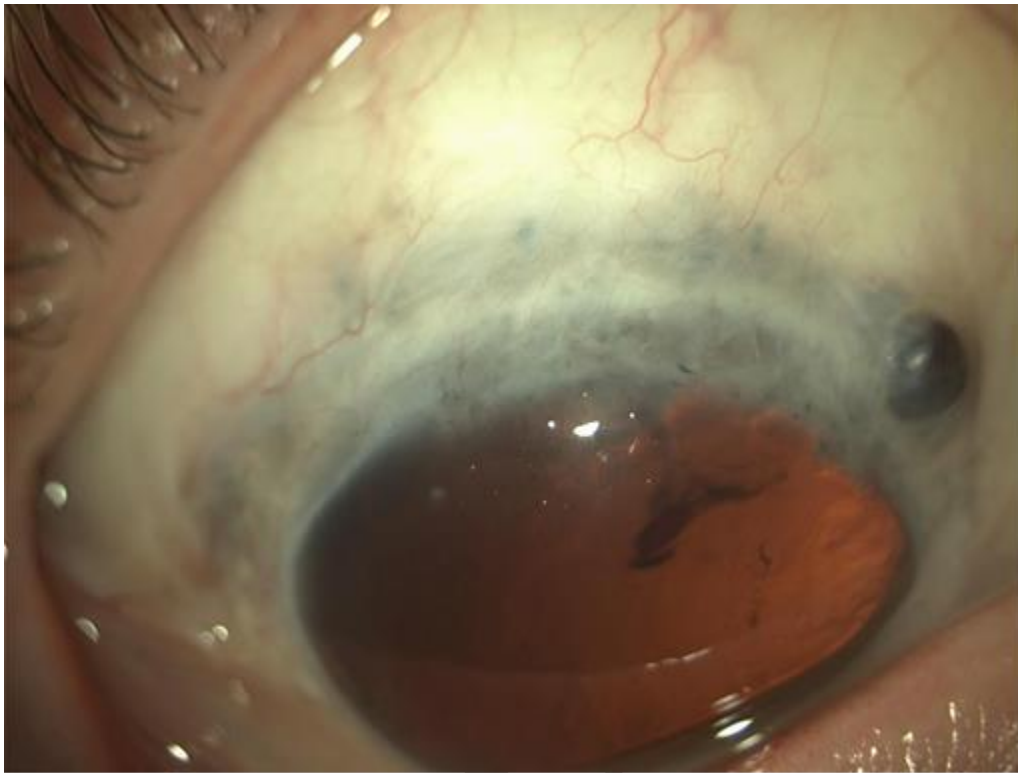


Figure 2. Intact and adapted scleral wound with the incarcerated uveal tissue at 2 o'clock

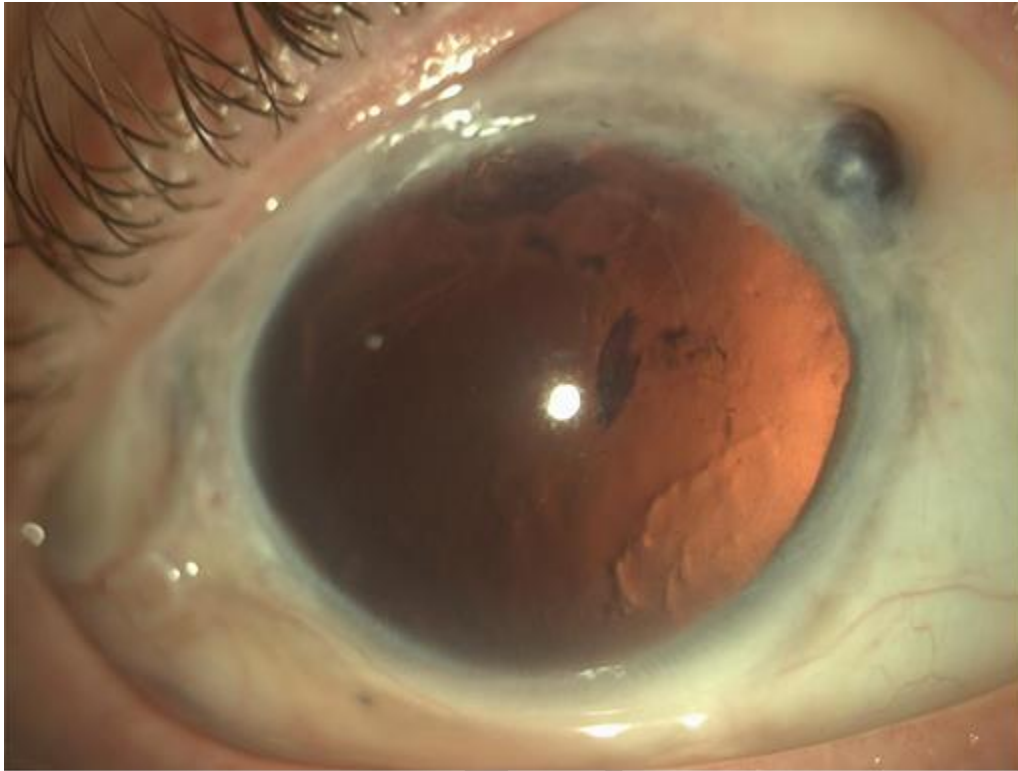


Figure 3. Corneal leucoma from 10 to 2 o'clock in the limbal zone, traumatic aniridia, the presence of vitreous body and hyphaema in anterior chamber

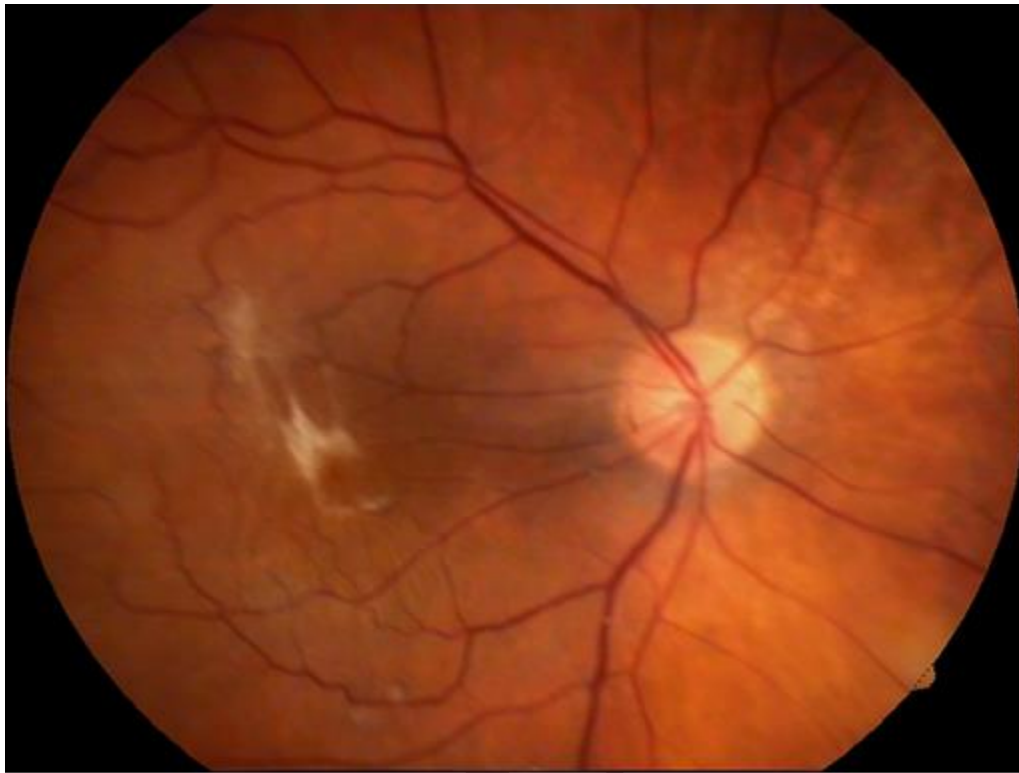


Figure 4. Photo fundus of epiretinal membrane in macula