



СРПСКИ АРХИВ
ЗА ЦЕЛОКУПНО ЛЕКАРСТВО
SERBIAN ARCHIVES
OF MEDICINE

Address: 1 Kraljice Natalije Street, Belgrade 11000, Serbia

+381 11 4092 776, Fax: +381 11 3348 653

E-mail: office@srpskiarhiv.rs, Web address: www.srpskiarhiv.rs

Paper Accepted*

ISSN Online 2406-0895

Case report / Приказ болесника

Ivan V Nikolić^{1,2,*}, Andrej Petreš³, Viktorija Vučaj-Ćirilović^{1,2}, Nenad Šolajić^{1,2},
Jelena Radić^{1,2}

**Implantation metastasis of colorectal cancer following percutaneous
biliary drainage**

Имплантациона метастаза колоректалног карцинома након перкутане дренаже
жучних путева

¹University of Novi Sad, Faculty of Medicine Novi Sad, Serbia;

²Oncology Institute of Vojvodina, Sremska Kamenica, Serbia;

³Clinical Center of Vojvodina, Novi Sad, Serbia

Received: August 19, 2022

Revised: September 20, 2022

Accepted: October 13, 2022

Online First: October 17, 2022

DOI: <https://doi.org/10.2298/SARH220819100N>

***Accepted papers** are articles in press that have gone through due peer review process and have been accepted for publication by the Editorial Board of the *Serbian Archives of Medicine*. They have not yet been copy-edited and/or formatted in the publication house style, and the text may be changed before the final publication.

Although accepted papers do not yet have all the accompanying bibliographic details available, they can already be cited using the year of online publication and the DOI, as follows: the author's last name and initial of the first name, article title, journal title, online first publication month and year, and the DOI; e.g.: Petrović P, Jovanović J. The title of the article. *Srp Arh Celok Lek*. Online First, February 2017.

When the final article is assigned to volumes/issues of the journal, the Article in Press version will be removed and the final version will appear in the associated published volumes/issues of the journal. The date the article was made available online first will be carried over.

***Correspondence to:**

Ivan V NIKOLIC

Put Dr Goldmana 4

21204 Sremska Kamenica

Serbia

E mail ivan.nikolic@mf.uns.ac.rs

Implantation metastasis of colorectal cancer following percutaneous biliary drainage

Имплантициона метастаза колоректалног карцинома након перкутане дренаже жучних путева

SUMMARY

Introduction Malignant biliary obstruction represents a poor prognostic sign of metastatic colorectal carcinoma. Percutaneous transhepatic biliary drainage (PTBD) is the procedure of choice for palliative biliary decompression, and this method have both a diagnostic and therapeutic value. One of the well-known complications following this procedure is the development of catheter tract metastases that occur in up to 6% of cases post-PTBD.

The aim was to present a patient with implantation metastases of colorectal cancer following PTBD.

Case report In the last six years, 89 patients underwent PTBD procedure at the Oncology Institute of Vojvodina. Among these patients, catheter tract implantation metastasis developed in one patient (1.1%). In this report, we present a patient who underwent right hemicolectomy in January 2015 at the Institute due to colon cancer located in the transverse colon. In January of 2018, a computed tomography scan of the abdomen showed metastatic disease and chemotherapy was initiated. However, 29 months following the start of chemotherapy, the patient developed jaundice, and as a result, PTBD procedure was performed. A control computed tomography scan of the abdomen in March of 2021 showed a *de novo* subcutaneous nodule 20 mm in diameter located at the level of ninth right rib. The nodule had been considered a part of the scar that formed at a place of catheter entry, and was still present eight months after PTBD procedure. Biopsy of the subcutaneous mass and pathohistological analysis confirmed well differentiated colon adenocarcinoma.

Conclusion Catheter tract implantation metastasis is not a rare complication following PTBD for malignant biliary obstruction. It generally has a poor prognosis. Nevertheless, literature review shows that radical surgical excision of the catheter tract tissue with hepatectomy can prolong survival in select group of patients.

Keywords: colorectal cancer; malignant biliary obstruction; implantation metastasis; percutaneous transhepatic biliary drainage

САЖЕТАК

Увод Билијарна опструкција је честа компликација метастатског колоректалног карцинома и удружена је са лошом прогнозом код ових пацијената. Перкутана трансхепатична билијарна дренажа (ПТБД) је широко распрострањена процедура за билијарну декомпресију узрокована малигнитетом која служи за дијагностичке, терапијске и палијативне сврхе. Појава метастаза на месту увођења катетера јавља се у 0,6–6% случајева.

Циљ рада је приказ пацијента са имплантиционом метастазом колоректалног карцинома након перкутане билијарне дренаже.

Приказ болесника На Институту за Онкологију Војводине у протеклих шест година, 89 пацијената су подвргнути ПТБД процедури, а појава имплантиционе метастазе на месту увођења катетера се јавила код једног пацијента (1,1%).

Представљамо пацијента којем је у нашој установи због карцинома попречног колона учињена у Јануару 2015 године десна хемиколектомија. Јануара 2018. године, ЦТ абдомена је указао на појаву метастатске болести те је започета хемиотерапија, али се појавила жутица 29 месеци касније те је урађена ПТБД процедура. Контролни ЦТ абдомена (март 2021. године) је показао појаву *de novo* субкутаног чвора 20 мм у пределу деветог ребра десно што је схваћено као место ожиљка на месту увођења катетера осам месеци након ПТБД процедуре. Биопсијом поткожне метастазе патохистолошки је верификован добро диферентовани аденокарцином дебелог црева.

Закључак Појава имплантиционих метастаза на месту увођења катетера због малигне билијарне опструкције није ретка компликација након ПТБД са генерално лошом прогнозом код ових пацијената. Ипак прегледом литературе код селектованих пацијената радикална операција са ексцизијом катетерског тракта која захтева и хепатектомију омогућава дуготрајније преживљавање.

Кључне речи: колоректални карцином; малигна билијарна опструкција; имплантициона метастаза; перкутана трансхепатична билијарна дренажа

INTRODUCTION

Malignant biliary obstruction represents a poor prognostic sign of metastatic colorectal carcinoma [1]. It usually develops as a consequence of metastatic tissue growth in the liver itself, on the peritoneum at the hilum of the liver, along the extrahepatic portions of the biliary tract, or in the extrahepatic lymph nodes [2]. In these cases, percutaneous transhepatic biliary drainage (PTBD) is the procedure of choice with a main purpose of palliative biliary decompression. In addition, PTBD can also have diagnostic and therapeutic value [3,4]. However, one of the well-known complications following this procedure is the development of catheter tract metastasis. Published reports show that this complication can occur in up to 6% of cases post-PTBD. In this case report, we present a patient with implantation metastases of colorectal cancer following percutaneous biliary drainage.

CASE REPORT

A 68-year-old man was admitted to our department where he had been receiving chemotherapy regularly according to the FOLFIRI protocol (5-Fluorouracil 400mg/m², 5-Fluorouracil 600mg/m² in 22h, Leucovorin 200mg/m², and Irinotecan 180mg/m²) every 2 weeks for metastatic colon cancer. During the interview with a physician, the patient complained of painful swelling on his right lower chest wall. On clinical examination, a 5x3cm solid, elastic nodule was palpated in the right anterolateral chest wall over the ninth rib and adjacent intercostal spaces. The mass was fixed to the chest wall. The overlying skin was mobile, but had a scar that corresponded to the previous PTBD procedure (Figure 1).

It is important to note that in January 2015 the patient underwent right hemicolectomy at the Institute due to colon cancer located in the transverse colon. The subsequent pathohistological examination confirmed TNM stage: G2 Adenocarcinoma T3N2(8/23)M0 with perivascular (pV+) and perineural invasion (pN+). In accordance with this, the patient

received 8 cycles of adjuvant chemotherapy with Capecitabin, and he had regular 6-month follow up.

In January of 2018, an abdominal CT scan showed enlarged intrabdominal lymph nodes surrounding the celiac plexus and superior mesenteric artery. A multidisciplinary team of physicians recommended the two-week FOLFIRI chemotherapy regimen. In June of 2020, after 29 months of stop-and-go chemotherapy regimen, the disease was radiologically stable, but with the apparent clinical onset of jaundice. An abdominal ultrasound showed dilatation of the right and left hepatic duct, as well as the common bile duct. Following this, in July of 2020, the PTBD with external and internal biliary drainage was successfully performed, which resulted in decrease of bilirubin levels during the course of the following 6 weeks. A control CT scan of the abdomen in March of 2021 showed stable disease and the presence of a *de novo* subcutaneous nodule 20mm in diameter at level of the 9th rib on the right in the area considered for a scar at a place of catheter entry during the PTBD procedure performed 8 months prior to this. The same treatment regimen (FOLFIRI) was continued, but at each subsequent hospitalization subcutaneous node was growing larger and and the patient started to complain of increasing pain and discomfort in this area. An ultrasound-guided core biopsy of the lesion dimension 4x3cm was performed, and histopathological examination of the standard hematoxylin and eosin (H&E) stained sections revealed neoplastic infiltration of fibrous tissue in the form of large lakes of extracellular mucin with occasional strips of neoplastic colorectal epithelium (Figure 2). Re-examination of the archived slides of the primary tumor of the transverse colon confirmed that the biopsied subcutaneous tissue had essentially the same morphological features (Figure 3). Moreover, after additional immunohistochemical analysis was performed, immunoreactivity for SATB-2 and CK20, and no staining with anti-CK7 antibody definitely confirmed the colorectal origin of the low-grade metastatic tumor.

DISCUSSION

Metastases along the catheter tract from PTBD procedure can originate from various primary tumors, but typically originate from metastatic pancreatic and biliary tumors. However, to our best knowledge, this is a first case report on implantation metastasis of colon cancer following PTBD and the information regarding the median time to detection post procedure, disease management, median survival, and prognosis specific for this case are lacking.

In cases that originated from the primary tumors of the biliary tract, median time to detection is 14 months post-PTBD, and it has been reported in up to 6% of people who underwent this procedure [5, 6]. Out of 89 patients that had this procedure performed at our institution over the course of six years, only the patient from the present case report developed catheter tract implantation metastasis (1.1% of total number of cases). Although there are several proposed mechanisms that explain pathogenesis of catheter tract metastasis, the precise mechanism has not been completely elucidated. There are reports showing that longer procedure times with multiple catheter insertions and biliary tract manipulations increase probability for tumor cell seeding. In addition, more differentiated tumors, and those with papillary histology are more prone to seeding along the catheter tract [6]. In accordance with this observation, pathohistology report on the presented patient confirmed that implantation subcutaneous metastasis contained well differentiated colorectal adenocarcinoma cells.

Oleaga et al. [7] was the first to report on a case of cutaneous metastasis of hilar cholangiocarcinoma.

Liu et al. [8] reviewed the English literature and found 30 reports on cases of cutaneous metastases in hilar cholangiocarcinoma.

In general, the prognosis for these patients is poor. However, Sakata et al. noted that the surgical removal of solitary implantation metastatic nodules was followed by a survival longer than one year in about 80% of patients [5]. In a study that examined four patients with this complication, patients' survival ranged from 8 to 18 months with post-excision median survival of 10.5 months [9].

PTBD represents an invasive procedure associated with severe complications and significant mortality. Literature review shows that per- and post-PTBD 7-day mortality rate ranges from 2.98–5.2%, while 30-day mortality rate ranges from 23.1 to 33% [10, 11, 12]. Lauterio et al reviewed results of six studies examining management of the patients with metastatic perihilar cholangiocarcinoma who underwent the PTBD procedure. In these studies, the reported mortality ranged between 0 and 12% [13-15]. The most commonly identified risk factors associated with increased postoperative complications were biliary tract manipulation and subsequent development of cholangitis and sepsis [16, 17].

The 2 types of interventions that are sometimes used as an alternative to PTBD in treatment of malignant biliary obstruction are endoscopic retrograde cholangiopancreatography (ERCP) and endoscopic ultrasound-guided biliary drainage (EUS-BD). A meta-analysis of randomized trials and observational studies that compared technical and clinical success rates and rates of complications for ERCP and EUS-BD, showed they are comparable to PTBD. In addition, in order for EUS-BD to be successfully performed, biliary ducts should be dilated, which is also noted requirement for successful PTBD. In ERCP and EUS-BD, successful biliary drainage is achieved in about 94%, and resolution of jaundice in 91- 94% of cases, with no significant difference in procedure duration or the incidence of overall post-procedural complications (overall complications ERCP vs. EUS-BD = 22.3% vs. 15.2%) [18–21]. Reports confirmed no significant difference in re-interventions because of jaundice in ERCP vs. EUS-BD [19, 20]. However, while the EUS-BP was not associated with

post-procedural pancreatitis, after ERCP 9.5% of patients developed this severe complication [19].

In conclusion, catheter tract implantation metastasis is not a rare complication following PTBD for malignant biliary obstruction. It is associated with generally poor prognosis. In select group of patients with a solitary node, radical surgery with excision of the catheter tract and hepatectomy allows survival longer than one year.

Conflict of interest: None declared.

Paper accepted

REFERENCES

1. Sellier F, Borie E, Sibertin Blanc C, Griffiths K, Dahan L, Giovannini M, et al. Clinical outcome after biliary drainage for metastatic colorectal cancer: Survival analysis and prognostic factors. *Dig Liver Dis.* 2018;50:189-94. PMID: 29054396 DOI: 10.1016/j.dld.2017.09.121
2. Kastelijn JB, Van der Loos M, Welsing P, Dhondt E, Koopman M, Moons L et al. Clinical outcomes of biliary drainage of malignant biliary obstruction due to colorectal cancer metastases: A systematic review. *Eur J Inter Med.* 2021 Jun;88:81-8 PMID: 33931267 DOI: 10.1016/j.ejim.2021.03.032
3. Yang G, Xiong Y, Sun JI, Tangi T, LI W, Wang G, Li J. Effect of different preoperative biliary drainage methods for resected malignant obstruction jaundice on the incidence rate of implantation metastasis: A meta analysis. *Oncology Letters.* 2020 September; 20(3):2217-24 DOI: 10.3892/ol.2020.11767
4. Mocan T, Horhat A, Mois E, Graur F, Tefas C, Craciun R, et al. Endoscopic or percutaneous biliary drainage in hilar cholangiocarcinoma: When and how? *World J Gastrointest Oncol.* 2021 Dec 15;13(12): 2050–63 PMID: 35070041 DOI: 10.4251/wjgo.v13.i12.2050
5. Sakata J, Shirai Y, Wakai T, Nomura T, Sakata E, Hatekeyama K. Catheter tract implantation metastases associated with percutaneous biliary drainage for extrahepatic cholangiocarcinoma. *World J Gastroenterol.* 2005;11:7024-7 PMID: 16437610 DOI: 10.3748/wjg.v11.i44.7024
6. Talukder SH, Behera A, Tandup CH, Mitra S. Isolated implant metastasis in chest wall due to seeding of transpercutaneously placed PTBD catheter tract in a case of hilar cholangiocarcinoma. *BMJ Case Rep.* 2017 Apr 18;2017:bcr2017219864. PMID: 28420643 DOI: 10.1136/bcr-2017-219864
7. Oleaga JA, Ring EJ, Freiman DB, McLean GK, Rosen RJ. Extension of neoplasm along the tract of a transhepatic tube. *AJR AM J Roentgenol.* 1980;135:841-2 PMID: 6255780 DOI: 10.2214/ajr.135.4.841
8. Liu M, Liu BL, Liu B, Guo L, Wang Q, Song Y, et al. Cutaneous metastasis of cholangiocarcinoma. *World J Gastroenterol.* 2015 Mar 14;21(10):3066-71 PMID: 25780307 DOI: 10.3748/wjg.v21.i10.3066
9. Rosich-Medina A, Liau SS, Jah A. Cutaneous metastases from cholangiocarcinoma following percutaneous transhepatic biliary drainage: case report and literature review: *Int J Surg Case Report.* 2010;1:33-6 DOI: 10.1016/j.ijscr.2010.08.002 PMID: PMC609955
10. Vandenaabeele LAM, Dhondt E, Geboes KP, Defreyne L. Percutaneous stenting in malignant biliary obstruction caused by metastatic disease: clinical outcome and prediction of survival according to tumor type and further therapeutic options. *Acta Gastroenterol Belg.* 2017;80(2):249-55 PMID: 29560690
11. Garcarek J, Kurcz J, Guzinski M, Janzak D, Sasiadek M. Ten Years Single Center Experience in Percutaneous Transhepatic Decompression of Biliary Tree in Patients with Malignant Obstructive Jaundice. *Advan Clin Exp Med.* 2012;21(5):621-32 PMID: 23356199
12. Rees J, Mytton J, Evison F, Mangat K.S, Patel P, Trudgill N. The outcome of biliary drainage by percutaneous transhepatic cholangiography for the palliation of malignant biliary obstruction in England between 2001 and 2014: a retrospective cohort study. *BMJ Open.* 2020 Jan 23;10(1):e 033576. PMID: 31980509 DOI: 10.1136/bmjopen-2019-033576
13. Lauterio A, De Carlis R, Centonze L, Buscemi V, Incerbone N, Vella I. et al. Current Surgical Management of Peri-Hilar and Intra-Hepatic Cholangiocarcinoma. *Cancers.* 2021 Jul 21;13(15):3657 PMID: 34359560 DOI: 10.3390/cancers13153657
14. Kennedy TJ, Zopp A, Qin Y, Zhao B, Guo P, Liu F. et al. Role of Preoperative Biliary Drainage of Liver Remnant prior to Extended Liver Resection for Hilar Cholangiocarcinoma. *HPB.* 2009 Aug;11(5):445-51 PMID: 19768150 DOI: 10.1111/j.1477-2574.2009.00090.x
15. Ribero D, Zimmiti G, Aloia T.A, Shindoh J, Forchino F, Amisano M. et al. Preoperative Cholangitis and Future Liver Remnant Volume Determine the Risk of Liver Failure in Patients Undergoing Resection for Hilar Cholangiocarcinoma. *J Am Coll Surg.* 2016;223:87-97 PMID: 27049784 DOI: 10.1016/j.jamcollsurg.2016.01.060
16. Iacono C, Ruzzenente A, Campagnaro T, Bortolasi L, Valdegamberi A, Guglielmi A. Role of Preoperative Biliary Drainage in Jaundiced Patients Who Are Candidates for Pancreatoduodenectomy or Hepatic Resection: Highlights and Drawbacks. *Ann Surg.* 2013;257: 191–204 PMID: 23013805 DOI: 10.1097/SLA.0b013e31826f4b0e
17. Ramanathan R, Borrebach J, Tohme S, Tsung A. Preoperative Biliary Drainage Is Associated with Increased Complications After Liver Resection for Proximal Cholangiocarcinoma. *J Gastrointest Surg.* 2018;22:1950–7. PMID: 29980975 DOI: 10.1007/s11605-018-3861-3
18. Kongkam P, Orprayoon T, Boonmee CH, Sodarat P, Seabmuangsai O, Wachiramatharuch CH et al. ERCP plus endoscopic ultrasound-guided biliary drainage versus percutaneous transhepatic biliary drainage for malignant hilar biliary obstruction: a multicenter observational open-label study. *Endoscopy.* 2021 Jan;53(1):55-62 PMID:32515005 DOI: 10.1055/a-1195-8197

19. Kakked G, Salameh H, Cheesman A, Kumta N, Nagula S, DiMaio Ch. Primary EUS guided biliary drainage versus ERCP drainage for the management of malignant biliary obstruction: A systematic review and meta analysis. *Endosc Ultrasound*. 2020;9:298-307 PMID: 32655080 DOI: 10.4103/eus.eus_10_20
20. Jin Z, Wei Y, Lin H, Yang J, Jin H, Shen S, et al. Endoscopic ultrasound-guided versus endoscopic retrograde cholangiopancreatography-guided biliary drainage for primary treatment of distal malignant biliary obstruction: A systematic review and meta-analysis. *Dig Endosc*. 2020;32:16-26 PMID: 31165527 DOI: 10.1111/den.13456
21. Bang JY, Hawes R, Varadarajulu Sh. Endoscopic biliary drainage for malignant distal biliary obstruction: Which is better-endoscopic retrograde cholangiopancreatography or endoscopic ultrasound? *Digestive Endoscopy*. 2022;34:317-24 PMID: 34748675, DOI: 10.1111/den.14186

Paper accepted

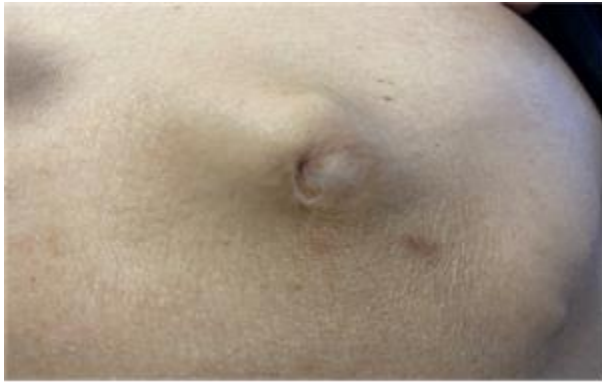

Figure 1. Clinical presentation of implantation metastasis- subcutaneous nodule in the anterior chest wall in the area of scar after percutaneous transhepatic biliary drainage procedure

Paper accepted

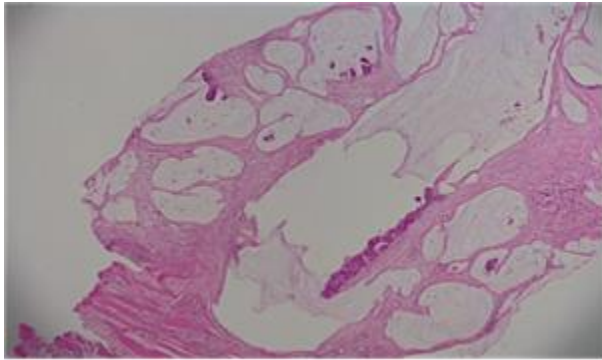


Figure 2. Core biopsy specimen with diagnosis of low-grade mucinous adenocarcinoma.

H&E staining, 100 × magnification

Paper accepted

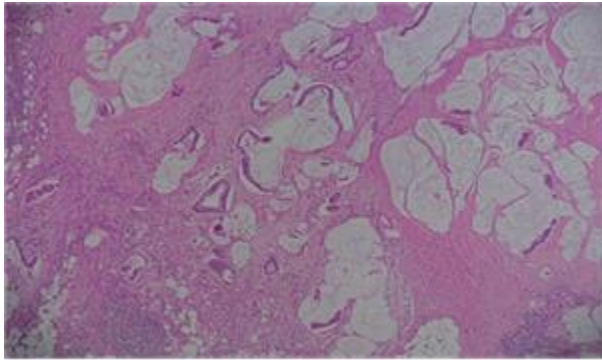


Figure 3. An original sample taken from the right hemicolectomy showing same histologic features of tumor as in the core biopsy; H&E staining, 100 × magnification

Paper accepted