



**СРПСКИ АРХИВ**  
ЗА ЦЕЛОКУПНО ЛЕКАРСТВО  
**SERBIAN ARCHIVES**  
OF MEDICINE

Address: 1 Kraljice Natalije Street, Belgrade 11000, Serbia

+381 11 4092 776, Fax: +381 11 3348 653

E-mail: [office@srpskiarhiv.rs](mailto:office@srpskiarhiv.rs), Web address: [www.srpskiarhiv.rs](http://www.srpskiarhiv.rs)

Paper Accepted\*

ISSN Online 2406-0895

**Case Report / Приказ болесника**

Simonida Bobić<sup>1,\*</sup>, Bojana Poparić-Banđur<sup>1</sup>, Milana Matović<sup>1</sup>, Lidija Pavlović<sup>1</sup>,  
Marijana Milović-Kovačević<sup>1,2</sup>

**Ribociclib-induced phototoxicity – the era of new drugs and new  
toxicities**

РИБОЦИКЛИБОМ ИНДУКОВАНА ФОТОТОКСИЧНОСТ – ЕРА НОВИХ ЛЕКОВА И НОВИХ  
ТОКСИЧНОСТИ

<sup>1</sup>Institute for Oncology and Radiology of Serbia, Belgrade, Serbia;

<sup>2</sup>University of Belgrade, Faculty of Medicine, Belgrade, Serbia

Received: September 25, 2024

Revised: December 8, 2024

Accepted: December 9, 2024

Online First: December 10, 2024

DOI: <https://doi.org/10.2298/SARH240925092B>

\* **Accepted papers** are articles in press that have gone through due peer review process and have been accepted for publication by the Editorial Board of the *Serbian Archives of Medicine*. They have not yet been copy-edited and/or formatted in the publication house style, and the text may be changed before the final publication.

Although accepted papers do not yet have all the accompanying bibliographic details available, they can already be cited using the year of online publication and the DOI, as follows: the author's last name and initial of the first name, article title, journal title, online first publication month and year, and the DOI; e.g.: Petrović P, Jovanović J. The title of the article. *Srp Arh Celok Lek*. Online First, February 2017.

When the final article is assigned to volumes/issues of the journal, the Article in Press version will be removed and the final version will appear in the associated published volumes/issues of the journal. The date the article was made available online first will be carried over.

\* **Correspondence to:**

Simonida BOBIĆ

Institute for Oncology and Radiology of Serbia, Pasterova 14, 11000 Belgrade, Serbia

Email: [simonidapupovac@yahoo.com](mailto:simonidapupovac@yahoo.com)

## Ribociclib-induced phototoxicity – the era of new drugs and new toxicities

### Рибоциклибом индукована фототоксичност – ера нових лекова и нових ТОКСИЧНОСТИ

#### SUMMARY

**Introduction** Ribociclib belongs to the family of cyclin-dependent kinases 4/6 inhibitors and it has been approved in 2017 for the treatment of patients with hormone receptor-positive (ER<sup>+</sup>) and human epidermal growth factor receptor 2-negative (HER2<sup>-</sup>) advanced breast cancer. As a drug that has been used for treatment of breast cancer for only few years its rare side effects are described through different case reports. Skin photosensitivity represents a range of dermatological conditions that are caused or exacerbated by sunlight exposure. Drug-induced photosensitivity can be seen in patients treated with all kinds of oncology treatments, including chemotherapeutic agents, targeted anticancer therapies and immune checkpoint inhibitors.

**Case Outline** We present a case of a patient with metastatic hormone receptor positive and HER2 negative metastatic breast cancer who developed phototoxic skin changes during the treatment with ribociclib/letrozole. During the treatment she developed mild redness of the skin in a strict photosensitive distribution and rash changed to erythematous confluent plaques on the neck and upper part of the chest, face and forearms. After treatment cessation the skin changes did not reappear.

**Conclusion** As the observed cutaneous adverse effect subsided after the treatment cessation and did not reappear after the initiation of palbociclib/letrozole treatment, it can be concluded that the adverse effects were the consequence of ribociclib action. Management of cutaneous adverse effects is different depending mostly of grade of cutaneous adverse effect and its severity.

**Keywords:** ribociclib; breast cancer; phototoxicity

#### САЖЕТАК

**Увод** Рибоциклиб припада породици инхибитора циклин зависних киназа 4/6 и одобрен је 2017. године за лечење пацијената са узнапредовалим карциномом дојке позитивним на хормонски рецептор (ER<sup>+</sup>) и хуманим епидермалним фактором раста 2 негативним (ХЕР2<sup>-</sup>). Пошто се рибоциклиб за лечење рака дојке користи само неколико последњих година, његови ретки нежељени ефекти су описани кроз различите приказе случајева. Кожна фотосензитивност обухвата широк спектар дерматолошких стања узрокованих или погоршаних током излагања сунцу. Фотосензитивност изазвана лековима може да се испољи код онколошких пацијената који се лече свим модалитетима системске терапије: хемиотерапеутицима, циљаном терапијом и имунолошком терапијом.

**Приказ болесника** Приказујемо случај пацијенткиње са метастатским хормонски рецептор позитивним ХЕР2 негативним карциномом дојке код које се јавила кожна фототоксичност током примене терапије рибоциклиб/летрозол. Током третмана појавило се благо црвенило коже у строго фотосензитивној дистрибуцији и осип се променио у еритематозне спојене плакове на врату и горњем делу грудног коша, лица и подлактица. После прекида примене лека промене на кожи се нису поново појавиле.

**Закључак** Пошто се испољено кожно нежељено дејство повукло након прекида терапије и није се поново јављало након примене терапије палбоциклиб/летрозол, може се закључити да је нежељено дејство последица примене рибоциклиба. Лечење кожних нежељених ефеката је различито у зависности углавном од степена кожних нежељених ефеката и његове тежине.

**Кључне речи:** рибоциклиб; карцином дојке; фототоксичност

## INTRODUCTION

Ribociclib belongs to the family of cyclin-dependent kinases 4/6 inhibitors (along with palbociclib and abemaciclib). It is administered orally and it operates by preventing oncogene retinoblastoma phosphorylation, thus blocking cell division [1]. Ribociclib has been approved

in 2017 for the treatment of patients with hormone receptor-positive (ER<sup>+</sup>) and human epidermal growth factor receptor 2-negative (HER2<sup>-</sup>) advanced breast cancer. The approval of ribociclib was supported by Phase III MONALEESA-2 study (Mammary Oncology Assessment of LEE011's Efficacy and Safety - NCT01958021), where its benefits both in progression-free survival and in overall survival were demonstrated [2]. More specifically, when administered together with the aromatase inhibitor letrozole, ribociclib achieved a 30% or greater reduction in tumor size in more than 53% of patients with measurable disease in comparison to letrozole monotherapy [2].

The most common adverse reactions of ribociclib, observed in 20% or more of patients, are neutropenia, nausea, fatigue, diarrhea, leukopenia, alopecia, vomiting, constipation, headache, and back pain. Also, hypersensitivity of the patient to the active substance or to peanuts and soy is a contraindication for the drug use [2]. Ribociclib may provoke several cutaneous adverse effects including rashes, vitiligo and bullous dermatitis [3]. Also, one case erythema dyschromicum perstans was reported after the use of ribociclib [4].

As an adverse effect, skin photosensitivity can be observed in patients treated with all kinds of oncology treatments, including chemotherapeutic agents, targeted anticancer therapies and immune checkpoint inhibitors [5]. Recently, one case of ribociclib-induced phototoxicity was documented in a woman that received ribociclib (600 mg) for seven months. It initially manifested as dyschromia over sun-exposed forearms and neck and subsequently as bullae formation [6]. Since the varieties of ribociclib-provoked skin photosensitivity have been rarely documented, we present this case report to add to the list of possible strong adverse effects that include development of rash and erythematous confluent plaques on sun-exposed body parts.

## CASE REPORT

The initial treatment of the left breast cancer started one and a half year ago, in February 2022, when partial resection of the left breast was done and the diagnosis of infiltrating ductal cancer (hormone receptor positive, HER2 negative) was confirmed. Postoperative radiotherapy was next performed and patient was on adjuvant hormonal therapy, oral tamoxifen, from April 2022 till January 2023. At this point, CT scan revealed multiple liver metastases. The treatment with letrozole and ribociclib has started from March of 2023. Laboratory findings were all in normal ranges. Ribociclib in a dose of 600 mg was applied orally once a day and letrozole of 2.5 mg, once a day.

The patient exhibited an atopic constitution and because of the already established allergy to one or several types of pollen she received antihistaminic treatment during the 1<sup>st</sup> cycle of ribociclib-letrozole (21 days). However, the patient stopped antihistaminic treatment around D15. During the break from ribociclib (that lasts for 7 days, from D21-D28), she developed mild redness of the skin in a strict photosensitive distribution (face, neck and upper part of the chest) on D26. She started with 2<sup>nd</sup> cycle of ribociclib/letrozole from D28 and on D2 (during 2<sup>nd</sup> cycle) rash changed to erythematous confluent plaques on the neck and upper part of the chest (Figure 1), face (Figure 2) and rash on the forearms (Figure 3). The treatment with ribociclib/letrozole was discontinued.

After all skin changes subsided and completely disappeared, in May of 2023 (around 30 days from the last treatment), the treatment continued with a different CDK4/6 drug – palbociclib, along with letrozol, and the further treatment was without complications.

The authors declare that the article was written according to ethical standards of the Serbian Archives of Medicine as well as ethical standards of institutions for each author involved.

The authors certify that they have obtained all appropriate patient consent forms. In the form, the patient has given her consent for her images and other clinical information to be reported in the journal.

## DISCUSSION

Drug-induced photosensitivity can be classified as either phototoxic or photoallergic reactions based on the underlying pathophysiological mechanism [5, 7]. Phototoxicity is a nonimmune-mediated response to cytotoxic damage caused by UV-induced generation of reactive oxygen species [5]. It is typically manifested as an exaggerated sunburn response with clearly demarcated erythema and edema occurring on sun-exposed skin. The main feature of phototoxicity is that it starts rapidly, within hours of exposure to the agent and UV radiation, and progressively develops to localized or more diffuse hyperpigmentation [5, 7]. The personalization of therapies in breast cancer has favored the introduction of new molecular-targeted therapies into clinical practice. Among them, cyclin-dependent kinases 4 and 6 (CDK4/6) inhibitors have acquired increasing importance, with the approval in recent years of palbociclib, ribociclib, and abemaciclib in combination with endocrine therapy (ET) [8]. MONALEESA-2 is a phase III randomized, double-blind, placebo-controlled study of ribociclib combined with letrozole for the treatment of postmenopausal women with HR+/HER2- advanced breast cancer who received no prior therapy for advanced disease [9]. In this study, adverse events of any grade that occurred in at least 35% of the patients in either group were neutropenia, nausea, infections, fatigue, and diarrhea [10]. MONALEESA-3 is a phase III randomized, double-blind, placebo-controlled study of ribociclib in combination with fulvestrant for treating postmenopausal women and men with HR+/HER2- advanced breast cancer who have received no or only one line of ET for advanced breast cancer [11], and in

this study neutropenia, nausea, and tiredness were the most prevalent of all-grade adverse events observed in 30% of patients [12].

Ribociclib-induced phototoxicity was already documented as dyschromia over sun-exposed forearms and neck and subsequent bullae formation [6]. On the other hand, the cutaneous manifestations observed in this case study (rash and erythematous confluent plaques) are likely photoallergic as the rash occurred after a few days of starting the drug and was gradually progressive. This is in line with the literature evidence as the most common clinical presentation of photoallergy, eczematous eruption, appears usually 24–72 h after sunlight exposure and treatment with causative agent. Symptoms tend to worsen and peak 48–72 h after onset and mostly resolves after removal of the causative agent and sun avoidance [5, 7].

Photoallergic drug reactions are mediated by a T cell-mediated immune mechanism, resulting in a delayed type IV hypersensitivity response, so they manifest only in pre-sensitized individuals and are much more rare than phototoxic drug reactions [5, 7]. Having in mind the atopic constitution of the patient, it is reasonable to assume that the observed cutaneous changes can be driven by the exaggerated immune reaction.

In general, CDK4/6 inhibitors can provoke rash as a side effect (data obtained from meta-analysis evaluating toxicity end points), but further details on the type of rash were not available [13]. Specifically, for ribociclib, conclusions drawn from the phase I trial performed to determine dose-limiting toxicity and maximum tolerated dose of ribociclib (performed in 21 patients), suggest that the rash is a common side effect as it presented in 52% of patients along with oral mucositis. Again, further details on rash type were not available [14].

In 2024 a retrospective cohort study of all patients with HR+/HER2– ABC treated with ribociclib at Humanitas Cancer Center between June 2017 and December 2022 was conducted and 14.3% of all patients experienced treatment-related cutaneous adverse events. The most

frequent CAEs were eczematous dermatitis (53.8%) and maculo-papular reaction (15.4%) [15]. Another study compared adverse events associated with CDK4/6 inhibitors based on FDA's adverse event reporting system and reported that different skin toxicities were observed in all three CDK4/6 inhibitors used [16].

The patient presented in this case report received a combination therapy (ribociclib/letrozole), and therefore, the possibility that photoallergy was initiated by letrozole action has to be taken into consideration. Letrozole is an aromatase inhibitor and is known to have cutaneous side effects. In phase 2 randomized study in postmenopausal women with breast cancer, receiving letrozole, skin rash was noted as a side effect in 23 out of 125 (18.4%) patients. The type of skin lesions was described as exfoliative, nodular, follicular, generalized, maculo-papular, and others [17]. However, no such cutaneous effects were observed after the treatment of the same patient with palbociclib/letrozole suggesting that the observed side effects were provoked by the action of ribociclib.

Establishing a diagnosis of photosensitive reactions induced by anticancer agents can be challenging and requires close evaluation of the clinical presentation and medication history of the patient. Also, these patients are often treated in combination with a range of other therapies that may be potentially involved in the occurrence of photosensitive reactions, and it can be very challenging to identify the most likely causative agent [7].

The involvement of ribociclib in the observed cutaneous adverse effect is straightforward as the symptoms subsided after the treatment cessation, and they did not appear again when the treatment option was changed. Letrozole was a part of both treatment options, and therefore the impact of this drug on the cutaneous adverse effects can be excluded. Although photoallergic dermatitis is a rare side effect of ribociclib, strict photoprotection should be advised to these patients while prescribing this medication. As different dermatologic adverse

events can lead to dose modifications and interruption or discontinuation of anticancer treatments in severe cases, the prophylactic behavior of the patient is strongly encouraged. In cases where preventative measures fail and photosensitivity occurs, symptomatic treatment with topical or systemic corticosteroids may help to reduce the impact of the photosensitive eruptions on patient quality of life and allow potentially life-saving cancer therapies to be continued without dose modification.

Recently, Abemaciclib [18] and Ribociclib [19] demonstrated to significantly improve the invasive disease free survival in intermediate and high risk populations of early HR+/HER2- breast cancer patients so the treatment with CDK4/6 inhibitors is being implemented in treatment of breast cancer patients with early breast cancer, as well as metastatic breast cancer, so the understanding and management of all side effects is crucial.

**Conflict of interest:** None declared.



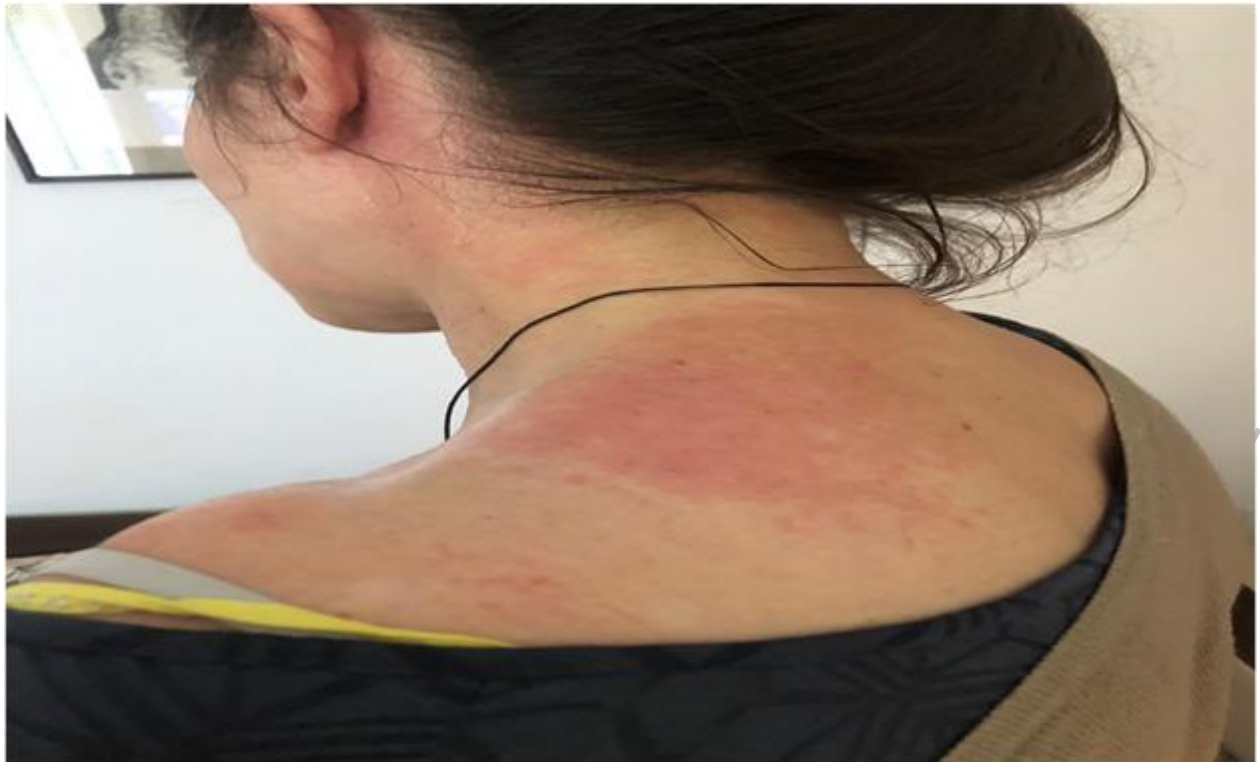## REFERENCES

1. Kim S, Tiedt R, Loo A, Horn T, Delach S, Kovats S, et al. The potent and selective cyclin-dependent kinases 4 and 6 inhibitor ribociclib (LEE011) is a versatile combination partner in preclinical cancer models. *Oncotarget*. 2018;9(81):35226–40. [DOI: 10.18632/oncotarget.26215] [PMID: 30443290]
2. Shah A, Bloomquist E, Tang S, Fu W, Bi Y, Liu Q, et al. FDA Approval: Ribociclib for the Treatment of Postmenopausal Women with Hormone Receptor-Positive, HER2-Negative Advanced or Metastatic Breast Cancer. *Clin Cancer Res*. 2018;24(13):2999–3004. [DOI: 10.1158/1078-0432.CCR-17-2369] [PMID: 29437768]
3. Raschi E, Fusaroli M, La Placa M, Ardizzoni A, Zamagni C, Poluzzi E, et al. Skin Toxicities with Cyclin-Dependent Kinase 4/6 Inhibitors in Breast Cancer: Signals from Disproportionality Analysis of the FDA Adverse Event Reporting System. *Am J Clin Dermatol*. 2022;23(2):247–55. [DOI: 10.1007/s40257-021-00645-0] [PMID: 34699032]
4. Mariano M, Donati P, Cameli N, Pigliacelli F, Morrone A, Cristaudo A. Ribociclib-Induced Erythema Dyschromicum Perstans (Ashy Dermatitis)-Like Pigmentation in a Metastatic Breast Cancer Patient. *J Breast Cancer*. 2021;24(1):117–21. [DOI: 10.4048/jbc.2021.24.e1] [PMID: 33634626]
5. Sibaud V. Anticancer treatments and photosensitivity. *J Eur Acad Dermatol Venereol*. 2022 Jun;36 Suppl 6(Suppl 6):51–8. [DOI: 10.1111/jdv.18200] [PMID: 35738806]
6. Jhan JY, Wang WE, Chu SC, Cheng CH, Chang CH. Case Report: Ribociclib-induced phototoxicity presented as dyschromia with subsequent bullae formation. *Front Oncol*. 2023;13:1184738. [DOI: 10.3389/fonc.2023.1184738] [PMID: 37692847]
7. Hofmann GA, Weber B. Drug-induced photosensitivity: culprit drugs, potential mechanisms and clinical consequences. *J Dtsch Dermatol Ges*. 2021;19(1):19–29. [DOI: 10.1111/ddg.14314] [PMID: 33491908]
8. Vieira C, Piperis MN, Sagkriotis A, Cottu P. Systemic treatment for hormone receptor-positive/HER2-negative advanced/metastatic breast cancer: A review of European real-world evidence studies. *Crit Rev Oncol Hematol*. 2022;180:103866. [DOI: 10.1016/j.critrevonc.2022.103866] [PMID: 36336168]
9. Novartis Pharmaceuticals. A Randomized Double-Blind, Placebo-Controlled Study of LEE011 in Combination With Letrozole for the Treatment of Postmenopausal Women With Hormone Receptor Positive, HER2 Negative, Advanced Breast Cancer Who Received no Prior Therapy for Advanced Disease. 2023. Available online: <https://classic.clinicaltrials.gov/ct2/show/NCT02941926>
10. Hortobagyi GN, Stemmer SM, Burris HA, Yap YS, Sonke GS, Paluch-Shimon S, et al. Ribociclib as First-Line Therapy for HR-Positive, Advanced Breast Cancer. *N Engl J Med*. 2016;375(18):1738–48. [DOI: 10.1056/NEJMoa1609709]. Erratum in: *N Engl J Med*. 2018;379(26):2582. [DOI: 10.1056/NEJMc180043] [PMID: 27717303]
11. Novartis Pharmaceuticals. A Randomized Double-Blind, Placebo-Controlled Study of Ribociclib in Combination With Fulvestrant for the Treatment of Men and Postmenopausal Women With Hormone Receptor Positive, HER2-Negative, Advanced Breast Cancer Who Have Received no or Only One Line of Prior Endocrine Treatment. 2023. Available online: <https://classic.clinicaltrials.gov/ct2/show/NCT02422615>
12. Slamon DJ, Neven P, Chia S, Fasching PA, De Laurentiis M, Im SA, et al. Phase III Randomized Study of Ribociclib and Fulvestrant in Hormone Receptor-Positive, Human Epidermal Growth Factor Receptor 2-Negative Advanced Breast Cancer: MONALEESA-3. *J Clin Oncol*. 2018;36(24):2465–72. [DOI: 10.1200/JCO.2018.78.9909] [PMID: 29860922]
13. Costa R, Costa RB, Talamantes SM, Helenowski I, Peterson J, Kaplan J, et al. Meta-analysis of selected toxicity endpoints of CDK4/6 inhibitors: Palbociclib and ribociclib. *Breast*. 2017;35:1–7. [DOI: 10.1016/j.breast.2017.05.016] [PMID: 28618307]
14. Seront E, Schmitz S, Papier M, van Maanen A, Henry S, Lonchay C, et al. Phase 1 Study Evaluating the Association of the Cyclin-Dependent Kinase 4/6 Inhibitor Ribociclib and Cetuximab in Recurrent/Metastatic p16-Negative Squamous Cell Carcinoma of the Head and Neck. *Front Oncol*. 2019;9:155. [DOI: 10.3389/fonc.2019.00155] [PMID: 30941307]
15. Borroni RG, Bartolini M, Gaudio M, Jacobs F, Benvenuti C, Gerosa R et al. Ribociclib-Induced Cutaneous Adverse Events in Metastatic HR+/HER2- Breast Cancer: Incidence, Multidisciplinary Management, and Prognostic Implication. *Oncologist*. 2024;29(6):484–92. [DOI: 10.1093/oncolo/oyae004] [PMID: 38242689]
16. Lin W, Zeng Y, Weng L, Yang J, Zhuang W. Comparative analysis of adverse events associated with CDK4/6 inhibitors based on FDA's adverse event reporting system: a case control pharmacovigilance study. *BMC Pharmacol Toxicol*. 2024;25(1):47. [DOI: 10.1186/s40360-024-00770-6] [PMID: 39123221]
17. Mayer IA, Prat A, Egle D, Blau S, Fidalgo JAP, Gnani M, et al. A Phase II Randomized Study of Neoadjuvant Letrozole Plus Alpelisib for Hormone Receptor-Positive, Human Epidermal Growth Factor Receptor 2-Negative Breast Cancer (NEO-ORB). *Clin Cancer Res*. 2019;25(10):2975–87. [DOI: 10.1158/1078-0432.CCR-18-3160] [PMID: 30723140]
18. Johnston SRD, Toi M, O'Shaughnessy J, Rastogi P, Campone M, Neven P, et al. Abemaciclib plus endocrine therapy for hormone receptor-positive, HER2-negative, node-positive, high-risk early breast cancer

(monarchE): results from a preplanned interim analysis of a randomised, open-label, phase 3 trial. *Lancet Oncol*. 2023;24(1):77–90. [DOI: 10.1016/S1470-2045(22)00694-5] [PMID: 36493792]

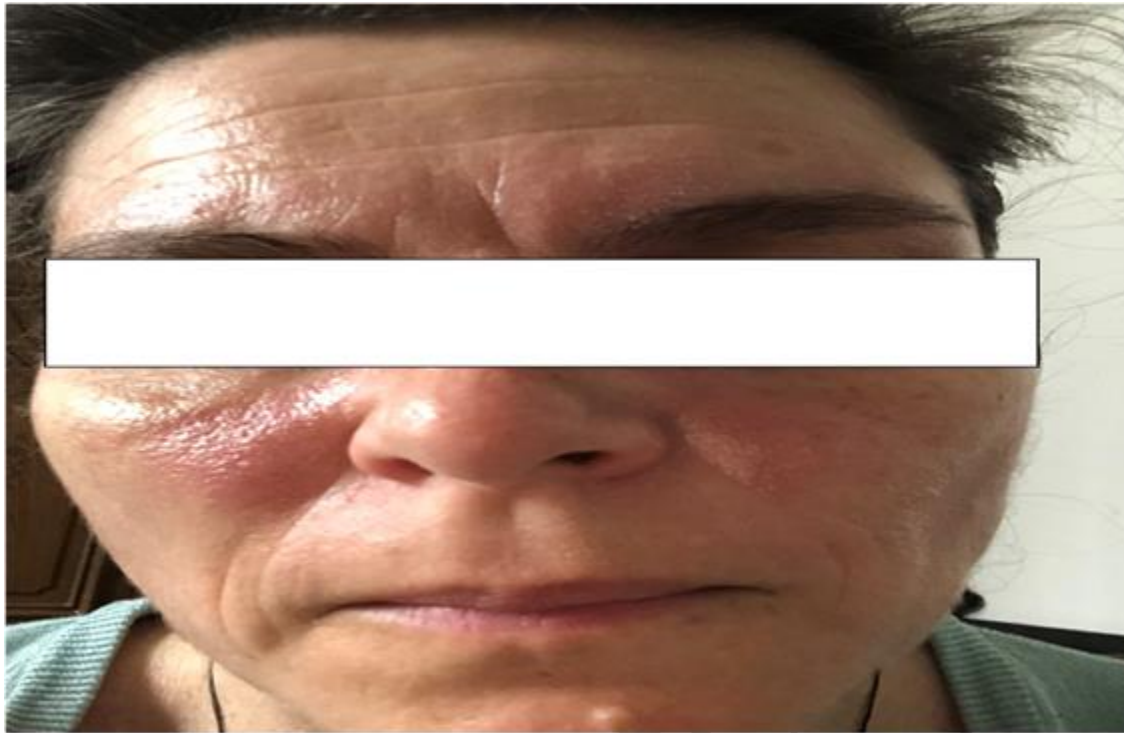
19. Slamon D. Ribociclib and endocrine therapy as adjuvant treatment in patients with HR+/HER2– early breast cancer: Primary results from the phase III NATALEE trial. *J Clin Oncol* (2023), LBA500. [DOI: 10.1200/JCO.2023.41.17\_suppl.LBA500]

Paper accepted

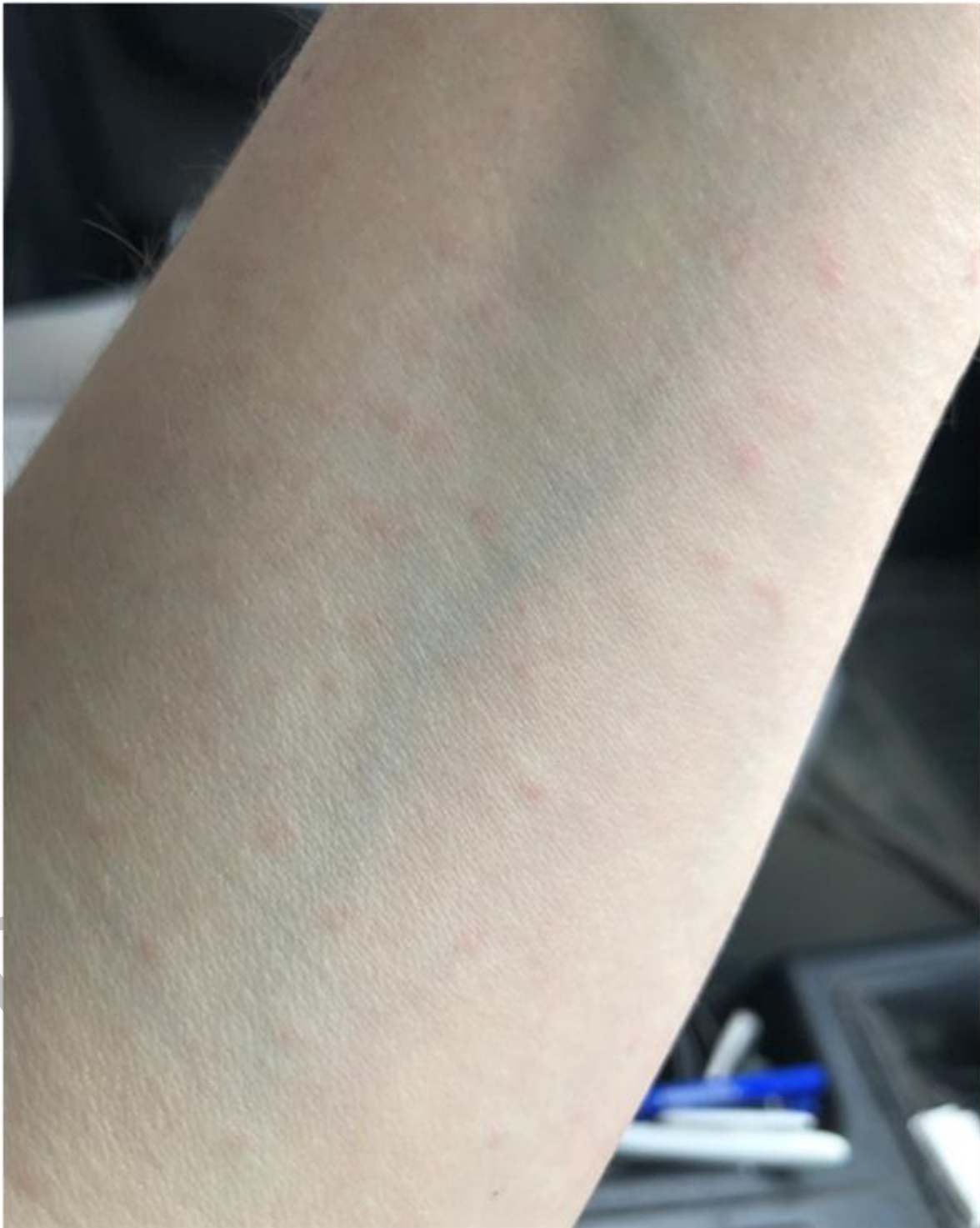

**Figure 1.** Erythematous confluent plaques on the neck and upper part of the chest

Paper accepted



**Figure 2.** Erythematous confluent plaques on the face



**Figure 3.** The rash on the forearm