



СРПСКИ АРХИВ
ЗА ЦЕЛОКУПНО ЛЕКАРСТВО
SERBIAN ARCHIVES
OF MEDICINE

Address: 1 Kraljice Natalije Street, Belgrade 11000, Serbia

+381 11 4092 776, Fax: +381 11 3348 653

E-mail: office@srpskiarhiv.rs, Web address: www.srpskiarhiv.rs

Paper Accepted*

ISSN Online 2406-0895

Case report / Приказ болесника

Goran Radunović¹, Tanja Miličić², Martina Bosić³, Ivan Jeremić⁴, Draško Dačić⁵,
Slavica Pavlov-Dolijanović^{1,*}

Corticosteroid treatment and growth of angioliomas in patient with two rare diseases: Pfeifer-Weber-Christian disease and benign multiple subcutaneous angioliomas

Лечење кортикостероидима и пораст ангиолиптома код болеснице са две ретке болести: Фајфер–Вебер–Кристијанова болест и доброћудни вишеструки неинфилтрирајући ангиолиптоми

¹University of Belgrade, Faculty of Medicine, Institute of Rheumatology, Belgrade, Serbia;

²University of Belgrade, Faculty of Medicine, University Clinical Center of Serbia, Clinic for Endocrinology, Diabetes, and Metabolic Diseases, Belgrade, Serbia;

³University of Belgrade, Faculty of Medicine, Institute of Pathology, Belgrade, Serbia;

⁴Institute of Rheumatology, Belgrade, Serbia;

⁵General Hospital, Požarevac, Serbia

Received: January 14, 2020

Revised: February 18, 2022

Accepted: March 18, 2023

Online First: March 22, 2023

DOI: <https://doi.org/10.2298/SARH200114033R>

***Accepted papers** are articles in press that have gone through due peer review process and have been accepted for publication by the Editorial Board of the *Serbian Archives of Medicine*. They have not yet been copy-edited and/or formatted in the publication house style, and the text may be changed before the final publication.

Although accepted papers do not yet have all the accompanying bibliographic details available, they can already be cited using the year of online publication and the DOI, as follows: the author's last name and initial of the first name, article title, journal title, online first publication month and year, and the DOI; e.g.: Petrović P, Jovanović J. The title of the article. *Srp Arh Celok Lek*. Online First, February 2017.

When the final article is assigned to volumes/issues of the journal, the Article in Press version will be removed and the final version will appear in the associated published volumes/issues of the journal. The date the article was made available online first will be carried over.

***Correspondence to:**

Slavica PAVLOV-DOLIJANOVIĆ

University of Belgrade, Faculty of Medicine, Institute of Rheumatology, Resavska 69, 11000 Belgrade, Serbia

E-mail: slavicapavlovdolijanovic@gmail.com

Corticosteroid treatment and growth of angioliomas in patient with two rare diseases: Pfeifer-Weber-Christian disease and benign multiple subcutaneous angioliomas

Лечење кортикостероидима и пораст ангиолиптома код болеснице са две ретке болести: Фајфер–Вебер–Кристијанова болест и доброћудни вишеструки неинфилтрирајући ангиолиптоми

SUMMARY

Introduction Pfeifer-Weber-Christian disease (PWCD) is a rare inflammatory disorder of the subcutaneous fatty tissue. Angiolipoma, is a benign adipocytic soft tissue tumor composed of mature adipose tissue and small vascular proliferations. Treatment with corticosteroids could lead to proliferation of fat tissue but the stimulation of angiolipoma growth during corticosteroid therapy is extremely rare.

Case outline We describe a case of a 46-year-old female patient with histopathological confirmation two rare diseases PWCD and benign multiple subcutaneous non-infiltrative angiolipomas. Angiolipomas were treated conservatively. Treatment for PWCD was prednisone 20 mg/day. Due to poor control of PWCD and rapid angiolipomas growth on forearms corticosteroids were discontinued after two months of use. Administration of oral Cyclosporine A led to a rapid remission of the PWCD, and with no new growth of angiolipomas.

Conclusion The successful therapy with the Cyclosporine A supports the hypothesis that PWCD is a T cell mediated autoinflammatory condition. Rapid growth of angiolipoma during corticosteroid therapy is an extremely rare condition.

Keywords: prednisone; angiolipoma; side effect; panniculitis

САЖЕТАК

Увод Фајфер–Вебер–Кристијанова болест (ПВЦД) је редак инфламаторни поремећај поткожног масног ткива. Ангиолипом, је бенигни адипоцитни тумор меког ткива који се састоји од зрелог масног ткива и малих васкуларних пролиферација. Лечење кортикостероидима може да доведе до умножавања масног ткива, али стимулација раста ангиолиптома током терапије кортикостероидима је изузетно ретка.

Приказ болесника Приказујемо болесницу стару 46 година која има хистолошку потврду две ретке болести ПВЦД и доброћудне вишеструке неинфилтрирајуће ангиолиптоме. Ангиолиптоми су лечени конзервативно. ПВЦД је лечена пронизомом 20 мг/дан. Због лоше контроле ПВЦД и брзог раста ангиолиптома на подлактици, кортикостероиди су прекинути након два месеца употребе. Примена оралног циклоспорина А довела је до брзе ремисије ПВЦД и није било новог пораста ангиолиптома.

Закључак Успешна терапија циклоспорином А подржава хипотезу да је ПВЦД аутоинфламаторно стање посредовано Т ћелијама. Убрзан раст ангиолиптома током кортикостероидне терапије је изузетно ретко стање.

Кључне речи: преднизон; ангиолипом; нежељени ефекат; паникулитис

INTRODUCTION

Pfeifer-Weber-Christian disease (PWCD), is a rare idiopathic disease characterized by lobular panniculitis of adipose tissue with systemic symptoms and multiple organ involvement and is usually treated with corticosteroids [1]. Angiolipomas are rare, benign subcutaneous tumors, composed of adipose tissue and blood vessels and often containing fibrin thrombi, that account for approximately 10% of tumors of fat [2]. For now, the

induction of growth of angioliipoma during corticosteroid treatment, was reported only in one case [3].

We described an unusual case of PWCD associated with benign multiple subcutaneous non-infiltrative angioliipomas (BMSNA) which gradually increased in size during corticosteroid therapy. To the best of our knowledge, there are no previous reports of this association (from 1944 to 2020).

CASE REPORT

A 46-year-old Caucasian female presented with relapsing and remitting biyearly flares of panniculitis (always masseteric space, where appear subcutaneous painful nodules with erythema in overlying skin) (Figure 1a), associated with fever, oral aphthous ulcers, arthralgia/arthritis, myalgia, and generalized weakness, for 15 years (from 2002-2017). Initially, the nodules spontaneously withdrew. Later, she received anti-inflammatory, local anti-edematous, and antibiotic therapy, with no improvement. In 2017 disease recurred every month. A skin biopsy (right masseteric cheek) showed predominantly lobular panniculitis (Figure 1b-d). She also had multiple soft, well-circumscribed, round subcutaneous tumours present on lower trunk, forearms, and upper legs, distributed in a symmetric pattern, and ranged from 1 cm x 1 cm to 1.5 cm x 2 cm in size (Figure 2a). This condition started in 2013.

Her personal history revealed Raynaud's phenomenon, and dry eyes and mouth since 2002, high cholesterol and triglycerides since 2010, radical hysterectomy for chronic salpingitis and oophoritis 2015, and allergy to penicillin. There was no known tubercular contact or a family history of a similar disorder.

Her body height was 172cm, body weight was 69.3 kg and body mass index were 23.4kg/m². The percentage of fat was 34.9%, and fat mass was 24.2kg (normal range 23-34%, vs 13.5-23.2 kg, respectively, Tanita analyzer). Complete blood cell count, erythrocyte

sedimentation rate, C-reactive protein, antinuclear antibodies (ANA), anti-neutrophilic cytoplasmic autoantibody, anticyclic citrullinated peptide, rheumatoid factor, anti Ro/SSA, anti La/SSB antibody, anticardiolipin antibody, anti-beta 2 glycoprotein-I antibody, cryoglobulins, immunoglobulin assay, protein electrophoresis, immunoelectrophoresis, IgG 4, C1 inhibitor and C1_q, circulating immune complexes, complement C3 and C4 levels, serum amylase, alpha 1-antitrypsin, angiotensin-converting enzyme, were all negative/normal. The renal functions and the electrolytes were also all normal. The urine was free of any sediments or protein. HLA B27 and HLA B51 was negative. Hepatitis B and hepatitis C virus, HIV, IGRA test for tuberculosis, *Brucella abortus bovis* test and *dirofilaria repens* test were negative. The chest radiograph and the abdominal ultrasonography were normal. Ultrasound of the major salivary gland was normal. Salivary ^{99m}Tc-pertechnetate scintigraphy showed decreased accumulation and excretory function in both parotid and submandibular glands. A salivary gland biopsy showed rare dispersed lymphocytes and plasma cells without acinar atrophy, a finding consistent with nonspecific sialadenitis (grade 0). Lissamine green and Schirmer's test were negative. Capillaroscopy was normal. Dual-energy X-ray absorptiometry scanning showed osteopenia (T-score of total hip was -1.0, and spine -1.4). The endocrinology investigation revealed the following pathologic parameters: cholesterol 9.46, LDL-cholesterol 5.12 and triglycerides 2.23 mmol/l (normal range < 5.2 vs < 3.4 vs < 1.7 mmol/l, respectively), and autonomic neuropathy. She was absent of insulin resistance. All other endocrine parameters such as the thyroid hormones, catecholamines in 24h urine, cortisol, adrenocorticotrophic hormone, dehydroepiandrosterone sulfate, prolactin, human growth hormone, parathyroid hormone, neuron-specific enolase and chromogranin A were normal. The luteinizing hormone and follicle-stimulating hormone showed iatrogenic menopause. Ultrasound of the forearm showed subcutaneous masses of adipose tissue with internal vascularity suggestive of angioliipoma (AL), (Figure 2b-c).

We established the diagnosis of PWCD and BMSNA, after other types of panniculitis and multiple lipomas were excluded (Table 1, Table 2). Angiolipomas were treated conservatively, because patient had no other complaints related to the excess fat tissue. Treatment for dyslipidemia was Rosuvastatin 20 mg/day, and Esetimibe 10 mg/day, but with unsatisfactory values of total cholesterol and LDL-ch. Treatment for PWCD was prednisone 20 mg/day.

Due to poor control of PWCD and rapid AL growth on forearms (approximately 10x10 mm to 25x17mm) corticosteroids were discontinued after two months of use. The patient underwent complete surgical excision of two tumours on forearms measured 25x15x10 mm and 22x13x9 mm, which were encapsulated and yellow with the appearance of adipose tissue with red areas corresponding to blood vessels (Figure 3a). Tumours were composed of the lobules of mature adipose tissue with focally grouped, branching capillaries and focal hyaline thrombi in capillaries, and were diagnosed as AL (Figure 3b-c).

Patient was treated with cyclosporine A (CyA), 6 mg/kg/day for 12 months. As she was with no disease activity reported and no new tumour growth CyA dose was reduced to 2.5 mg/kg/day. Eight months after the dose reduction, patient was readmitted due to one-month history of abdominal discomfort, weight loss, nausea, and vomiting, accompanied by arthritis, fever, and oral aphthous ulcers. The dose of CyA was increased to 6 mg/kg/day.

Appendectomy was performed and histopathological analysis revealed acute phlegmonous appendicitis. Due to pronounced peritoneal adhesions, the mesoappendix was difficult to see but seemed to be unchanged. Patient is currently disease-free with no new growth of AL.

This case report was approved by the institutional ethics committee, and written consent was obtained from the patient for the publication of this case report and any accompanying images.

DISCUSSION

Clinically, AL are painful and relatively small tumors (< 2 cm) with a predilection for the upper extremities, and most commonly occur at an earlier age (second and third decades of life), usually in male patients [2, 4]. In our case the patient was female and was older than most reported cases. In the literature, appearance of numerous AL after corticosteroid therapy was reported only once, in a male patient after 15-year-long therapy with prednisone and azathioprine in the treatment of bilateral kidney transplantation [3]. In our case, tumours have already been present before the initiation of therapy. Their growth was induced after only two months of prednisone treatment. Exogenous-steroids-induced AL were also described in a young male after misuse of anabolic steroids [5]. A variable length of period from initiation of steroid use till appearance of lipomatosis or AL and presence of androgen receptors expression in AL suggest anabolic effects of steroids, rather than immunosuppression, as a mechanism of fat cell proliferation [2, 3, 6]. Beside AL, there was a report of another epidural lipomatous tumour, a hibernoma in a 6-year-old child with juvenile rheumatoid arthritis treated with prednisone for four years [7]. We believe this case represent spinal lipomatosis with remnants of brown fat cell rather than a true tumour.

Histopathological findings in AL, with lobules of mature adipocytes and proliferation of capillaries with focal hyaline thrombi, enable easy diagnosis. Diagnostic difficulties can occur in cases with a prominent proliferation of capillaries and small amount of fat tissue [4]. In our case, histopathological appearance was typical, and diagnosis was easily made.

However, the panniculitides are heterogenous inflammatory diseases of subcutaneous fat tissue that could bring diagnostic challenge and require thorough clinicopathological exploration [1, 8]. This is especially true in case of lobular panniculitides where a detailed clinical and histopathological evaluation led to reassessment of an entity previously known as PWCD. Because morphological findings in such biopsies pointed out to other specific

diseases, it was suggested this term should be abandoned in dermatology [9]. However, in our case other types of panniculitides were excluded and diagnosis of PWCD was made.

The rarity of PWCD makes it hard to assess the response of the disease to the therapeutic strategies. Accordingly, treatment options are empiric. They are derived on the basis of individual cases. Drugs used in the treatment of PWCD include corticosteroid therapy, fibrinolytic agents, hydroxychloroquine, azathioprine, thalidomide, cyclophosphamide, tetracycline, CyA, mycophenolate mofetil, anti-TNF treatment and intravenous immune globulin therapy [1, 10-12]. CyA and corticosteroids have been proved most effective [11, 13]. In the present case, we also showed successful response to CyA. Cyclosporine A has potent immunosuppressive properties that result from selective inhibition of T-lymphocyte activation. This suggests that the T-lymphocyte may have an important role in the pathogenesis of PWCD.

To conclude, presented case illustrated a typical problem of every patient suffering from rare disease - a too long period of time from the onset of symptoms to diagnosis and treatment. PWCD and BMSA represents diseases with a broad spectrum of symptoms and thus also a difficult differential diagnosis that require patience of the physician. This case specifically highlights the histopathological aspects of PWCD and angioliipoma as a vital clue to the diagnosis, and supports the hypothesis that PWCD is a T cell mediated autoinflammatory condition, and may represent an association between corticosteroid use and the growth of angioliipomas. We hope that our experiences will also can contribute to greater awareness of these rare disorders.

ACKNOWLEDGEMENT

This article has been posted as a preprint on Research Square

Conflict of interest: None declared.

Paper accepted

REFERENCES

1. Rotondo C, Corrado A, Mansueto N, Cici D, Corsi F, Pennella A, et al. Pfeifer-Weber-Christian Disease: A Case Report and Review of Literature on Visceral Involvements and Treatment Choices. *Clin Med Insights Case Rep.* 2020;13:1179547620917958. doi: 10.1177/1179547620917958.
2. Herbst KL. Subcutaneous Adipose Tissue Diseases: Dercum Disease, Lipedema, Familial Multiple Lipomatosis, and Madelung Disease. In: Feingold KR, Anawalt B, Boyce A, Chrousos G, de Herder WW, Dhatariya K, Dungan K, Hershman JM, Hofland J, Kalra S, Kaltsas G, Koch C, Kopp P, Korbonits M, Kovacs CS, Kuohung W, Laferrère B, Levy M, McGee EA, McLachlan R, Morley JE, New M, Purnell J, Sahay R, Singer F, Sperling MA, Stratakis CA, Trencle DL, Wilson DP, editors. *Endotext* [Internet]. South Dartmouth (MA): MDText.com, Inc.; 2000–2019 Dec 14. PMID:31895524 .
3. Clayman E, King K, Harrington MA. Corticosteroid-Associated Angiolipomatosis. *Eplasty.* 2017;17:ic9. eCollection 2017. PMID:28458766.
4. Bilings SD, Requena L. Angiolipoma. In: Elder DE, Massi D, Scolyer RA, Willemze R, editors. *WHO Classification of Skin Tumours.* 4th ed. France: International Agency for research on Cancer; 2018. p. 300. ISBN-13 (Print Book) 978-92-832-2440-2
5. Syed SP, Brooks DG, Haupt HM, Bellucci K, Martin AM, Podolski V, Brooks JJ. Anabolic steroids causing growth of benign tumors: androgen receptor in angiolipomas. *J Am Acad Dermatol.* 2007;57(5):899-900. doi: 10.1016/j.jaad.2007.06.012
6. Kim K, Mendelis J, Cho W. Spinal Epidural Lipomatosis: A Review of Pathogenesis, Characteristics, Clinical Presentation, and Management. *Global Spine J.* 2019;9(6):658-65. doi.org/10.1177/2192568218793617
7. Perling LH, Laurent JP, Cheek WR. Epidural hibernoma as a complication of corticosteroid treatment. Case report. *J Neurosurg.* 1988;69(4):613-6. doi: 10.3171/jns.1988.69.4.0613
8. Morita TCAB, Trés GFS, García MSC, Halpern I, Criado PR, de Carvalho JF. Panniculitides of particular interest to the rheumatologist. *Adv Rheumatol.* 2019;59(1):35. doi: 10.1186/s42358-019-0077-5.
9. White JW Jr, Winkelmann RK. Weber-Christian panniculitis: a review of 30 cases with this diagnosis. *J Am Acad Dermatol.* 1998;39(1):56-62. doi:10.1016/s0190-9622(98)70402-5
10. Somalanka S, Udo I, Nair H, Baikunje S. Pfeifer-Weber-Christian disease and successful treatment with mycophenolate mofetil: a case report. *BMJ Case Rep.* 2019;12(5):e229167. doi: 10.1136/bcr-2018-229167.
11. Wang Y, Zhao J, Ji LL, Zhang S, Zhang Z. Weber-Christian disease presenting with lung nodules dramatically improved with corticosteroid therapy: one case report and literature review. *Int J Rheum Dis.* 2018;21(2):573-578. doi: 10.1111/1756-185X.12620.
12. Noh G, Han CW. Intravenous Immune Globulin (IVIg) Therapy After Unsuccessful Treatment with Corticosteroid and Cyclosporine A in Pfeifer-Weber-Christian Disease: A Case Report. *Am J Case Rep.* 2021;22:e929519. doi: 10.12659/AJCR.929519.
13. Cantarini L, Fanti F, Galeazzi M, Martino S, Miracco C, Biagioli M, et al. Efficacy of cyclosporine A treatment in relapsing febrile lobular panniculitis associated with small vessel vasculitis. *Rheumatol Int* 2010;30:797–799. doi: 10.1007/s00296-009-0990-8.

Table 1 Classification of panniculitis and conditions associated with panniculitis

Type of panniculitis	
I.	Lobular panniculitis
	<ol style="list-style-type: none"> 1. Pfeifer-Weber-Christian disease (Idiopathic relapsing febrile lobular non-suppurative panniculitis) 2. Panniculitis in systemic connective tissue diseases: (Systemic lupus erythematosus, Rheumatoid arthritis, Vasculitis, Myositis, Systemic sclerosis, Eosinophilic fasciitis, Eosinophilia-myalgia syndrome) 3. Complement deficiency 4. Lipodystrophic panniculitis 5. Enzymatic panniculitis: (pancreatitis, pancreatic carcinoma, alpha-1-antitrypsin deficiency) 6. Factitial panniculitis 7. Cytophagic histiocytic panniculitis 8. Post-steroid panniculitis (withdrawal of glucocorticoids) 9. Hodgkin's lymphoma and leukemia 10. Rothmann-Makai syndrome (Lipogranulomatosis subcutaneous)
II.	Septal panniculitis
	<ol style="list-style-type: none"> 1. Erythema nodosum 2. Subacute nodular migratory panniculitis (Vilanova disease)
III.	Mixed panniculitis
	<ol style="list-style-type: none"> 1. Lupus profundus panniculitis 2. Erythema nodosum-like lesions in Behcet's syndrome
V.	Panniculitis with vasculitis
	<ol style="list-style-type: none"> 1. Vasculitis of small blood vessels 2. Medium-size vessel vasculitis (small arteries or arterioles) 3. Polyarteritis nodosa 4. Erythema induratum (nodular vasculitis)

Table 2 Rare syndromes associated with lipomas

Syndrome	Components
Familial angioliomatosis	Family history of similar lesions, autosomal-recessive or autosomal-dominant fashion
Benign symmetric lipomatosis (Madelung's disease, Launois-Bensaude's syndrome)	Diffuse or circumscribed symmetrical accumulation of adipose tissue, primarily around the neck, back, shoulders and upper trunk
Neurofibromatosis type I	Café au lait macules, cutaneous/subcutaneous neurofibromas, axillary or groin freckling, optic pathway glioma, nodules, bony dysplasia
Cellular angioliopoma	Histologic are composed almost entirely of small vessels (>95 % of the lesion)
Spindle cell-lipoma	Subcutaneous nodule in the head and neck region, composed of mature adipocyte and bland spindle cells
Angiomyxoliopomas	Contains mature adipose tissue, extensive myxoid stroma and numerous blood vessels
Lipomatosis syndrome in patients infected with HIV	Lipomas, peripheral lipodystrophy, central adiposity, dyslipidemia, insulin resistance
Bannayan-Zonana syndrome	Multiple lipomas, hemangiomas, macrocephaly
Cowden disease	Lipomas, hemangiomas, goiter, various skin and mucosal lesions (including intraoral papillomas, acral keratoses, facial trichilemmomas), colorectal hamartomatous polyps, gastric polyps with hyperplastic features
Fröhlich syndrome	Multiple lipomas, sexual infantilism, obesity
Proteus syndrome	Pelvic lipomatosis, fibroplasia of hands and feet, skeletal hypertrophy, bony exostoses, scoliosis, pigmented skin lesions

Figure 1. a – Induration of the skin in the right masseteric space; b – focal lobular lymphocytic infiltration around small blood vessels (asterisk) along with slightly widened interlobular septum with rare epithelioid granulomas (arrow), (Haematoxylin and Eosin staining, magnification $\times 40$); c – granulomas were composed of epithelioid histiocytes and lymphocytes, without necrosis or giant cells (magnification $\times 100$); d – rare small areas of fat cell necrosis and foamy histiocytes (lipophagic necrosis) were noted, unrelated to areas with granulomas (magnification $\times 400$)

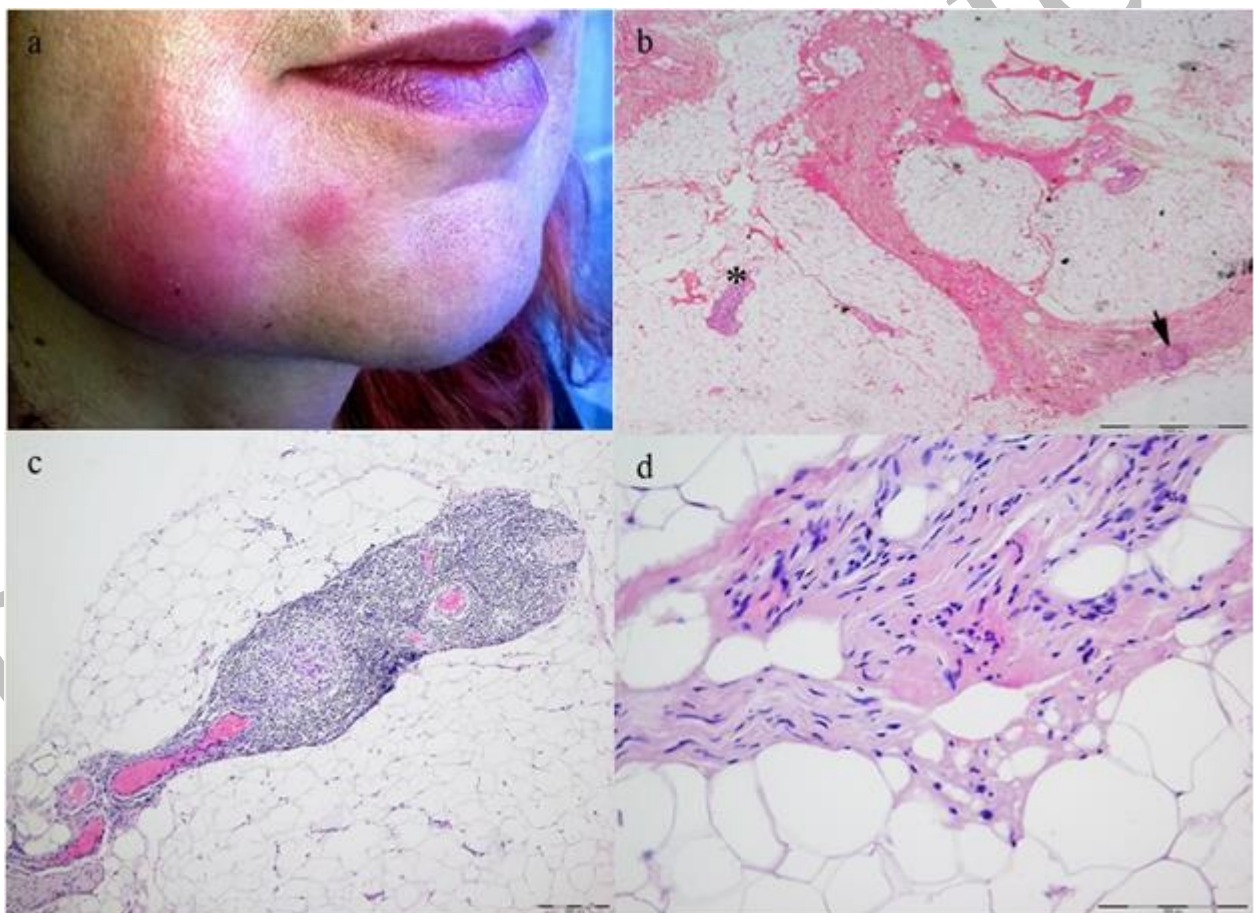


Figure 2. a – Multiple well-circumscribed, round subcutaneous tumours in the forearms of patient (black arrows); b – the grayscale sonogram of forearms tumours showed three heterogeneous hyperechoic ovoid masses in the subcutaneous layer, with internal echogenic strands (white cross), deep tumour capsules (black arrows), and no lateral and superficial capsules (white arrows); c – the colour Doppler sonogram showed presence of vascularity

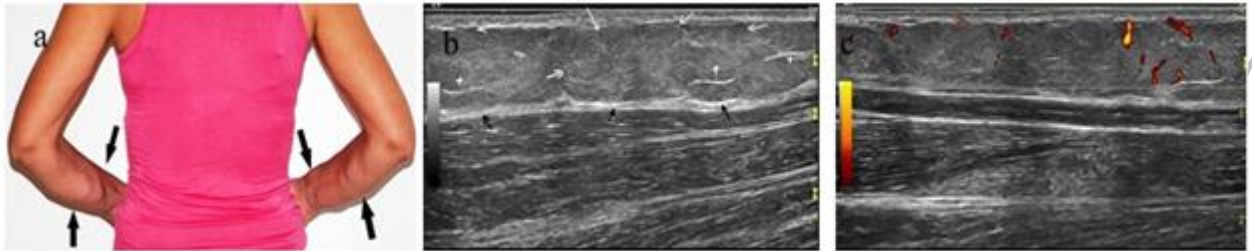


Figure 3. a – Macroscopic encapsulated yellow adipose tissue with red areas corresponding to blood vessels; b – on histopathology, in lobules of mature adipose tissue focally grouped branching capillaries were seen (Haematoxylin and Eosin staining, magnification $\times 100$); c – some of capillaries contained hyaline thrombi (arrows) enabling diagnosis of angioliipomas (Haematoxylin and Eosin staining, magnification $\times 200$)

