



СРПСКИ АРХИВ
ЗА ЦЕЛОКУПНО ЛЕКАРСТВО
SERBIAN ARCHIVES
OF MEDICINE

Address: 1 Kraljice Natalije Street, Belgrade 11000, Serbia

+381 11 4092 776, Fax: +381 11 3348 653

E-mail: office@srpskiarhiv.rs, Web address: www.srpskiarhiv.rs

Paper Accepted¹

ISSN Online 2406-0895

Original Article / Оригинални рад

Milica Jovanović-Medojević^{1,*}, Dragana Jovanović², Mina Medojević^{3,4}, Strahinja Nedić¹,
Đorđe Stratimirović⁵, Sanja Vujašković¹, Mirjana Vujašković¹

**The prevalence and severity of molar incisor hypomineralization
in group of students – a cross-sectional study**

Заступљеност и тежина хипоминаерализације молара и секутића
у групи студената – студија пресека

¹University of Belgrade, School of Dental Medicine, Department for Restorative Dentistry and Endodontics, Belgrade, Serbia;

²University of Belgrade, School of Dental Medicine, Belgrade, Serbia;

³Université de Bordeaux, Institut National de la Santé et de la Recherche Médicale, BioTis, U1026, Bordeaux, France;

⁴University of Belgrade, School of Dental Medicine, Implant-Research Center, Belgrade, Serbia;

⁵University of Belgrade, School of Dental Medicine, Department of Basic Sciences, Belgrade, Serbia

Received: March 12, 2025

Revised: March 30, 2025

Accepted: March 31, 2024

Online First: April 1, 2025

DOI: <https://doi.org/10.2298/SARH250312028J>

¹**Accepted papers** are articles in press that have gone through due peer review process and have been accepted for publication by the Editorial Board of the *Serbian Archives of Medicine*. They have not yet been copy-edited and/or formatted in the publication house style, and the text may be changed before the final publication.

Although accepted papers do not yet have all the accompanying bibliographic details available, they can already be cited using the year of online publication and the DOI, as follows: the author's last name and initial of the first name, article title, journal title, online first publication month and year, and the DOI; e.g.: Petrović P, Jovanović J. The title of the article. Srp Arh Celok Lek. Online First, February 2017. When the final article is assigned to volumes/issues of the journal, the Article in Press version will be removed and the final version will appear in the associated published volumes/issues of the journal. The date the article was made available online first will be carried over.

***Correspondence to:**

Milica JOVANOVIĆ-MEDOJEVIĆ

University of Belgrade, School of Dental Medicine, Department for Restorative Dentistry and Endodontics,
Rankeova 4, 11000 Belgrade, Serbia

E-mail: medojevic.milica@gmail.com

The prevalence and severity of molar incisor hypomineralization in group of students – a cross-sectional study

Заступљеност и тежина хипоминаерализације молара и секутића у групи студената – студија пресека

SUMMARY

Introduction/Objective The aim of this study was to investigate the prevalence and conditions of teeth with molar incisor hypomineralization (MIH) in the early adult population.

Methods A cross-sectional study was conducted of 298 students of the school of Dental Medicine, University of Belgrade from the third to the fifth year of study. The presence of MIH was registered on the basis of European Academy of Paediatric Dentistry (EAPD) diagnostic criteria and oral health and caries risk were assessed by standard dental examination and determination of DMF index values. The MIH sample was divided into two groups: untreated teeth (the estimation of the degree of hypomineralization was based on the color, location and size of the hypomineralized part of the enamel) and treated teeth (where types of preventive and various restorative treatments were registered). Statistical analysis was performed using the χ^2 test ($p < 0.05$).

Results MIH was observed in 90 subjects (30.2%). The results of the oral health examination showed that the average DMF index was medium risk (7.66). for the MIH sample. MIH-untreated teeth showed mild or moderate degree of hypomineralization. The presence of extensive carious lesions, secondary caries, as well as the loss of the first permanent molars teeth was statistically significantly higher ($p < 0.05$) compared to the sample without MIH changes.

Conclusion The study results confirmed the problem in recognizing and adequately treating MIH altered teeth.

Keywords: molar incisor hypomineralization; MIH; student population; cross-sectional study

САЖЕТАК

Увод/Циљ Циљ овог истраживања био је да се испита заступљеност и стање хипоминаерализованих првих сталних молара (*molar incisor hypomineralization – MIH*) у студентској популацији.

Методе Епидемиолошка студија пресека је спроведена након писане сагласности 298 испитаника, студената Стоматолошког факултета Универзитета у Београду од III до V године студија. Присуство *MIH*-а је регистровано на основу критеријума Европске академије за дечју стоматологију а стандардним стоматолошким прегледом и одређивањем вредности КЕП индекса процењен је ризик за орално здравље и каријес. Узорак са *MIH*-ом је подељен у две групе: нелечени зуби (на којима је на основу боје, локализације и величине хипоминаерализованог дела глеђи процењен степен њихове хипоминаерализације) и лечени зуби (на којима су регистровани превентивни и различити рестауративни третмани). Подаци су статистички анализирани тестом χ^2 ($\alpha=0,05$).

Резултати *MIH* је уочен код 90 испитаника (30,2%). Резултати оралног здравственог прегледа показали су да је КЕП индекс за узорак са *MIH*-ом 7,66. Нетретирани *MIH* зуби су показали благи или умерени степен хипоминаерализације. Присуство екстензивних каријесних лезија, секундарног каријеса, као и екстракција првих сталних молара било је статистички значајно веће ($p < 0,05$) у поређењу са зубима без промена *MIH*.

Закључак Резултати студије су потврдили проблем у препознавању и адекватном лечењу *MIH*-ом измењених зуба.

Кључне речи: хипоминаерализација првих молара и секутића; *MIH*; студентска популација; студија пресека

INTRODUCTION

Hypomineralization of molars and incisors (MIH) is a developmental enamel disorder that affects first permanent molars and often permanent incisors [1]. The clinical picture of MIH depends on its severity and can range from opaquer white, cream colored markings or yellow-brown color, superficial enamel defects to atypical caries located on at least one permanent molar [2].

MIH is a qualitative enamel defect caused by reduced mineralization, which, according to research by Crombie et al, can be up to 58.8% [3]. The mineralization disorder occurs at the level of the enamel-dentine junction and spreads towards the surface of the tooth [3]. Pathogenetically, MIH results from dysfunctional ameloblast resorption and inhibition of proteolytic enzymes, which results in retention of enamel proteins, disruption of hydroxyapatite crystal growth and enamel maturation [4]. The enamel of hypomineralized teeth is structurally compromised due to higher protein and water content, altered color, increased porosity and irregularly organized hydroxyapatite crystals [5]. Mechanical property tests (hardness and modulus of elasticity) of enamel affected by MIH reveal significantly lower values compared to healthy enamel [3]. The consequences of this enamel structure are increased tooth sensitivity (especially in the early eruptive phase), increased accumulation of dental plaque and, consequently, a tendency to rapid caries development [6]. Therefore, MIH represents a public health concern that negatively affects the oral health of patients, as well a great therapeutic challenge for clinicians [7, 8].

Although MIH can be diagnosed in childhood at the time of eruption of permanent first molars and central incisors (6 - 8 years), clinicians are often faced with the consequences of unrecognized MIH lesions that have not been adequately treated [4]. MIH is often misdiagnosed or diagnosed too late, so the therapy of hypomineralized teeth is delayed and inappropriate [9]. Due to extreme sensitivity and difficulty in maintaining oral hygiene, patients with hypomineralization avoid regular dental check-ups, which combined with difficulties in achieving proper anesthesia consequently deepen dental anxiety [9, 10]. Hypomineralized teeth are sensitive and painful, and their therapy is therefore complex and specific [10]. The porous structure of enamel with weakly bonded crystals and irregular arrangement of enamel prisms makes adhesion difficult, compromising the success of restorative treatments, which often results in the occurrence of subacute pulpitis [11]. Therefore, MIH patients require significantly more dental interventions compared to patients without MIH [12].

Therapeutic approaches for hypomineralized teeth can be implemented in three directions: prevention, restorative procedures (with or without endodontic therapy) and extractions. Preventive measures are implemented through adequate risk assessment, early diagnosis, remineralization, desensitization, fissure filling, education on maintaining proper oral hygiene and the benefits of anticariogenic nutrition. Materials used in restorative procedures are most often Glas Ionomer Cements (GIC), resin-modified GIC, compomers, composite materials, metal crowns and onlays [13–16].

After adequate preventive and restorative procedures have been carried out, it is necessary to constantly control the marginal integrity of restorations (due to frequent enamel fractures) and to ensure that the patient is adhering to an adequate hygienic-dietary regime [15, 16, 17].

Studies on the prevalence and degree of hypomineralization, as well as applied therapeutic procedures of MIH, were conducted in children and their results indicate a different prevalence of MIH (2.8–40.2%) [18]. Limited data exists on monitoring the success of applied preventive and therapeutic measures as well as the follow-up of MIH-affected teeth in early adulthood. It is necessary to analyze the success of implemented preventive measures, methods of therapy, as well as the stability and adequacy of restorations using certain dental materials in the treatment of MIH.

The aim of this study is to examine the prevalence and condition of hypomineralized first permanent molars and incisors in the population of young adult patients (students of the School of Dental Medicine, University of Belgrade).

METHODS

Data source

The present study had been designed as an observatory cross-sectional study and carried out during the summer semester (March 14th to May 13th) of the academic year 2021/2022. The study protocol was approved by the Ethics Committee of the School of Dental Medicine, University of Belgrade, Belgrade, Serbia (No 36/31) in accordance with the Declaration of Helsinki.

Participants

Participants in this study are 298 students (223 female and 75 male) of VI, VIII and X semester attending the School of Dental Medicine, University of Belgrade, Belgrade, Serbia, who voluntarily gave and signed their written consent (available in Appendix) to participate in the research. Students born between the years 1993 and 2001 participated in the study, with the majority of participants born between 1998 and 2000, resulting in 157 students (more than 50%).

All students were divided into two groups, sample without MIH and sample in which MIH was diagnosed. Eligibility criteria: all students who showed at least one tooth affected by molar-incisor hypomineralization were referred for inclusion in the study and categorized in the MIH

group. Exclusion criteria were: patients undergoing orthodontic treatment with the fixed appliance; which did not allow an adequate clinical examination. Students with other developmental defects of teeth (fluorosis, amelogenesis imperfecta, and dentinogenesis imperfecta), syndromes associated with enamel formation defects were classified in group without MIH.

Recording procedure

The clinical examination was performed in a dental clinic setting, using a standard dental mirror and probe by one examiner, assisted by two students. Data on the status of all teeth were recorded, classified and entered into a modified WHO epidemiological survey record from 2013 [19]. After a clinical dental examination of the dental status of all participants, a MIH sample was selected, consisting of subjects in whom the diagnosis of hypomineralized molars and incisors was confirmed. The presence of MIH was registered on the basis of EAPD diagnostic criteria:

- Demarcated opacities,
- Enamel disintegration - Posteruptive enamel breakdown (PEB),
- Atypical restorations,
- Extraction due to MIH,
- Retention or non-eruption of molars and incisors
- Larger and atypical carious lesions with blurring along the edges of the cavity [20].

Lesions smaller than 1 mm were not verified as MIH, nor were changes in the form of opacity observed only on the incisors, without molar involvement [20].

The condition of all teeth, including first permanent molars and upper central incisors, was recorded in the questionnaires for both groups (with or without MIH) (questionnaires available in Appendix). The occurrence and the size of caries lesion (primary and secondary) were noted, as well as the presence of preventive treatments (sealants), restoration of examined teeth (occurrence and size of the fillings, prosthodontic treatment), endodontic treatments and the number of extracted teeth. Oral health and caries risk were assessed by standard dental examination and determination of DMF-T (Decayed, Missing, Filled Teeth) index values [21].

The sample with MIH was divided into two groups: untreated teeth and teeth that had undergone preventive and restorative treatment. In untreated hypomineralized teeth, information about

color (white, yellow or brown), localization (vestibular or oral surfaces and/or occlusal or incisal) and size of the lesion (< 30% of the tooth surface (mild defects), 31–49% of the tooth surface (moderate defects), > 50% of the tooth surface (severe defects)) were recorded and based on them, the degree of hypomineralization was assessed [17].

Statistical analyses

Statistical analysis of the obtained data was performed using the Chi-Square test for independent samples at a confidence level of 5% ($\alpha=0.05$).

RESULTS

In the population of 298 students in the third, fourth and fifth year of basic integrated studies at the School of Dental Medicine, University of Belgrade, Belgrade, Serbia, MIH was observed in 90 subjects, representing 30.2%

(female – 75, male – 15). In the group with MIH (90 students), there were 9 subjects without caries, fillings and non-orthodontic extractions.

The color distribution, localization, and size of enamel defects are shown in Table 1. Among MIH diagnosed teeth without any preventive and therapeutic procedures, a mild (92%) or moderate degree of hypomineralization (8%) was observed, with mostly white spots (87%) that affected the vestibular/oral (46%) i.e. occlusal/incisal (54%) surfaces of the teeth relatively equally.

The results of the oral health examination showed that the KEP for the sample with MIH

$$(K - 37, E - 55, P - 589) / 90 = 7.66$$

The results of the analysis of teeth affected by MIH in which different therapeutic procedures were applied, revealed the presence of extensive caries lesions, secondary caries, as well as the loss of teeth affected by MIH that was statistically significantly higher ($p<0.05$) compared to the sample without MIH changes (Tables 2 and 3).

A statistically significant difference was observed in the number of surfaces affected by fillings of the first permanent molars in the sample from MIH compared to molars not affected by hypomineralization (Table 4 and Figure 1).

DISCUSSION

The prevalence of MIH in our study was 30.2%. The degree of representation is somewhat higher compared to the results of epidemiological studies, which reported a rate of 3.6% to 25% in European countries [22, 23]. However, the results of the Jalevik systematic review show a wider variation in the prevalence of MIH (2.4–40.2%) [24]. There are no official data on the prevalence of MIH for Serbia, although it is estimated to be around 19.5% [25]. The reasons for the higher degree of MIH in this population can be found in the turbulent time in which the subjects were born (time of NATO bombing and exposure to various stressful and toxic factors) [1–4]. This increase in MIH is in agreement with the results of an epidemiological pilot study by Elzein et al., who observed a positive correlation in the prevalence of MIH in the bombed areas of Lebanon [26].

The gender of the students was not significant in the finding of MIH, although a greater number of women showed MIH changes (75 female and 15 male) which reflected the structure of the sample (223 female and 75 male).

It is fully expected that teeth in which MIH has been observed, where preventive and therapeutic procedures have not been carried out, show mostly isolated mild or moderate degree of hypomineralization, with mostly white spots. This population includes 10% of BO students (without caries, fillings and extractions due to caries). Therefore, it is extremely important to recognize the degree of these hypomineralizing changes, in order to apply adequate preventive and therapeutic measures. A mild or moderate degree of hypomineralization with adequate maintenance of oral hygiene enables a healthy set of teeth.

The increased degree of caries risk in the MIH sample (7.66 i.e. medium caries risk) indicates a high vulnerability of the MIH population to the occurrence of carious lesions. The presentation of different preventive and therapeutic procedures in the sample with and without MIH on the first permanent molars and central upper incisors indicates an increased number of primary and secondary carious lesions in the MIH sample compared to students without this hypomineralization. Hypomineralized molars have a five to ten times greater need for dental treatment than molars without MIH [13]. The restoration of hypomineralized teeth very often presents a problem, especially in defining the edges of the cavity (hypomineralized parts of the enamel cause the appearance of marginal permeability and endanger the success of the restoration). It is recommended to include the complete porous enamel in the cavity, but with the maximum preservation of healthy enamel that has changed color [26]. For this reason, it is extremely

important to recognize MIH changes and start increased prevention as soon as MIH teeth emerge, due to their propensity for posteruptive enamel deterioration and higher prevalence of carious lesions. The frequent occurrence of secondary caries and tooth crown fractures require more frequent dental controls with monitoring of the success of the implemented preventive and therapeutic procedures.

Defects on the incisors are usually milder than the changes on the molars, and the mild, mostly yellow-white changes are discolored over time by food and drink dyes and are less noticeable with age. Resin infiltration technique (DMG Icon) was performed on three teeth of the MIH population in order to improve the aesthetic properties of these teeth. This preparation improves optical properties by acting on translucency (refractive index of the resin infiltrate (1.52) is close to the index of healthy enamel (1.62)) [19]. Preparation for aesthetic fillings of hypomineralized incisors should be as conservative as possible, and the degree of treatment depends on the patient's age, aesthetic concern and interest of the patients themselves, as well as the severity of the lesion.

However, the incisal edge of MIH central incisors tends more often to have post-eruptive fractures, which represents a challenge in restoration, thus significantly more endodontic treatments were performed on the central incisors of the MIH population compared to students without MIH.

Also, the size of the restorations, i.e. the number of tooth surfaces included in the restoration is significantly higher in the population of students with MIH. The large area of hypomineralized first permanent molars is probably a consequence of higher enamel porosity and lower mechanical resistance, especially in severe MIH lesions. First permanent molars as occlusion carrier teeth must be adequately restored prosthetically in order to prevent pathological fractures of these teeth.

Endodontic treatment of first permanent molars with MIH does not show a higher degree of frequency compared to students without MIH. The reason is probably to be found in the age of the patients. Based on the anamnestic data obtained from the subjects, it was found out that the MIH-affected molars were the cause of their dental problems from the moment they erupted. They were restored with fillings that did not persist long in the cavity, with frequent occurrence of secondary caries and crown fractures. Complex and long-term endodontic therapies were carried out on such teeth, but they usually had to be extracted. A systematic review by Taylor et al. 2020 showed that partial and coronal pulpotomies have both short and long-term high

success rates, while conventional pulpectomy or regenerative techniques have limited success in MIH molars [27]. Thus, partial or coronary pulpotomies can be considered as a potential endodontic treatment option for molars affected by MIH.

The presentation of different therapeutic procedures in the sample with and without MIH on the first permanent molars indicates an increased number of non-orthodontic extractions in the MIH sample compared to students without this hypomineralization. Extracted first permanent molars have a significant impact on adequate occlusion, and expensive implant-prosthetic solutions is necessary. Extraction of first permanent molars with severe hypomineralization changes and a poor prognosis must be considered at an early age based on a comprehensive dental evaluation. A multidisciplinary approach that includes the opinion of both the pediatric dentist and the orthodontist is necessary to enable balance and compensation of the bite [28].

To the best of our knowledge, this is the first study which investigated the prevalence and conditions of teeth with molar and incisor hypomineralization in the student (young adult) population in Serbia. This study enabled the evaluation of changes in the oral health of patients with MIH over time and the possible formation of priorities and ways of directing existing resources for prevention and therapy.

CONCLUSION

The results of this study confirmed the problem in recognizing teeth affected by molar incisor hypomineralization and their adequate therapy. During the treatment of MIH teeth, the degree of hypomineralized changes and their long-term prognosis must be taken into account, as well as specific characteristics in the form of increased pain sensitivity of such teeth. Early diagnosis, adequate therapy in the post-eruptive phase, active application of preventive measures and regular check-ups of young adult patients are extremely important for the preservation of teeth affected by hypomineralization.

ACKNOWLEDGEMENT

A part of the results from this article was presented and published in the form of an abstract at the 61st School of Dental Medicine Students' Scientific Meeting (Jovanović D, Teofilović K. Condition of teeth with Molar Incisor Hypomineralisation in the student population of the

School of Dental Medicine in Belgrade. Proceedings of the 61st School of Dental Medicine Students' Scientific Meeting; 2022 Mar 28-29; Belgrade, Serbia).

The authors would like to thank students who were involved in the study.

Conflict of interest: None declared.

REFERENCES

1. Bussaneli DG, Vieira AR, Santos-Pinto L, Restrepo M. Molar-incisor hypomineralisation: an updated view for aetiology 20 years later. *Eur Arch Paediatr Dent*. 2022;23(1):193–8. [DOI: 10.1007/s40368-021-00659-6] [PMID: 34392496]
2. Alzahrani AY, Alamoudi NMH, El Meligy OAES. Contemporary Understanding of the Etiology and Management of Molar Incisor Hypomineralization: A Literature Review. *Dent J*. 2023;11:157. [DOI: 10.3390/dj11070157] [PMID: 39735046]
3. Crombie F, David Manton D, Kilpatrick N. Aetiology of molar–incisor hypomineralization: a critical review. *Int J Paediatr Dent*. 2009;19:73–83. [DOI: 10.1111/j.1365-263X.2008.00966.x] [PMID: 19250392]
4. Hubbard MJ, Mangum JE, Perez VA, Williams R. A Breakthrough in Understanding the Pathogenesis of Molar Hypomineralisation: The Mineralisation-Poisoning Model. *Front Physiol*. 2021;12:802833. [DOI: 10.3389/fphys.2021.802833] [PMID: 34992550]
5. Tynior W, Świętek A, Hudy D, Ilczuk-Rypuła D, Strzelczyk JK. Molecular Detection of HPV, EBV, HSV-1, HCMV, and *H. pylori* Pathogens: An Evaluation among Polish Children with Molar Incisor Hypomineralization (MIH). *Pathogens*. 2024;13(4):345. [DOI: 10.3390/pathogens13040345] [PMID: 38668300]
6. Rodd HD, Graham A, Tajmehr N, Timms L, Hasmun N. Molar Incisor Hypomineralisation: Current Knowledge and Practice. *Int Dent J*. 2021;71(4):285–91. [DOI: 10.1111/idj.12624] [PMID: 34286697]
7. Elhennawy K, Rajjoub O, Reissmann DR, Doueiri MS, Hamad R, Sierwald I, Wiedemann V, et al. The association between molar incisor hypomineralization and oral health-related quality of life: a cross-sectional study. *Clin Oral Investig*. 2022;26(5):4071–7. [DOI: 10.1007/s00784-022-04523-9] [PMID: 35147789]
8. Vicioni-Marques F, Carvalho MR, Raposo F, de Paula-Silva FWG, de Queiroz AM, Leal SC, et al. Association of dental hypersensitivity and anxiety in children with molar-incisor hypomineralisation (MIH). *Eur Arch Paediatr Dent*. 2023;24(3):313–9. [DOI: 10.1007/s40368-023-00803-4] [PMID: 37199855]
9. Cook C, Lopez RM. Is molar incisor hypomineralisation (MIH) a new disease of the 21st century? *Pediatr Dent J*. 2022;32(2):67–76. [DOI: 10.1016/j.pdj.2022.04.001]
10. Rodríguez ÓA, Laverde M, Rojas-Gualdrón DF, Cárdenas JM, Mejía JD, de Farias AL, et al. The level of dental fear and anxiety is higher in children with both severe Molar-Incisor Hypomineralisation and active dental caries lesions compared to children without these conditions. *Eur Arch Paediatr Dent*. 2024;25(5):655–62. [DOI: 10.1007/s40368-024-00923-5] [PMID: 39207662]
11. Quintero Y, Restrepo M, Rojas-Gualdrón DF, Farias AL, Santos-Pinto L. Association between hypomineralization of deciduous and molar incisor hypomineralization and dental caries. *Braz Dent J*. 2022;33(4):113–9. [DOI: 10.1590/0103-6440202204807] [PMID: 36043563]
12. Awwad A, Hamad R, Schiffner U, Splieth CH, Schmoeckel J. Effect of Prevalence and Severity of Molar-Incisor Hypomineralization on Oral Health-Related Quality of Life: A Systematic Review and Meta-Analysis. *Acta Stomatol Croat*. 2023;57(4):381–94. [DOI: 10.15644/asc57/4/8] [PMID: 38283314]
13. Lygidakis NA. Treatment modalities in children with teeth affected by molar-incisor enamel hypomineralisation (MIH): A systematic review. *Eur Arch Paediatr Dent*. 2010;11(2):65–74. [DOI: 10.1007/BF03262715] [PMID: 20403300]
14. Inchingolo AM, Inchingolo AD, Viapiano F, Ciocia AM, Ferrara I, Netti A, et al. Treatment Approaches to Molar Incisor Hypomineralization: A Systematic Review. *J Clin Med*. 2023;12(22):7194. [DOI: 10.3390/jcm12227194] [PMID: 38002806]
15. Enax J, Amaechi BT, Farah R, Liu JA, Schulze Zur Wiesche E, Meyer F. Remineralization Strategies for Teeth with Molar Incisor Hypomineralization (MIH): A Literature Review. *Dent J (Basel)*. 2023;11(3):80. [DOI: 10.3390/dj11030080] [PMID: 36975577]
16. Butera A, Pascadopoli M, Pellegrini M, Trapani B, Gallo S, Radu M, et al. Biomimetic hydroxyapatite paste for molar-incisor hypomineralization: A randomized clinical trial. *Oral Dis*. 2023;29(7):2789–98. [DOI: 10.1111/odi.14388] [PMID: 36135352]
17. Lygidakis NA, Garot E, Somani C, Taylor GD, Rouas P, Wong FSL. Best clinical practice guidance for clinicians dealing with children presenting with molar-incisor-hypomineralisation (MIH): an updated European Academy of Paediatric Dentistry policy document. *Eur Arch Paediatr Dent*. 2022;23(1):3–21. [DOI: 10.1007/s40368-021-00668-5] [PMID: 34669177]

18. Villanueva Gutiérrez T, Barrera Ortega CC, García Pérez A, González-Aragón Pineda AE. Relationship between Molar Incisor Hypomineralization (MIH) severity and cavitated carious lesions in schoolchildren. *Acta Odontol Latinoam*. 2019;32(3):133–40. [PMID: 32176236]
19. Petersen PE, Baez RJ, Ogawa H. Global application of oral disease prevention and health promotion as measured 10 years after the 2007 World Health Assembly statement on oral health. *Community Dent Oral Epidemiol*. 2020;48(4):338–48. [DOI: 10.1111/cdoe.12538] [PMID: 32383537]
20. Ghanim A, Silva MJ, Elfrink MEC, Lygidakis NA, Mariño RJ, Weerheijm KL, et al. Molar incisor hypomineralisation (MIH) training manual for clinical field surveys and practice. *Eur Arch Paediatr Dent*. 2017;18(4):225–42. [DOI: 10.1007/s40368-017-0293-9] [PMID: 28721667]
21. Gadallah LK, Korayem E, Wahby R. Oral health-related quality of life in Egyptian children with Molar Incisor Hypomineralisation: An observational study. *BDJ Open*. 2024;10:89. [DOI: 10.1038/s41405-024-00272-x] [PMID: 39616152]
22. Weerheijm KL, Mejåre I. Molar incisor hypomineralization: a questionnaire inventory of its occurrence in member countries of the European Academy of Paediatric Dentistry (EAPD). *Int J Paediatr Dent*. 2003;13(6):411–6. [DOI: 10.1046/j.1365-263x.2003.00498.x] [PMID: 14984047]
23. Nisii F, Mazur M, De Nuccio C, Martucci C, Spuntarelli M, Labozzetta S, et al. Prevalence of molar incisor hypomineralization among school children in Rome, Italy. *Sci Rep*. 2022;12(1):7343. [DOI: 10.1038/s41598-022-10050-0] [PMID: 35513418]
24. Jälevik B. Prevalence and diagnosis of Molar-Incisor-Hypomineralisation (MIH): a systematic review. *Eur Arch Paediatr Dent*. 2010;11(2):59–64. [DOI: 10.1007/BF03262714] [PMID: 20403299]
25. Ivanović M, Živojinović tumba V, Marković D, Šindolić V. Treatment options for hypomineralized first permanent molars and incisors. *Serbian Dent J*. 2006;53:174–80. [DOI: 10.2298/SGS0603174I]
26. Elzein R, Chouery E, Abdel-Sater F, Bacho R, Ayoub F. Relation between molar-incisor hypomineralization (MIH) occurrence and war pollutants in bombarded regions: Epidemiological pilot study in Lebanon. *Niger J Clin Pract*. 2021;24(12):1808–13. [DOI: 10.4103/njcp.njcp_702_20] [PMID: 34889789]
27. Taylor KS, Mahtani KR, Aronson JK. Summarising good practice guidelines for data extraction for systematic reviews and meta-analysis. *BMJ Evid Based Med*. 2021;26(3):88–90. [DOI: 10.1136/bmjebm-2020-111651] [PMID: 33632720]
28. Cobourne MT, Williams A, Harrison M. National clinical guidelines for the extraction of first permanent molars in children. *Br Dent J*. 2014;217(11):643–8. [DOI: 10.1038/sj.bdj.2014.1053] [PMID: 25476643]

Table 1. Distribution of color, localization and size of lesions of molar incisor hypomineralization (MIH)-affected teeth that were not treated

Teeth with MIH		16	11	21	26	36	46	Total N (%)
Color	White	24	35	36	18	14	22	149 (87)
	Yellow	2	1	1	2	3	7	16 (9)
	Brown	1			1	2	3	7 (4)
Localization	Vestibular/oral	14	12	14	11	11	18	80 (46)
	Occlusal/incisal	13	24	23	10	8	14	92 (54)
Size	< 30%	24	35	37	18	17	28	172 (92)
	31–49%	3	1		3	2	4	13 (8)
	> 50%							

Table 2. Distribution of preventive and therapeutic procedures in a sample with and without molar incisor hypomineralization (MIH) on permanent first molars

Procedure	Tested teeth							
	16		26		36		46	
	without MIH (208)	with MIH (90)	without MIH (208)	with MIH (90)	without MIH (208)	with MIH (90)	without MIH (208)	with MIH (90)
Preventive and therapeutic method								
Fissure sealing	52 (25%)	13 (14.4%)		10 (9%)	52 (25%)	10 (9%)	60 (28.8%)	13 (14.4%)
Temporary fill				1 (1.1%)				
DMG Icon								
Endodontic therapy	2 (1%)		2 (1%)		1 (0.5%)	2 (1%)	1 (0.5%)	
Crowns inlay onlay veneers						1 (0.5%)		
Non-orthodontic extractions	4 (1.9%)	5 (5.6%)	2 (1%)	3 (3.3%)	3 (1.4%)	6 (2.9%)	3 (1.4%)	13 (14.4%)
Caries		3 (3.3%)	2 (1%)	4 (4.4%)				
Secondary caries	2 (1%)	4 (4.4%)	2 (1%)	4 (4.4%)	1 (0.5%)	2 (1%)	1 (0.5%)	4 (4.4%)

Table 3. Distribution of preventive and therapeutic procedures in a sample with and without molar incisor hypomineralization (MIH) on permanent upper central incisors

Procedure	Tested teeth			
	11		21	
Preventive and therapeutic method	without MIH (208)	with MIH (90)	without MIH (208)	with MIH (90)
Fissure sealing				
Temporary fill				
DMG Icon		1 (1.1%)		2 (1%)
Endodontic therapy	1 (0.5%)	4 (4.4%)		4 (4.4%)
Crowns inlay onlay veneers	1 (0.5%)	2 (1%)	1 (0.5%)	2 (1%)
Non-orthodontic extractions				
Caries	2 (1%)		1 (0.5%)	
Secondary caries				

Table 4. Distribution number of surfaces with fillings on teeth 16, 26, 36, 46, 11, 21 in the sample with and without molar incisor hypomineralization (MIH)

Tested teeth	16		26		36		46		11		21	
Number of surfaces with fillings	without MIH (208)	with MIH (90)	without MIH (208)	with MIH (90)	without MIH (208)	with MIH (90)	without MIH (208)	with MIH (90)	without MIH (208)	with MIH (90)	without MIH (208)	With MIH (90)
I	2 (1%)	16 (17.8%)	2 (1%)	21 (23.3%)	4 (1.9%)	21 (23.3%)	4 (1.9%)	13 (14.4%)	2 (1%)	2 (2.2%)	4 (1.9%)	4 (4.4%)
II	2 (1%)	21 (23.3%)	7 (3.7%)	20 (22.2%)	8 (3.8%)	17 (18.9%)	6 (2.9%)	18 (20%)		1 (1.1%)		1 (1.1%)
III	4 (1.9%)	12 (13.3%)	2 (1%)	13 (14.4%)		14 (15.5%)	4 (1.9%)	10 (11.1%)		2 (2.2%)		2 (2.2%)
IV	2 (1%)	4 (4.4%)		6 (6.7%)	1 (0.5%)	10 (11.1%)	1 (0.5%)	8 (8.9%)				

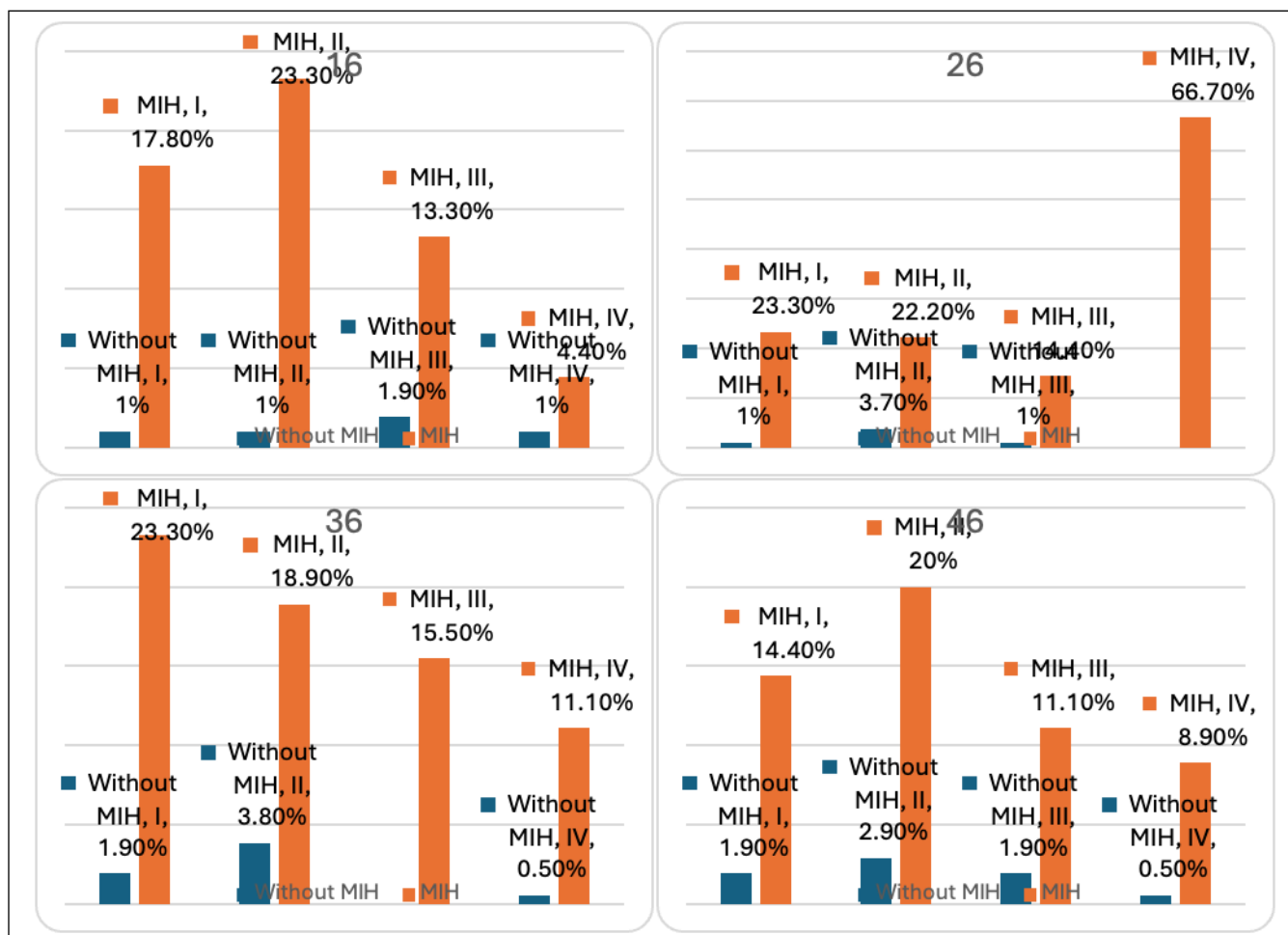


Figure 1. Distribution number of surfaces with fillings on the first permanent molars

APPENDIX

Informed Consent of the Patient

Researchers:

Prof. Dr. Mirjana Vujašković

Assoc. Prof. Dr. Milica Jovanović-Medojević

Student Dragana Jovanović

Student Katarina Teofilović

Study: Dental status of teeth affected by Molar-incisor hypomineralisation in students' population

With this document, we wish to inform you about the aim and significance of this research. Please read this document carefully, and if you have any additional questions, feel free to ask the researchers.

This study has been approved by the Ethics Committee of the Faculty of Dentistry, University of Belgrade, under the number

What is MIH?

Molar-incisor hypomineralization (MIH) is a developmental disorder that most commonly affects the first permanent molars and incisors. Healthy enamel is a highly mineralized hard dental tissue, composed of 96% inorganic materials, 1% organic materials, and 3% water. MIH is a qualitative enamel defect caused by reduced mineralization (lower percentages of apatite, calcium, and phosphate), making the enamel of these teeth dysfunctional due to higher protein and water content. Hypomineralized enamel has an altered color, is porous, prone to fractures, and more susceptible to rapid caries development.

What is the goal-aim of the study?

The goal of this study is to identify various etiological factors involved in the development of MIH, as well as to assess the application of different therapeutic methods and the survival rate of MIH-affected teeth in younger adult patients, specifically in the student population of the Faculty of Dentistry.

What data will be collected in this study?

Data will be collected on potential etiological factors that caused the development of dental hypomineralization, as well as the size, location, and color of such lesions. The type of therapy applied to the hypomineralized teeth will also be noted.

How will the data be handled?

At the end of the study, the results will be published in a scientific journal. In this article, no participant will be identifiable. Data will be preserved for an indefinite time.

CONSENT FORM

I am well informed about this study. I have thoroughly read this information. I had the opportunity to ask any questions regarding this research, and they were answered to my satisfaction. I agree to participate in this study. I understand that I can withdraw my consent at any time without any justification.

Name and last name:

Date of Birth:

Signature:

Date:

By signing this, I confirm that I have been properly informed, both orally and in writing, about the research.

Clinical research record (patients without MIH)

Subject number _____ Date of clinical examination _____

Dental record number _____

Patient's initials _____

Gender 1 - M 2 - F

Date of birth _____

Smoker: 1 - No 2 - Yes _____ cigarettes per day



Epidemiological dental record 2013.

Dental Status by Tooth Surfaces:

	18	17	16	15	14	13	12	11	21	22	23	24	25	26	27	28
Occ.																
Mes.																
Buc.																
Dis.																
Oral.																

	48	47	46	45	44	43	42	41	31	32	33	34	35	36	37	38
Occ.																
Mes.																
Buc.																
Dis.																
Oral.																

Parameters recorded on different tooth surfaces and entered into the Status:

- 0 = healthy
- 1 = cavity
- 2 = secondary cavity
- 3 = filling without caries
- 4 = missing due to caries
- 5 = missing for other reasons
- 6 = sealed fissures
- 7 = fixed prosthetic restorations/crowns, dental implants, veneers
- 8 = unerupted
- 9 = extracted for orthodontic reasons

Additional notes

Clinical research record (patients with MIH)

Subject number _____ Date of clinical examination _____

Dental record number _____

Patient's initials _____

Gender 1- M 2 - F

Date of birth _____

Smoker: 1- No 2 - Yes _____ cigarettes per day

**Epidemiological dental record 2013.****Dental Status by Tooth Surfaces:**

	18	17	16	15	14	13	12	11	21	22	23	24	25	26	27	28
Occ.																
Mes.																
Buc.																
Dis.																
Oral.																

	48	47	46	45	44	43	42	41	31	32	33	34	35	36	37	38
Occ.																
Mes.																
Buc.																
Dis.																
Oral.																

Parameters recorded on different tooth surfaces and entered into the Status:

- 0 = healthy
- 1 = cavity
- 2 = secondary cavity
- 3 = filling without caries
- 4 = missing due to caries
- 5 = missing for other reasons
- 6 = sealed fissures
- 7 = fixed prosthetic restorations/crowns, dental implants, veneers
- 8 = unerupted
- 9 = extracted for orthodontic reasons

Additional notes

Table 1. Color, localization, and size of lesions on MIH-affected teeth that have not been treated

Tooth affected by MIH		17	16	11	21	26	27	36	37	46	47
Color	White										
	Yellowish										
	Brownish										
Localisation	Vestibular/oral										
	Occlusal/incisal										
Size	< 30%										
	31-49%										
	> 50%										

Legend: Color (white, yellowish, or brownish discoloration), Localization (vestibular and oral surfaces and/or occlusal and incisal surfaces), Size of the lesion:

- < 30% of the tooth surface (mild defects)
- 31-49% of the tooth surface (moderate defects)
- 50% of the tooth surface (advanced defects)

Table 2. Treatment Methods for Hypomineralized Teeth

MIH affected tooth	16	11	21	26	36	46
Fissure sealing						
Temporary filling (perseverance of vitality or endodontic treatment)						
Composite or GIC filling (Black classification)						
Endodontic treatment (quality assessment)						
Crown, inlay, onlay						
Extraction						