



СРПСКИ АРХИВ
ЗА ЦЕЛОКУПНО ЛЕКАРСТВО
SERBIAN ARCHIVES
OF MEDICINE

Address: 1 Kraljice Natalije Street, Belgrade 11000, Serbia

+381 11 4092 776, Fax: +381 11 3348 653

E-mail: office@srpskiarhiv.rs, Web address: www.srpskiarhiv.rs

Paper Accepted*

ISSN Online 2406-0895

Original Article / Оригинални рад

Milka Gardašević¹, Milan Tešić^{2,*}, Aleksandra Petković Ćurčin³, Boban Labović⁴,
Zdravko Brković⁵

**Correlation of nerve conduction velocity and the number of newly created
axons in the regeneration of the facial nerve in rabbits after application of
platelet-rich plasma**

Корелација брзине нервне проводљивости и броја новостворених аксона у
регенерацији фацијалног нерва код кунића после примене
плазме богате тромбоцитима

¹Military Medical Academy, Clinic for maxillofacial surgery, Belgrade, Serbia;

²Požarevac General Hospital, Department for Ear, Nose, and Throat and Oral and Maxillofacial Surgery,
Požarevac, Serbia;

³Military Medical Academy, Institute for Medical Research, Belgrade, Serbia;

⁴Military Medical Academy, Clinic for Neurology, Belgrade, Serbia;

⁵University Clinical Center of Serbia, Clinic for pulmonology, Intensive Care Unit, Belgrade, Serbia

Received: July 11, 2023

Revised: November 16, 2023

Accepted: December 21, 2023

Online First: January 12, 2024

DOI: <https://doi.org/10.2298/SARH230711006G>

* **Accepted papers** are articles in press that have gone through due peer review process and have been accepted for publication by the Editorial Board of the *Serbian Archives of Medicine*. They have not yet been copy-edited and/or formatted in the publication house style, and the text may be changed before the final publication.

Although accepted papers do not yet have all the accompanying bibliographic details available, they can already be cited using the year of online publication and the DOI, as follows: the author's last name and initial of the first name, article title, journal title, online first publication month and year, and the DOI; e.g.: Petrović P, Jovanović J. The title of the article. Srp Arh Celok Lek. Online First, February 2017.

When the final article is assigned to volumes/issues of the journal, the Article in Press version will be removed and the final version will appear in the associated published volumes/issues of the journal. The date the article was made available online first will be carried over.

***Correspondence to:**

Milan TEŠIĆ

Požarevac General Hospital, Department for Ear, Nose, and Throat and Oral and Maxillofacial Surgery, Bratstva Jedinstva
135, Požarevac, Serbia

Email: dr.milantesic@gmail.com

Correlation of nerve conduction velocity and the number of newly created axons in the regeneration of the facial nerve in rabbits after application of platelet-rich plasma

Корелација брзине нервне проводљивости и броја новостворених аксона у регенерацији фацијалног нерва код кунића после примене плазме богате тромбоцитима

SUMMARY

Introduction/Objective Peripheral nerve lesions are frequent occurrences in both human and animal, leading to the emotional burden of disturbed facial expression and functional problems that have an impact on numerous activities of daily living.

This study aimed to investigate the nerve conduction velocity in newly created axons and the efficacy of locally applied platelet-rich plasma on the recovery of facial nerve functions after surgical transection and repairment.

Methods The study was conducted in three phases, over a period of six weeks, on 24 male chinchillas, weighing 2.5–3 kg and aged between three and four months. Depending on nerve repairment type, rabbits were assigned into four groups: group I (suture), group II (suture and fibrin sealant), group III (suture and platelet-rich plasma) and group IV (suture, fibrin sealant and platelet-rich plasma).

Results Most successful regeneration of the facial nerve after six weeks of nerve repair was achieved in groups III and IV in which, in addition to neurosuture, the nerve was treated with platelet-rich plasma, with or without the use of fibrin sealant (which had no role in the regeneration process), ($\alpha = 0.05$). The movements of the auricle followed the process of nerve recovery, and the number of newly created axons was directly proportional to the nerve conduction velocity ($p < 0.05$).

Conclusion Local application of platelet-rich plasma can accelerate the functional recovery of the facial nerve. Available growth factors and bioactive proteins present in platelet-rich plasma may have clinical implications for surgical treatment of patients after facial nerve injury.

Keywords: surgical repair; facial nerve; injuries; experimental animals; platelet-rich plasma

САЖЕТАК

Увод /Циљ Повреде периферних нерава су честа појава и код људи и код животиња, а које поред емоционалног терета поремећене експресије лица условљавају и функционалне проблеме који утичу на бројне активности свакодневног живота.

Циљ ове студије је био да испита брзину нервне проводљивости у новонасталим аксонима и ефикасност локалне примене плазме богате тромбоцитима на опоравак функција фацијалног нерва, после хируршке трансекције и репарације живца.

Метод Истраживање је спроведено у три фазе, у периоду од шест недеља, на 24. чинчиле, мушког пола, тежине од 2,5 до 3 кг и старости између три и четири месеца. Према типу репарације нерва, зечеви су распоређени у четири групе: I група (сутура), II група (сутура и фибрински лепак), III група (сутура и плазма богата тромбоцитима) и IV група (сутура, фибрински лепак и плазма богата тромбоцитима).

Резултати Најуспешнија регенерација фацијалног нерва после шест недеља од репарације, постигнута је у III и IV групи, у којима је поред неуросутуре живац био третиран плазмом богатом тромбоцитима, са или без употребе фибринског лепка (који није имао улогу у процесу зарастања), ($\alpha = 0,05$). Покрети аурикуле пратили су процес нервне регенерације, а број новостворених аксона директно је био пропорционалан брзини нервне проводљивости ($p < 0.05$).

Закључак Локална примена плазме богате тромбоцитима може убрзати функционални опоравак фацијалног живца. Доступни фактори раста и биоактивни протеини садржани у плазми богатој тромбоцитима могу имати клиничке импликације за хируршким лечењем пацијената после повреде фацијалног нерва.

Кључне речи: хируршка репарација; фацијални живац; повреде; лабораторијске животиње; плазма богата тромбоцитима

INTRODUCTION

The facial nerve innervates the facial muscles and conditions facial expression as an

important part of non-verbal communication and a means of emotions recognizing [1].

Facial nerve injuries accounts for 6–27% of all facial nerve palsies [2] and the most common causes of paralysis are tumor resections, basilar skull fractures, penetrating traumas and iatrogenic injures [1]. Beside of emotional burden of disturbed facial expression, facial nerve paralysis can cause functional problems that have an impact on numerous activities of daily living [1–4].

For surgeons, iatrogenic injuries of facial nerve are of particular importance, which most often occur in different types of surgery - parotid gland tumor resection, middle ear/temporomandibular surgery, mastoidectomy, resection of neural tumors, etc. [2, 3, 4]. Iatrogenic injuries can be the result of nerve traction, thermal lesion by electrocautery and partial or complete nerve transection [1]. Determining the extent of trauma is often challenging, and the most used method for describing the severity (degree) of injury is the Sunderland scale [5].

The Sunderland scale describes the five stages of damage peripheral nerve fibers - I neuropraxia, as the lightest form; II mild axonotmesis (interruption of the axon with myelin sheaths while preserving the connective tissue sheath); III moderate axonotmesis (interruption of both the axon and the endoneurium); IV severe axonotmesis (interruption of the endo and perineurium while preserving the epineurium) and V neurotmesis (partial or complete cutting of the nerve), [5]. Due to compression and nerve stretching during surgical procedures neuropraxia and axonotmesis are most often, but reversible in nature. If there is a partial and/or complete nerve transection, then we are talking about neurotmesis and consequent flaccid muscle paralysis, which is irreversible if the nerve is not repaired [1, 5].

In order to understand nerve damage classification scale, it is important to know the concept of Wallerian degeneration, which creates terms for nerve healing [5]. Process begins proximal to the site of injury (node of Ranvier) and continues distally to the neuromuscular

junction, with the injured axon regenerating approximately 1 mm in 24h [6]. In cases of complete nerve transection, degeneration lasts approximately 72 hours, and days or weeks after of contusion or peripheral nerve damage [7]. By the end of the third week, Schwann cells proliferate inside the basal membrane of the distal part of the axon and if there is a defect, they bridge it. After three weeks of injury, both the neuron and the distal part of the axon are capable of regeneration [1, 8]. Reduction of epineural degeneration and perineural scar formation by application of platelet-rich plasma (PRP) could lead to faster and more complete recovery [8]. These data impose the purpose question of use of biological growth factors obtained from PRP that would promote the regeneration process of damaged nerve [8, 9].

Therefore, this study aimed to investigate the nerve conduction velocity (NCV) in newly created axons and the efficacy of locally applied PRP on the recovery of facial nerve functions after surgical transection and repairment.

METHODS

Experimental design

This study was conducted at the Institute for Medical Research, Military Medical Academy in Belgrade, Serbia, from 2013 to 2015. Histological sections and analysis were done at the Institute for Pathological Anatomy, Faculty of Veterinary Medicine, University of Belgrade.

In our study a rabbit facial nerve model was used (its injury leads to asymmetry in the position and function of the auricle) for demonstrating of facial paralysis "in vivo" conditions. Each individual was in control of themselves.

The study was conducted in three phases, lasting six weeks, on 24 male chinchillas (*Oryctolagus cuniculus*), weighing 2.5–3 kg and aged between three and four months. Two weeks before and during the entire study, the animals were kept in the same environmental

conditions (individual cages, room temperature of $23 \pm 3^{\circ}\text{C}$, air humidity from 10% to 55% and a natural day/night cycle) with free access to food and water.

Phases of the study

First phase: Electroneurography (ENoG) and behavioral analysis

In the first phase of the study, ENoG was performed on both auricles (left and right) in order to determine the NCV of the facial nerve. Rabbits were anesthetized with a combination of ketamine (Ketamidol® 10% injection; 35mg/kg i.m.), acepromazine (Promace®; 0.1mg/kg i.m.) and atropine (Atropine®; 0.04mg/kg i.m.). Two monopolar needle electrodes were placed subcutaneously in symmetrical points of the innervation field of facial nerve (m. orbicularis oris and m.orbicularis oculi). A bipolar electrode was placed above the nerve trunk, and exposed to stimulation (evoked potential determines the speed of nerve conduction (m/s)).

During the study, once a week, the left (experimental) auricula movements were observed and analyzed by behavioral method and then compared with the mobility of the right (control) ear using a 5-point scale, ranging from 0 = no movement, 1 = barely detectable movements, 2 = less significant movements, 3 = larger asymmetric movements to 4 = symmetric movements [10].

Second Phase

In the second phase, the following procedures were carried out:

- Preparation of PRP and fibrin sealant (FS)

The preparation of PRP was made from 5 ml of blood taken from the ear vein of each rabbit, in test tubes with 0.4 ml of citrate, by the method of double centrifugation (Figure 1-A). From the 5 ml of blood taken, 0.3 ml of PRP was obtained, which with the addition of antifibrinolytics (tranexamic acid 1-5 mg per 0.5 ml cryoprecipitate) and calcium chloride (0.05 ml 10% CaCl_2 per 1 ml PRP) as an activator, was applied to the site of neurorrhaphy [11].

In addition to PRP, in groups II and IV, FS was also applied, as commercial preparation-

Beriplast® P Combi-Set 0.5/1 ml, [12].

- Surgical transection and nerve repairment

Preoperatively, the same dose of anesthetic was prepared as in the first phase, with the addition of general anesthesia with the local application of mepivacaine (Mepivacaine HCl 3%) with epinephrine in a dose of 1:100.000 at the incision site. In all rabbits, an identical surgical procedure was performed - identification of the trunk of the left facial nerve, surgical transection (before bifurcation), (Figure 1-B) and nerve repair. Depending on repairment type, rabbits were assigned into four groups: I group (suture), II group (suture and FS), III group (suture and PRP) and IV group (suture, FS and PRP). In all groups, the nerve ends were reconstructed with an epineural suture, nylon 9-0. Mapping of the repaired part of the nerve was performed with a thread of suture, cut to a length of 1 cm (Figure 1-C, 1-D). Skin was sutured with nylon 5-0.

After six weeks of repair, the following was done: ENoG of the left nerve (in order to determine NCV), harvesting of nerve specimen in mapped site for histological analysis (Figure 1-E), and nerve sampling from the right side for comparison.

Third Phase: Histological analysis of newly created axons and ENoG

In the third phase, a histological analysis of the samples of the repaired nerves was carried out and the proportionality between the number of newly created axons and NCV was determined.

Histological analysis

Surgical nerve specimens (5 mm in length) were fixed for 24 hours in 4% buffered formalin solution and then washed with water, dehydrated in alcohol of increasing concentration (70–100%) and lyophilized in xylene and embedded in paraffin. Paraffin blocks were cut with a microtome to a sample thickness of 3–5 µm. The sections were stained with hematoxylin and eosin, according to the manufacturer's instructions. Positive immunoreactivity

for S100 was recorded as nuclear staining. The preparations were examined with a light microscope at a magnification of $400\times$. The average number of axons was calculated by the average number of four randomized fields of each preparation and expressed numerically (Figure 2-A, 2-B). After six weeks of repairment, the NCV of left auricle was determined by ENoG and results were compared with the data from the first phase.

Statistical analysis

Data were analyzed in GraphPad Prism 9.0.0 statistical package, with significance $p<0.05$. Obtained values are presented as mean \pm standard deviation.

After testing the normality of the distribution of variables by groups, the T-test (for features with a normal distribution) was used to determine statistical significance. For non-parametric features, the Kruskal–Wallis test was used to evaluate the significance of group differences and Wilcoxon–Mann–Whitney test for the evaluation of intergroup differences (to determine with certainty which methods of nerve repairment had a statistically significant difference in the effects) [13, 14].

This study was approved by the institutional Ethics Committee (No. 5603/2, 11.03.2013., Faculty of Medicine, University of Belgrade)

RESULTS

The results are summarized on the basis of conducted ENoG examination of nerve velocity, observation scale of gross recovery of auricle movements and histological analysis of newly created axons. The most successful regeneration of the facial nerve after six weeks of repairment was achieved in groups III and IV in which, in addition to the neurosuture, the nerve was treated with PRP, with or without the use of FS (which had no benefit in the healing process). The movements of the auricle followed the process of nerve regeneration and the number of newly created axons was directly proportional to the NCV.

In the first phase of the experiment, the NCV of the experimental (left) and control (right) side was determined in all rabbits. On the radar diagram of the NCV effects, in the space of applied methods, it can be seen that the measured values of the left and right sides are almost identical (the differences are less than one m/s in all animals), which leads to the conclusion that there is no statistically significant difference in results (Figure 3-A).

In the third phase, the NCV on the left side was determined ENoG and the obtained values were compared with the results from the first phase. The analysis indicates that in groups I and II the NCV is significantly reduced compared to the same groups before the experiment, which concludes that the methods of applying the suture itself and FS are ineffective in the process of nerve regeneration. In groups III and IV, where PRP was applied, the results are similar and matches the values of the same groups before nerve transection. This showed the superiority of groups III and IV compared to groups I and II (Figure 3-B).

Comparison of group differences (six weeks after the nerve repairment) indicates that there are no significant differences in NCV between groups I and II (calculated test value; $W_b=39$). Intercomparison of group I with groups III and IV ($W_b=57$), showed higher NVC values at the upper critical threshold (at significant level $\alpha=0.05$ and equal sample size; $n_1=n_2=6$), so we can conclude that significantly better results are achieved with the applied reparation methods in the groups III and IV. Also, based on the test value ($W_b=57$), methods applied in groups III and IV are superior prior to the method in group II, while when comparing methods III and IV, the test value ($W_b=44.5$) was within the significance threshold interval, which means that there is no statistically significant difference in effects when comparing these two groups (Table 1).

During the experiment, once a week in all groups, the gross recovery of auricle movements on left side was observed, and compared with auricula movements on control side. Results were summarized based on a five-point scale. In groups III and IV the scale values

from left side were almost identical to values of control side at the end of six-week period, which speaks in favor of applied PRP method (Figure 3-C).

Six weeks after nerve repairment and animal sacrifice, previously mapped nerve specimens were taken from left and also from right side. Samples were histologically processed. Results showed that number of newly created axons in groups III and IV are almost equal to the number in control group (Figure 4-A). The FS used in groups II and IV showed inefficiency in reparation process in group II, while in the group IV (combined with PRP) effect was satisfactory and almost the same as in control group. This observation imposes that FS when used alone, has no effect in nerve healing process and priority is given to PRP. In addition to the increase in number of newly created axons, the histological analysis also revealed a greater proliferation of Schwann cells in groups III and IV (Table 2).

Summarizing the results of ENoG, it is shown that the growth of the number of newly created axons is directly proportional to the NCV, primarily observed in groups III and IV, which favors the application of PRP as the method of choice in nerve repairment (Figure 4-B).

DISCUSSION

Facial nerve injuries are complicated lesions and the treatment of consequential functional impairment and facial paralysis due to nerve injury continues to evolve, and an understanding of the various methods of injury assessment and therapy are critical to successful treatment [3]. In general, surgical procedures for the treatment of facial paralysis consist of primary neuroorrhaphy, interposition nerve grafting, nerve transfers, etc. [3]. Common to all these procedures is the primary neurosuture, which should be performed whenever possible [15], with the exception of long-term facial paralysis (approximately two years after injury) in which degeneration of the end motor plates has already followed and then reinnervation procedures are futile [16]. Additional procedures such as the application of PRP, botulinum

toxin and FS can be of great help in the process of nerve regeneration [3, 10, 12]. Such modalities have the potential to change the current treatment algorithm [3].

Numerous studies showing the effectiveness of PRP in tissue engineering are still at the experimental level [9, 17] and matches with the results of our study. Namely, analyzing the collected results with an emphasis on facial nerve regeneration, it was concluded that growth factors obtained from autologous PRP influenced the proliferation of axons in experimental animals and accelerated nerve recovery, whether PRP was used alone [18], in combination with other biological materials [19] or stem cells [20].

Growth factors obtained from PRP affect neuroregeneration processes by forming a microenvironment that leads to the proliferation of Schwann cells as the basic units in the axon synthesis process [8, 11, 14, 18–21]. It has been shown that the highest growth factor activity in the proliferation of Schwann cells is in the platelet concentrate, which is approximately $\leq 450\%$ of the number of platelets in whole blood [22]. Therefore, in our study, there is a high percentage of Schwann cell proliferation and a high number of newly created axons, groups III and IV, (Table 2) given that the concentration of platelets in PRP ($2.567.523 \pm 1.126.519 \times 10^3$ / μ l) was 4 times higher than in whole blood ($593.780 \pm 116.349 \times 10^3$ / μ l) of rabbits.

Regarding the effectiveness of using FS in peripheral nerve regeneration [10, 12, 23], it was found that FS alone, has no [10] or very little role in healing [23]. Such data from the literature are in accordance with our research, in which FS showed no benefit. As in the previously conducted meta-analysis, it can be concluded that combining FS with neurosuture only enables precise alignment of nerve fibers and their positioning, thus preventing dehiscence [12].

When it comes to the functional outcomes, in our research, it was noted that the movements of the auricle followed the process of nerve regeneration, and the number of newly created axons was directly proportional to the NCV. This was primarily determined in groups

III and IV, which blends with the research of Li et al., who confirmed the success of PRP application in the nerve regeneration after three weeks [18]. Cho et al. also support these facts with their research in which the best functional outcomes were achieved 4 to 6 weeks after surgery [24], while in the work of Şentürk et al., the best results were achieved after 5 weeks [25]. Also, in our previous research, where we compared the effects of PRP application on facial nerve recovery, in two time periods (6 and 10 weeks), we did not find significant differences in nerve recovery in the tenth week compared to the sixth week [26].

Finally, when we "transfer" the experimental results in the clinical environment, we can say that and patients and doctors alike must be patient, because the recovery of an injured nerve (whether it is a contusion or a complete interruption of the nerve) is slow, and the optimal elapsed time for improving functional outcomes is 4-6 weeks [14, 24–27], while complete nerve recovery is achieved within 6-8 months after the onset of symptoms [3, 28, 29]. Similar to previously published research, there are limitations of our study, i.e. the knowledge obtained in "in vivo" experiments must be "moved" to clinical settings [30], in order to obtain official confirmation of the success of the PRP technique in the process of facial nerve regeneration on patients. It should also be the continuation (next phase) of our study.

CONCLUSION

Electroneurographic tests performed before and six weeks after nerve repairment showed a significant improvement in NCV in groups III and IV, with the results indicating almost identical values of experimental and control groups III and IV. Histological analyses revealed that the number of axons in experimental groups III and IV is significantly higher when comparing with groups I and II, and that the number of new axons in experimental groups III and IV is close to the number of the same control groups.

The FS used in group IV had no effect on nerve healing process, because, when used

alone with suture it showed no benefit in group II, and as such has no significance in group IV. By objectifying the ear movements of experimental side, a higher score was confirmed in groups III and IV, which is another parameter that speaks in favor of the of PRP application.

Available growth factors and bioactive proteins present in platelet-rich plasma may have clinical implications for surgical treatment of patients after facial nerve injury. Clinical studies are currently based on a very small sample and further randomized studies with larger samples are necessary to better define the role of PRP in the facial nerve regeneration process.

ACKNOWLEDGMENTS

The authors would like to thank Dr. Dragan Đurđević, veterinarian, for his immense help in working with laboratory animals and Nikola Kostić, B.Sc. physicist, on graphics and images processing.

This manuscript is a part of the research conducted for the doctoral dissertation: Gardašević M. Evaluation of the effectiveness of the application of plasma enriched with platelets in the process of facial nerve regeneration in rabbits [dissertation]. Kragujevac: University of Kragujevac; 2023.

Conflict of interest: None declared.

REFERENCES

1. Mistry RK, Hohman MH, Al-Sayed AA. Facial Nerve Trauma. 2023 Mar 1. In: StatPearls. Treasure Island (FL): StatPearls Publishing; 2023. [PMID: 31971735]; <https://www.ncbi.nlm.nih.gov/books/NBK553095/>
2. Hohman MH, Bhama PK, Hadlock TA. Epidemiology of iatrogenic facial nerve injury: a decade of experience. *Laryngoscope*. 2014; 124(1):260-5. [DOI: 10.1002/lary.24117] [PMID: 23606475]
3. Gordin E, Lee TS, Ducic Y, Arnaoutakis D. Facial nerve trauma: Evaluation and considerations in management. *Craniomaxillofac Trauma Reconstr*. 2015; 8(1):1-13. [DOI: 10.1055/s-0034-1372522] [PMID: 25709748]
4. Zourntou SE, Makridis KG, Tsougos CI, Skoulakis C, Vlychou M, Vassion A. Facial nerve: A review of the anatomical, surgical landmarks and its iatrogenic injuries. *Injury*. 2021; 52(8):2038-48. [DOI: 10.1016/j.injury.2021.05.029] [PMID: 34074487]
5. Sunderland S. The anatomy and physiology of nerve injury. *Muscle Nerve*. 1990; 13(9):771-84. [DOI: 10.1002/mus.880130903] [PMID: 2233864]
6. Sulaiman W, Gordon T. Neurobiology of peripheral nerve injury, regeneration, and functional recovery: from bench top research to bedside application. *Ochsner J*. 2013; 13(1):100-8. [PMID: 23531634]
7. Gordon T. Electrical stimulation to enhance axon regeneration after peripheral nerve injuries in animal and humans. *Neurotherapeutics*. 2016; 13(2):295-310. [DOI: 10.1007/s13311-015-0415-1] [PMID: 26754579]
8. Wang S, Liu X, Wang Y. Evaluation of platelet-rich plasma therapy for peripheral nerve regeneration: A critical review of literature. *Front Bioeng Biotechnol*. 2022; 10:808248. [DOI: 10.3389/fbioe.2022.808248] [PMID: 35299637]
9. Alves R, Grimalt R. A review of platelet-rich plasma: History, biology, mechanism of action, and classification. *Skin Appendage Disord*. 2018; 4(1):18-24. [DOI: 10.1159/000477353] [PMID: 29457008]
10. Farrag TY, Lehar M, Verhaegen P, Carson KA, Byrne PJ. Effect of platelet-rich plasma and fibrin sealant on facial nerve regeneration in a rat model. *Laryngoscope*. 2007; 117(1):157-65. [DOI: 10.1097/01.mlg.0000249726.98801.77] [PMID: 17202946]
11. Sanchez M, Yoshioka T, Ortega M, Delgado D, Anitua E. Ultrasound-guided platelet-rich plasma injections for the treatment of common peroneal nerve palsy associated with multiple ligament injuries of the knee. *Knee Surg Sports Traumatol Arthrosc*. 2014; 22(5):1084-9. [DOI: 10.1007/s00167-013-2479-y] [PMID: 23519544]
12. Koopman JE, Duraku LS, de Jong T, de Vries RBM, Michiel Zuidam J, Hundepool CA. A systematic review and meta-analysis on the use of fibrin glue in peripheral nerve repair: Can we just glue it? *J Plast Reconstr Aesthet Surg*. 2022; 75(3):1018-33. [DOI: 10.1016/j.bjps.2022.01.007] [PMID: 35125308]
13. Fay MP, Proschan MA. Wilcoxon-Mann-Whitney or t test? On assumptions for hypothesis tests and multiple interpretations of decision rules. *Stat Surv*. 2010; 4:1-39. [DOI: 10.1214/09-SS051] [PMID: 20414472]
14. Bayrak AF, Olgun Y, Ozbakan A, Aktas S, Kulan CA, Kamaci G et al. The effect of insulin like growth factor - 1 on recovery of facial nerve crush injury. *Clin Exp Otorhinolaryngol*. 2017; 10(4):296-302. [DOI: 10.21053/ceo.2016.00997] [PMID: 28264555]
15. Terzis JK, Konofaos P. Nerve transfers in facial palsy. *Facial Plast Surg*. 2008; 24(2):177-93. [DOI: 10.1055/s-2008-1075833] [PMID: 18470829].
16. Chu EA, Byrne PJ. Treatment considerations in facial paralysis. *Facial Plast Surg*. 2008; 24(2):164-9. [DOI: 10.1055/s-2008-1075831] [PMID: 18470827]
17. Gardašević M, Živić M, Djurdjević D, Petković-Ćurčin A. Application of different techniques in facial nerve reconstruction on experimental models. *Acta Veterinaria-Beograd*. 2023; 73(2):155-70. [DOI: 10.2478/acve-2023-0012] [UDK: 616.833.17-001]
18. Li L, Cai J, Yuan Y, Mao Y, Xu L, Han Y, et al. Platelet-rich plasma can release nutrient factors to promote facial nerve crush injury recovery in rats. *Saudi Med J*. 2019; 40(12):1209-17. [DOI: 10.15537/smj.2019.12.24747] [PMID: 31828272]
19. Şahin MM, Cayonu M, Dinc SK, Ozkocer E, İlhan M, Uzunoğlu E, et al. Effect of chitosan and platelet-rich plasma on facial nerve regeneration in an animal model. *Eur Arch Otorhinolaryngol*. 2022; 279(2):987-94. [DOI: 10.1007/s00405-021-06859-6] [PMID: 33956207]
20. Sun Y, Yhang R, Mao X, Zhang M. [Research of acellular xenogenic nerve combined with adipose-derived stem cells and platelet rich plasma in repair of rabbit facial nerve injury]. *Zhongguo Xiu Fu Chong Jian Wai Ke Za Zhi*. 2018; 32(6):736-44. [DOI: 10.7507/1002-1892.201711079] [PMID: 29905054]
21. Hu B, Zhang H, Xu M, Li L, Wu M, Zhang S, et al. Delivery of basic fibroblast growth factor through an in situ formatting smart hydrogel activates autophagy in Schwann cells and improves facial nerves generation via the PAK-1 signaling pathway. *Front Pharmacol*. 2022; 13:778680. [DOI: 10.3389/fphar.2022.778680] [PMID: 35431972]

22. Zhu Y, Jin Z, Wang J, Chen S, Hu Y, Reu L, et al. Ultrasound guided platelet-rich plasma injection and multimodality ultrasound examination of peripheral nerve crush injury. *NPJ Regen Med.* 2020; 5(1):21. [DOI: 10.1038/s41536-020-00101-3] [PMID: 33298932]
23. Benfield C, Isaacs J, Mallu S, Kurtz C, Smith M. Comparison of nylon suture versus 2 fibrin glue products for delayed nerve coaptation in an animal model. *J Hand Surg Am.* 2021; 46(2):119-15. [DOI: 10.1016/j.jhsa.2020.09.021] [PMID: 33261957]
24. Cho HH, Jang S, Lee SC, Jeong HS, Park JS, Han JY, et al. Effect of neural-induced mesenchymal stem cells and platelet-rich plasma on facial nerve regeneration in an acute nerve injury model. *Laryngoscope.* 2010; 120(5):907-13. [DOI: 10.1002/lary.20860] [PMID: 20422684]
25. Şentürk F, Bahadır O, Aktaş O, Bıyık AF, Ercan E. Effects of titanium prepared platelet rich fibrin on facial nerve regeneration: an experimental study. *Braz J Otorhinolaryngol.* 2022; 88(6):867-74. [DOI: 10.1016/j.bjorl.2020.11.014] [PMID: 33441277]
26. Gardašević MF, Petković-Čurčin A, Vojvodić DV, Marjanović U, Djurdjević D, Jović S, et al. Assessment of efficacy of platelet-rich plasma application in regeneration of the facial nerve in rabbits. *Vojnosanit Pregl.* 2023; 80(4):349-55. [DOI: 10.2298/VSP171208048G] [UDK: 616.833.17-089-085.382-092.9]
27. Yadav A, Ramasamy TS, Lin SC, Chen SH, Lu J, Liu YH, et al. Autologous platelet-rich plasma growth factor reduces M1 macrophages and modulates inflammatory microenvironments to promote sciatic nerve regeneration. *Biomedicines.* 2022; 10(8):1991. [DOI: 10.3390/biomedicines10081991] [PMID: 36009539]
28. Banks CA, Knox C, Hunter DA, Mackinnan SE, Hohman MH, Hadlock TA. Long-term functional recovery after facial nerve transection and repair in the rat. *J Reconstr Microsurg.* 2015; 31(3):210-6. [DOI: 10.1055/s-0034-1395940] [PMID: 25629206]
29. Fliss E, Yanko R, Zaretski A, Tulchinsky R, Arad E, Kedar DJ, et al. Facial nerve repair following acute nerve injury. *Arch Plast Surg.* 2022; 49(4):501-9. [DOI: 10.1055/s-0042-1751105] [PMID: 35919546]
30. Ricci E, Riva G, Dagna F, Cavalot AL. The use of platelet-rich plasma gel in superficial parotidectomy. *Acta Otorhinolaryngol Ital.* 2019; 39(6):363-66. [DOI: 10.14639/0392-100X-2093] [PMID: 30933175]

Table 1. Simultaneous comparison of groups (methods) I, II, III, and IV in third phase of the experiment

Kruskal-Wallis M1 = M2 = M3 = M4 M1 # M2 # M3 # M4 significant level ($\alpha = 0.05$)	Nerve conduction velocity					
	Wilcoxon Wa; significant level ($\alpha = 0.05$); n1 = n2 = 6, significant interval (28, 50)					
	I-II	I-III	I-IV	II-III	II-IV	III-IV
	H0: M2 = M1 H1: M2 > M1	H0: M3 = M1 H1: M3 > M1	H0: M4 = M1 H1: M4 > M1	H0: M3 = M2 H1: M3 > M2	H0: M4 = M2 H1: M4 > M2	H0: M4 = M3 H1: M4 > M3
H = 17.878	Wb = 39	Wb = 57	Wb = 57	Wb = 57	Wb = 57	Wb = 44.5
$H_V = 3, \alpha < 7.815$	$28 < Wb < 50$	$Wb > 50$	$Wb > 50$	$Wb > 50$	$Wb > 50$	$28 < Wb < 50$
*		*	*	*	*	

M – applied method (group); H, Hv – test value; H0 – hypothesis 0; H1 – hypothesis 1; Wb – test score;

* – statistically significant difference

Table 2. Comparative overview of histological characteristics of the damaged nerve reparation six weeks after intervention

Histological characteristics	Groups			
	I	II	III	IV
Number of newly created axons	22 ^a	26.5 ^b	86.5	87
Number of Schwann cells	10 ^b	12 ^b	83.5	82

Statistical significance: ^a $p < 0.05$ vs. Groups II, III, and IV (Kruskal–Wallis and Mann–Whitney–Wilcoxon test); ^b $p < 0.05$ vs. Groups III and IV (Kruskal–Wallis and Mann–Whitney–Wilcoxon test)

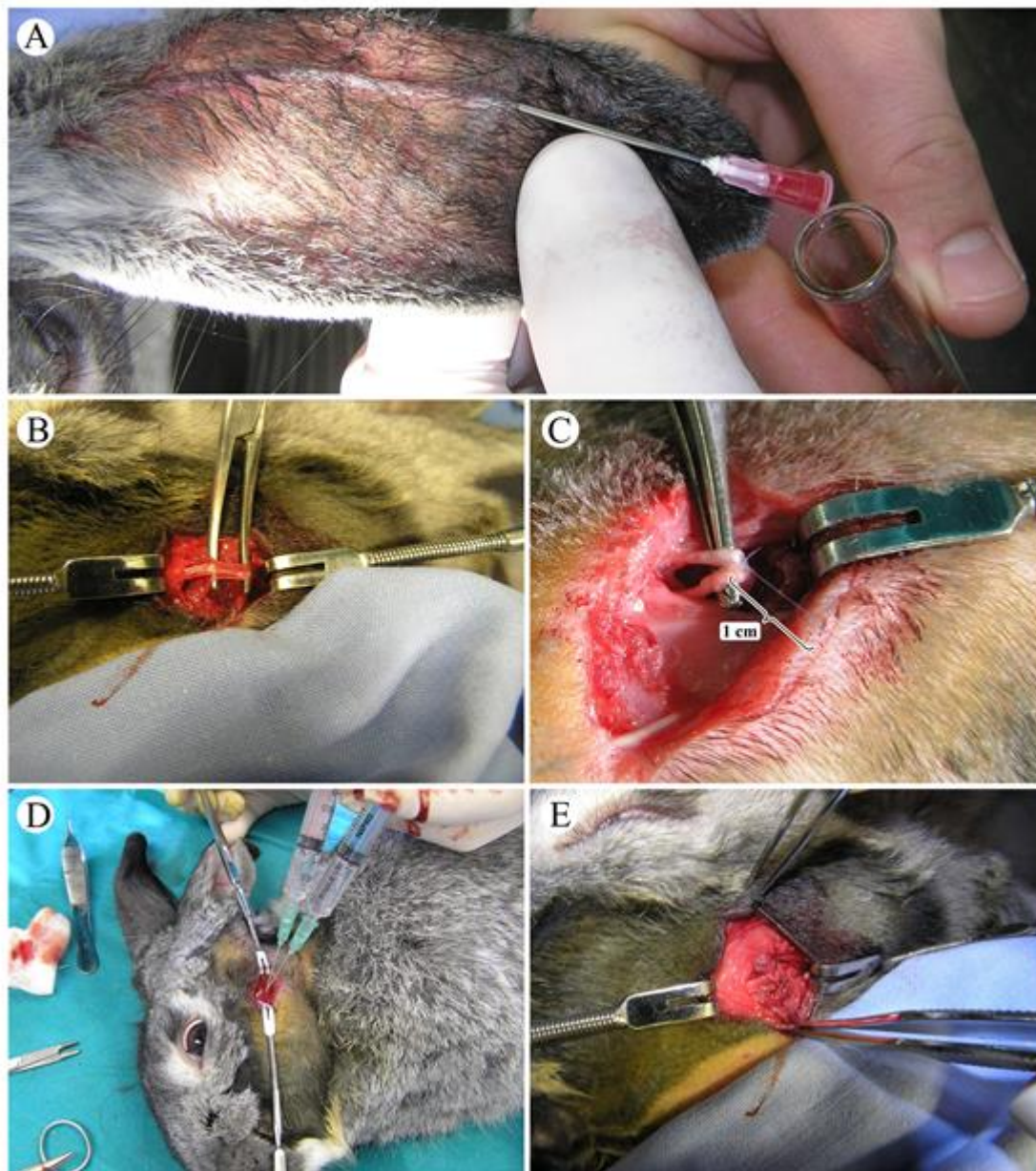


Figure 1. Preparation of platelet-rich plasma and surgical procedures: A – blood collection process: venipuncture; B – identification of facial nerve trunk; C – suture and nerve mapping; D – application of platelet-rich plasma; E – site of nerve sampling (harvesting) for histological analysis

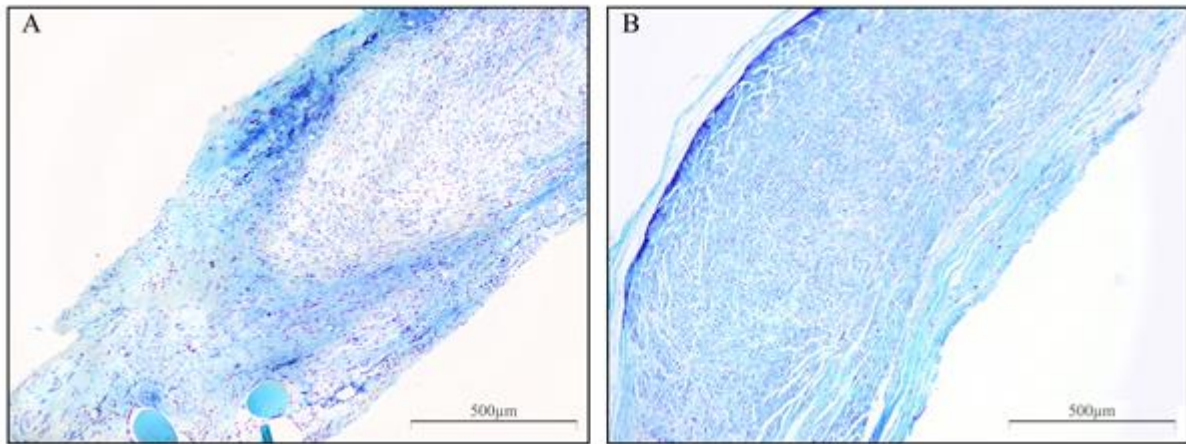


Figure 2. Histological analysis of repaired nerve: A – Group I (suture); B – Group IV (suture + fibrin sealant + platelet-rich plasma); note a greater proliferation of Schwann cells in group IV

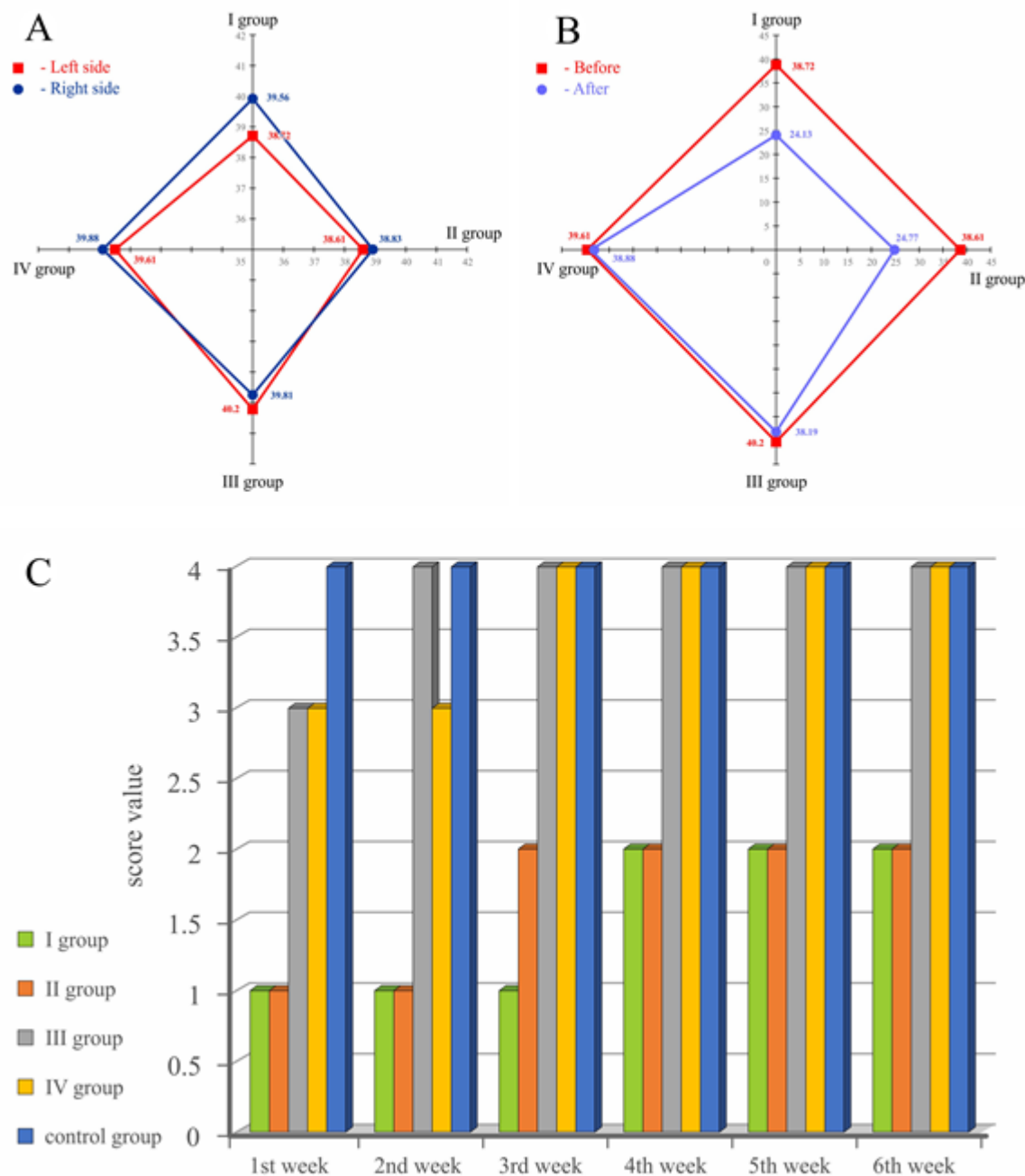


Figure 3. Comparison of nerve conduction velocity (NCV) and gross recovery of auricular movements between groups; A – radar diagram of NCV effects of the experimental (left) and control (right) side of auricle in first phase; B – radar diagram of NCV effects before and six weeks after nerve repair (first and third phase) of the left side; C – score dependency (0–4) of the control (right) and experimental (left) side of auricular movements during six weeks period

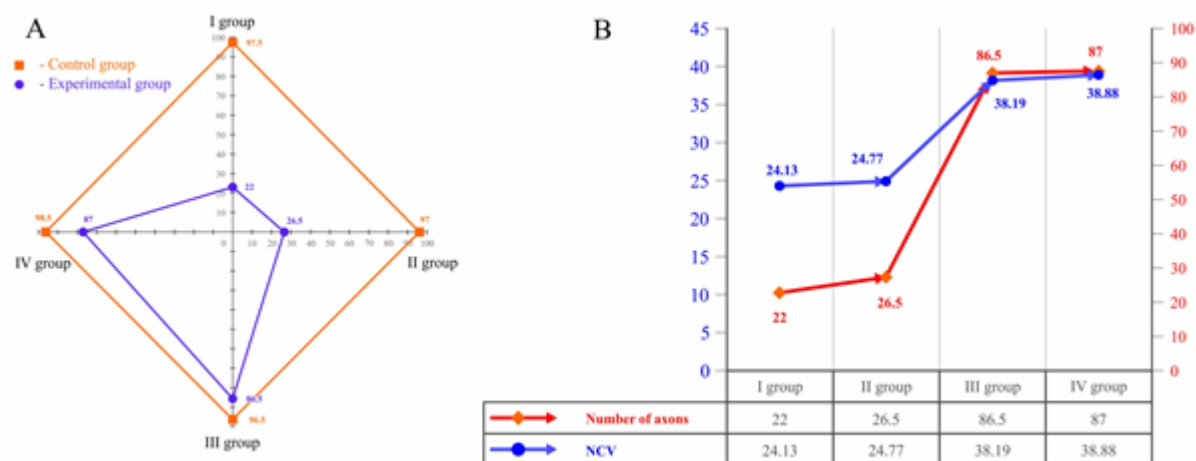


Figure 4. Number of newly created axons and their's velocity potential after nerve repair; A – radar diagram comparison of the number of newly created axons between the control and experimental group; B – action potential velocity of axons between groups (I–IV)