

## REVIEW ARTICLE / ПРЕГЛЕД ЛИТЕРАТУРЕ

# Fractures of the acetabulum – surgical treatment and complications

Saša Milenković<sup>1,2</sup>, Milan Mitković<sup>1,2</sup>, Milorad Mitković<sup>1</sup>, Predrag Stojiljković<sup>1,2</sup><sup>1</sup>University of Niš, Faculty of Medicine, Niš, Serbia;<sup>2</sup>Clinical Centre of Niš, Clinic for Orthopaedic Surgery and Traumatology, Niš, Serbia**SUMMARY**

Acetabular fractures represent severe injuries that mostly occur in car accidents, or after falling from greater heights, most often in the working male population. Acetabular fractures are present in our clinical practice and their treatment requires good education and surgical training. Surgical experience is one of the prerequisites for achieving good treatment results, since these fractures are accompanied by numerous complications. In order to acquire knowledge and skills in this field of surgery, it is necessary to have a national center for education at one of the medical faculties in Serbia. All dislocated acetabular fractures ( $\geq 2$  mm) require early surgery, anatomical reduction, and stable internal fixation of acetabular fracture. Acetabular fracture-dislocation requires urgent reduction of the dislocated femoral head. The anatomic reduction of the fracture is related to the time of definitive bone fixation of the fracture. Fourteen days after the fracture, anatomic reduction is more difficult to achieve. In addition to the factors that positively affect the results of treatment, there are negative factors as well, which result in poor outcomes. They are directly correlated to the initial trauma that occurs at the time of injury. Fracture comminution, large dislocation ( $> 20$  mm), injury of the femoral head, posterior dislocation of the hip, impaction, traumatic or iatrogenic sciatic nerve palsy – these are all factors that negatively affect the outcome and are responsible for complications, as opposed to positive factors.

**Keywords:** acetabulum; fractures; surgical treatment; complications

**INTRODUCTION**

The poor outcomes of conservative treatment of acetabular fractures, back in the 1950s, led Letournel and Judet [1] to embark on a new era of surgical treatment. The principles of open reduction and stable internal fixation that they founded are still valid today, despite the great advances in orthopedics and traumatology. Acetabular fractures are severe, occurring in young, working, more frequently male population, in car accidents or in falls from heights [2]. The incidence of acetabular fractures is about three fractures per 100,000 patients per year [3]. The city of Niš is the largest city of the Nišava District with a population of about 350,000, over 2,000,000 inhabitants of Southern and Eastern Serbia gravitate towards it. It has a tertiary institution and an incidence of acetabular fractures of about three fractures per 100,000 patients per year. Considering the gravitational and treatable population at the Clinical Centre of Niš, the Clinic for Orthopaedic Surgery and Traumatology has made a significant step forward with regard to the modern approach and treatment of acetabular fractures. In younger patients, these fractures are usually caused by a strong axial force acting through the femoral shaft or a direct force acting through a greater trochanter. In the elderly, acetabular fractures can cause low-energy trauma due to the presence of osteoporosis. Acetabular fractures, primarily dislocated ( $> 2$  mm),

are treated surgically with open fracture reduction and stable internal fixation with acetabulum reconstructive plates/screws. The complications that accompany these fractures are numerous – traumatic sciatic nerve injury, iatrogenic sciatic nerve injury, infection, revision osteosynthesis, deep vein thrombosis (DVT), heterotopic ossification (HO) – Brooker I–IV, femoral head osteonecrosis, secondary osteoarthritis (OA) of the hip [4]. Some of these complications require later revision surgery, which is reflected in total hip replacement [5]. Due to all of the above and the complexity of acetabular surgery, constant education of the surgeon and surgical experience are required to achieve excellent and good outcomes, as it has been shown that surgical experience is an important factor directly correlated to achieving excellent and good outcomes [6].

**CLINICAL ANATOMY OF THE ACETABULUM**

The clinical anatomy of the acetabulum divides the acetabulum into the anterior and posterior columns, which are arranged in the inverted “Y” shape. The anterior column is the anterior part of the iliac bone that extends to the pubic bone. It contains the anterior part and the edge of the iliac wing, the pelvic edge, the anterior wall of the acetabulum, and the upper branch of the pubic bone. The posterior column consists

**Received • Примљено:**

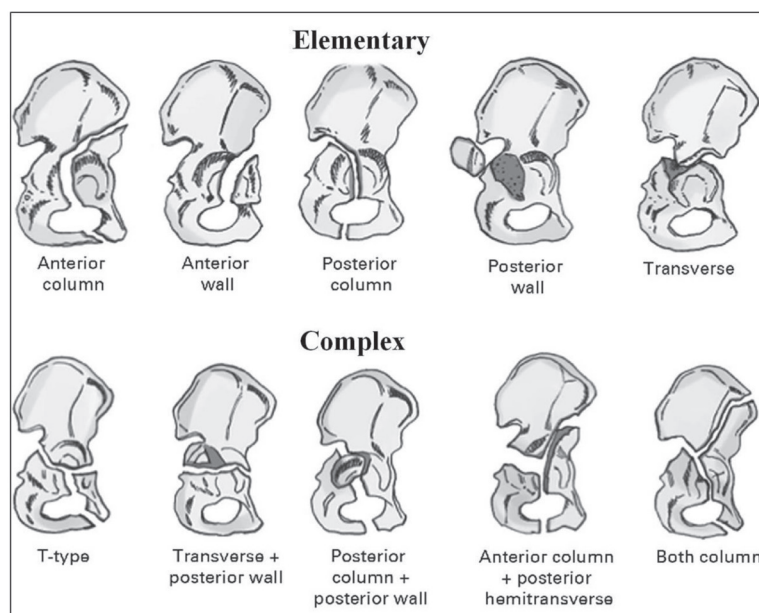
April 12, 2020

**Accepted • Прихваћено:**

November 13, 2020

**Online first:** November 18, 2020**Correspondence to:**

Saša MILENKOVIĆ  
University of Niš  
Faculty of Medicine  
Clinic for Orthopaedic Surgery  
and Traumatology  
Clinical Centre of Niš  
18000 Niš, Serbia  
[sasaortoped@gmail.com](mailto:sasaortoped@gmail.com)



**Figure 1.** Classification of acetabular fractures according to Letournel and Judet [9]

of parts of the iliac and ischiadic bones, large and small ischiadic notches, posterior wall of the acetabulum, most of the quadrilateral surface, and ischiadic tuberositas. The upper part of the acetabulum, through which load forces are transmitted, is called the roof of the acetabulum. The vertical line that runs through the center of the femoral head and the line that goes through the fracture of the acetabulum make an angle called the “acetabular roof angle” [4].

### MECHANISM OF INJURY

Acetabular fractures are caused by the action of an axial force through the femoral shaft. The type of fracture of the acetabulum, its anterior or posterior structure, depends on the position of the femoral head at the time of impact into the acetabulum. Another way of creating an acetabular fracture is through the action of a direct force over a greater trochanter when the quadrilateral surface of the acetabulum (central luxation) is most commonly fractured [4].

### CLASSIFICATION OF ACETABULAR FRACTURES

The pioneers of acetabular surgery, Letournel and Judet [1], represented a classification that stood the test of time, and is still valid and applicable worldwide. According to this classification, acetabular fractures are divided into elementary and complex [7, 8, 9] (Figure 1).

### RADIOLOGIC EVALUATION

Our teachers, our teachers’ teachers used clinical examination and radiographic diagnostics, which included radiography in the antero-posterior position and two oblique Judet views (iliac oblique and obturator oblique). These

three projections were sufficient for the experienced surgeon to evaluate the stability of the fracture and determine the surgical approach during surgical treatment. Modern diagnostics in the form of computed tomography (CT) and 3D-CT allows the surgeon to see a clear three-dimensional image of the acetabulum that will determine the type of surgical approach, will allow him to see the size of the bone fragments, the degree of dislocation, comminution, impaction, the presence of loose bodies in the acetabulum [10, 11].

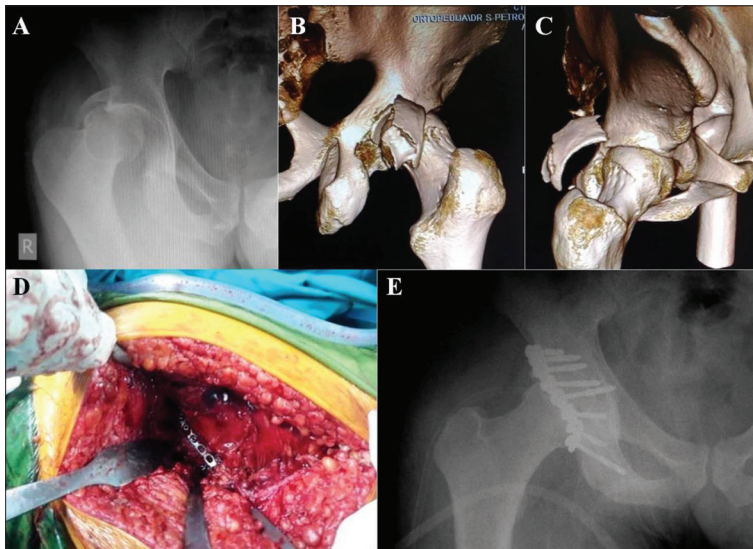
### TREATMENT OF ACETABULAR FRACTURE

Undislocated ( $\leq 2$  mm), stable acetabular fractures can be treated conservatively. The question is whether skeletal traction is required in this treatment. The authors believe that skeletal traction is not necessary in undislocated acetabular fractures; the patient can walk without weight-bearing for six to eight weeks. Partial to full weight-bearing is allowed after this period, with rehabilitation. In patients with dislocated fractures who cannot undergo surgical treatment, closed reduction via skeletal traction with bed rest for the initial six to eight weeks may be used. Dislocated ( $\geq 2$  mm) and unstable acetabular fractures are treated surgically – by open reduction and stable internal fixation, or by percutaneous minimally invasive surgery, which require experience and intraoperative fluoroscopy. In order to achieve satisfactory functional and radiographic results, it is necessary to achieve acetabular congruence and anatomic reduction, stable internal fixation. Early activation and rehabilitation is required, without weight-bearing from six to eight weeks after surgery, when partial weight-bearing begins to increase and progressively increases over the next few weeks, until full weight-bearing is achieved [6, 12, 13, 14]. The most common surgical approaches used for surgical open reduction and internal fixation are anterior ilio-inguinal, anterior ilio-femoral, posterior Kocher–Langenbeck, combined anterior and posterior, modified Stoppa, anterior pararectal surgical approach (Figures 2–5). Understanding of these surgical approaches requires training, continuous education and raises the question of the existence of a national educational center, because, regardless of the number of orthopedic surgeons, there are very few who are familiar with this pathology.

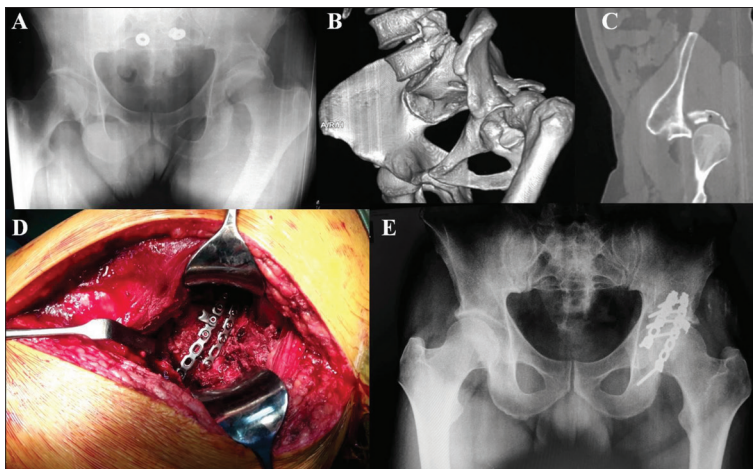
### PRIMARY TOTAL HIP REPLACEMENT AFTER ACETABULAR FRACTURE

There is much controversy regarding primary total hip replacement in fresh acetabular fractures. The issue of “fixed or replaced” is always the question, especially in older patients. In any case, primary total hip replacement

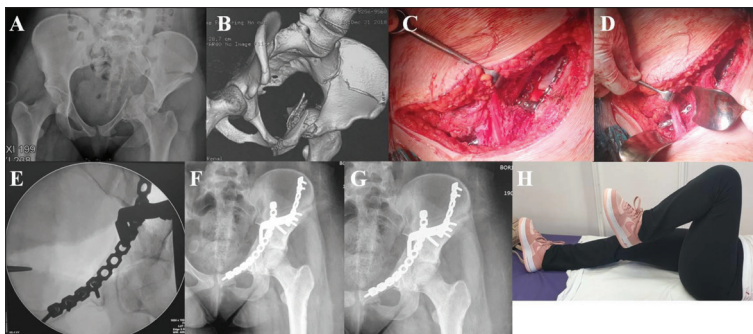




**Figure 2.** Open reduction and internal fixation of acetabular fracture-dislocation; A: X-ray after the injury; B, C: 3D computed tomography scan after reduction of dislocated femoral head shows a dislocated posterior wall acetabular fracture; D: intraoperative view after fracture fixation by Kocher–Langenbeck surgical approach; E: X-ray after the surgery



**Figure 3.** Open reduction and stable internal fixation of acetabular fracture-dislocation; A: X-ray after the injury; B: 3D computed tomography (CT) view shows fracture of the posterior wall of the acetabulum and posterior hip dislocation; C: sagittal CT view shows posterior acetabular fracture-dislocation; D: intraoperative view after fracture fixation; E: postoperative X-ray



**Figure 4.** T-fracture of the acetabulum associated with iliac bone fracture in a 20-year-old patient; A: X-ray after the injury; B: 3D computed tomography view; C, D: intraoperative views after fracture fixation through the anterior ilio-inguinal surgical approach; E: intraoperative fluoroscopy; F: postoperative X-ray; G: X-ray six months after the injury; H: functional outcome, after six months post-injury was excellent

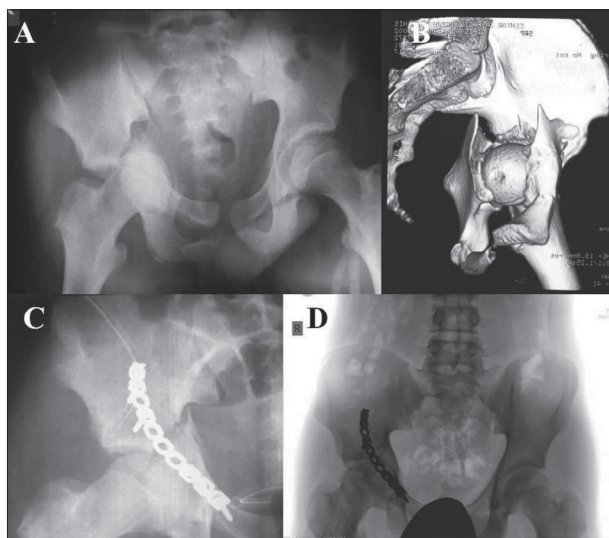
is used in the treatment of fresh acetabular fractures, and numerous complications that accompany this surgery are described. Indications are set on a case-by-case basis and recommended for individually selected cases [15, 16, 17] (Figure 6).

## COMPLICATIONS AFTER ACETABULAR SURGERY

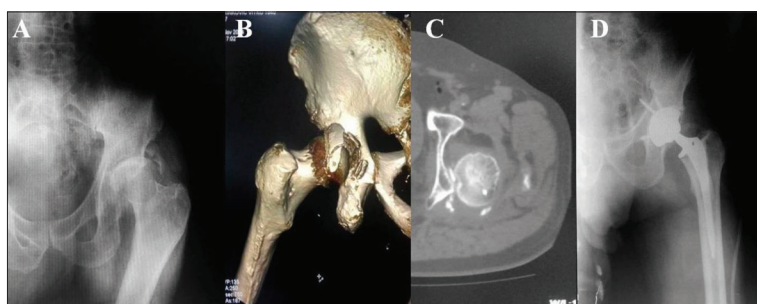
Based on clinical practice and contemporary literature, the most common complications accompanying the surgical treatment of acetabular fractures are the following: traumatic and iatrogenic sciatic nerve palsy, thromboembolic complications (DVT) and pulmonary thromboembolism (PE), infection, loss of osteosynthesis after surgical fixation of the fracture, HO, femoral head osteonecrosis, secondary OA of the hip [4, 6, 18, 19].

## TRAUMATIC AND IATROGENIC SCIATIC NERVE PALSY

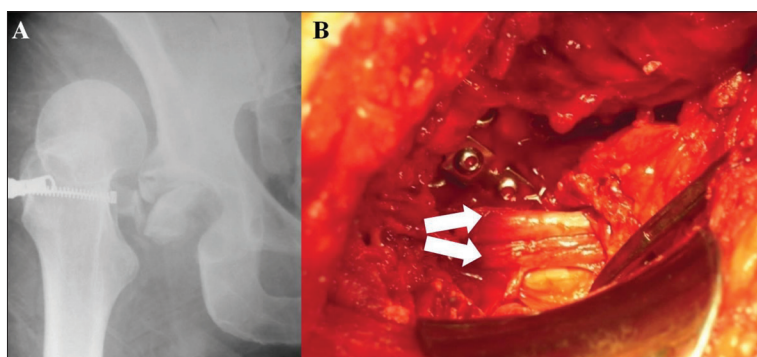
Contemporary literature describes traumatic and iatrogenic sciatic nerve palsy or its peroneal division [20, 21]. The injuries of the peroneal division of the sciatic nerve are most common. These injuries are more common in the posterior hip dislocation associated with acetabular fracture, caused by the pressure of the dislocated femoral head or the pressure of the bone fragment from the posterior wall of the acetabulum at the time of injury. According to Bogdan et al. [22], out of 137 patients with acetabular fractures, 57% had traumatic nerve injury. Immediate reduction of dislocated hip and early fixation of the acetabulum reduce pressure on the nerve and allow better functional recovery of the nerve. In addition to the traumatic lesion, iatrogenic injuries to the sciatic nerve have also been described. Iatrogenic injury can be caused by rough surgical work, manipulations during surgery, careless handling of elevators and retractors, the presence of a postoperative hematoma. In order to prevent iatrogenic injury to the sciatic nerve, knee flexion during surgery is necessary to relieve the nerve, clear identification and protection of the nerve during surgery, special attention should be paid to the presence of possible anatomic variations of the sciatic nerve (Figure 7), postoperative drainage is required. Haidukewych et al. [23] reported an incidence of 7.9% of iatrogenic sciatic nerve injuries after acetabular surgery.



**Figure 5.** T-fracture of the acetabulum in a 14-year-old patient; in such fractures, surgical reduction and fracture fixation is usually performed with a combined anterior and posterior Kocher–Langenbeck approach in one act or staging surgery at intervals of two to three days; given the patient's age and fracture reduction achieved, we used only anterior approach and further treatment was continued with cutaneous traction for three weeks; A: X-ray after the injury; B: 3D computed tomography view after the injury; C: X-ray after fracture fixation through the anterior ilio-inguinal approach; D: X-ray after six months



**Figure 6.** Primary total hip replacement after fresh posterior wall acetabular fracture with posterior hip dislocation in a 74-year-old patient; A: X-ray after the injury; B: 3D computed tomography (CT) view; C: sagittal CT view shows posterior hip dislocation with a fracture of the posterior wall of the acetabulum; D: X-ray after primary total hip replacement



**Figure 7.** Anatomical variation of the sciatic nerve shows a sciatic nerve high division in the gluteal region, in a 48-year-old patient with a comminuted posterior wall acetabular fracture associated with posterior hip dislocation and traumatic palsy of sciatic nerve; A: X-ray after the injury; B: intraoperative view after acetabular fracture fixation; the arrows show the sciatic nerve high division

## THROMBOEMBOLIC COMPLICATIONS (DVT) AND PULMONARY THROMBOEMBOLISM

Post-traumatic and postoperative thromboembolism is a significant problem in patients with acetabular fractures. These complications accompany acetabular surgery despite thromboprophylaxis, especially in elderly patients over 60 years of age, patients with increased risk for DVT, complex fractures, and delayed osteosynthesis of acetabular fractures after two weeks [24]. According to Wang et al. [25], in a series of 110 patients with pelvic and acetabular fractures, 29.09% had DVT, three patients had PE. In addition, the incidence of DVT in patients with acetabular fractures was significantly higher than that of patients with pelvic fractures. According to Althuwaykh et al. [26], the incidence in a series of 404 patients with acetabular fracture was 5%, while 1.7% of the patients had PE. Despite the prophylaxis, the prevalence of post-traumatic and postoperative thromboembolism is approximately 11% [27].

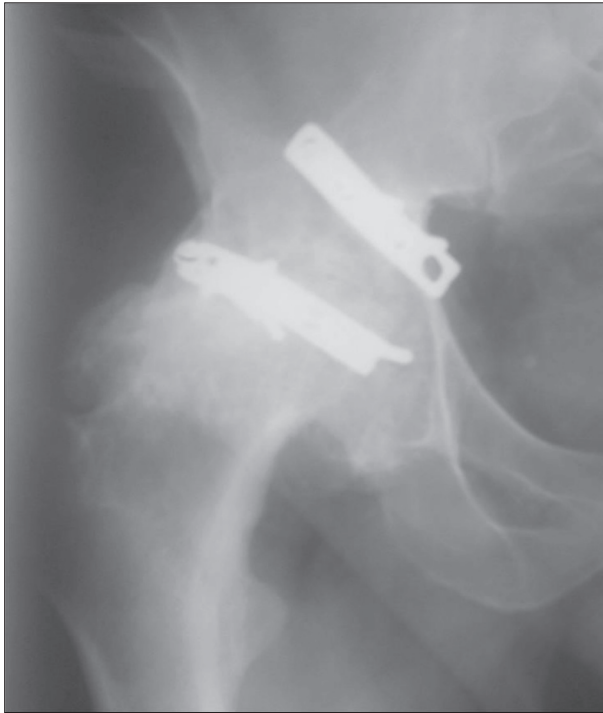## INFECTIONS AND REVISION SURGERY

Early revision surgery is rarely used in cases of loss of fixation or surgical debridement and irrigation in early infections after osteosynthesis of acetabular fractures. Infections, superficial or deep, are rare due to good vascularization but are present and should be considered. Postoperatively, antibiotic prophylaxis is required until postoperative drainage is extracted. According to Ding et al. [28], 7% of patients required revision surgery due to debridement and irrigation after wound infection; according to Iqbal et al. [29], 5.4% required revision. Similar data was reported by Suzuki et al. [30]. According to Negrin and Seligson [31], revision surgery due to secondary loss of reduction, seroma/hematoma, and wound infection was in 6%. According to Giannoudis et al. [32], the incidence of infection after surgical treatment of acetabular fractures was 4.4%.

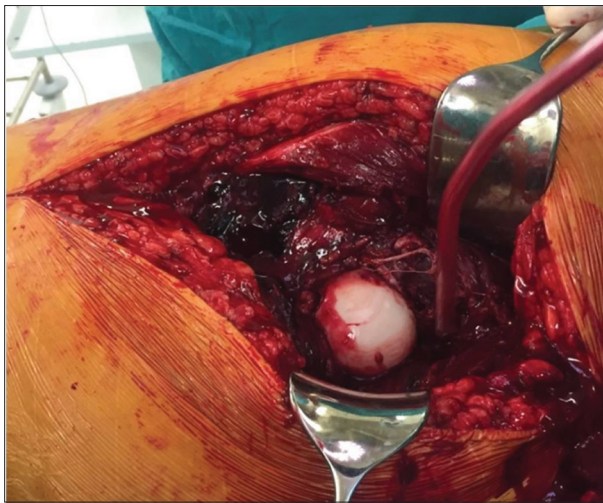
## HETEROTOPIC OSSIFICATION

HO is also clearly described and it accompanies this type of surgery [33]. In many centers, indomethacin or low-dose radiotherapy is administered as prophylaxis to prevent the development of HO [34]. In a meta-analysis of 2394 displaced fractures by Giannoudis et al. [32], the HO incidence was 25.6% with Brooker grade III or IV at 5.7%.





**Figure 8.** Hip ankylosis in a 73-year-old patient, caused by secondary osteoarthritis of the hip; the acetabular surgery was done at another institution 39 years previously



**Figure 9.** Intraoperative view during the open reduction of a dislocated hip in a 55-year-old patient with the posterior wall acetabular fracture associated with posterior hip dislocation

### FEMORAL HEAD OSTEO NECROSIS

This complication can occur several months to several years after acetabular fracture. As a result of the femoral head osteonecrosis, fragmentation and collapse of the femoral head can occur, which will cause secondary OA of the hip. Although it is sometimes difficult to diagnostically differentiate the OA and osteonecrosis, it is not uncommon to see both intraoperatively. Different authors describe the different incidence of the femoral head osteonecrosis. According to Pavelka et al. [35], 11.7% of patients developed the femoral head osteonecrosis. The fact is that the femoral head osteonecrosis is much more common in

acetabular fractures that are associated with posterior hip dislocation [36]. According to Giannoudis et al. [32], the incidence of osteonecrosis was 5.6%, while the incidence of osteonecrosis after acetabular fracture was 5%, and 9.2% for acetabular fractures associated with posterior hip dislocation. Posterior hip dislocation is an orthopedic emergency and therefore any dislocated hip should be reduced urgently after hospitalization. A number of authors show the importance of urgent reduction of the dislocated hip in the prevention of the femoral head osteonecrosis [37–40]. Late reduction after 24 hours from the injury increases the possibility of osteonecrosis. According to one of our studies, the incidence of the femoral head osteonecrosis after acetabular fracture – dislocations in which the hip was reduced within 24 hours of injury – was 5.55%, while in a hip reduced after 24 hours after the injury occurred, osteonecrosis incidence was 27.77% [41].

### SECONDARY OSTEOARTHRITIS OF THE HIP

The occurrence of secondary OA of the hip is associated with a non-anatomical reduction of the acetabular fracture during definitive fixation. The literature describes a significantly lower percentage of secondary OA of the hip in anatomically reduced acetabular fractures [42]. Secondary OA of the hip accompanies acetabular fractures and is usually associated with non-anatomical fracture reduction. Meena et al. [43] published a paper according to which not achieving anatomical reduction, associated injuries, initial fracture dislocation (> 20 mm), posterior hip dislocation, late definitive fixation of acetabulum, age, can negatively affect the achievement of good outcome. According to Matta [44], the number of anatomic reductions decreased as time to surgery increased. Pascarella et al. [40] also describe the importance of anatomic reduction of acetabular fractures in achieving excellent and good outcomes. Pavelka et al. [35] published data on 32.81% secondary OA of the hip, 24 months after acetabular fracture. Cahueque et al. [45] published 48% secondary OA, two years after the acetabular fracture. There are other authors who believe that secondary OA occurs several years after the injury, despite anatomic reduction, which only confirms the importance and severity of the acetabular fracture and the anatomical specificity of the acetabulum and hip joint [46] (Figure 8). Some of the cases with secondary OA of the hip require further surgery – total hip replacement [5, 47].

### TIME OF DEFINITIVE ACETABULAR FIXATION

Numerous authors agree that the time interval from injury to definitive acetabular fixation should not be longer than seven days, preferably three to five days. Dailey et al. [42] achieved the best anatomic reduction of acetabular fracture in the first three days after the fracture. According to Brueton [48], the timing of surgery was found to be directly related to the quality of the clinical result. Similar results are presented by Matta et al. [44]. With the delay of

definitive acetabular surgery, the possibility of anatomic reduction is reduced. Definitive osteosynthesis after two to three weeks of the fracture impairs fracture reduction, increases intraoperative bleeding, which adversely affects surgical work. In clinical practice, there are also individual cases with acetabular fracture associated with posterior hip dislocation when definitive acetabular fixation is performed within 24 hours after the injury, due to the need for open reduction of the hip that could not have been reduced by the closed method (Figure 9).

## SURGICAL EXPERIENCE

Surgical experience, reflected primarily in the manual ability and familiarity of the surgeon with a certain surgical problem, is an important prerequisite for success. In acetabular surgery, surgical experience is of great importance. Surgical experience is one of the preconditions for successful treatment of acetabular fractures. In order to acquire knowledge and necessary skills in this field of traumatology, it is necessary to have a national educational center at one of the medical faculties in Serbia. The literature clearly indicates the importance of surgical experience in the treatment of acetabular fractures [7]. Even though we have a sufficient number of orthopedic surgeons in Serbia, we unfortunately have a small number of surgeons who are experienced in this field of traumatology. So far, this experience has been gained abroad in large trauma centers under the guidance of experts. Although rare, acetabular fractures are present in our traumatology practice. It matters whether the patient will return to pre-operative activity

after the acetabular fracture, or whether the acetabular fracture will leave lasting consequences and disability.

## CONCLUSION

Proper diagnosis of acetabular fractures, good knowledge of the acetabular anatomy, experience of the surgeon, early definitive acetabular osteosynthesis, anatomic reduction, and early rehabilitation are only prerequisites for achieving excellent and good outcomes. Whether we will have excellent or good outcomes depends on the initial trauma that caused the damage. Damage is often inevitable, and whether it will be less or greater, it may also depend on ourselves, who deal with this segment of traumatology. We have achieved a lot in acetabular surgery, but still not enough to say that we are in step with the developed world. Including more surgeons in our institutions, who will deal with acetabular surgery, education and training, the existence of a national educational center that will have the opportunity to educate on cadavers are necessary if we want to advance this demanding area of traumatology – pelvic and acetabular surgery.

## ACKNOWLEDGEMENTS

This paper was supported by the University of Niš, Faculty of Medicine, internal project No. 64, titled “Total hip arthroplasty after earlier acetabular fractures.”

**Conflict of interest:** None declared.

## REFERENCES

- Letournel E, Judet R. Fracture of the acetabulum. 2nd edition. Berlin: Springer-Verlag; 1993.
- Dakin GJ, Eberhardt AW, Alonso JE, Stannard JP, Mann KA. Acetabular fracture patterns: Associations with motor vehicle crash information. *J Trauma*. 1999;47(6):1063–71.
- Laird A, Keating JF. Acetabular fractures: A 16-year prospective epidemiological study. *J Bone Joint Surg Br*. 2005;87(7):969–73.
- Milenković S. Pelvic and acetabular fractures. Monography. Nis: Medical faculty of Nis; 2018.
- Milenkovic S, Mitkovic M, Mitkovic M, Stojiljkovic P. Total hip arthroplasty after acetabular fracture surgery. *Int Orthop*. 2020. In print. doi: 10.1007/s00264-020-04676-w
- Ziran N, Soles GLS, Matta JM. Outcomes after surgical treatment of acetabular fractures: a review. *Patient Saf Surg*. 2019;13:16.
- Alton TB, Gee AO. Classifications in brief: Letournel classification for acetabular fractures. *Clin Orthop Relat Res*. 2014;472(1):35–8.
- Judet R, Judet J, Letournel E. Fractures of the acetabulum: classification and surgical approaches for open reduction. Preliminary report. *J Bone Joint Surg Am*. 1964;46:1615–46.
- Hutt JRB, Ortega-Briones A, Daurka JS, Bircher MD, Rickman MS. The ongoing relevance of acetabular fracture classification. *Bone Joint J*. 2015;97(8):1139–43.
- Lawrence DA, Menn K, Baumgaertner M, Haims MA. Acetabular fractures: Anatomic and clinical considerations. *Am J Roentgenol*. 2013;201(3):425–36.
- Scheinfeld MH, Dym AA, Spektor M, Avery LL, Dym RJ, Amanatullah DF. Acetabular fractures: what radiologists should know and how 3D CT can aid classification. *Radiographics*. 2015;35(2):555–77.
- Milenkovic S. Elementary acetabular fractures – Our experiences. 4th Congress of North Macedonian Association of Orthopedics and Traumatologists (MADOT 2018); Abstract book: 42. Ohrid – North Macedonia, 2018.
- Milenkovic S, Saveski J, Radenkovic M, Vidic G, Trajkovska N. Surgical treatment of displaced acetabular fractures. *Srp Arh Celok Lek*. 2011;139(7–8):496–500.
- Milenković S, Mitković M, Radenković M, Mladenović D, Micić I. Surgical treatment of the posterior wall acetabular fractures. Third Congress of Serbian Trauma Association (STA); Abstract book: 119. Zlatibor, 2012.
- Mears DC, Velyvis JH. Acute total hip arthroplasty for selected displaced acetabular fractures: Two to twelve-year results. *J Bone Joint Surg Am*. 2002;84(1):1–9.
- Iqbal F, Ullah A, Younus S, Aliuddin A, Zia OB, Khan N. Functional outcome of acute primary total hip replacement after complex acetabular fractures. *Eur J Orthop Surg Traumatol*. 2018;28(8):1609–16.
- Malhotra R, Gautam D. Acute total hip arthroplasty in acetabular fractures using modern porous metal cup. *J Orthop Surg (Hong Kong)*. 2019;27(2):2309499019855438.
- Milenkovic S. Acetabular fractures – our experience, results and complications. First Congress of the Association of Orthopaedics and Traumatologists of Montenegro (AMOT) with international participation; Abstract book: 103. Bečići – Montenegro, 2019.
- Milenkovic S, Mitkovic M, Mitkovic M. Complications after posterior wall fractures of the acetabulum. VIth Congress of Serbian Trauma Association (STA). Invited Lecturer; Abstract book: 56–62. Vrnjačka Banja, 2020.
- Lehmann W, Hoffmann M, Fensky F, Nüchtern J, Großterlinden L, Aghayev E, et al. What is the frequency of nerve injuries associated with acetabular fractures? *Clin Orthop Relat Res*. 2014;472(11):3395–403.

21. Issack PS, Helfet DL. Sciatic nerve injury associated with acetabular fractures. *HSS J*. 2009;5(1):12–8.
22. Bogdan Y, Tornetta P 3rd, Jones C, Gilde A, Schemitsch E, Vicente M, et al. Neurologic injury in operatively treated acetabular Fractures. *J Orthop Trauma*. 2015;29(10):475–8.
23. Haidukewych GJ, Scaduto J, Herscovici D Jr, Sanders RW, Di Pasquale T. Iatrogenic nerve injury in acetabular fracture surgery: A comparison of monitored and unmonitored procedures. *J Orthop Trauma*. 2002;16(5):297–301.
24. El-Daly I, Reidy J, Culpan P, Bates P. Thromboprophylaxis in patients with pelvic and acetabular fractures: a short review and recommendations. *Injury*. 2013;44(12):1710–20.
25. Wang P, Kandemir U, Zhang B, Wang B, Li J, Zhuang Y, et al. Incidence and risk factors of deep vein thrombosis in patients with pelvic and acetabular fractures. *Clin Appl Thromb Hemost*. 2019;25:1076029619845066.
26. Althuwaykh SH, Alnasser AM, Khubrani AM, Alamari ZS, Aljuhani WS. Prevalence of venous thromboembolism in patients with acetabular or hip fractures and their association with hemoglobin concentration. *J Musculoskelet Surg Res*. 2020;4(1):21–4.
27. Stannard JP, Singhanian AK, Lopez-Ben RR, Anderson ER, Farris RC, Volgas DA, et al. Deep-vein thrombosis in high-energy skeletal trauma despite thromboprophylaxis. *J Bone Joint Surg Br*. 2005;87(7):965–8.
28. Ding A, O'Toole VR, Castillo R, Reahl B, Montalvo R, Nascone WJ, et al. Risk factors for early reoperation after operative treatment of acetabular fractures. *J Orthop Trauma*. 2018;32(7):251–7.
29. Iqbal F, Younus S, Asmatullah, Bin Zia O, Khan N. Surgical site infection following fixation of acetabular fractures. *Hip Pelvis*. 2017;29(3):176–81.
30. Suzuki T, Morgan SJ, Smith WR, Stahel PF, Gillani SA, Hak DJ. Postoperative surgical site infection following acetabular fracture fixation. *Injury*. 2010;41(4):396–9.
31. Negrin L, Seligson D. Results of 167 consecutive cases of acetabular fractures using the Kocher–Langenbeck approach: a case series. *J Orthop Surg Res*. 2017;12(1):66.
32. Giannoudis PV, Grotz MR, Papakostidis C, Dinopoulos H. Operative treatment of displaced fractures of the acetabulum. A meta-analysis. *J Bone Joint Surg Br*. 2005;87(1):2–9.
33. Firoozabadi R, Alton T, Sagi HC. Heterotopic ossification in acetabular fracture surgery. *J Am Acad Orthop Surg*. 2017;25(2):117–24.
34. Baschera D, Rad H, Collopy D, Zellweger R. Incidence and clinical relevance of heterotopic ossification after internal fixation of acetabular fractures: retrospective cohort and case control study. *J Orthop Surg Res*. 2015;10:60.
35. Pavelka T, Salášek M, Bárta P, Fridrich F, Džupa V. Avascular necrosis of femoral head and coxarthrosis progression after acetabular fractures. *Acta Chir Orthop Traumatol Cech*. 2019;86(6):381–9.
36. Milenkovic SS, Mitkovic MM, Mitkovic BM. Avascular necrosis of the femoral head after traumatic posterior hip dislocation with and without acetabular fracture. *Eur J Trauma Emerg Surg*. 2020. Online ahead of print. doi: 10.1007/s00068-020-01495-x
37. Hougaard K, Thomsen PB. Traumatic posterior dislocation of the hip–prognostic factors influencing the incidence of avascular necrosis of the femoral head. *Arch Orthop Trauma Surg*. 1986;106(1):32–5.
38. Ahmed G, Shiraz S, Riaz M, Ibrahim T. Late versus early reduction in traumatic hip dislocations: A meta-analysis. *Eur J Orthop Surg Traumatol*. 2017;27(8):1109–16.
39. Kellam P, Ostrum RF. Systematic review and meta-analysis of avascular necrosis and posttraumatic arthritis after traumatic hip dislocation. *J Orthop Trauma*. 2016;30(1):10–6.
40. Pascarella R, Cerbasi S, Politano R, Balato B, Fantasia R, Orabona G, et al. Surgical results and factors influencing outcome in patients with posterior wall acetabular fracture. *Injury*. 2017;48(8):1819–24.
41. Milenković S, Mitković M, Saveski J, Micić I, Stojiljković P, Stanojković M, et al. Avascular necrosis of the femoral head in the patients with posterior wall acetabular fractures associated with dislocations of the hip. *Acta Chir Jugosl*. 2013;60(2):65–9.
42. Dailey SK, Phillips CT, Radley JM, Archdeacon MT. Achieving anatomic acetabular fracture reduction – When is the best time to operate? *J Orthop Trauma*. 2016;30(8):426–31.
43. Meena UK, Tripathy SK, Sen RK, Aggarwal S, Behera P. Predictors of postoperative outcome for acetabular fractures. *Orthop Traumatol Surg Res*. 2013;99(8):929–35.
44. Matta JM. Fractures of the acetabulum: accuracy of reduction and clinical results in patients managed operatively within three weeks after the injury. *J Bone Joint Surg Am*. 1996;78(11):1632–45.
45. Cahueque M, Martínez M, Cobar A, Bregni M. Early reduction of acetabular fractures decreases the risk of post-traumatic hip osteoarthritis? *J Clin Orthop Trauma*. 2017;8(4):320–6.
46. Alonso JE, Volgas DA, Giordano V, Stannard JP. A review of the treatment of hip dislocations associated with acetabular fractures. *Clin Orthop Relat Res*. 2000;(377):32–43.
47. Milenković S, Mitković M, Mitković M, Sojiljković P. Total hip arthroplasty in treating post-traumatic arthrosis of the hip after acetabular fracture. *Balneoclimatologija*. 2017;41(2):202–5.
48. Brueton RN. A Review of 40 Acetabular Fractures: The importance of early surgery. *Injury*. 1993;24(3):171–4.

## Преломи зглобне чашице кука – хируршко лечење и компликације

Саша Миленковић<sup>1,2</sup>, Милан Митковић<sup>1,2</sup>, Милорад Митковић<sup>1</sup>, Предраг Стојиљковић<sup>1,2</sup>

<sup>1</sup>Универзитет у Нишу, Медицински факултет, Ниш, Србија;

<sup>2</sup>Клинички центар Ниш, Клиника за ортопедију и трауматологију, Ниш, Србија

### САЖЕТАК

Преломи зглобне чашице кука представљају изузетно тешке повреде које најчешће настају у саобраћајним удесима или приликом пада са већих висина, најчешће код радно активне мушке популације. Преломи зглобне чашице кука су присутни у нашој клиничкој пракси и захтевају добру едукацију и обученост кадрова за лечење. Хируршко искуство је један од предуслова за постизање добрих резултата лечења јер ове преломе прате бројне компликације. Ради стицања знања и вештина из ове области хирургије, потребно је да постоји национални центар за едукацију при неком од медицинских факултета у Србији. Сви дислоцирани преломи ( $\geq 2$  mm) зглобне чашице кука се лече хируршки, а за постизање добрих резултата неопходна је рана анатомска репозиција и стабилна унутрашња фиксација. Код прелома зглобне чаши-

це са ишчашењем кука неопходна је хитна репозиција ишчашеног кука. Анатомска репозиција прелома је повезана са временом дефинитивне коштане фиксације прелома. После 14 дана од прелома анатомска репозиција се теже постиже. Поред ових фактора који позитивно утичу на крајње резултате лечења, са друге стране постоје и негативни фактори који утичу на постизање лоших резултата лечења. Они су директно повезани са тежином иницијалне повреде која настаје у тренутку прелома. Коминуција прелома, велика дислокација ( $> 20$  mm), повреда главе фемура, ишчашење кука, утиснуће, трауматска или јатрогена повреда седалног нерва су фактори који негативно утичу на резултате и одговорни су за компликације, на супрот позитивним факторима. **Кључне речи:** зглобна чашица кука; преломи; хируршко лечење; компликације