

CASE REPORT / ПРИКАЗ БОЛЕСНИКА

Primary hepatic pregnancy

Srđan Dikić^{1,2}, Željko Miković^{2,3}, Borislav Tošković^{1,2}, Svetlana Dragojević^{2,3}, Ljubomir Srbinović³¹Bežanijska Kosa University Hospital Medical Center, Belgrade, Serbia;²University of Belgrade, Faculty of Medicine, Belgrade, Serbia;³Narodni Front Obstetrics and Gynecology Clinic, Belgrade, Serbia

SUMMARY

Introduction Hepatic pregnancy is an extremely rare form of ectopic pregnancy, and represents a difficult challenge for both diagnostics and treatment.

Case outline A 40-year-old *gravida 0 para 0* patient in 6 + 0 gestational weeks was admitted to the hospital with lower abdominal pain, positive bHCG values, and presence of free intra-abdominal fluid. She had a history of infertility, and also a previous surgery due to pelvic endometriosis. Urgent open surgery was performed due to signs of hypovolemic shock. We discovered a rupture of the left ovarian corpus luteum cyst. Bleeding management was achieved with preservation of ovarian tissue. Patient recovered, bHCG levels continued to rise, and five days after surgery free intra-abdominal fluid reappeared with upper abdominal pain and tenderness. After transferring patient to abdominal surgery clinic, second surgery was performed, where we confirmed the presence of hepatic pregnancy. After this procedure, patient fully recovered.

Conclusion The method of choice for an ectopic pregnancy treatment is laparoscopic surgery, but when laparoscopy is not possible, the site of ectopic pregnancy could be difficult to diagnose. Prolonged time for making accurate diagnosis increases the risk of ectopic pregnancy complications.

Keywords: hepatic pregnancy; ectopic pregnancy; bHCG; acute abdomen

INTRODUCTION

Ectopic pregnancy is a rare condition that occurs in 1–2% of all reported pregnancies [1]. There has been an increase in the incidence of ectopic pregnancies over the past few decades. This could be explained by three contributing factors: a greater use of assisted reproductive technologies, a high incidence of pelvic inflammatory diseases, and increased awareness of this condition. However, the incidence of abdominal pregnancy is extremely low, and it occurs in only 1% of all ectopic pregnancies [2].

Abdominal pregnancy refers to a pregnancy implanted in the peritoneal cavity, external to the uterine cavity and fallopian tubes. The placenta can be implanted in any of the abdominal organs and it can separate from the site of implantation at any time during pregnancy, which leads to hemorrhagic shock. Abdominal pregnancy is a potentially life-threatening form of ectopic pregnancy because of difficult and often late diagnosis. It is associated with a wide range of signs and symptoms according to the location. The diagnosis of abdominal pregnancy is often missed during routine ultrasonography (US) [3].

In contrast to tubal ectopic pregnancies, primary methotrexate therapy of early gestations in abdominal pregnancy has a high risk of failure due to more advanced gestational age at which these pregnancies are discovered [4].

CASE REPORT

A 40-year-old patient was admitted to hospital with lower abdominal pain. She had a history of infertility and had a conservative surgery due to endometriosis (done five years prior through lower transverse laparotomy). Amenorrhea was 6 + 0 weeks. The initial value of β -HCG was 621 mIU/mL. US exam showed the presence of intra-abdominal free fluid and empty uterine cavity with no adnexal masses. Monitoring of vital signs showed systolic blood pressure below 90, pulse rate of 130 bpm, and diuresis below 30 ml/h (after receiving 500 ml of 0.9% Sodium Chloride solution intravenously). Due to clinical findings of intra-abdominal bleeding and hypovolemic shock, the patient underwent an emergent surgical procedure by lower transverse laparotomy approach from previous surgery. Intraoperative finding was the rupture of the left ovarian corpus luteum cyst with heavy intra-abdominal bleeding (over two liters). Both Fallopian tubes and the right ovary were unaffected. Small bowels, caecum, rectosigmoid colon, and infracolic part of omentum were explored and no sign of ectopic pregnancy was noticed. Histopathological report showed a corpus luteum cyst on the left ovary. After the surgery, the patient fully recovered, but β -HCG levels continued to rise (1052 mIU/mL). Postoperative US showed no signs of either intrauterine or extrauterine pregnancy. At that time, a small formation found in the liver, 37 × 25 mm in diameter, was considered clinically indistinctive (Figure 1).

Received • Примљено:

February 7, 2020

Revised • Ревизија:

August 5, 2020

Accepted • Прихваћено:

September 9, 2020

Online first: September 14, 2020**Correspondence to:**Ljubomir SRBINOVIĆ
Narodni Front Obstetrics and
Gynecology Clinic
Kraljice Natalije 62
11000 Belgrade, Serbia
srbinovic@gmail.com

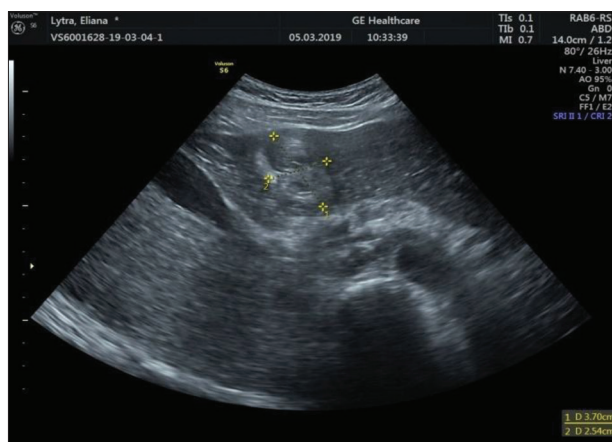


Figure 1. Ultrasonography finding: at first no significance was given to formation found in liver near hilus; differential diagnosis was liver hemangioma

All clinical findings suggested the presence of ectopic pregnancy in the liver. The patient was transported to abdominal surgery clinic for further evaluation and treatment. An urgent computed tomography revealed the presence of a mass of 6 × 5 cm in diameter in the left liver lobe (between liver segments III and IV), with an oval central portion of lower density, and with the peripheral region of higher density in the contrast plan scan. There was a significant amount of fluid, which corresponds to the density of blood, below the left lobe of the liver and above the stomach (Figure 2).

After the urgent computed tomography examination, the patient underwent an open surgery with an upper medial laparotomy. We found around 500 ml of blood in the space between the left lobe of the liver and the stomach. After the evacuation of a blood which was predominantly coagulated,

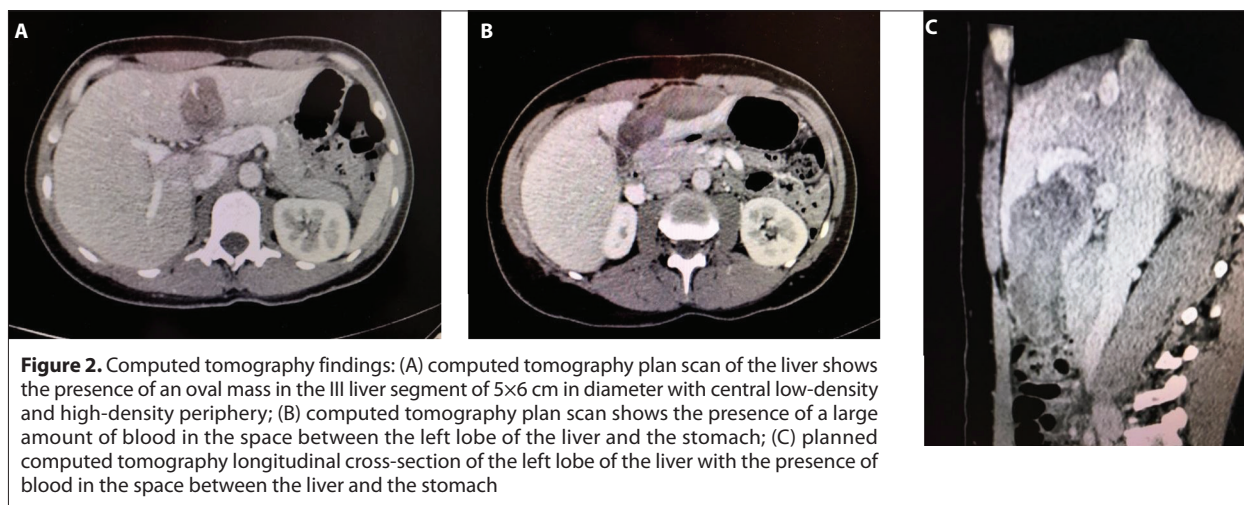


Figure 2. Computed tomography findings: (A) computed tomography plan scan of the liver shows the presence of an oval mass in the III liver segment of 5×6 cm in diameter with central low-density and high-density periphery; (B) computed tomography plan scan shows the presence of a large amount of blood in the space between the left lobe of the liver and the stomach; (C) planned computed tomography longitudinal cross-section of the left lobe of the liver with the presence of blood in the space between the liver and the stomach

On the third postoperative day we performed diagnostic dilatation and curettage of the uterine cavity. Histopathological exam indicated the presence of an endometrial intraepithelial neoplasia, but no evidence of intrauterine pregnancy. After this intervention β -HCG levels dropped to 861 mIU/mL, but soon continued to rise to the level of 1132 mIU/mL. Since intrauterine pregnancy was excluded, we suspected the presence of ectopic abdominal pregnancy of unknown location and administered a single dose of methotrexate (50 mg).

The patient decided to leave the hospital against medical advice. She was suggested to repeat serum β -HCG values in three days. The values were higher than previous, 1668 mIU/mL. On the fifth day upon methotrexate administration, the patient checked into our hospital with pain in the upper parts of the abdomen. Levels of β -HCG were 2060 mIU/mL. On US we discovered the presence of free fluid intra-abdominally (small quantities) and abnormal US imaging of the liver. The US exam revealed a hyperechogenic structure of six centimeters in diameter in the left lobe near the hilum of the liver. The patient had tenderness in the upper parts of the abdomen.

ectopic pregnancy was detected below the falciform ligament in the third liver segment. Expulsion of the ectopic pregnancy was then performed from the existing liver cavity. Gauze with hypertonic solution of sodium chloride was placed in the cavity of the ectopic pregnancy. The surgical procedure was completed with a single liver suture, as well as hemostasis with a bipolar diathermy. More than three liters of isotonic solution of sodium chloride was placed in the abdominal cavity and two drains were placed: one under the liver, and the other in Douglas space (Figure 3).

The β -HCG value (460 mIU/mL) one day after the surgical procedure indicates a significantly lower value than before the surgery. Six days after the surgery the β -HCG level was 32 mIU/mL. Prior to the surgical procedure, hemoglobin value was 109 g/L, and on the day of the patient's release it was 110 g/L only with one blood transfusion (280 ml) after the operation. The patient was discharged on the seventh day in excellent condition.

The histopathology exam confirmed diagnosis of ectopic pregnancy with presence of trophoblastic tissue found in liver.

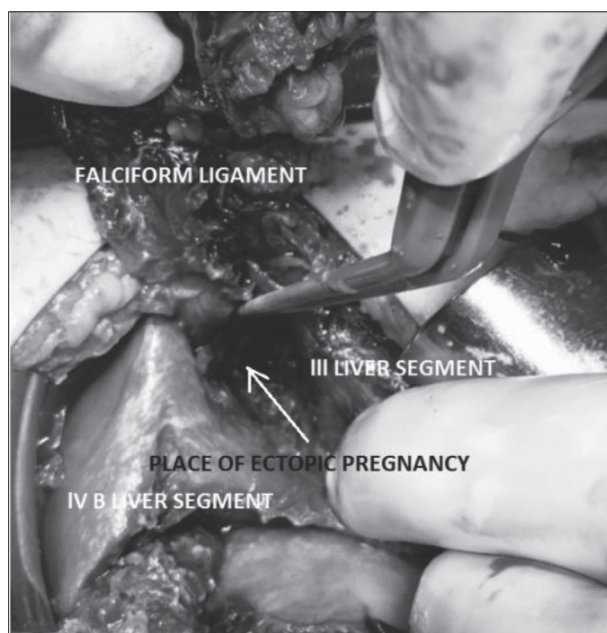

Figure 3. Intraoperative findings: segment III of the liver and place of the ectopic pregnancy next to segment IV of the liver below the falciform ligament after the expulsion of the ectopic pregnancy from the liver cavity

DISCUSSION

Ectopic liver pregnancy is a very rare condition (1:15,000 pregnancies), but also a very dangerous gynecological disease mostly because of life-threatening intra-abdominal bleeding especially when occurring in the liver or spleen [5, 6]. Although the mechanism of primary hepatic pregnancy is unknown, it can be assumed that the risk factors of its occurrence could be: ovarian cysts, adhesions, pelvic or tubal inflammatory diseases, as well as the specificity of the hepatic tissue characterized by huge blood supply, which could lead to a higher possibility of trophoblast implantation and development of gestation sac [7].

In the presented case, the patient had previously suffered from endometriosis and an ovarian cyst, which have been proven operatively and by ultrasound examination. In our case, the rise of β -HCG levels after the prior operation was an alarm for ectopic pregnancy progression.

Further evaluation of endometrial intraepithelial neoplasia found after dilation and curettage procedure is

required to confirm the diagnosis of a true premalignant endometrial lesion and exclude an associated endometrial carcinoma in the patient [8]. Inadequately prepared, as well as pathologically altered endometrium could be one of the explanations for ectopic pregnancy in the presented case.

Abdominal pregnancy represents great diagnostic challenge. A common symptom for hepatic pregnancy is upper right abdominal tenderness. However, our patient did not show any symptoms regarding upper parts of abdomen in the beginning, which made diagnostic process more difficult [3, 9].

It is important to emphasize the presence of two episodes of internal bleeding in this case. The reason for the first episode of bleeding was a rupture of the left ovarian corpus luteum cyst, while the second episode occurred due to the bleeding from the liver at the implantation site of trophoblastic tissue.

Preferred method of choice for treatment of ectopic pregnancy should be laparoscopy, where whole abdominal cavity could be explored [10, 11]. Certain, uncomplicated cases of hepatic pregnancy could be treated with methotrexate [9]. In cases of hepatic pregnancy medial laparotomy could have advantage in bleeding control, considering vascularization of the hepatic tissue [12]. Unfortunately, due to hypovolemic shock, our patient underwent urgent open surgery. Laparoscopy should be performed whenever possible to avoid misdiagnosis of abdominal pregnancy and further complications.

NOTE

Ethical compliance statement: We confirm that we have read the journal's position on issues involving ethical publication and affirm that this work is consistent with those guidelines.

Ethical standards: All procedures performed in studies involving human participants were in accordance with the ethical standards of the institutional and/or national research committee and with the 1964 Helsinki declaration and its later amendments or comparable ethical standards. Written consent to publish all shown material has been obtained from the patient.

Conflict of interest: None declared.

REFERENCES

- Jurkovic D. Diagnosis and management of ectopic pregnancy. *British Medical Journal*. 2011;342:3397.
- Fylstra DL. Ectopic pregnancy not within the (distal) fallopian tube: Etiology, diagnosis, and treatment. *Am J Obstet Gynecol*. 2012;206(4):289–99.
- He S, Cheng Y, Zhang G, Qi H, Sun Q. Primary hepatic pregnancy: a case report with a history of cesarean section and oral contraceptives, with review of literature. *Int J Clin Exp Pathol*. 2019;12(12):4344–8.
- Walker JJ. Ectopic pregnancy. *Clin Obstet Gynecol*. 2007;50:89–99.
- Taran FA, Kagan KO, Hübner M, Hoopmann M, Wallwiener D, Brucker S. The diagnosis and treatment of ectopic pregnancy. *Dtsch Arztebl Int*. 2015;112(41):693–704.
- Cai YY, Xiao EH, Shang QL, Xiao LZ. Ectopic pregnancy in the liver incidentally diagnosed by imaging: a case report. *Exp Ther Med*. 2017;14(1):373–6.
- Ali V, Lilja JF, Chuang AZ, Mogallapu RV, Sabonghy E. Incidence of perihepatic adhesions in ectopic gestation. *Obstet Gynecol*. 1998;92(6):995–8.
- Semere LG, Ko E, Johnson NR, Vitonis AF, Phang LJ, Cramer DW, et al. Endometrial Intraepithelial Neoplasia Clinical Correlates and Outcomes. *Obstet Gynecol*. 2011;118(1):21–8.
- Sibetcheu Tchatou A, Tchounzou R, Mbuagbaw L, Mboudou ET. Successful medical treatment of a hepatic pregnancy: a case report. *J Med Case Rep*. 2017;11(1):70.

10. Zhao RF, Huang SR, Xu LL, Liu NP, Liang N. Successful management of a live 14-week primary hepatic ectopic pregnancy combined with a residual horn of the uterus using laparoscopy. *Chin Med J (Engl)*. 2017;130(24):3013–4.
11. Garzon S, Raffaelli R, Montin U, Ghezzi F. Primary hepatic pregnancy: report of a case treated with laparoscopic approach and review of the literature. *Fertil Steril*. 2018;110(5):925–31.
12. Wang T, Chen P, Bian D. Primary hepatic pregnancy. *Clin Res Hepatol Gastroenterol*. 2017;41(3):241–2.

Примарна хепатична трудноћа

Срђан Дикић^{1,2}, Жељко Миковић^{2,3}, Борислав Тошковић^{1,2}, Светлана Драгојевић^{2,3}, Љубомир Србиновић³

¹Клиничко-болнички центар „Бежанијска коса“, Београд, Србија;

²Универзитет у Београду, Медицински факултет, Београд, Србија;

³Гинеколошко-акушерска клиника „Народни фронт“, Београд, Србија

САЖЕТАК

Увод Хепатичка трудноћа је веома редак облик ектопичне трудноће и представља велики изазов за дијагностику и лечење.

Приказ болесника Четрдесетогодишња болесница (*para 0, gravida 0*), у 6 + 0 недељи трудноће примљена је на клинику због болова у доњем делу абдомена, са позитивним вредностима *bHCG* и слободном течношћу у абдомену. У анамнези се наводи присутан инфертилитет, као и претходна операција због ендометриозе. Због знакова хиповолемијског шока, болесница је хитно оперисана. Интраоперативно је констатована руптура цисте жутог тела левог јајника. Хемостаза је успостављена уз очување ткива јајника. Болесница се опоравила, али су вредности *bHCG* наставиле

да расту и петог постоперативног дана долази до поновног накупљања слободне течности у трбуху са појавом болова и напетости у горњим делу абдомена. После превођења болеснице на одељење абдоминалне хирургије, поново је оперисана и том приликом потврђено је да се ради о хепатичној трудноћи. После ове процедуре болесница се потпуно опоравила.

Закључак Метода избора за ектопичну трудноћу је лапароскопска хирургија, али када лапароскопија није могућа, место ектопичне трудноће није лако пронаћи. Продужено време у постављању прецизне дијагнозе повећава ризик од компликација ектопичне трудноће.

Кључне речи: хепатична трудноћа; ектопична трудноћа; *bHCG*; акутни абдомен