



## ORIGINAL ARTICLE / ОРИГИНАЛНИ РАД

# Our results in the treatment of tarsal dislocations

Maksim Kovačević<sup>1,2</sup>, Marijana Kovačević<sup>1,2</sup>, Sanja Marić<sup>1,2</sup>, Nenad Lalović<sup>1,2</sup>, Milivoje Dostić<sup>1,2</sup>, Vjeran Saratlić<sup>2</sup>

<sup>1</sup>Foča University Hospital, Foča, Republic of Srpska, Bosnia and Herzegovina;

<sup>2</sup>University of East Sarajevo, Faculty of Medicine, Foča, Republic of Srpska, Bosnia and Herzegovina

## SUMMARY

**Introduction/Objective** Tarsal dislocations are rare injuries. Usually, they are caused by high-energy trauma. Depending on the type of dislocation, surgical treatment or closed reduction is used. In this study, 13 patients are presented with the aim to analyze the type of feet dislocations, their treatment, and outcome.

**Methods** Tarsal dislocation cases treated in the University Hospital in Foča were analyzed during the period 2009–2016. All the cases were clinically and radiographically examined and monitored on control examinations at least three years. The mobility of joints was measured and pain existence was estimated by visual analogue scale.

**Results** All 13 patients with tarsal dislocation were male. Four patients were treated surgically (two patients with tarsometatarsal and one with cuboid and navicular dislocation) and other patients had non-surgical treatment. In 10 patients, an excellent functional result has been achieved and in two patients with tarsometatarsal dislocation a good functional result. In one patient with cuboidal dislocation satisfactory functional result has been achieved.

**Conclusion** Out of the 13 reviewed patients with tarsal dislocations, functional results were rated as excellent in 10 dislocations, good in two, and satisfactory in one. Diagnosis and treatment of foot dislocations are demanding, but a favorable functional outcome can be expected with an adequate treatment of these injuries.

**Keywords:** foot; injuries; outcome; treatment

## INTRODUCTION

Tarsal dislocations are rare injuries. There are several types of tarsal dislocations. The most significant are: subtalar dislocations, cuboid bone dislocations, navicular bone dislocations and dislocations of Lisfranc joint.

Subtalar dislocation is defined as simultaneous dislocation of both the talonavicular and the talocalcaneal joints without a major fracture [1].

Subtalar dislocations are classified as medial, lateral, posterior, and anterior based on the displacement of the foot in relationship to the talus. These are uncommon injuries, representing approximately 1% of all traumatic injuries of the foot and 1–2% of all dislocations, being associated with high-energy trauma [2, 3].

Recent studies have emphasized the complex anatomic and kinematic relationship between the talocalcaneal and talonavicular joints and their contributions to hindfoot function [4].

Medial dislocation is the most common and it accounts for 65–85% of all subtalar dislocations. It is the result of forced inversion of the foot when the foot is in the plantar flexion [5].

The cuboid stabilizes the lateral column of the foot. It is the only bone to articulate with both the midtarsal and tarsometatarsal joints. These articulations give the cuboid marked stability, which is reinforced by multiple

ligamentous, tendinous and soft tissue attachments. The cuboid dislocations are rare injuries and are frequently overlooked and misdiagnosed on initial presentation. The mechanism of injury is postulated to include a forced inversion and plantar flexion movement of the foot [6].

The navicular is the keystone of the medial longitudinal arch, and is rigidly stabilized by an extensive network of dorsal and plantar ligaments [7]. The navicular bone more often suffers dislocation fracture than pure dislocation [8]. The central third portion is relatively avascular. When devoid of surrounding soft tissues, as in the case of complete dislocation, it is prone to avascular necrosis.

A Lisfranc dislocation or injury typically describes a spectrum of injuries involving the tarsometatarsal joints of the foot. The Lisfranc joint itself is composed of the articulation between the first, second, and third metatarsals bones, and the cuneiform bones [9].

In this study, patients are presented with the aim to analyze the type of tarsal dislocations, their treatment, and outcome.

## METHODS

The patients with the tarsal dislocation of the foot, who were treated at the University

Received • Примљено:  
November 2, 2019

Revised • Ревизија:  
June 2, 2020

Accepted • Прихваћено:  
June 3, 2020

Online first: June 17, 2020

### Correspondence to:

Maksim KOVAČEVIĆ  
Hasana Kikića 13  
73300 Foča  
Republic of Srpska  
Bosnia and Herzegovina  
[maksimmilicanovi@yahoo.com](mailto:maksimmilicanovi@yahoo.com)

Hospital in Foča (Bosnia and Herzegovina), were analyzed during the period from January 1, 2009 to January 1, 2016. All patients were clinically and radiographically examined and monitored during their hospitalization and then in control examinations in orthopedic ambulance after one and three months, then one and three years after their injury and in case of complications after that period. During every examination, the mobility of joints was measured and pain existence estimated by visual analogue scale with marking 0–10. Zero indicates the absence of pain, while 10 represents the most intense pain possible. X-rays performed at first examination and control examinations were also analyzed. For the patients without pain and those who maintained joint mobility, it was considered they had an excellent functional result. For the patients with the pain which can be classified as 1 or 2 according to the visual analogue scale, or the existence of an easy limitation of joints mobility up to one-third of the arc of motion was considered to be a good functional result. For the patients with the pain which can be classified as 3 according to visual analogue scale or the existence of an easy limitation of joints mobility more than one-third of the circumference movement was considered to be a satisfactory functional result of treatment.

This study protocol was done in accordance with the ethical principles of the Declaration of Helsinki. The data were collected in a setting of usual care, in order to measure the outcome of the treatment. The patients were asked to indicate if they did not allow their anonymous data to be used for scientific studies. The research was approved by the institutional Committee on Ethics of the University Hospital Foča (1/20)

Descriptive statistics were used to calculate central tendency (mean), range, and standard deviation.

**RESULTS**

Thirteen tarsal dislocations treated between 2009 and 2016 were reported. They were male; the average age was 24 years. The most common was subtalar and tarsometatarsal dislocation (Table 1). Five patients with subtarsal dislocation, five with tarsometatarsal dislocation, two with cuboid dislocation, and one patient with dislocation of the navicular bone were treated (Table 1).

The average time from trauma to treatment was 60 ± 19.5 minutes (subtalar dislocations 25, 30, 45, 65, 85 minutes, tarsometatarsal dislocations 55, 60, 65, 75, 80, cuboid dislocations 45, 65 and navicular dislocation 85 minutes).

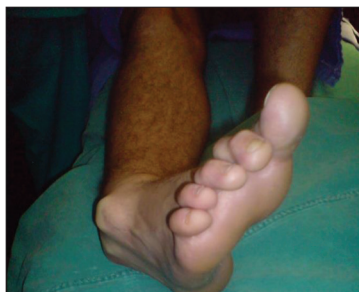Computed tomography scans were performed in most patients with tarsal dislocations (7/13).

**Table 1.** Basic data of patients with tarsal dislocation

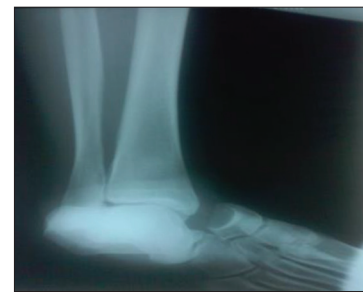Characteristics	Dislocation Type				Total	
	Subtalar	Tarsometatarsal	Cuboid	Navicular		
Number of patients	5	5	2	1	13	
Age	18–24	19–27	29–48	14	24.5 ± 8.9 (14–48)	
Patients surgically treated	0	2	1	1	4	
Treatment outcome	Excellent	5	3	1	1	10
	Good	0	2	0	0	2
	Satisfactory	0	0	1	0	1

**Table 2.** The average time from trauma to treatment

Characteristics	Dislocation Type				Total
	Subtalar	Tarsometatarsal	Cuboid	Navicular	
Number of patients	5	5	2	1	13
Average time from trauma to treatment (minutes)	50	67	55	85	60 ± 19.5
Minimum (minutes)	25	55	45	85	15
Maximum (minutes)	85	80	65	85	80



**Figure 1.** Subtalar dislocation of basketball players



**Figure 2.** X-ray image of subtalar dislocation

The mechanism of injury was different. In cuboid dislocations, one subtalar and two tarsometatarsal, injury occurred in a traffic accident. In dislocation of the navicular bone, the injury was caused by a jump from the height and in three subtalar dislocations, injury was sustained during the sports activities. In four tarsometatarsal dislocations, the injury was sustained by the fall. Four patients were treated surgically.

In all five cases of subtalar dislocation, it was medial dislocation. Closed reduction was performed as urgent and was performed less than two hours after injuries in general anesthesia (Figures 1 and 2, Table 2).

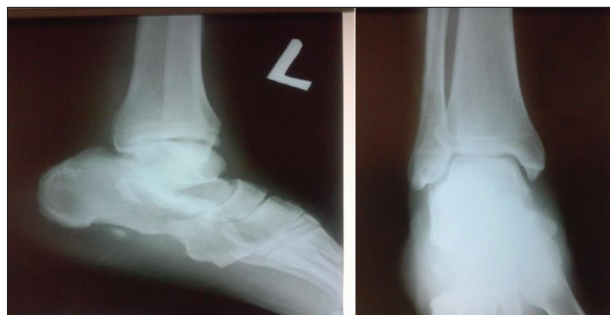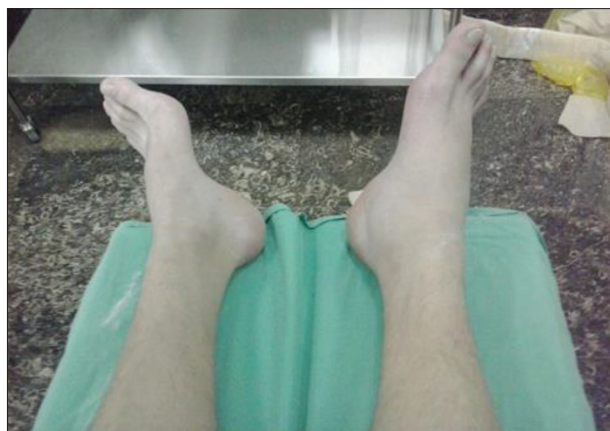
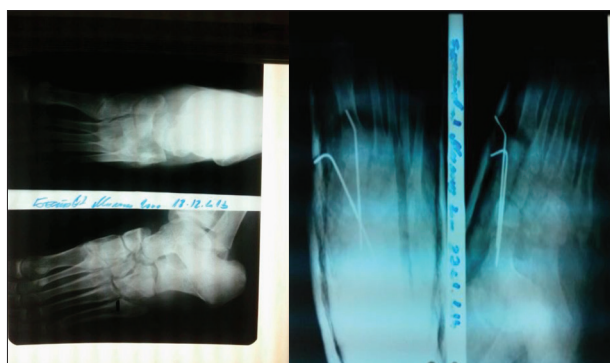Computed tomography scans were performed in 3/5 subtalar dislocations after closed reduction.

During the follow-up period, three years after the injury, there was no appearance of aseptic necrosis or other complications. At the end of the treatment of all patients, an excellent functional result was achieved. All patients returned to their previous levels of activities with a normal range of motion (Table 3).

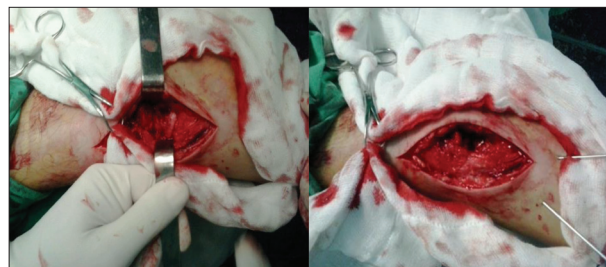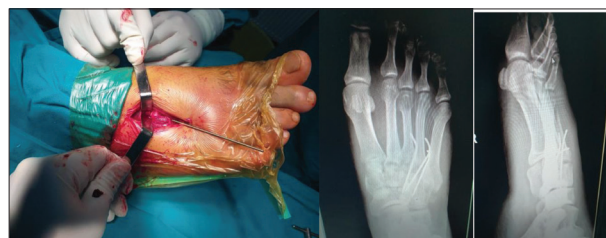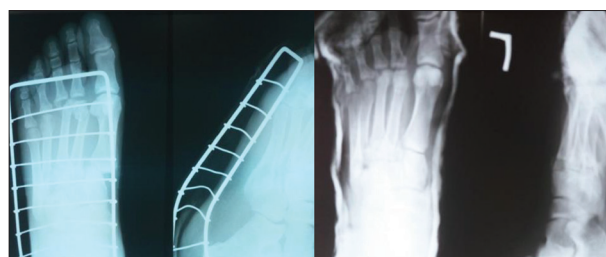
We report two patients with dislocation of the cuboid bone. One patient had an open dislocation of the cuboid bone (Figure 3). Open reduction of the cuboid bone was performed through the already present wound, and another patient refused surgery and the cuboid bone remained dislocated.

**Table 3.** Range of motion ankle and foot joints and return to preinjury levels of activity

Characteristics		Dislocation Type				Total
		Subtalar	Tarsometatarsal	Cuboid	Navicular	
Number of patients		5	5	2	1	13
Range of motion ankle and foot joints	Normal	5	3	1	1	10
	limitation less than 1/3	0	2	0	0	2
	limitation more than 1/3	0	0	1	0	1
Return to preinjury levels of activity		5	5	1	1	14

**Figure 3.** X-ray images after dislocation of the cuboid bone**Figure 4.** Dislocation of the navicular bone occurred when the student jumped through the school window**Figure 5.** X-ray images of dislocation of the navicular bone before and after the surgery

In the first injury, an excellent functional result was achieved. In the second injury an intensive physiotherapy was applied. Satisfactory functional result was achieved with the presence of the pain. The patient marked the pain with 3 on the visual analogue scale and also experienced limited joint mobility of the ankle and foot more than one

**Figure 6.** Intraoperative photos of dislocations of the navicular bone and photos after the open reduction and K-wire stabilization**Figure 7.** Intraoperative photos tarsometatarsal dislocation after the open reduction and K-wire stabilization and postoperative X-ray image**Figure 8.** X-ray images before and after the closed reduction of tarsometatarsal dislocation

third of the movement range (Ankle dorsiflexion/ankle plantarflexion (active) -10/-20, Foot inversion/foot eversion (active) -15/-10). The patient did not return to pre-injury levels of activity (Table 3).

One dislocation of the navicular bone was described. The injury was caused by patient jumping from a height. Dislocation was treated surgically with open reduction and K-wire stabilization (Figures 4, 5 and 6).

We report five patients with tarsometatarsal dislocation. Two dislocations were treated surgically (Figure 7) and three dislocations was treated non-surgically by closed reduction (Figure 8).

Computed tomography scans were performed in 4/5 tarsometatarsal dislocations. Functional results were rated excellent in three dislocations, and good in two dislocations. Two patients had limited joint mobility of the ankle and foot less than one third of the movement range (ankle dorsiflexion/ankle plantarflexion (active) -5/-10, -5/-10,

Foot inversion/foot eversion (active) -10/-5, -5/-5), and light intensity pain during higher load (on visual analogue scale 1, 2). All the patients returned to their previous levels of activities.

## DISCUSSION

In the seven-year period, at the University Hospital in Foča (Bosnia and Herzegovina), 13 patients with tarsal dislocation were treated. All were male and the mechanism of injury was different. Four patients were treated surgically while others had nonsurgical treatment.

All patients received low-molecular-weight heparin for thromboprophylaxis. The duration of treatment was during the period of immobilization. All surgically treated patients received a single-dose cefazolin (2 g) as an antibiotic prophylaxis. We used the multidisciplinary team approach for pain management.

An excellent joint function was achieved in 10 patients. In two patients the function was good and in one joint function was satisfactory.

Subtalar dislocations are three to ten times more common in male than in female and generally occur in the second or the third decade of life [10]. Medial subtalar dislocation can be a diagnostic problem, because it is a rare injury, and moreover, X-ray of the injury can be confusing due to superposition of bones [11]. The diagnosis of subtalar dislocation is usually made on anteroposterior, lateral, and oblique radiographs of the foot or ankle. The nature of the deformity often limits radiographic positioning. Medial subtalar dislocation results in medial and plantar displacement of the navicular relative to the talar head and medial displacement of the calcaneus relative to the talus. The tibiotalar joint remains congruent. After reduction, standard anteroposterior and lateral radiographs of the foot as well as anteroposterior and mortise views of the ankle should be obtained to confirm optimal results. In the absence of deformity, postreduction radiographs are usually of better quality than those obtained at the time of injury [12]. Closed reduction of these dislocations should be performed as early as possible to avoid further damage to the skin and neurovascular structures. If this is not possible, then open reduction without further delay is recommended [3, 13, 14].

Prognosis of isolated acute traumatic subtalar dislocations is favorable. Emergent closed reduction makes it possible to remove soft tissue injuries [15]. Complications of these injuries include posttraumatic arthrosis of subtalar, talonavicular or tibiotalar joint, aseptic necrosis of the talus and contracture of subtalar joint [16]. The risk of posttraumatic subtalar osteoarthritis is significant, even without an initial subtalar lesion. A postreduction computed tomography scan will enable the diagnosis of osteochondral lesions [15]. Newer evidence supports shorter-term immobilization followed by early range of motion after the initial injury in order to prevent stiffness [17, 18].

All five presented cases with subtalar dislocation had nonsurgical treatment according to the above-mentioned

principles. Examination of the foot revealed an obvious deformity, substantial soft-tissue edema, and foot pain. Anteroposterior and lateral radiographs of the ankle was sufficient for the diagnosis subtalar dislocations. Urgent closed reduction of these dislocations was performed under general anesthesia. Computed tomography findings after closed reduction did not alter the treatment plan for any of the patients studied. After reduction, below knee cast was applied. Immobilization was removed after three weeks and the patients were not to bear any weight for the next three weeks. All the patients have undergone physiotherapy.

During the observation period after the injury, which lasted three years, there was no appearance of aseptic necrosis or other complications. At the end of the treatment, an excellent functional result was achieved. All the patients returned to their previous activities with a normal range of motion. An excellent outcome of patients with subtalar dislocation can be expected if: the injury was caused by low energy forces; quick reposition was performed; and the immobilization was not long [19].

We report two patients with dislocation of the cuboid bone. One patient had open dislocation of the cuboid bone. Open reduction of the cuboid bone was performed through the already present wound. After reduction, immobilization was applied. Immobilization was removed after six weeks. He received anti-tetanus prophylaxis.

Other patient refused surgery and the cuboid bone remained dislocated. Both patients have undergone physiotherapy.

An excellent functional result was achieved in one patient and the full mobility feet joints was restored, while in patient who refused surgery the result was satisfactory. He had limited joint mobility of the ankle and foot, pain during higher load (on visual analogue scale 3), and did not return to preinjury levels of activity.

Cuboid dislocations are rare injuries and are frequently overlooked and misdiagnosed on initial presentation [20]. The mechanism of injury is postulated to include a forced inversion and plantar flexion movement of the foot [21]. Important clinical findings include lateral foot pain, a palpable gap at the cuboid level and difficulty to bear weight. Radiographic evaluation of the region is often difficult because of overlap and superimposition of the bones. Anteroposterior, lateral and oblique radiographs should be obtained. Open reduction is usually required [22, 23].

Isolated dislocations of the navicular bone without fracture are rare injuries [24]. Because of the complexity of the midtarsal and tarsometatarsal joint complex, the exact mechanism of injury is often not known, particularly when there are multiple deforming forces present, as in high-energy injuries. The clinical symptoms and signs are swelling over the dorsomedial aspect of the foot; tenderness at the "N spot", which is defined as the proximal dorsal portion of the navicular; and pain with active inversion and passive eversion. For all midfoot injuries, standard anteroposterior, lateral and oblique radiographs should be obtained.

The main aim of treatment is early stable anatomical reduction. The fixation method varies from using screws,

plates, Kirschner wires, or external fixators. Complications include prolonged disability due to persistent pain in the navicular; stiffness of the midfoot; nonunion of associated fractures; avascular necrosis of the navicular; deformity of the foot; and post-traumatic arthritis [25, 26].

We report one dislocation of the navicular bone, which was treated surgically by early anatomical open reposition. After K-wire stabilization, below knee cast was applied. Immobilization was removed after four weeks and the patients were non-weight bearing for the next three weeks. All the patients have undergone physiotherapy.

An excellent functional result was achieved. The full mobility feet joints were restored. The patients returned to his previous activities.

Tarsometatarsal joint fracture-dislocation is an easily overlooked injury, which will cause abnormal transduction of the stress from midfoot to forefoot. Therefore, the surgical treatment is essential to obtain anatomical reduction [27].

The following cases are highly suggestive of a Lisfranc lesion:

- 1) Plantar ecchymosis at the level of the midfoot;
- 2) Pain on palpation or manipulation of the tarsometatarsal joints;
- 3) Altered sensitivity in the back of the first intermetatarsal space;
- 4) The “piano key test”, which consists of moving the head of the affected metatarsal while firmly holding the midfoot and hindfoot;
- 5) An increase in the distance between the hallux and the second finger, known as a “positive gap”, which correlates with inter-cuneiform instability.

In these cases, we must request a radiographic non-weight-bearing study based on three views:

- 1) Anteroposterior: the alignment between the medial edge of the second metatarsal and the medial edge of the second cuneiform bone should be checked. The distance between the bases of the first and second metatarsals should not exceed 2 millimeters. The “fleck sign,” a small bone fragment in the first intermetatarsal space, indicates the avulsion of the Lisfranc ligament;
- 2) Internal oblique: the alignment between the medial border of the cuboid bone and the medial border of the fourth metatarsal should be checked;
- 3) Lateral: the dorsal/plantar displacement of the metatarsals should be assessed.

The definitive surgical intervention must be deferred 10–15 days until the healing of the soft tissues and the appearance of wrinkles on the skin (wrinkle sign). The traditional treatment for Lisfranc lesions is open reduction and internal fixation. However, some authors believe that primary partial arthrodesis offers better results and a lower rate of re-operations [28]. Functional outcomes

after Lisfranc fractures are most dependent on the quality of anatomical reduction and not the choice of fixation implant used [29].

Marín-Peña et al. [30] reviewed the patients who had Lisfranc dislocation and showed that after 14 years the score of the American Association of Orthopedic Surgeons for ankle joint and the foot, which included the presence of the pain, function and alignment, was 91.7/100. For the evaluation of long-term outcome of these injuries functional parameters should be the focus of assessment, instead of radiological changes [30].

All patients had pain associated with swelling and inability to walk. Computed tomography scans were performed in 4/5 subtalar dislocations. Three patients with stable fractures were treated with closed reduction and cast immobilization. Two patients with unacceptable closed reduction and risk of soft tissue compromise were treated with open reduction and K-wire stabilization followed by cast immobilization. All patients were informed about the risks, benefits, and alternatives of a given procedure or intervention. They all demanded for less traumatic procedures.

The analysis of long-term data showed three patients with excellent functional results and two with good results. Two patients have limited joint mobility of the ankle and foot less than one third of the movement range and light intensity pain during higher load (on visual analogue scale 1, 2). All the patients returned to their previous levels of activities.

We report 13 tarsal dislocations. Functional result was rated excellent in 10 dislocations, good in two, and satisfactory in one.

After the treatment, there was a minimal limitation range of the movements of the feet joints (in 10 patients there were no restriction of movement, in two patients it was less than one-third of the range of the movement) while in one patient the restriction was more than third of the range of the movement. Two patients had light intensity pain during higher load (on visual analogue scale 1, 2), and one had pain during higher load (on visual analogue scale 3). The results were comparable with the results stated in the literature.

## CONCLUSION

Tarsal dislocations are rare injuries. Diagnostics and the treatment of these dislocations are demanding but with adequate treatment a favorable functional outcome can be expected. Out of the 13 reviewed patients with tarsal dislocations, functional result were rated excellent in 10 dislocations, good in two, and satisfactory in one.

**Conflicts of interest:** None declared.

## REFERENCES

- Benabbouha A, Ibou N. Rare case of pure medial subtalar dislocation in a basketball player. *Pan Afr Med J.* 2016;23:106.
- Aharram S, Derfoufi A, Kharraji A, Amghar J, Benhamou M, Daoudi A, et al. Un cas rare de luxation astragalo-scapho-calcanéenne interne [A rare case of internal astragalo-scapho-calcanéenne interne]. *Pan Afr Med J.* 2018;31:91.
- Prada-Cañizares A, Auñón-Martín I, Vilá Y Rico J, Pretell-Mazzini J. Subtalar dislocation: management and prognosis for an uncommon orthopaedic condition. *Int Orthop.* 2016;40(5):999–1007.
- Arnold JB, Caravaggi P, Fraysse F, Thewlis D, Leardini A. Movement coordination patterns between the foot joints during walking. *J Foot Ankle Res.* 2017;10:47.
- Zimmer TJ, Johnson KA. Subtalar dislocations. *Clin Orthop Relat Res.* 1989;(238):190–4.
- Jacobson FS. Dislocation of the cuboid. *Orthopaedics.* 1990;13(12):1387–9.
- Early JS, Hansen ST Jr. Midfoot and navicular injuries. In: Helal B, Rowley DI, Cracchiolo A III, Myerson M, editors. *Surgery of disorders of the foot and ankle.* London: Martin Dunitz; 1996. p. 731–47.
- Vaishya R, Patrick JH. Isolated dorsal fracture dislocation of the tarsal navicular. *Injury.* 1991;22(1):47–8.
- Buchanan BK, Donnally III CJ. Dislocation, Lisfranc. *StatPearls [Internet]. Treasure Island (FL): StatPearls Publishing; 2019–2019 Jun 3.*
- Freund KG. Subtalar dislocations: a review of the literature. *J Foot Surg.* 1989;28(5):429–32.
- Manojlović R, Starcević B, Tabaković D, Tulić G, Lesić A, Bumbasirević M. Medial subtalar dislocation—case report. *Srp Arh Celok Lek.* 2010;138(3–4):252–5.
- Melenevsky Y, Mackey RA, Abrahams RB, Thomson NB 3rd. Talar Fractures and Dislocations: A Radiologist's Guide to Timely Diagnosis and Classification. *Radiographics.* 2015;35(3):765–79.
- Nkaoui M, Boufettal M, Sasbou Y, Kharraz M, El Ouadaghir M, Lamrani MO, et al. Luxation sous-talienne interne pure: à propos d'un cas [Pure internal subtalar dislocation: about a case]. *Pan Afr Med J.* 2017;27:123.
- Yglesias B, Andrews K, Hamilton R, Lea J, Shah R, Ebraheim N. Case report: irreducible medial subtalar dislocation with incarcerated anterior talar head fracture in a young patient. *J Surg Case Rep.* 2018;2018(7):rjy168.
- Ruhlmann F, Poujardieu C, Vernois J, Gayet LE. Isolated Acute Traumatic Subtalar Dislocations: Review of 13 Cases at a Mean Follow-Up of 6 Years and Literature Review. *J Foot Ankle Surg.* 2017;56(1):201–7.
- Rammelt S, Bartoniček J, Park KH. Traumatic Injury to the Subtalar Joint. *Foot Ankle Clin.* 2018;23(3):353–74.
- Grear BJ. Review of talus fractures and surgical timing. *Orthopedic Clinics of North America.* 2016;47(3):625–37.
- Arain AR, Adams CT, Haddad SF, Moral M, Young J, Desai K, et al. Diagnosis and Treatment of Peritalar Injuries in the Acute Trauma Setting: A Review of the Literature. *Adv Orthop.* 2020;2020:1852025.
- Lasanianos NG, Lyras DN, Mouzopoulos G, Tsutseos N, Garnavos C. Early mobilization after uncomplicated medial subtalar dislocation provides successful functional results. *J Orthop Traumatol.* 2011;12(1):37–43.
- Sheahan K, Pomeroy E, Bayer T. An isolated cuboid dislocation. A case report. *Int J Surg Case Rep.* 2017;39:1–4.
- Agha RA, Fowler AJ, Saetta A, Barai I, Rajmohan S, Orgill DP; SCARE Steering Group. A protocol for the development of reporting criteria for surgical case reports: The SCARE statement. *Int J Surg.* 2016;27:187–9.
- Kaiser PB, Briceno J, Kwon JY. Complete Cuboid Dislocation With Associated Lisfranc Injury: A Case Report and Review of the Literature. *J Foot Ankle Surg.* 2019;58(2):398–402.
- Sheahan K, Pomeroy E, Bayer T. An isolated cuboid dislocation. A case report. *Int J Surg Case Rep.* 2017;39:1–4.
- Konstantinidis I, Symeonidis PD, Polyzos D, Antonarakos P, Givissis P, Dimitriou C. Talonavicular Dislocation—What Lies Beneath? *J Am Podiatr Med Assoc.* 2018;108(5):397–404.
- Pathria MN, Rosenstein A, Bjorkengren AG, Gershuni D, Resnick D. Isolated dislocation of the tarsal navicular: a case report. *Foot Ankle.* 1988;9(3):146–9.
- MAQ Ansari. Isolated complete dislocation of the tarsal navicular without fracture: A rare injury. *Ci Ji, Yi Xue, Za Zhi.* 2016;28(3):128–31.
- Xiao YU, Pang QJ, Yang CC. Functional outcome of tarsometatarsal joint fracture dislocation managed according to Myerson classification. *Pak J Med Sci.* 2014;30(4):773–7.
- Moracia-Ochagavía I, Rodríguez-Merchán EC. Lisfranc fracture-dislocations: current management. *EFORT Open Rev.* 2019;4(7):430–44.
- Lau S, Guest C, Hall M, Tacey M, Joseph S, Oppy A. Functional Outcomes Post Lisfranc Injury—Transarticular Screws, Dorsal Bridge Plating or Combination Treatment? *J Orthop Trauma.* 2017;31(8):447–52.
- Marín-Peña OR, Viloria Recio F, Sanz Gómez T, Larrainzar Garijo R. Fourteen years follow up after Lisfranc fracture-dislocation: functional and radiological results. *Injury.* 2012;43 Suppl 2:S79–82.

## Наша искуства у лечењу тарзалних луксација

Максим Ковачевић<sup>1,2</sup>, Маријана Ковачевић<sup>1,2</sup>, Сања Марић<sup>1,2</sup>, Ненад Лаловић<sup>1,2</sup>, Миљивоје Достић<sup>1,2</sup>, Вјеран Саратлић<sup>2</sup>

<sup>1</sup>Универзитетска болница Фоча, Фоча, Република Српска, Босна и Херцеговина;

<sup>2</sup>Универзитет у Источном Сарајеву, Медицински факултет Фоча, Фоча, Република Српска, Босна и Херцеговина

### САЖЕТАК

**Увод/Циљ** Тарзалне луксације су ретке повреде. Обично су узроковане траумом високе енергије. Зависно од врсте луксације примењује се оперативно лечење или ортопедска репозиција. У раду је приказано 13 болесника са тарзалним луксацијама са циљем да се анализирају тип луксација, њихово лечење и исход.

**Метод**е Анализирали су случајеви луксација стопала лечени у Универзитетској болници Фоча у периоду 2009–2016. године. Сви су клинички и радиографски обрађени те праћени на контролним прегледима најмање три године. Мерена је покретљивост зглобова и постојање болова процењено је визуелно-аналогном скалом.

**Резултати** Свих 13 приказаних болесника са тарзалним луксацијама били су мушког пола. Четири болесника лече-

на су оперативно (два болесника са тарзометатарзалном и по један са кубоидном и навикуларном луксацијом), а остали неоперативно. Код 10 болесника је постигнут одличан функционални резултат, код два болесника са тарзометатарзалном луксацијом добар, а код једног са кубоидном луксацијом задовољавајући резултат.

**Закључак** Од 13 болесника са тарзалним луксацијама лечених током седам година код десет је постигнут одличан резултат, код два добар, а код једног задовољавајући. Дијагностика и лечење луксација стопала су захтевни али адекватним лечењем ових повреда може се очекивати повољан функционални резултат.

**Кључне речи:** стопало; повреда; исход; лечење