



ORIGINAL ARTICLE / ОРИГИНАЛНИ РАД

Comparison of video-assisted thoracoscopic surgery and standard surgical approach in treatment malignant thymus tumor stage I and II – propensity score analysis

Vanja Kostovski¹, Milena Pandrc², Aleksandar Ristanović¹, Dejan Stojković¹, Nebojša Marić¹, Vlado Cvijanović¹, Ljubinko Đenić¹, Aleksandar Nikolić¹, Slobodan Milisavljević³

¹Military Medical Academy, Clinic for Thoracic and Cardiac Surgery, Belgrade, Serbia;

²Military Medical Academy, Clinic for Cardiology, Belgrade, Serbia;

³Clinical Centre Kragujevac, Clinic for General and Thoracic Surgery, Kragujevac, Serbia

SUMMARY

Introduction/Objective Besides sternotomy, video-assisted thoracoscopic surgery (VATS) is used for thymus tumors treatment.

The objective of our study was to compare oncological and perioperative outcomes in patients with I–II stage of thymic tumors treated with VATS or standard sternotomy procedures.

Method The study included only primary I–II thymoma according to the Masaoka classification, treated between May 2006 and February 2018. Out of 116 treated patients that had pathohistologically verified stage, 100 (86.2%) were matched by propensity score for sex, age, body mass index, myasthenia, tumor size, Masaoka classification stage. Oncological (direct post-operative survival, recurrence) and perioperative outcomes (intraoperative and postoperative complications, length of hospitalization) that affect the efficacy and safety of surgical techniques have been analyzed and compared between the two groups. **Results** Among 50 patients operated by VATS, 34 patients (68%) were treated by uniportal approach, 13 (26%) by biportal and three (6%) by threeportal approach. The VATS intervention had shorter intervention time ($p < 0.001$), duration of hospitalization ($p < 0.001$), and usage of thoracic drainage ($p < 0.001$). There was a significant difference in terms of late control ($p < 0.001$). There was no significant difference between the groups regarding visual analogue scale score, as well as in terms of the time of recurrence ($p = 0.305$, $p = 0.268$).

Conclusion Compared to standard sternotomy, VATS thymectomy is an equally effective and significantly safer method with a minimum rate of intra and postoperative complications.

Keywords: thymoma; video assisted thoracoscopy; open thymectomy

INTRODUCTION

Thymus carcinomas belong to the group of epithelial tumors of the thymus, mainly located in the anterior mediastinum [1]. They belong to the group of rare and invasive malignancies and make up to 1.5% of all malignant tumors, and only 0.06% of all tumors of thymus in general [1, 2]. They most commonly occur between the age of 30 and 60, but they can also occur in early childhood and elderly life, without significant predilection by gender [2, 3]. It is important to underline that a few patients have systemic symptoms including autoimmune disease [4]. Approximately 30% of patients with thymoma have myasthenia gravis [5]. Post-thymectomy myasthenia gravis is registered in around 1–3% of the operated patients, and this disorder progresses after extensive thymectomy mostly characterized for open surgery [5, 6, 7].

In surgery, Masaoka Koga staging system is commonly used as the most important determinant of long-term prognosis after surgical resection [8]. Resection/surgery is the first and

most important modality for treating tumors of the thymus; the possibility of implementing a complete resection is the most important parameter that defines a long-term prognosis [9, 10]. The rate of relapse ranges from 1–5% for non-invasive to 20% for invasive complete resective tumors [11, 12]. There are controversial attitudes considering surgery, surgical approach, the place of thoracoscopic methods, and the extent of thymoma resection [4].

Nowadays, the majority of thymoma patients have VATS surgery at the Military Medical Academy. Numerous reports show that patients with Masaoka stage I–II thymoma underwent VATS [4, 12]. The minimally invasive approach is the recommended option in the I–II stage of the tumor, while for stage III there are no data on patient's long-term survival, so that open surgery is represented as a therapeutic approach [8, 13–16]. The invasion to the innominate vein, phrenic nerve, or other major vessels should be a contraindication to VATS [13]. It is widely accepted that VATS is technically safe and feasible for thymoma with

Received • Примљено:
July 16, 2019

Revised • Ревизија:
June 8, 2020

Accepted • Прихваћено:
June 10, 2020

Online first: June 19, 2020

Correspondence to:

Milena PANDRC
Crnotravska 17
11000 Belgrade, Serbia
pandrcmilena@yahoo.com

a diameter < 50 mm [14]. VATS mostly includes unipolar technique by one-sided approach (right or left side) with respect to the anatomical localization of the thymus. The right-side approach is more secure because of the relationship with the brachiocephalic vein [4]. Although the definitive guidelines have not yet been established regarding the extent of thymoma resection, it is well known that extensive resection of the thymus may increase the potential risk of the intra and post-operative complications [4].

By developing minimally invasive surgery, video-assisted thoracoscopic surgery (VATS) is imposed as an excellent alternative to sternotomy procedures [1, 16, 17]. However, the safety of VATS and the achievement of a complete stable remission as an efficiency measure and evaluation criterion in assessing the radicalism of resection remain insufficiently examined, since most of the previously cited studies, as well as the studies included in the aforementioned analysis, encompassed a relatively small number of patients.

The study was based on analysis and comparison of oncological outcomes (direct post-operative survival, recurrence), as well as analysis and comparison of the type and frequency of perioperative outcomes (intra and postoperative complications, duration of hospitalization) in patients with I–II stage of thymic tumors treated with VATS and standard sternotomy procedures.

METHODS

The retrospective cohort study included 156 patients with primary thymus tumors, operated at the Clinic for thoracic and cardiac surgery in the period from 2006 to 2018. Criteria for exclusion from the study were incomplete medical documentation (56 patients or 20%), comorbidities that did not allow anesthesia (25 patients or 8.92%), advanced malignant disease (35 patients or 12.5%), coagulopathy (six patients or 2.14%), alcoholism (one patient or 0.36%) and the use of psychoactive substances (one patient or 0.36%). A total of 116 treated patients have the pathohistologically verified stage I–II thymoma according to the Masaoka classification. The remaining 40 patients or 14.4% either died because of complication during the intervention (four patients or 1.44%) or had a stage III–IV thymoma according to the Masaoka classification (36 patients or 12.96%).

Using propensity score based on six variables (sex, age, body mass index, myasthenia, tumor size, Masaoka classification stage) each patient in the VATS-treated group was “matched” with a patient in a group treated with a standard thymectomy with the same propensity score. Of total number of patients included in study (116), 100 patients (86.2%) were matched, resulting in the formation of two identical groups with similar sociodemographic and clinical features (Figure 1).

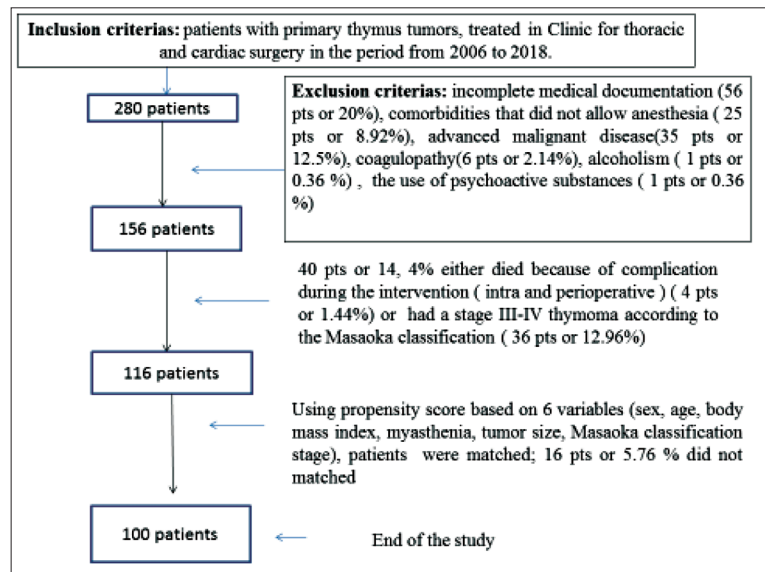


Figure 1. Design of the study

All epidemiological (sex, age) and anthropometrical data (height, body mass, body mass index derived as (body mass/height² (kg/m²)) were recorded in medical documentation, as well as the number comorbidities and the Charlson Comorbidity Index. In hospital medical abstracts we have also found the data considering comedications (number of drugs and daily doses of drugs) and tumor size.

Among 156 patients underwent surgery, 98 patients (62.8% of the operated) were treated with standard thymectomy. Those from the group who survived the intervention and had the stage I–II thymoma according to the Masaoka classification, were included in matching (58 patients or 59% of all treated with the standard procedure, or 37.5% of all surgery patients).

Since 2012, VATS thymectomy has become a standard surgical technic for thymectomy. VATS technic by one-sided approach (to the right or left side) respects to the anatomical localization of the thymus. All patients treated with VATS were familiar with the surgical approach, potential risks, and complications, and they signed a standardized consent at the Military Medical Academy.

All procedures performed in study involving human participants were in accordance with the ethical standards of the Ethical Commission of Belgrade University of Defense (Ethical Approval from October 30, 2018)

Oncological and perioperative outcomes (intraoperative and postoperative) that affect the efficacy and safety of surgical techniques have been analyzed and compared between the two groups. The following variables were included: duration of the surgical intervention, the length of hospitalization and thoracic drainage, the late control, recurrence.

The first follow-up was one month after the surgery. The patients had the thorax multislice computed tomography done before the control. After six months, they were also checked by the operator and a neurologist. The late control followed after the six-month follow up, regularly planned 12 months after the intervention, but it occurred early if the patient has some late complication of the

intervention (intercostal neuralgia, psychiatric problems linked with the treatment, neurological exacerbation). The time of the late control was expressed in months. Initially, the patient was checked by the operator, who indicated the next procedures and consultations. The visual analogue scale was used for evaluation of post-surgical pain.

Complete statistical analysis of data was made using commercial statistical software SPSS Statistics for Windows, Version 18.0. (SPSS Inc., Chicago, IL, USA). In the case of continuous variables, the data are presented as median, min-max, and interquartile range (IQR) (25–75th percentile). The distribution of data was checked using the Shapiro–Wilk test. Depending on the results of this test, statistical significance between the groups was tested using a t-test for independent groups or alternatively Mann–Whitney test. Some variables are presented in the form of frequencies of particular features (categories) and statistical significance will be determined using the χ^2 test. A statistically significant difference is assessed at the minimum level $p < 0.05$.

RESULTS

Of the total number of patients included in the study (116), 100 patients (86.2%) were matched. There was no statistically significant difference in distribution in terms of sex between two groups ($p = 0.316$). The study results did not show significant difference in distribution and type of comorbidities between the groups. The most frequent associated disease in each group was hypertension (VATS vs. thoracotomy: 16% vs. 18%, $p = 1.000$) (Tables 1 and 2).

There was no statistically significant difference in age ($p = 0.588$), body mass index ($p = 0.424$), number of comorbidities and Charlson Comorbidity index ($p = 0.735$ and $p = 0.828$ successively), number of drugs ($p = 0.676$) and tumor size ($p = 0.566$) between the group treated with VATS and the group treated with standard technique (Table 2). There was no statistically significant difference in the daily dose of drugs (Pronison®, Imuran®, proton pump inhibitors (IPP), vitamin D (Alpha D3), CaCO₃) between the groups (successively $p = 0.597$, $p = 0.111$, $p = 0.832$, $p = 0.664$, $p = 0.664$) (Table 3).

Among the 50 patients treated with VATS, uniportal approach was used in 34 patients (68%), biportal in 13 patients (26%) and threeportal in three patients (6%).

The duration of VATS intervention was significantly shorter compared to the standard intervention, as well as hospitalization stay and thoracic drainage ($p < 0.001$, $p < 0.001$, $p < 0.001$). All the patients achieved the late control, but the thoracotomy-treated patients came

Table 1. Gender and comorbidities of the study population

Parameters	VATS (n = 50)	Thoracotomy (n = 50)	p values*
Gender: Male	30 (55.6%)	24 (44.4%)	0.316
Gender: Female	20 (43.5%)	26 (56.5%)	0.316
Comorbidities (no/yes)	40 (80) / 10 (20)	41 (82) / 9 (18)	1.000
Hypertension (no/yes)	42 (84) / 8 (16)	41 (82) / 9 (18)	1.000
Iron deficiency (no/yes)	50 (100) / -	49 (98) / 1 (2)	1.000
Diabetes mellitus (no/yes)	48 (98) / 2 (4)	50 (100) / -	0.495
Ischemic brain disease (no/yes)	49 (98) / 1 (2)	50 (100) / -	1.000
Chronic obstructive pulmonary disease (no/yes)	48 (98) / 2 (4)	50 (100) / -	0.495
Chronic kidney disease (no/yes)	49 (98) / 1 (2)	50 (100) / -	1.000
Hypertrophio prostatae benigna (no/yes)	49 (98) / 1 (2)	49 (98) / 1 (2)	1.000
Other diseases (no/yes)	47 (94) / 3 (6)	50 (100) / -	0.242

* χ^2 test; data are presented as absolute numbers (%)

Table 2. Epidemiological and clinical features of the patients treated with VATS and standard surgery

Epidemiological and clinical characteristics of the patients	VATS (n = 50)	Thoracotomy (n = 50)	p values*
Age (years)	39.5 (27–59.25)	39.5 (33–55.75)	0.588
Body mass index (kg/m ²)	23.9 (22.5–26.4)	24.21 (22.70–26.8)	0.424
Number of comorbidities	0 (0–0)	0 (0–0)	0.735
Charlson Comorbidity Index	0 (0–0)	0 (0–0)	0.828
Number of drugs	0 (0–2.25)	0 (0–2)	0.676
Tumor size (mm)	60 (50–80)	60 (50–95)	0.566

Data are presented as median (IQR – 25–75th percentile);

* Mann–Whitney test

Table 3. Comedication in the group treated with VATS and with the open surgery

Comedication	VATS (n = 50)	Thoracotomy (n = 50)	p values*
Pronison® (mg)	0 (00–20)	0 (0–20)	0.597
Imuran® (mg)	0 (0–0)	0 (0–0)	0.111
Proton pump inhibitors–IPP (mg)	0 (0–40)	0 (0–40)	0.832
Vitamin D–Alpha D3 (mcg)	0 (0–50)	0 (0–50)	0.664
Number of drugs	0 (0–5)	0 (0,00–5)	0.664

Data are presented as median (IQR – 25–75th percentile);

* Mann–Whitney test

Table 4. Surgical outcomes compared between the patients treated with VATS and with open thymectomy

Surgical outcomes	VATS (n = 50)	Thoracotomy (n = 50)	p values*
Duration of operation (min)	50 (45–60)	120 (90–150)	< 0.001
Duration of hospitalisation (days)	4 (3–6)	9 (7–10.25)	< 0.001
Thoracic drainage (days)	2 (1–3)	4 (3–5)	< 0.001
Late control (months)	12 (12–12)	11 (9–12)	< 0.001
Visual analogue scale (0–10)	2 (1–3)	2 (2–3)	0.305
Reccurrence time (months)	0 (0–0)	0 (0–1.50)	0.268

Data are presented as median (IQR – 25–75th percentile);

*Mann–Whitney test

significantly earlier (11 months vs. 12 months after the surgery, $p < 0.001$). The patients underwent thoracotomy who came earlier to the late control (five patients or 10% thoracotomy-treated) had the intercostal neuralgia (two patients or 4% thoracotomy-treated), psychiatric problems linked with the treatment (one patient or 2% thoracotomy-treated) and neurological exacerbation (two patients or 4%

thoracotomy-treated). There was no difference in regard to visual analogue score, as well as in the time of recurrence between the groups ($p = 0.305$, $p = 0.268$) (Table 4).

DISCUSSION

Our study results obtained from the analyzing and comparing oncological and perioperative outcomes of the VATS thymectomy and standard thoracotomy support VATS as the recommended approach in the I–II stage of the thymus tumor.

Consistently with our results is the recommendation of the VATS technique as a “gold standard” for the I–II stage of the tumor [9, 14, 15, 16]. For III–IV thymoma there are no data on long-term survival of the patients, so that open surgery is suggested as a therapeutic approach [9, 14, 15, 16]. Based on the previous cited recommendations and ethical principles, our study design did not include stage III–IV thymoma, also excluding other comorbidities’ influence upon treatment decision among study patients.

Numerous studies confirm the equal efficacy of VATS thymectomy compared to standard sternotomy, comparable radicalism, and long-term survival, with a better cosmetic effect, lower intensity of postoperative pain and blood loss, reduced hospitalization time, lower early and late postoperative morbidity [7, 16–30].

Besides thymoma, some study data referred the importance of VATS surgery in myasthenia gravis treatment. Thymectomy in patients with myasthenia gravis supported stable clinical course, leading to clinical remission and reduce the dose of comedications used in conservative treatment [7]. A 12-year-long study that monitored the long-term efficacy of VATS thymectomy as part of the treatment of non-myomatous myasthenia gravis suggests an improvement in 91.6% of surgical cases and a stable remission of 22.2% [18]. There was no measurable difference between the study groups in the daily dose of comedications used in conservative treatment of myasthenia gravis and its side effects (osteoporosis, acute gastritis), supporting previous data considering comparable radicalism. It seems to be important; having in mind that post-thymectomy myasthenia gravis is reported in almost 3% of the operated patients, mostly after standard procedure [5, 6, 7].

Assessing efficacy through the mass of the removed tissue, Lee et al. [19] stated that there is no difference between VATS and open surgery in terms of radicalism of the procedure. Comparable oncological outcomes also refer to Ye et al. [20]. Wang et al. [21] report that there is no difference in terms of a five-year survival between the patients subjected to VATS and open surgery as part of the treatment of thymoma. The same conclusions arise from the studies of Chao et al. [22], as well as Qi et al. [23].

Zahid et al. [24] point out the equivalent postoperative mortality and achieve a stable remission of VATS compared to open surgery. In addition, their study results highlight the superiority of VATS in terms of duration of hospitalization, bleeding, cost of surgery, intensity of

pain, and cosmetic effect [24–27]. Ashleigh et al. [25] in meta-analysis underlined the results that are consistent with the referred data. Our study data supported previous cited reports considering duration of VATS procedure and hospitalization, thoracic drainage, with the equal intensity of pain objectified by the visual analogue scale. In addition, recurrences occur with a frequency 0–6.7%, which is comparable to open thymectomy [15, 26, 27]. The recently published meta-analysis, which involved about 1200 patients, points out that VATS is superior in terms of safety (lower incidence of complications and myasthenic crisis) compared to open surgery and equally effective in achieving a complete stable remission [28].

Our results are in accordance with previous referred study findings, especially in the term of late control. The group treated with VATS had the third (late) control later than the group treated with standard thymectomy because they had fewer complications with the comparable time of recurrence.

In Serbia, the first VATS thymectomy was applied in 2012. The Military Medical Academy data referred 70 VATS thymectomies done by three-, two-, and uniportal approach until the end of 2018 [7]. With the improvement of surgical technique, VATS uniportal approach becomes standard and dominant in the Clinic for Thoracic Surgery of the Military Medical Academy in the treatment of stage I–II thymus tumors.

Our study, involving 116 patients, presents a respectable contribution to the further analysis of clinically significant data on VATS thymectomy as an alternative operating pathway for treating I–II patients with thymic tumor compared to standard thymectomy. Results obtained in this study indicate the benefit of VATS thoracoscopy compared to standard thymectomy, which is reflected in greater safety and equal or greater efficacy of VATS, as well as in a lower incidence of postoperative complications and faster recovery. VATS thymectomy is far less invasive and represents an equally effective solution compared to standard sternotomy. Postoperative procedure includes a low-intensity pain, while the scar is small. In addition, the intervention itself can be well presented and documented. Recovery is significantly shorter, and the costs of treatment are lower. The length of home treatment and absence from work is also significantly shorter in patients treated with VATS. Possible complications of VATS thymectomy could include intercostal neuralgia, psychiatric problems linked with the treatment, neurological exacerbation, just like those in alternative methods of thymectomy, but less frequent.

Limitations of our study are retrospective character of the study and great number of excluded patients due to restrictive inclusion criteria.

CONCLUSION

Compared to standard sternotomy, VATS thymectomy is equally as effective and a significantly safer method with a minimum rate of intra and postoperative complications. Our findings support previous study results considering

VATS thymectomy as a gold standard for malignant thymus tumour (stage I and II). Further study on the greater numbers of participants would be necessary to define the effectiveness of VATS surgery for the stage III–IV thymoma according to the Masaoka classification.

Limitation of the study

Limitations of our study are retrospective character of the study and great number of excluded patients due to restrictive inclusion criteria.

Ethical approval

All procedures performed in studies involving human participants were in accordance with the ethical standards of

the Ethical Commission of the University of Belgrade, Faculty of Medicine, and with the 1964 Helsinki declaration and its later amendments or comparable ethical standards. All procedures performed in study involving human participants were in accordance with the ethical standards of the Ethical Commission of Belgrade University of Defense (Ethical Approval from October 30, 2018) Informed consent was obtained from all individual participants included in the study.

ACKNOWLEDGMENTS

This work was not financed nor funded.

Conflict of interest: None declared.

REFERENCES

- Jaković R. Anatomija i kliničko radiološka podela medijatinuma. U: Jaković R. Tumori pluća–dijagnostika i hirurško lečenje. Jugoslovenska knjiga: Beograd; 2000. p. 541–6.
- Chung DA. Thymic carcinoma – analysis of nineteen clinicopathological studies. *Thorac Cardiovasc Surg.* 2000;48(2):114–9.
- Wu J, Fang W, Chen G. The enlightenments from ITMIG Consensus on WHO histological classification of thymoma and thymic carcinoma: refined definitions, histological criteria, and reporting. *J Thorac Dis.* 2016;8(4):738–43.
- Odaka M, Tsukamoto Y, Shibasaki T, Mori S, Asano H, Yamashita M, et al. Surgical and oncological outcomes of thoracoscopic thymectomy for thymoma. *J Vis Surg.* 2017;3:54.
- Rusidanmu A, Feng M, Xu J, Wang L, He C, Hu J. Trans-sternotomy versus video-assisted thoracic surgery for early-stage thymoma patients: a meta-analysis. *Gland Surg.* 2020;9(2):342–51.
- Kondo K, Monden Y. Myasthenia gravis appearing after thymectomy for thymoma. *Eur J Cardiothorac Surg.* 2005;28(1):22–5.
- Martić V, Marić N, Cvijanović V. The neurological outcome of patients with myasthenia gravis underwent thymectomy via sternotomy and video assisted thoracoscopic surgery (VATS). *Vojnosanit Pregl.* 2020. [in press]. [DOI: 10.2298/VSP190715133M]
- Detterbeck FC, Nicholson AG, Kondo K, Van Schil P, Moran C. The Masaoka-Koga stage classification for thymic malignancies: clarification and definition of terms. *J Thorac Oncol.* 2011;6(7 Suppl 3):S1710–6.
- Girard N, Ruffini E, Marx A, Faivre-Finn C, Peters S, ESMO Guidelines Committee. Thymic epithelial tumors: ESMO Clinical Practice Guidelines for diagnosis, treatment and follow-up. *Ann Oncol.* 2015;26(Suppl 5):v40–55.
- Tianci C, Shen Z, Chen S, Lin Y, Gao L, Zhang Z, et al. Median sternotomy versus minimally invasive thymectomy for early-stage thymoma: A systematic review and meta-analysis protocol. *Medicine (Baltimore).* 2019;98(51):e18359.
- Okumura M, Shiono H, Inoue M, Tanaka H, Yoon HE, Nakagawa K, et al. Outcome of surgical treatment for recurrent thymic epithelial tumors with reference to world health organization histologic classification system. *J Surg Oncol.* 2007;95(1):40–4.
- Drevet G, Collaud S, Tronc F, Girard N, Maury JM. Optimal management of thymic malignancies: current perspectives. *Cancer Manag Res.* 2019;11:6803–14.
- Wang GW, Tao T, Li CK, Li QC, Duan GX, Sang HW, et al. Comparison between thoracoscopic and open approaches in thymoma resection. *J Thorac Dis.* 2019;11(10):4159–68.
- Marulli G, Rea F, Melfi F, Schmid TA, Ismail M, Fanucchi O, et al. Robot-aided thoracoscopic thymectomy for early-stage thymoma: a multicenter European study. *J Thorac Cardiovasc Surg.* 2012;144(5):1125–30.
- Erşen E, Kılıç B, Kara HV, İşcan M, Sarbay I, Demirkaya A, et al. Comparative study of video-assisted thoracoscopic surgery versus open thymectomy for thymoma and myasthenia gravis. *Wideochir Inne Tech Maloinwazyjne.* 2018;13(3):376–82.
- Okumura M, Shintani Y, Ohta M, Kadota Y, Inoue M, Shiono H. Minimally invasive surgical procedures for thymic disease in Asia. *J Vis Surg.* 2017;27(3):96.
- Takeo S, Shoji F, Toyokawa G, Kozuma Y, Yamazaki K. Video-assisted thoracoscopic thymectomy for early-stage thymoma: A review. *Glob Surg.* 2019;5(5):1–5.
- Manlulu A, Lee TW, Wan I, Law TY, Chang C, Garzon JC, et al. Video-assisted thoracic surgery thymectomy for nonthymomatous myasthenia gravis. *Chest.* 2005;128(5):3454–60.
- Lee CY, Kim DJ, Lee JG, Park IK, Bae MK, Chung KJ. Bilateral video-assisted thoracoscopic thymectomy has a surgical extent similar to that of transsternal extended thymectomy with more favorable early surgical outcomes for myasthenia gravis patients. *Surg Endosc.* 2011;25(3):849–54.
- Ye B, Tantai JC, Ge XX, Li W, Feng J, Cheng M, et al. Surgical techniques for early-stage thymoma: video-assisted thoracoscopic thymectomy versus transsternal thymectomy. *J Thorac Cardiovasc Surg.* 2014;147(5):1599–603.
- Wang H, Gu Z, Ding J, Tan L, Fu J, Shen Y, et al. Perioperative outcomes and long-term survival in clinically early-stage thymic malignancies: video-assisted thoracoscopic thymectomy versus open approaches. *J Thorac Dis.* 2016;8(4):673–9.
- Chao YK, Liu YH, Hsieh MJ, Wu YC, Chen TP, Lu MS, et al. Long-term outcomes after thoracoscopic resection of stage I and II thymoma: a propensity-matched study. *Ann Surg Oncol.* 2015;22(4):1371–6.
- Qi K, Wang B, Wang B, Zhang LB, Chu XY. Video-assisted thoracoscopic surgery thymectomy versus open thymectomy in patients with myasthenia gravis: a meta-analysis. *Acta Chir Belg.* 2016;116(5):282–8.
- Zahid I, Sharif S, Routledge T, Scarci M. Video-assisted thoracoscopic surgery or transsternal thymectomy in the treatment of myasthenia gravis? *Interact Cardiovasc Thorac Surg.* 2011;12(1):40–6.
- Ashleigh Xie, Richard T, Kevin P, Tristan DY. Video-assisted thoracoscopic surgery versus open thymectomy for thymoma: systematic review. *Ann Cardiothorac Surg.* 2015;4(6): 495–508.
- Kondo K, Monden Y. Therapy for thymic epithelial tumors: a clinical study of 1,320 patients from Japan. *Ann Thorac Surg.* 2003;76(3):878–84; discussion 884–5.
- Fiorelli A, Mazzella A, Cascone R, Caronia FP, Arrigo E, Santini M. Bilateral thoracoscopic extended thymectomy versus sternotomy. *Asian Cardiovasc Thorac Ann.* 2016;24(6):555–61.
- Qi K, Wang B, Wang B, Zhang YB, Chu XY. Video-assisted thoracoscopic surgery thymectomy versus open thymectomy in patients with myasthenia gravis: a meta-analysis. *Acta Chir Belg.* 2016;116(5):282–8.
- Mineo TC, Ambrogi V. Video-assisted thoracoscopic thymectomy surgery: Tor Vegata experience. *Thorac Cardiovasc Surg.* 2015;63(3):187–93.
- Muhammad MI. Thymectomy by video-assisted thoracoscopy versus open surgical techniques. *Asian Cardiovasc Thorac Ann.* 2014;22:442–7.

Поређење видеоасистиране торакоскопске хирургије и стандардног хируршког приступа у лечењу малигнух тумора тимуса I и II стадијума – анализа „пропензити скором“

Вања Костовски¹, Милена Пандрц², Александар Ристановић¹, Дејан Стојковић¹, Небојша Марић¹, Владо Цвијановић¹, Љубинко Ћенић¹, Александар Николић¹, Слободан Милисављевић³

¹Војномедицинска академија, Клиника за грудну и кардиохирургију, Београд, Србија;

²Војномедицинска академија, Клиника за кардиологију, Београд, Србија;

³Клинички центар Крагујевац, Клиника за општу и грудну хирургију, Крагујевац, Србија

САЖЕТАК

Увод/Циљ Хируршко лечење тумора тимуса (тимектомије) може се спровести кроз стернотомни приступ или видеоасистираном торакоскопском хирургијом (ВАТС).

Циљ студије је да упореди онколошке и периоперативне исходе (интраоперативне и постоперативне компликације, дужину хоспитализације) код болесника са I и II стадијумом тумора тимуса лечених методом ВАТС или стандардном тимектомијом.

Метод Студија је обухватила болеснике са примарним тумором тимуса, I и II патохистолошког стадијума према Масаокиној класификацији, оперисане у периоду између маја 2006. и фебруара 2018. године. Од 116 болесника њих 100 (86,2%) уврштено је у анализу „пропензити скором“ према полу, старости, индексу телесне масе, мијастенији, величини тумора, стадијуму по Масаокиној класификацији. Онколошки и периоперативни исходи који утичу на ефикасност и

безбедност хируршке технике су анализирани и упоређени између две групе.

Резултати Од 50 болесника оперисаних ВАТС-ом, код 34 болесника (68%) примењен је унипортални приступ, код 13 болесника (26%) бипортални, а код три болесника (6%) трипортални приступ. ВАТС операција је значајно краће трајала ($p < 0,001$), захтевала је краћу хоспитализацију ($p < 0,001$) и употребу дрена ($p < 0,001$). Оперисани ВАТС-ом су се касније јављали ($p < 0,001$). Није било разлике у погледу ВАС скорa, као ни у погледу времена настанка рецидива између испитиваних група ($p = 0,305$, $p = 0,268$).

Закључак У односу на стандардну стернотомију, ВАТС тимектомија је подједнако ефикасна и значајно безбеднија метода са минималном стопом интраоперативних и постоперативних компликација.

Кључне речи: тимом; видеоасистирана торакоскопија; отворена тимектомија